



Combined Topography-Guided Trans-Epithelial PRK and PTK for Recalcitrant Recurrent Corneal Erosions in Lattice Corneal Dystrophy

Francesco Pignatelli ¹, Fedele Passidomo¹, Rosa Buonamassa², Alfredo Niro ¹, Giuseppe Addabbo¹

¹Eye Clinic, “SS. Annunziata” Hospital, ASL Taranto, Taranto, Italy; ²Department of Basic Medical Sciences, Neuroscience and Sense Organs, University of Bari “Aldo Moro”, Bari, Italy

Correspondence: Fedele Passidomo, Eye Clinic, “SS. Annunziata” Hospital, ASL Taranto, Via Francesco Bruno, 1, Taranto, 74121, Italy, Tel +39 3288569125, Email dotpaoli@yahoo.it

Purpose: To report morphologic and functional changes after topography-guided trans-epithelial photorefractive keratectomy (PRK) combined with phototherapeutic keratectomy (PTK) for recalcitrant recurrent corneal erosions in Lattice Corneal Dystrophy (LCD).

Methods: One case report.

Results: A 78-year-old man presented us with decreased visual acuity [20/100 in right eye (RE), and 20/400 in left eye (LE)], and redness with foreign body sensation in both eyes. Clinical examination revealed epithelial erosions, and linear stromal opacities involving the center of the cornea in both eyes, supporting the diagnosis of LCD. Several medical approaches including autologous serum, amniotic membrane extract, and nerve growth factor eye drops allowed a temporary improvement in symptoms. A single-step topography-guided trans-epithelial PRK combined with PTK (CIPTA[®]2 software, iVis Technologies) was performed in both eyes. After surface ablation using PRK, PTK was performed using masking agents (1% hydroxy-methylcellulose) to smooth the ablated surface. Subsequently, 0.02% Mitomycin C was applied over the ablated surface. At the 3-month follow-up, a resolution of corneal erosions, and stromal opacities were observed in both eyes, with a visual improvement to 20/25 in the RE and 20/50 in the LE. Furthermore, spherical equivalent, keratometric astigmatism, and corneal morphological irregularity index improved.

Conclusion: Recalcitrant corneal erosions and stromal opacities in LCD may be successfully treated using combined topography-guided trans-epithelial PRK and PTK.

Keywords: corneal dystrophy, recurrent corneal erosions, phototherapeutic keratectomy, topography-guided photorefractive keratectomy

Introduction

Lattice corneal dystrophy (LCD) is an autosomal hereditary corneal disease in which amyloid material deposits in the anterior stroma, causing linear, double-contoured lattice-like opacities primarily in the central cornea.¹ LCD is usually symmetrical, but sometimes the cornea of one eye remains clear.¹ LCD usually begins at the end of the first decade and affects males and females equally.² LCD is known to have five subtypes: LCDI, II, III, IIIA, IV.³

In type I LCD, whose prevalence is unknown, the deposits are confined to the corneal stroma without systemic amyloidosis.² This condition can lead to visual impairment for the development of diffuse central haze, recurrent corneal erosions (RCEs), and delayed epithelial healing after corneal surgical treatment.⁴

Treatment involves the management of the RCEs through a contact lens, medical therapy, phototherapeutic keratectomy (PTK), and ultimately corneal transplantation.⁵ PTK is the procedure of choice for the treatment of shallow corneal deposits, improving vision and delaying the need to perform Penetrating Keratoplasty or deep anterior lamellar keratoplasty.⁵ Unfortunately, in patients with LCD, dystrophic deposits usually recur after all aforementioned procedures.⁵

The possibility of combining photorefractive keratectomy (PRK) with PTK in patients with RCEs has been previously recognized, improving visual acuity and preventing the recurrences of the erosions.^{6,7} Furthermore, topography-guided excimer

laser treatment has been shown to be a potentially effective technique due to its ability to analyze and localize corneal irregularities and to prevent stromal and epithelial defects as well as haze development, and the final refractive result could be more predictable.⁸

Here, we report a case of unresponsive to medical therapy RCEs in LCD successfully treated with topography-guided trans-epithelial PRK combined with PTK.

Case Report

A 78-year-old man presented to our Ophthalmology Unit of “SS. Annunziata” Hospital, Taranto, complaining a progressive bilateral decreased vision, repeated episodes of sudden onset of pain with redness, and foreign body sensation. Concerning ophthalmic history, he underwent previously conventional phacoemulsification with IOL implantation in both eyes, and trabeculectomy in right eye (RE). He was under topic antiglaucoma therapy in both eyes. His visual acuity was 20/100 in RE and 20/400 in the left eye (LE). Slit lamp examination revealed corneal erosions and relevant stromal opacities with branching lines in the inferior portion of the cornea of both eyes. The lesions spared the peripheral cornea and did not involve the limbus. No other pathological findings were observed. Ophthalmological examination of the family members of our patient revealed similar clinical findings in the patient’s daughter and son, supporting the diagnosis of RCEs in LCD with an autosomal dominant inheritance.

The Institutional Review Board (IRB) of the Ophthalmology Unit of “SS. Annunziata” Hospital, Taranto approved the study protocol. All clinical procedures were conducted according to the principles of the Declaration of Helsinki. The patient provided informed consent for all procedures and their possible complications were explained. The patient gave informed consent for the publication of any case details and accompanying images. The IRB of the Ophthalmology Unit of “SS. Annunziata” Hospital, Taranto gave the approval for the publication of this case report.

Our first attempt was using autologous serum drops four times daily with no improvement at all.⁹ A treatment with amniotic membrane extract eye drops (AMEED) was started.¹⁰ Even in this case, the improvement in symptoms was temporary with no effect on the corneal opacities. The patient was subsequently placed under nerve growth factor (NGF) eye drops q.i.d.¹¹ After a few days, there was an improvement in symptoms. After one month of treatment, the patient was uncomfortable, complaining again foreign body sensation. The slit lamp examination showed corneal epithelium irregularities, RCEs, and stromal opacities.

The combined treatment with PRK and PTK was scheduled in both eyes, firstly in the LE and, after 2 weeks in the RE. A trans-epithelial topography-guided approach using the iRes[®] excimer laser platform (iVIS Technologies, Taranto, Italy) was performed under topical oxibuprocaine anesthesia.

The customized treatment was based on refractive and morphological data including spherical error collected by the visual acuity examination; biometric data including anterior chamber depth, intraocular lens (IOL) power, and axial length; corneal morphological irregularity index (CMI) measured by tomographer (Precisio2[®], iVIS Technologies, Taranto, Italy); target refractive zone and ablation zone defined by the projection of an ideal pupil, identified by dynamic pupillometry (pMetrics[®], iVIS Technologies, Taranto, Italy), onto the ideal corneal surface. The Corneal Interactive Programmed Topographic Ablation software (CIPTA[®], iVIS Technologies, Taranto, Italy) determined the volume of ablation as the intersection between the anterior shape detected by the tomographer and the ideal shape determined taking care of the total corneal astigmatism and of the high order of aberrations, by means of a ray tracing process.^{8,12}

The customized ablation profile obtained with PRK, had a refractive zone of 5.00 mm in RE and 3.8 mm in LE, and a connecting zone of 8.80 mm in RE and 9.1 mm in LE. The cumulative ablation depth was 34 μ m in the RE and 90 μ m in the LE. After surface ablation, PTK was performed using masking agents (1% hydroxy-methylcellulose) to smooth the ablated surface. Subsequently, 0.02% Mitomycin C (MMC, 0.2 mg/mL, diluted in BSS[®]) was applied over the ablated surface for a duration of 20 seconds. At the end of the procedure, a soft therapeutic contact lens was placed.

Postoperatively, topical dexamethasone and amikacin eye drops were administered four times daily for one week. The patient was then put on 0.1% fluorometholone eye drops and artificial tears eye drops for 12 weeks, which were gradually tapered afterward. The contact lens was removed after 1 week. At the 3-month follow-up, a slit lamp examination revealed a clear central cornea in both eyes (Figure 1).

The final visual acuity improved to 20/25 in the RE and 20/50 in the LE at 3 months after treatment. The keratometric astigmatism improved from -1.71 D to -0.92 D in RE, and from -5.43 D to -1.12 D in LE. CMI decreased from 16.04

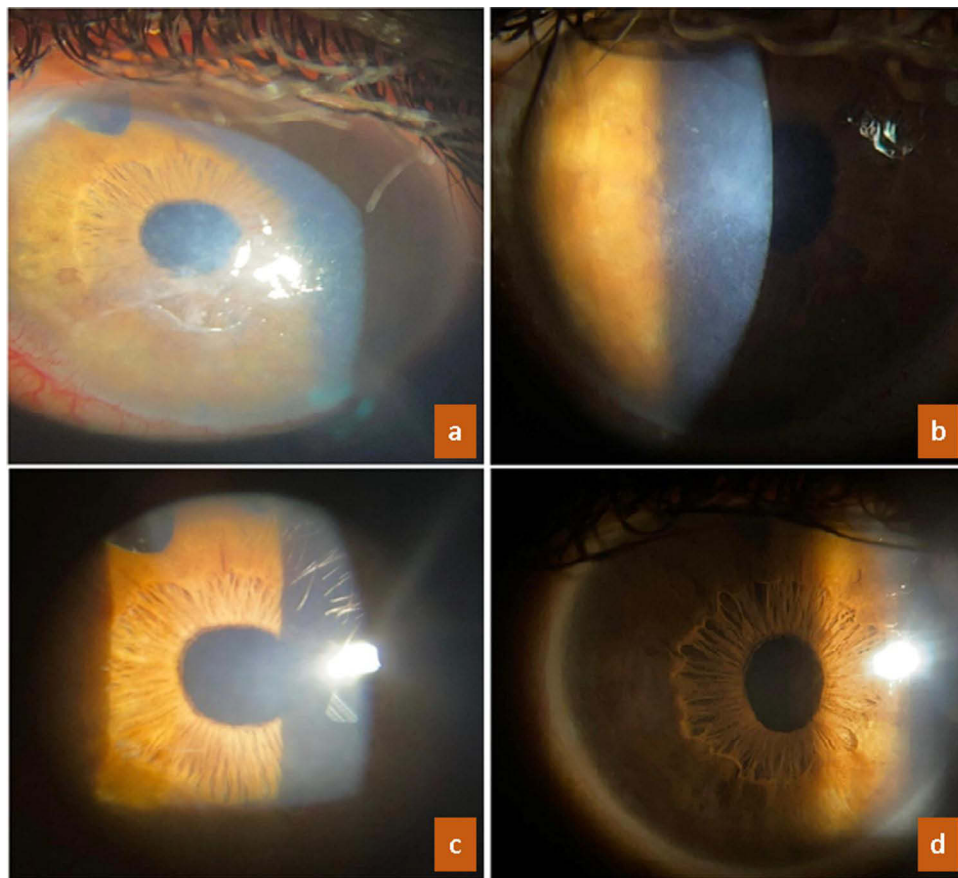


Figure 1 ((a), right eye; (b), left eye) Slit-beam photographs demonstrate stromal opacities with branching lines in both eyes, complicated by corneal erosions in right eye; ((c), right eye; (d), left eye) after 3 months from combined excimer laser treatment, corneal clarity has been recovered with the resolution of epithelial erosions and the disappearance of stromal opacities.

μm to $7.84 \mu\text{m}$ in RE and from $53.07 \mu\text{m}$ to $37.04 \mu\text{m}$ in LE, and minimum corneal thickness was reduced from $570 \mu\text{m}$ to $508 \mu\text{m}$ in RE, and from $576 \mu\text{m}$ to $452 \mu\text{m}$ in LE. The postoperative follow-up was uneventful. The ablation map and topographic changes of both eyes were reported in Figures 2 and 3.

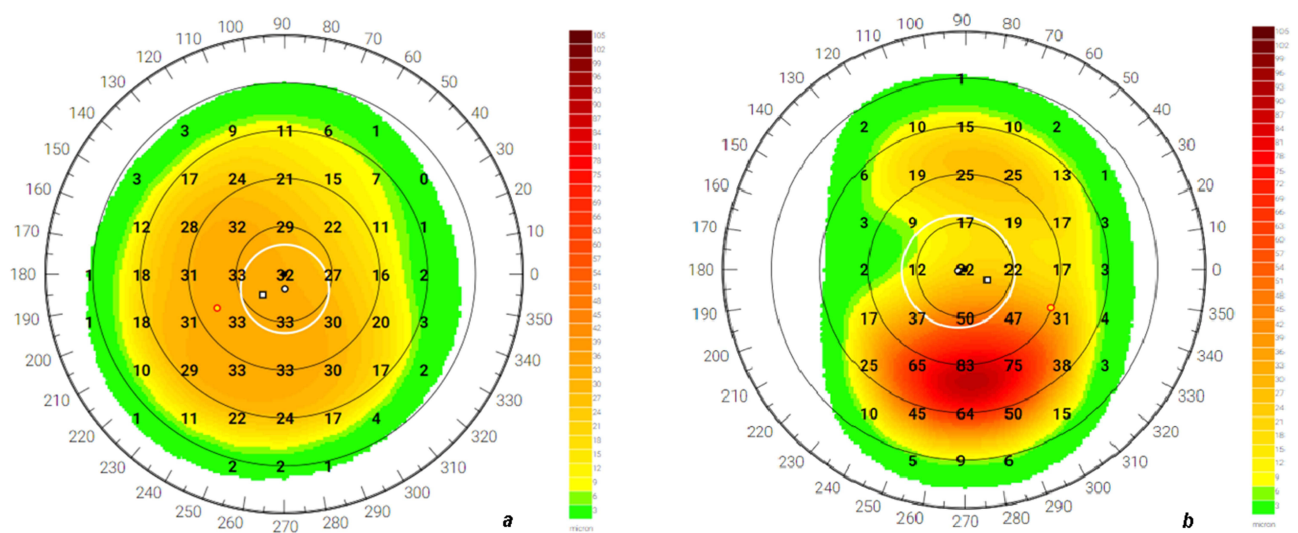


Figure 2 Ablation map of right (a) and left (b) eye.

steepening flatter areas, and reduces the risk of glare. However, topographic treatment analysis should be integrated with measurements obtained from manifest spherocylindrical refraction, allowing to obtain predictable refractive results.

In the literature, there are only a few cases of RCE syndrome in corneal dystrophies treated with refractive surgery.^{6,7} To our knowledge, this is the first case of RCEs in LCD, unresponsive to medical therapy, successfully treated with a combined approach using a topography-guided trans-epithelial no-touch ablation with PRK and PTK. The major advantage of this approach is the possibility of removing in a single step the necessary fraction of epithelium and stroma according to the planned ablation profile. Its efficacy could be ensured by the reduced influence of the epithelial thickness variability using the trans-epithelial approach, and by the increased predictability of the refractive results thanks to the customized topography-guided laser treatment that is centered on the corneal apex rather than the pupil center, also addressing the issue of angle k .

Combining topography-guided trans-epithelial no-touch PRK and PTK could be an effective treatment for epithelial erosions and stromal opacities in LCD after unsuccessfully medical therapy. It could be helpful in preventing the recurrence of corneal erosions, and improving visual acuity. This procedure needs a longer follow-up and further study to evaluate its efficacy.

Funding

There is no funding to report.

Disclosure

There are no conflicts of interest.

References

1. Zhu F, Li M, Zhang C, Chen C, Ying F, Nie D. In vivo confocal microscopy qualitative investigation of the relationships between lattice corneal dystrophy deposition and corneal nerves. *BMC Ophthalmol*. 2021;21(1):449. doi:10.1186/s12886-021-02149-1
2. Weiss JS, Møller HU, Aldave AJ, et al. IC3D classification of corneal dystrophies. *Cornea*. 2015;34(2):117–159. doi:10.1097/ICO.0000000000000307
3. Lisch W, Weiss JS. Clinical and genetic update of corneal dystrophies. *Exp Eye Res*. 2019;186:107715. doi:10.1016/j.exer.2019.107715
4. Resch MD, Schlötzer-Schrehardt U, Hofmann-Rummelt C, Kruse FE, Seitz B. Alterations of epithelial adhesion molecules and basement membrane components in lattice corneal dystrophy (LCD). *Graefes Arch Clin Exp Ophthalmol*. 2009;247(8):1081–1088. doi:10.1007/s00417-009-1046-1
5. Han KE, Choi S, Kim T, et al. Pathogenesis and treatments of TGFBI corneal dystrophies. *Prog Retin Eye Res*. 2016;50:67–88. doi:10.1016/j.preteyeres.2015.11.002
6. Kremer I, Blumenthal M. Combined PRK and PTK in myopic patients with recurrent corneal erosion. *Br J Ophthalmol*. 1997;81:551–554. doi:10.1136/bjo.81.7.551
7. Zaidman GW, Hong A. Visual and refractive results of combined PTK/PRK in patients with corneal surface disease and refractive errors. *J Cataract Refract Surg*. 2006;32(6):958–961. doi:10.1016/j.jcrs.2005.11.046
8. Spadea L, Visioli G, Mastromarino D, Alexander S, Pistella S. Topography-guided trans-epithelial no-touch photorefractive keratectomy for high irregular astigmatism after penetrating keratoplasty: a prospective 12-months follow-up. *Ther Clin Risk Manag*. 2021;17:1027–1035. doi:10.2147/TCRM.S329932
9. Lee JH, Kim MJ, Ha SW, Kim HK. Autologous platelet-rich plasma eye drops in the treatment of recurrent corneal erosions. *Korean J Ophthalmol*. 2016;30(2):101. doi:10.3341/kjo.2016.30.2.101
10. Sabater-Cruz N, Figueras-Roca M, Ferrán-Fuertes M, et al. Amniotic membrane extract eye drops for ocular surface diseases: use and clinical outcome in real-world practice. *Int Ophthalmol*. 2021;41(9):2973–2979. doi:10.1007/s10792-021-01856-4
11. Bonini S, Lambiasi A, Rama P, et al. Phase II randomized, double-masked, vehicle-controlled trial of recombinant human nerve growth factor for neurotrophic keratitis. *Ophthalmology*. 2018;125(9):1332–1343. doi:10.1016/j.ophtha.2018.02.022
12. Guccione L, Mosca L, Legrottaglie EF, et al. Customized therapeutic ablation with A 1000 Hz excimer laser after corneal surgery. *Invest Ophthalmol Vis Sci*. 2011;52(14):5752.
13. Rosenberg ME, Tervo TM, Petroll WM, Vesaluoma MH. In vivo confocal microscopy of patients with corneal recurrent erosion syndrome or epithelial basement membrane dystrophy. *Ophthalmology*. 2000;107(3):565–573. doi:10.1016/s0161-6420(99)00086-x
14. Oxervate - EMEA/H/C/004209 - R/0037 Oxervate: EPAR - Product Information. Available from: https://www.ema.europa.eu/en/documents/product-information/oxervate-epar-product-information_en.pdf. Accessed May 4, 2023.

International Medical Case Reports Journal

Dovepress

Publish your work in this journal

The International Medical Case Reports Journal is an international, peer-reviewed open-access journal publishing original case reports from all medical specialties. Previously unpublished medical posters are also accepted relating to any area of clinical or preclinical science. Submissions should not normally exceed 2,000 words or 4 published pages including figures, diagrams and references. The manuscript management system is completely online and includes a very quick and fair peer-review system, which is all easy to use. Visit <http://www.dovepress.com/testimonials.php> to read real quotes from published authors.

Submit your manuscript here: <https://www.dovepress.com/international-medical-case-reports-journal-journal>