

# Appropriate Delivery of Antitachyarrhythmia Therapy Despite Magnet Placement Over Implanted Cardioverter-Defibrillator: A Case Report

Vishal K. Gajendran, MD,\* Tahmeed Contractor, MBBS,† Ryan C. Tone, MD,\* Carin R. Mascetti, MD,\* and Melissa D. McCabe, MD, MSCR\*

The fundamental perioperative concern for patients with implantable cardioverter-defibrillators (ICDs) is the potential for electromagnetic interference (EMI) from monopolar electrosurgery. The ICD may interpret electromagnetic signals as a tachyarrhythmia and deliver an inappropriate shock to the patient. Magnet placement is often used to avoid this problem since a magnet will often deactivate an ICD's tachyarrhythmia therapy. We report a case in which magnet placement over an ICD failed to suspend tachyarrhythmia therapy because of imprecise magnet positioning. This case demonstrates the possibility for error when relying on a magnet to suspend tachyarrhythmia therapies. (A&A Practice. 2021;15:e01465.)

## GLOSSARY

**ACC** = American College of Cardiology; **AHA** = American Heart Association; **ASA** = American Society of Anesthesiologists; **BOL** = beginning of life; **CIED** = cardiac implantable electronic device; **EMI** = electromagnetic interference; **ERI** = elective replacement indicator; **HRS** = Heart Rhythm Society; **ICD** = implantable cardioverter-defibrillator; **VF** = ventricular fibrillation; **VS** = ventricle sensed

The principal perioperative issue in patients with implantable cardioverter-defibrillators (ICDs) is potential electromagnetic interference (EMI) generated from monopolar electrosurgery. This can result in inappropriate tachyarrhythmia detection and resultant therapy including shocks. To avoid this problem, anesthesia providers must be prepared to inactivate tachyarrhythmia therapies when EMI is likely. Suspension of tachyarrhythmia therapies can be done via manual device reprogramming or by placing a magnet on the device. Many providers use a magnet to suspend anti-tachycardia therapy; however, there are reports of failed magnet response and inappropriate shock with EMI.<sup>1-5</sup> In addition, when using a magnet, many providers routinely position the magnet centrally over the device; however, some manufacturers recommend off-center magnet placement.

We report a case where, despite placement of a magnet over an ICD, it failed to suspend the tachyarrhythmia therapy and the patient received an appropriate shock for ventricular fibrillation (VF) shortly after induction of

anesthesia. We discuss the reasons a response may not be elicited by a magnet and the magnet usage guidelines from each manufacturer. Health Insurance Portability and Accountability Act written authorization for publication of the case report was obtained from the patient.

## CASE DESCRIPTION

A 52-year-old man with a prior history of cecal volvulus, right hemicolectomy, and loop ileostomy presented for ileostomy reversal. His medical history included coronary artery disease with a prior myocardial infarction, American College of Cardiology (ACC) class C heart failure with reduced ejection fraction (left ventricular ejection fraction of 25%), severe mitral regurgitation, and associated World Health Organization class 2 moderate pulmonary hypertension. An ICD (Fortify Assura VR 1357-40Q Abbott, formerly St Jude Medical, Sylmar, CA) with optisure bipolar lead was placed 8 months prior. It was programmed for the detection and therapy of VF at 200 bpm and to only monitor for ventricular tachycardia at 171 bpm. Bradycardia parameters were programmed to VVI 40 bpm. The patient completed an outpatient ICD interrogation 3 months prior. The underlying rhythm was sinus at 98 bpm, and there was no evidence of tachyarrhythmias or pacing dependence. He was on ACC/American Heart Association (AHA) guideline-directed medical therapy for heart failure and was felt to be euvolemic before surgery.<sup>6</sup>

Before induction, standard American Society of Anesthesiologists (ASA) monitors were placed, and the radial artery was cannulated. Induction proceeded with lidocaine, propofol, fentanyl, and rocuronium, followed by endotracheal intubation. Phenylephrine was bolused as needed to maintain systolic blood pressure >130 mm Hg and mean arterial pressure 80 to 90 mm Hg. A magnet was placed centrally over the ICD generator and secured in place with tape. The patient was positioned supine, prepped, and draped with an electrosurgery

From the \*Department of Anesthesiology and †Department of Cardiology, Loma Linda University, Loma Linda, California.

Accepted for publication April 5, 2021.

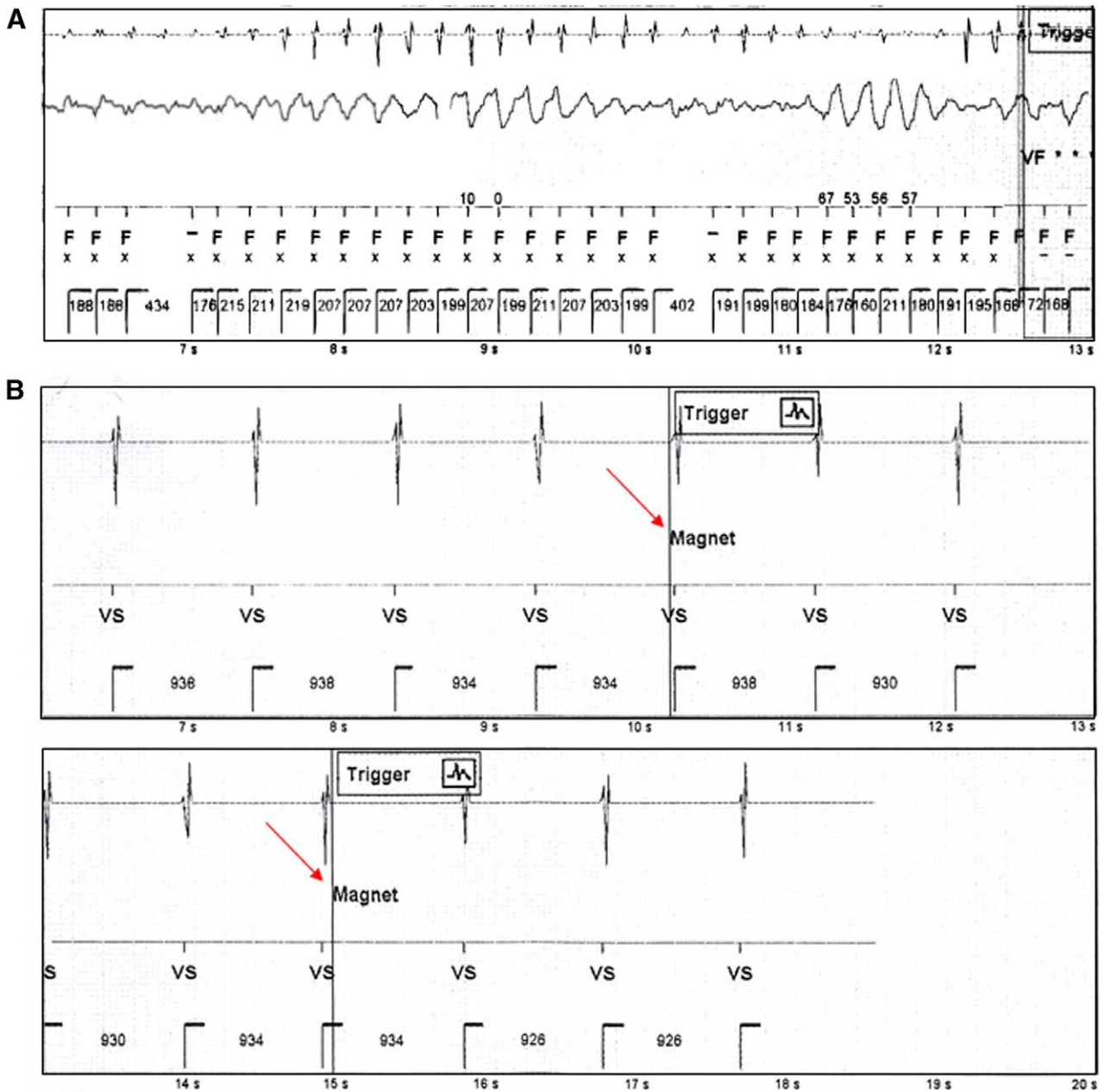
Funding: Supported by the Department of Anesthesiology, Loma Linda University.

The authors declare no conflicts of interest.

Address correspondence to Melissa D. McCabe, MD, Department of Anesthesiology, Loma Linda University, 11234 Anderson St, MC 2532, Loma Linda, CA. Address e-mail to mmccabe@llu.edu.

Copyright © 2021 The Author(s). Published by Wolters Kluwer Health, Inc. on behalf of the International Anesthesia Research Society. This is an open-access article distributed under the terms of the Creative Commons Attribution-Non Commercial-No Derivatives License 4.0 (CCBY-NC-ND), where it is permissible to download and share the work provided it is properly cited. The work cannot be changed in any way or used commercially without permission from the journal.


DOI: 10.1213/XAA.0000000000001465



**Figure 1.** Device interrogation. A, Detection of VF and tachycardia therapy. B, Initial magnet detection disabling tachycardia therapies was followed by intermittent periods of device activation. Although the magnet was never removed, magnet response was detected 6 discrete times. The red arrows in the figure indicate 2 distinct episodes of magnet detection separated by approximately 5 s. Since the magnet remained secured in place, repeated magnet detection is most likely related to failure to maintain an adequate magnetic field due to inaccurate placement. VF indicates ventricular fibrillation; VS, ventricle sensed.

dispersive electrode (COVIDIEN, Mansfield, MA) placed on the right outer thigh. Before incision, the patient developed VF and hemodynamic instability with loss of pulsatility in the arterial line waveform. Although the magnet remained secured over the generator, the ICD delivered appropriate therapy before the anesthesiologists attempted to remove the magnet. Hemodynamics were supported with 10- $\mu$ g epinephrine and pressures normalized after normal sinus rhythm was restored. Anesthesiology and surgery teams decided to postpone the case pending cardiac electrophysiology evaluation.

The patient was extubated and transported to the postanesthesia care unit. The ICD was interrogated, confirming ventricular arrhythmia and appropriate therapy (Figure 1A). Notably, magnet detection by the device was intermittent (Figure 1B) despite the magnet being secured in position without disruption. A detailed discussion with the cardiac electrophysiology team and Abbott technical services revealed that the cause of this phenomenon was inaccurate placement of the magnet centrally over the device.



**Figure 2.** Magnet positioning. A, Abbott (formerly St Jude Medical) Fortify Assura DR. The arc of the magnet is positioned over the right or left side of the device. B, Biotronik Intica VR-T DX Magnet is positioned off center with the arc slightly above the housing. The arrow denotes the space between the arc of the magnet and the top of the generator. C, Boston Scientific Mini ICD, (D) Medtronic Evera XT DR, and (E) MicroPort (formerly Sorin) Platinum Magnet centered over the device. ICD, implantable cardioverter-defibrillator.

**Table. Manufacturer Recommendations**

| Manufacturer                 | Abbott <sup>a9</sup>  | Biotronik <sup>d10</sup>   | Boston Scientific <sup>d11,12</sup>   | Medtronic <sup>d13</sup>                              | MicroPort <sup>b14</sup>                                    |
|------------------------------|---|--|---|---|---|
| Magnet position              | The magnet should be positioned off-center so that the curve of the 'donut' magnet is over the left or right side of the device (Figure 2A) | Place the magnet directly over the implanted ICD. The best placement is to offset the magnet so that the opening of the ring rests slightly above the top of the housing (Figure 2B) | Position the magnet over the middle of the pulse generator, in close proximity (within 3 cm from the pulse generator can) (Figure 2C) | Place the magnet directly over the device (Figure 2D) | Apply magnet over the ICD in the position shown (Figure 2E) |
| Tone with magnet detection   | None  | None   | Beeping tone (once per second for the duration of magnet detection) <sup>c</sup>  | Continuous tone (maximum duration 30 s) <sup>d</sup>  | None <sup>e</sup>   |
| Programmable magnet response | Yes   | No <sup>f</sup>  | Yes   | No  | No  |

Magnet positioning, detection, and associated programmability of magnet responsiveness for implantable cardioverter-defibrillator.

Abbreviations: BOL, beginning of life; ERI, elective replacement indicator; ICD, implantable cardioverter-defibrillator.

<sup>a</sup>Formerly St Jude Medical.

<sup>b</sup>Formerly Sorin.

<sup>c</sup>CONFIENT and VITALITY ICD (Boston Scientific, Marlborough, MA) will emit beeping tones synchronous with R wave for the duration of magnet detection. EMBLEM and SQ-RX (Boston Scientific, Marlborough, MA) subcutaneous ICD will emit 1 beep on magnet detection, followed by a beeping tone synchronous with the R wave for up to 60 s.

<sup>d</sup>Intermittent on/off tone occurs when there is a clinician alert. Dual high/low tone may indicate device malfunction.

<sup>e</sup>Magnet application initiates synchronous pacing (BOL 96 ppm/ERI 80 ppm) in all models except Platinum.

<sup>f</sup>After 8 h of magnet use, the device reactivates therapy functions. If suspension of tachycardia therapy is still needed, the magnet must be removed—at least 1 meter away for 5 min.

## DISCUSSION

Magnets are sometimes placed on ICD at the time of surgery to avoid EMI-related inappropriate shocks. We report a case of a magnet failing to suppress ICD firing as a result of inaccurate positioning, serendipitously leading to an appropriate shock for VF that developed after induction of anesthesia in a high-risk patient. Perioperative pacemaker and ICD management by the anesthesia provider is crucial to avoid asystole in pacing-dependent patients or inappropriate shocks in patients with ICD due to electrosurgery-related EMI.

The Heart Rhythm Society (HRS) and ASA in conjunction with the AHA, ACC, and the Society of Thoracic Surgeons have developed a consensus statement regarding perioperative cardiac implantable electronic device (CIED) management, and in 2020, the ASA released an updated practice advisory.<sup>7,8</sup> Patients with ICD should have documented device interrogation within 3 to 6 months of a surgical procedure to identify battery life, programmed therapies, pacing dependence, and tachyarrhythmias.<sup>7,8</sup> There have been case reports of inappropriate ICD therapy, CIED damage, and patient

injury with inadequate preoperative evaluation and erroneous assumptions about the effects of magnet application.<sup>1,2</sup>

When EMI is likely, magnet placement to suspend anti-tachycardia therapy may suffice in some patients with ICD that are not pacing-dependent. This presumption is not appropriate for all patients and care should be individualized.<sup>7-9</sup> The most recent ASA practice advisory cautions against indiscriminate use of magnet over an ICD.<sup>8</sup> While magnets prove useful in their ability to temporarily suspend tachyarrhythmia therapy, each device manufacturer has different specifications for proper magnet placement (Figure 2 and Table). For instance, a centrally positioned donut magnet may not maintain an adequate magnetic field to suspend tachyarrhythmia therapies on Abbott CIED. Instead, Abbott recommends placing the magnet to the side of the device in its long axis so that the arc of the magnet is over most of the generator (Figure 2A). Inaccurate magnet placement can result in inappropriate shock or life-threatening asystole during surgery. We suggest displaying a chart with appropriate magnet positioning in operating rooms, emergency rooms, or crash carts to avoid this situation.

There are several other issues with reliance on magnet application for suppression of tachycardia therapies. Only Boston Scientific and Medtronic devices emit a tone when a magnet is detected (Table). However, continuous suspension of antitachyarrhythmia therapy can only be confirmed with Boston Scientific ICD that emits a beeping tone once every second for the duration of magnet detection. Auscultation of the generator with a stethoscope may enhance the provider's ability to hear the tones when there is significant ambient noise or when the device is implanted in a deep pocket. The response to magnet application may be programmable, and in rare situations, magnet application will not suspend tachyarrhythmia therapies. For ICD with a programmable magnet response, the response to magnet application must be programmed "ON" for a magnet to suspend tachyarrhythmia therapy.

Surgical positioning also affects magnet usage. Magnets are more likely to become dislodged when surgery is performed in the prone or lateral position. Inappropriate ICD shocks have been described when a magnet was used to suspend tachyarrhythmia therapy in the lateral position.<sup>2</sup> In addition, patient habitus may complicate magnet placement. Inappropriate shock with EMI has been described in patients with high body mass index as it may be difficult to maintain an adequate magnetic field when there is excess tissue overlying the generator.<sup>4</sup> Rarely, software incompatibility between the device and programmer may contribute to problems with reprogramming.<sup>3</sup>

While the primary perioperative concern with CIED remains EMI, in this case, the ICD appropriately recognized an intrinsic, aberrant rhythm, and delivered therapy. This case demonstrates the potential for errors with reliance on magnet use. One solution for patients undergoing general anesthesia is to have expert interrogation and programming of any CIED. However, this infrastructure is not well established in many institutions. While this patient did not experience harm, this will clearly not always be the case when EMI occurs. Therefore, familiarity with manufacturer recommendations and device functionality is prudent for today's anesthesiologists.

In conclusion, we report a rare case of "appropriate" ICD detection and therapy for VF despite magnet placement. This case highlights the importance of accurate magnet placement using the recommended positioning from each device manufacturer. It is important for the anesthesiologist to ensure proper CIED function and obtain CIED-related recommendations before surgery. ■■

#### DISCLOSURES

**Name:** Vishal K. Gajendran, MD.

**Contribution:** This author helped care the patient, draft and edit the manuscript, approve the final version to be published, and ensure the accuracy and integrity of the work.

**Name:** Tahmeed Contractor, MBBS.

**Contribution:** This author helped interpret the data, draft the manuscript, approve the final version to be published, and ensure the accuracy and integrity of the work.

**Name:** Ryan C. Tone, MD.

**Contribution:** This author helped care the patient, interpret the clinical data, draft and edit the manuscript, approve the final version to be published, and ensure the accuracy and integrity of the work.

**Name:** Carin R. Mascetti, MD.

**Contribution:** This author helped draft and edit the manuscript, approve the final version to be published, and ensure the accuracy and integrity of the work.

**Name:** Melissa D. McCabe, MD, MSCR.

**Contribution:** This author helped with conception, clinical data interpretation, and drafting and editing the manuscript; has approved the final version to be published; and ensured the accuracy and integrity of the work.

**This manuscript was handled by:** BobbieJean Sweitzer, MD, FACP.

#### REFERENCES

- Schulman PM, Rozner MA. Case report: use caution when applying magnets to pacemakers or defibrillators for surgery. *Anesth Analg*. 2013;117:422–427.
- Goel V, Shankar H, Mulpuru SK, Ramakrishna H. Inappropriate defibrillator shocks during cervical medial branch radiofrequency ablation: a case report. *A A Pract*. 2020;14:e01286.
- McFaul CM, Lombaard S, Arora V, Van Cleve WC, Rooke GA, Prutkin JM. Unexpected shocks from a subcutaneous implantable cardioverter-defibrillator despite attempted reprogramming and magnet use: a case report. *A A Pract*. 2020;14:e01178.
- Streckenbach SC, Benedetto WJ, Fitzsimons MG. Implantable cardioverter-defibrillator shock delivered during electroconvulsive therapy despite magnet application: a case report. *A A Pract*. 2020;14:e01284.
- Römers H, VAN Dijk V, Balt J. Erroneous magnet positioning leads to failure of inhibition of inappropriate shock during fast conducting atrial fibrillation episodes. *Pacing Clin Electrophysiol*. 2017;40:741–743.
- Yancy CW, Jessup M, Bozkurt B, et al. 2013 ACCF/AHA guideline for the management of heart failure: executive summary: a report of the American College of Cardiology Foundation/American Heart Association Task Force on practice guidelines. *Circulation*. 2013;128:1810–1852.
- Crossley GH, Poole JE, Rozner MA, et al. The Heart Rhythm Society (HRS)/American Society of Anesthesiologists (ASA) Expert Consensus Statement on the perioperative management of patients with implantable defibrillators, pacemakers and arrhythmia monitors: facilities and patient management this document was developed as a joint project with the American Society of Anesthesiologists (ASA), and in collaboration with the American Heart Association (AHA), and the Society of Thoracic Surgeons (STS). *Heart Rhythm*. 2011;8:1114–1154.
- American Society of Anesthesiologists. Practice advisory for the perioperative management of patients with cardiac implantable electronic devices: pacemakers and implantable cardioverter-defibrillators 2020. *Anesthesiology*. 2020;132:225–252.
- Jacob S, Panaich SS, Maheshwari R, Haddad JW, Padanilam BJ, John SK. Clinical applications of magnets on cardiac rhythm management devices. *Europace*. 2011;13:1222–1230.
- Abbott. Technical Insight: Magnet Use for Abbott Implanted Cardioverter-Defibrillators. TI18 010 Rev F. February 2019.
- Biotronik. Technical Information Piece: Magnet Use for Temporarily Diabling Tachycardia Detection and Therapy in ICD Devices. April 9, 2020.
- Boston Scientific. Expected Magnet Response of Boston Scientific Pacemakers and Defibrillators. March 30, 2016. Accessed September 9, 2020. [https://www.bostonscientific.com/content/dam/bostonscientific/quality/education-resources/english-a4/EN\\_ACL\\_Magnet\\_Response\\_20160330.pdf](https://www.bostonscientific.com/content/dam/bostonscientific/quality/education-resources/english-a4/EN_ACL_Magnet_Response_20160330.pdf).
- Boston Scientific. Magnet Use With Boston Scientific Pacemakers and CRT-Ps. December 20, 2013. Accessed September 9, 2020. [https://www.bostonscientific.com/content/dam/bostonscientific/quality/education-resources/english/ACL\\_Magnet\\_Use\\_Pacemakers\\_CRTPs\\_20131220.pdf](https://www.bostonscientific.com/content/dam/bostonscientific/quality/education-resources/english/ACL_Magnet_Use_Pacemakers_CRTPs_20131220.pdf).
- Medtronic. Magnet Operation: CRHF Technical Services Standard Letter. September 2016. Accessed September 9, 2020. [https://www.medtronic.com/crs-upload/letters/102/102\\_102\\_CQES-StandardLetter-MagnetInstructions-Combined-IPG-and-ICD-FINALv2-2016-Sep02-Edit-2019-Nov12.pdf](https://www.medtronic.com/crs-upload/letters/102/102_102_CQES-StandardLetter-MagnetInstructions-Combined-IPG-and-ICD-FINALv2-2016-Sep02-Edit-2019-Nov12.pdf).
- Sorin. Sorin CRM ICD Magnet Mode Operation. Revision G ed2018.