



Combinatorial therapy is a safe and durable treatment option in *ALK*-rearranged non-small cell lung cancer with an acquired *MET* exon 14 skipping mutation mediated resistance to alectinib: a case report

Charley Jang^{1^}, Joshua Sabari²

¹Department of Medicine, NYU Grossman School of Medicine, New York, NY, USA; ²Department of Hematology and Oncology, NYU Langone Health Perlmutter Cancer Center, NYU Grossman School of Medicine, New York, NY, USA

Contributions: (I) Conception and design: Both authors; (II) Administrative support: Both authors; (III) Provision of study materials or patients: Both authors; (IV) Collection and assembly of data: Both authors; (V) Data analysis and interpretation: Both authors; (VI) Manuscript writing: Both authors; (VII) Final approval of manuscript: Both authors.

Correspondence to: Charley Jang, MD, MSc. Department of Medicine, NYU Grossman School of Medicine, 545 1st Ave, Unit 2F, New York, NY 10016, USA. Email: Charley.Jang@nyulangone.org.

Background: Anaplastic lymphoma kinase (*ALK*) tyrosine kinase inhibitors (TKIs) are standard first line treatment for *ALK*-rearranged non-small cell lung cancer (NSCLC) and have demonstrated high and durable response rates. Despite these initial responses, patients eventually develop resistance through *ALK* dependent and *ALK* independent alterations. These resistance mechanisms have made treatment decisions increasingly more complex. Here we describe a case of an acquired mesenchymal epithelial transition factor (*MET*) exon 14 skipping (*METex14*) mutation mediated resistance to alectinib in a patient with *ALK*-rearranged lung adenocarcinoma.

Case Description: We present a 72-year-old male with a 2-pack year smoking history and end-stage renal disease on hemodialysis diagnosed with metastatic lung adenocarcinoma harboring an echinoderm microtubule-associated protein 4 (*EML4*)-*ALK* fusion gene mutation. The patient was initially treated with alectinib with good response. However, the patient eventually developed resistance. Next generation sequencing of a liquid biopsy at time of progression revealed a *MET* exon 14 skip mutation. The patient was started on dual alectinib and capmatinib therapy, which led to a rapid and durable response.

Conclusions: This is the first case report of the successful treatment of *METex14* mutation mediated resistance to alectinib with combination therapy of alectinib and capmatinib, which led to a rapid and durable response in our patient. This case highlights the importance of resequencing patients at the time of progression to identify potential actionable *ALK* dependent and independent resistance alterations. Combinatorial therapy may provide a promising effective and safe therapy option for patients who acquire resistance after initial TKI therapy.

Keywords: Non-small cell lung cancer (NSCLC); combinatorial therapy; tyrosine kinase inhibitor resistance (TKI resistance); case report

Submitted Sep 23, 2023. Accepted for publication Dec 11, 2023. Published online Dec 22, 2023.

doi: 10.21037/tlcr-23-613

View this article at: <https://dx.doi.org/10.21037/tlcr-23-613>

[^] ORCID: 0009-0002-2110-862X.

Introduction

Anaplastic lymphoma kinase (*ALK*)-rearrangements occur in approximately 5% of non-small cell lung cancer (NSCLC) (1). NSCLC harboring *ALK* rearrangements are highly sensitive to *ALK* inhibitors demonstrating high and rapid response rates. Despite these robust responses, patients inevitably develop acquired resistance leading to clinical relapse. These resistance mechanisms can be classified into *ALK* dependent alterations and *ALK* independent alterations with the latter being less well characterized. *ALK* dependent mechanisms include *ALK* secondary mutations or amplification in which dependency on *ALK* signaling persists. *ALK* independent mechanisms include the activation of bypass pathways including *EGFR*, *KIT*, *HER*, *MET*, *SRC*, and *IGF-1R* pathways which result in the reactivation of downstream effectors leading to tumor cell proliferation and survival.

Identifying these resistance mechanisms is important in treating patients who acquire *ALK* resistance as *ALK* dependent alterations may indicate persistent dependence on *ALK* signaling. In these cases, alternative *ALK* tyrosine

kinase inhibitors (TKIs) may be potentially effective therapeutic options. On the other hand, *ALK* independent resistance mechanisms may necessitate an alternative therapeutic approach. Here we report a case of an acquired mesenchymal epithelial transition factor (*MET*) exon 14 skipping (*METex14*) mutation mediated resistance to alectinib in a patient with Stage IV *ALK*-rearranged lung adenocarcinoma successfully treated with combination therapy of capmatinib and alectinib. We present this case in accordance with the CARE reporting checklist (available at <https://tldr.amegroups.com/article/view/10.21037/tlcr-23-613/rc>).

Case presentation

A 72-year-old male with a 2-pack year smoking history and end-stage renal disease (ESRD) on hemodialysis presented to the emergency department with two days of chest tightness. A computed tomography (CT) scan revealed a right unilateral pleural effusion and a 1.5 cm heterogenous mass in the left lung apex. Pleural fluid cytology was significant for an *ALK*-positive metastatic lung adenocarcinoma by immunohistochemistry. Programmed death-ligand 1 (PD-L1) staining was negative. Next-generation sequencing (NGS) was performed on the pleural fluid cytoblock using the Oncomine Focus Assay targeted panel, which confirmed an echinoderm microtubule-associated protein 4 (*EML4*)-*ALK* gene fusion. No other relevant alterations, including *MET* amplification or *METex14* mutation, were identified (Table S1). A liquid biopsy using the FoundationOne Liquid CDx assay was also performed which did not identify the *ALK* rearrangement or *MET* mutations (Table 1). The patient was treated with alectinib 600 mg twice daily. Interval imaging at 5 months demonstrated overall stable disease. The patient had clinical improvement in his symptoms including shortness of breath and chest tightness. He tolerated alectinib well without significant adverse events. However, CT imaging at 7 months demonstrated interval growth of the left apical lung nodule and a new right apical nodule. Patient declined a tissue biopsy at the time of progression. A liquid biopsy using the FoundationOne Liquid CDx assay was performed, which revealed a *MET* exon 14 skip mutation (3028G>A). The *ALK* rearrangement was not identified on the liquid biopsy (Table 1).

Prior to the development of TKIs, pemetrexed-based chemotherapy was the standard front-line therapy for *ALK*-positive NSCLC as these patients have been

Highlight box

Key findings

- This case report demonstrates the safety and efficacy of dual alectinib and capmatinib therapy in acquired mesenchymal epithelial transition factor exon 14 skipping mutation mediated resistance to alectinib.

What is known and what is new?

- Despite the durable and high response rates of anaplastic lymphoma kinase (*ALK*) tyrosine kinase inhibitors (TKIs) in *ALK*-rearranged non-small cell lung cancer (NSCLC), resistance mechanisms eventually develop limiting their clinical impact.
- *ALK* independent resistance mechanisms remain less well characterized, which have made treatment decisions increasingly more complex.

What is the implication, and what should change now?

- Resequencing should be performed at time of progression as this can identify potential actionable mutation mediated resistance acquired after TKI therapy.
- Combinatorial treatment strategies should be considered as potential safe and durable treatment options for patients with oncogene addicted NSCLC who acquire TKI resistance secondary to actionable resistance mutations.
- Alectinib and capmatinib dual therapy did not require dose adjustments to achieve a safe and effective response in a patient with end-stage renal disease.

Table 1 Next-generation sequencing results from liquid biopsies at time of diagnosis and progression

Historic patient findings	Diagnosis, variant allele frequency	Time of progression, variant allele frequency
Tumor mutational burden	1 mutation/megabase	1 mutation/megabase
Microsatellite status	Microsatellite instability-high not detected	Microsatellite instability-high not detected
Tumor fraction	Elevated tumor fraction not detected	Elevated tumor fraction not detected
<i>MET</i>		
Exon 14 splice site (D1010N)	Not detected	0.87%
<i>CDH1</i>		
Splice site 1137G>A	0.33%	0.27%
<i>DNMT3A</i>		
K812	Not detected	0.45%
Y735C	Not detected	0.41%
Splice site 1015-2A>T	Not detected	0.29%
<i>TET2</i>		
N275fs*18	0.81%	1.10%
<i>TP53</i>		
V173M	6.20%	6.20%

MET, mesenchymal epithelial transition factor.

shown to derive greater benefit from pemetrexed with longer progression-free survival when compared to other oncogene-addicted NSCLC, including *EGFR* and *KRAS* mutations (2). However, targeted therapies have replaced chemotherapy-based regimens for both *ALK*-positive and *MET*-positive NSCLC as standard front-line therapy leading to significant improvements in progression-free survival and overall survival along with high response rates and milder toxicities. Capmatinib has demonstrated high response rates in both treated (41%) and treatment-naïve (68%) patients with NSCLC with a *METex14* mutation. These patients also demonstrated durable responses with a median duration response of 9.7 and 12.6 months in treated and treatment-naïve patients, respectively (3). As a result, the decision was made to initiate capmatinib 400 mg twice daily in combination with alectinib 600 mg twice daily. Interval imaging at one month demonstrated significant response with decreased size of the left apical nodule and improved mediastinal and left supraclavicular lymphadenopathy (Figure 1). Patient remains on therapy and continues to demonstrate overall stable disease at 15 months (Figure 2).

All procedures performed in this study were in accordance with the ethical standards of the institutional and/or national

research committee(s) and with the Helsinki Declaration (as revised in 2013). Written informed consent was obtained from the patient for publication of this case report and accompanying images. A copy of the written consent is available for review by the editorial office of this journal.

Discussion

Second-generation *ALK* TKIs have significantly improved survival outcomes in NSCLC, especially in patients whose tumors harbor *EML4-ALK* translocations. In a study that compared alectinib with crizotinib, alectinib demonstrated a median progression free survival of 34.8 months in previously untreated, advanced *ALK*-positive NSCLC (4). However, the clinical impact of *ALK*-inhibitors is limited due to the inevitable development of resistance mechanisms. The emergence of these resistance mechanisms has made treatment decisions increasingly more complex.

Our patient demonstrated an initially durable response with overall stable disease radiographically on alectinib and had improvement in symptoms of shortness of breath and chest tightness. However, our patient eventually developed progression of disease at 7 months. Plasma NGS of a liquid biopsy at the time of progression revealed an acquired

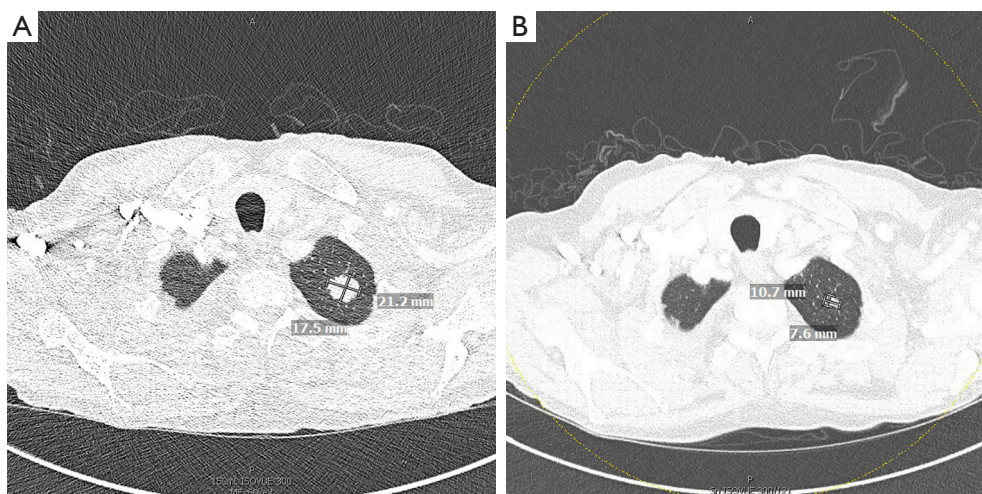


Figure 1 Imaging at time of progression on alectinib (A) and on-treatment with dual therapy of capmatinib and alectinib (B) of a 72-year-old male with an acquired *MET* exon 14 skipping mutation mediated resistance to alectinib. *MET*, mesenchymal epithelial transition factor.

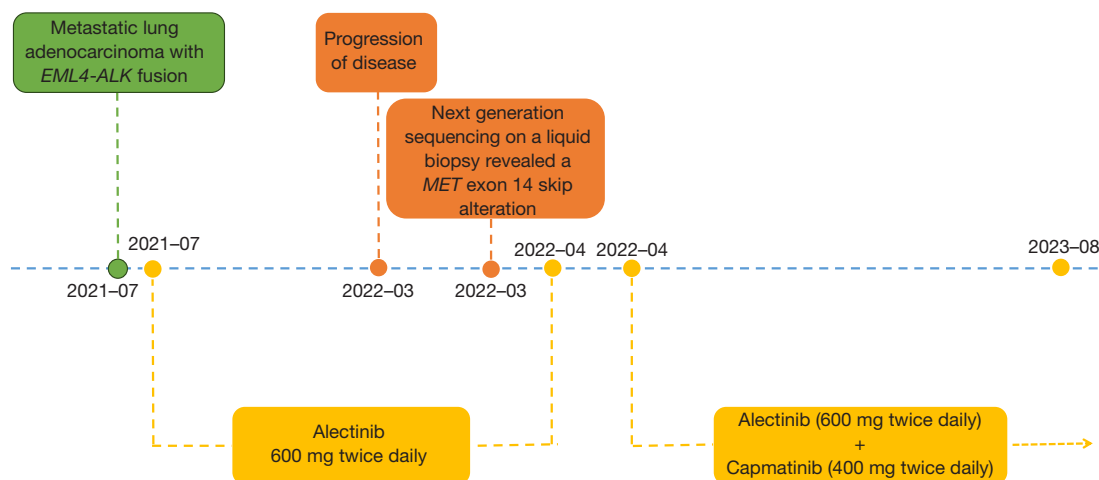


Figure 2 Patient timeline. Green represents the time of diagnosis. Orange represents the time of progression. Yellow represents prior and current treatment regimens. 2023-08 represents the last timepoint assessed during the case study. *EML4*, echinoderm microtubule-associated protein 4; *ALK*, anaplastic lymphoma kinase; *MET*, mesenchymal epithelial transition factor.

*MET**ex14* mutation (3028G>A). *MET**ex14* is present in about 3–4% of lung adenocarcinomas (4,5). Crizotinib, which is a multi-kinase inhibitor approved for *ALK*- or *ROS1*-rearranged NSCLC, has been shown to have activity against *MET* kinase (6). Thus, crizotinib may be an effective treatment strategy for *ALK* rearranged NSCLC with *MET* mediated resistance. In a case report by Daniel *et al.*, crizotinib led to a partial response with a 35% reduction

in distant metastases that was maintained for 3 months in an *ALK* rearranged NSCLC with an acquired *MET**ex14* mediated resistance to alectinib (7). Additional studies have shown that patients with acquired *MET*-driven resistance such as *MET* amplification after treatment with next-generation *ALK* inhibitors may benefit from therapies that target both *ALK* and *MET* (8,9).

The development of highly specific *MET* inhibitors

such as tepotinib and capmatinib have demonstrated both robust responses and tolerable safety profiles in patients with *METex14* NSCLC (3,10). These TKIs have also been shown to have antitumor activity in patients with *MET*-amplified NSCLC. Concurrent *MET* amplification has been reported in 15–21% of *METex14* positive NSCLC (5,11,12). Both liquid biopsy and tissue-based NGS in our patient did not reveal a concurrent *MET* amplification. Because of the high response rates, we elected to start the patient on capmatinib. The decision was also made to continue alectinib as we believe the clonal driver mutation was the *EML4-ALK* fusion gene mutation and the *METex14* was the subclonal resistance mutation. This combinatorial therapy regimen led to a durable response in our patient.

However, successful combination therapy must not only demonstrate superior efficacy but must also demonstrate tolerable safety profiles. Combination therapies are often limited by increased risk for adverse events as was the case with osimertinib and durvalumab combination therapy in *EGFR*-mutant lung cancer, which led to a ten-fold increase in interstitial lung disease compared to osimertinib or durvalumab monotherapy (13). In a prior study evaluating the efficacy and tolerability of *ALK/MET* combination therapies in *ALK*-rearranged NSCLC, all three patients who were treated with a combination of alectinib and capmatinib experienced treatment related adverse events. Two of these patients required dose interruptions for grade 2 peripheral edema and persistent grade 1 pyrexia. All three patients developed grade 2 peripheral edema requiring initiation of diuretics. Other toxicities included grade 1 transaminase level elevation and grade 1 muscle and grade 1 joint adverse events (14). Our patient experienced lower extremity edema. However, this was not dose limiting potentially due to ongoing dialysis for his ESRD. Our patient had no other significant adverse events with combination therapy of alectinib and capmatinib. Further case reports have also shown success in treating *EGFR*-mutant NSCLC with acquired *MET* mediated resistance with combinatorial therapy of *EGFR*-TKI and *MET* inhibitors (15,16). Thus, in patients who acquire resistance after initial TKI therapy, combinatorial therapy may provide a promising effective and safe therapy option to overcome *ALK* TKI resistance.

In addition, our case report demonstrated the safety and efficacy of alectinib and capmatinib in ESRD patients on dialysis. This may be partly explained by the fact that alectinib and capmatinib are both metabolized by cytochrome P450 3A4 into their active metabolites, which

are removed by the biliary system. In addition, both alectinib and capmatinib and their metabolites are bound to human plasma protein which may prevent their elimination by the dialysis membrane. In a case report evaluating the pharmacokinetics of alectinib in a patient with advanced lung adenocarcinoma undergoing hemodialysis and receiving the standard full dose of alectinib, the maximal observed plasma concentration of alectinib was shown to be similar to those in non-ESRD patients (17). Dose adjustments in either alectinib or capmatinib were not required in our patient to achieve a durable response without significant adverse events. However, further studies are needed to evaluate the pharmacokinetics and assess the long-term safety and efficacy of both alectinib and capmatinib in patients with renal impairments.

The initial *ALK* rearrangement was not identified from the liquid biopsy NGS at the time of progression. The *ALK* rearrangement may not have been detected as the patient was receiving alectinib at the time of the liquid biopsy collection. Moreover, the low sensitivity and risk of false-negative tests with liquid biopsy NGS have limited their clinical impact leading to recommendations by the United States Food and Drug Administration for tumor biopsy-based NGS in patients with negative test results on liquid biopsy NGS to confirm mutational status. A limitation of this case report is that our patient did not undergo repeat tissue biopsy at time of progression. It is unlikely, although possible, that the *METex14* clone represents a second primary lung cancer.

Conclusions

Patients should undergo resequencing at time of progression to identify potential actionable mutation mediated resistance mechanisms. To our knowledge this is the first reported case of dual alectinib and capmatinib therapy in a patient with *ALK* rearranged NSCLC and *METex14* mediated primary resistance. Combinatorial therapy remains a promising treatment option for patients who develop acquired resistance mechanisms after TKI therapy. Moreover, up-front treatment with multikinase inhibitors and combination therapy that co-target *ALK* with *MET*, *EGFR*, and *KIT* may lead to a synergistic and more durable response and suppression of TKI resistance than monotherapy alone. Further prospective studies are needed in this setting to better understand the efficacy and safety profile of combinatorial therapies to improve outcomes in NSCLC.

Acknowledgments

The authors would like to express their gratitude to the pharmacists, clinicians, nurses, and staff who contributed to the care of this patient.

Funding: None.

Footnote

Reporting Checklist: The authors have completed the CARE reporting checklist. Available at <https://tldr.amegroups.com/article/view/10.21037/tlcr-23-613/rc>

Peer Review File: Available at <https://tldr.amegroups.com/article/view/10.21037/tlcr-23-613/prf>

Conflicts of Interest: Both authors have completed the ICMJE uniform disclosure form (available at <https://tldr.amegroups.com/article/view/10.21037/tlcr-23-613/coif>). J.S. declares consultant and advisory roles in AstraZeneca, Abbvie, Genentech, Janssen, Jazz, Loxo Lilly, Mirati, Navire, Pfizer, Regeneron, Sanofi Genzyme, Takeda; and receives Research Funding (Institutional) from Janssen and Boehringer Ingelheim. The other author has no conflicts of interest to declare.

Ethical Statement: The authors are accountable for all aspects of the work in ensuring that questions related to the accuracy or integrity of any part of the work are appropriately investigated and resolved. All procedures performed in this study were in accordance with the ethical standards of the institutional and/or national research committee(s) and with the Helsinki Declaration (as revised in 2013). Written informed consent was obtained from the patient for publication of this case report and accompanying images. A copy of the written consent is available for review by the editorial office of this journal.

Open Access Statement: This is an Open Access article distributed in accordance with the Creative Commons Attribution-NonCommercial-NoDerivs 4.0 International License (CC BY-NC-ND 4.0), which permits the non-commercial replication and distribution of the article with the strict proviso that no changes or edits are made and the original work is properly cited (including links to both the formal publication through the relevant DOI and the license). See: <https://creativecommons.org/licenses/by-nc-nd/4.0/>.

References

1. Arbour KC, Riely GJ. Diagnosis and Treatment of Anaplastic Lymphoma Kinase-Positive Non-Small Cell Lung Cancer. *Hematol Oncol Clin North Am* 2017;31:101-11.
2. Camidge DR, Kono SA, Lu X, et al. Anaplastic lymphoma kinase gene rearrangements in non-small cell lung cancer are associated with prolonged progression-free survival on pemetrexed. *J Thorac Oncol* 2011;6:774-80.
3. Wolf J, Seto T, Han JY, et al. Capmatinib in MET Exon 14-Mutated or MET-Amplified Non-Small-Cell Lung Cancer. *N Engl J Med* 2020;383:944-57.
4. Peters S, Camidge DR, Shaw AT, et al. Alectinib versus Crizotinib in Untreated ALK-Positive Non-Small-Cell Lung Cancer. *N Engl J Med* 2017;377:829-38.
5. Schrock AB, Frampton GM, Suh J, et al. Characterization of 298 Patients with Lung Cancer Harboring MET Exon 14 Skipping Alterations. *J Thorac Oncol* 2016;11:1493-502.
6. Drilon A, Clark JW, Weiss J, et al. Antitumor activity of crizotinib in lung cancers harboring a MET exon 14 alteration. *Nat Med* 2020;26:47-51.
7. Daniel C, Callens C, Melaabi S, et al. Acquired Exon 14 MET Mutation Associated With Resistance to Alectinib in a Patient With ALK-Rearranged NSCLC. *JTO Clin Res Rep* 2020;1:100082.
8. Shiraishi T, Yamasaki K, Kidogawa M, et al. Successful Treatment with Crizotinib to Overcome Drug Resistance Possibly Due to Mesenchymal-epithelial Transition Amplification in a Lung Cancer Patient with the Echinoderm Microtubule-associated Protein-like 4-anaplastic Lymphoma Kinase Fusion Gene. *Intern Med* 2023;62:3215-21.
9. Ji J, Mitra A, Camidge DR, et al. Early Alectinib Resistance From MET Amplification in ALK-Rearranged NSCLC: Response to Crizotinib with Re-Response to Alectinib and Crizotinib. *Clin Lung Cancer* 2021;22:e851-5.
10. Paik PK, Felip E, Veillon R, et al. Tepotinib in Non-Small-Cell Lung Cancer with MET Exon 14 Skipping Mutations. *N Engl J Med* 2020;383:931-43.
11. Tong JH, Yeung SF, Chan AW, et al. MET Amplification and Exon 14 Splice Site Mutation Define Unique Molecular Subgroups of Non-Small Cell Lung Carcinoma with Poor Prognosis. *Clin Cancer Res* 2016;22:3048-56.
12. Awad MM, Oxnard GR, Jackman DM, et al. MET Exon

- 14 Mutations in Non-Small-Cell Lung Cancer Are Associated With Advanced Age and Stage-Dependent MET Genomic Amplification and c-Met Overexpression. *J Clin Oncol* 2016;34:721-30.
13. Oxnard GR, Yang JC, Yu H, et al. TATTON: a multi-arm, phase Ib trial of simertinib combined with selumetinib, savolitinib, or durvalumab in EGFR-mutant lung cancer. *Ann Oncol* 2020;31:507-16.
 14. Dagogo-Jack I, Kiedrowski LA, Heist RS, et al. Efficacy and Tolerability of ALK/MET Combinations in Patients With ALK-Rearranged Lung Cancer With Acquired MET Amplification: A Retrospective Analysis. *JTO Clin Res Rep* 2023;4:100534.
 15. Wang Y, Tian P, Xia L, et al. The clinical efficacy of combinatorial therapy of EGFR-TKI and crizotinib in overcoming MET amplification-mediated resistance from prior EGFR-TKI therapy. *Lung Cancer* 2020;146:165-73.
 16. Wilgucki M, Yeung V, Ho G, et al. Osimertinib and Capmatinib Combination Therapy to Overcome MET Y1003N-Mediated Resistance in EGFR-Mutant NSCLC: A Case Report. *JTO Clin Res Rep* 2022;3:100396.
 17. Park JE, Yoon YR, Kim CH, et al. Pharmacokinetics of alectinib and its metabolite M4 in a patient with advanced lung adenocarcinoma undergoing hemodialysis: A case report. *Thorac Cancer* 2022;13:1224-6.

Cite this article as: Jang C, Sabari J. Combinatorial therapy is a safe and durable treatment option in *ALK*-rearranged non-small cell lung cancer with an acquired *MET* exon 14 skipping mutation mediated resistance to alectinib: a case report. *Transl Lung Cancer Res* 2023;12(12):2558-2564. doi: 10.21037/tlcr-23-613