

A CARE-compliant article: a case report of idiopathic brachial neuritis treated with ultrasound-guided electroacupuncture

Po-Hsuan Su, MD^a, Chen-Jei Tai, MD, PhD^{a,b,*}

Abstract

Rationale: Electroacupuncture is commonly used for treating nerve injury. However, studies published in recent years have not described an appropriate method for accurately identifying the location and depth of injured nerves beneath the acupoints.

Patient concerns: A 26-year-old male patient had left shoulder pain and weakness after tetanus, diphtheria, and pertussis vaccination and was diagnosed with idiopathic brachial neuritis 24 months before this study. The patient had undergone prednisone and ibuprofen treatment in another hospital, but the therapeutic effect was poor and limited.

Diagnoses: The nerve conduction studies showed decreased amplitude over the left supraspinatus and deltoid muscles. Electromyography showed increased giant waves and polyphasic waves with reduced recruitments in the left deltoid muscle and increased giant waves with reduced recruitment in the left supraspinatus muscle. The condition was diagnosed with idiopathic brachial neuritis.

Interventions: Ultrasound was used to identify the location and depth of axillary and suprascapular nerves, and direct electroacupuncture was conducted at the quadrangular space and suprascapular notch to stimulate the nerves. Other needles were placed according to deltoid and supraspinatus muscles origins and insertions. The procedure was conducted once a week, and rehabilitation activities were conducted daily.

Outcomes: The patient experienced significant improvements of left shoulder pain and muscle weakness after ultrasound-guided electroacupuncture treatment. The total shoulder pain and disability index score declined from 49.23% to 11.54%. The scores of both pain and disability domains improved and maintained stable declining after the intervention. The disability of the arm, shoulder; and hand scores declined from 60 to 23.3. According to amplitude data from nerve conduction studies, the injured axillary nerve showed remarkable improvement in the third month. Muscle strength improved to the normal state. The patient was generally satisfied with the ultrasound-guided electroacupuncture treatment.

Lesson: Ultrasound-guided electroacupuncture was based on anatomical correlations between nerves and muscles and on electrical stimulation theories. The results suggest that this intervention might be an alternative therapy for idiopathic brachial neuritis. Furthermore, in this study, it had minimal adverse effects. This therapy is demonstrated to be effective in future controlled studies.

Abbreviations: DASH = disability of the arm, shoulder, and hand, EMG = electromyography, NCS = nerve conduction studies, SPADI = shoulder pain and disability index, VAS = visual analog scale.

Keywords: case report, electroacupuncture, idiopathic brachial neuritis, ultrasound guidance

Editor: N/A.

Informed written consent was obtained from the patient for publication of this case report and accompanying images.

The authors have no funding and conflicts of interest to disclose.

Supplemental Digital Content is available for this article.

^a Department of Traditional Chinese Medicine, Taipei Medical University Hospital,

^b Department of Obstetrics and Gynecology, School of Medicine, College of Medicine, Taipei Medical University, Taipei, Taiwan.

* Correspondence: Chen-Jei Tai, Department of Traditional Chinese Medicine, Taipei Medical University Hospital, Taipei 11031, Taiwan (e-mail: chenjtai@tmu.edu.tw).

Copyright © 2019 the Author(s). Published by Wolters Kluwer Health, Inc. This is an open access article distributed under the terms of the Creative Commons Attribution-Non Commercial-No Derivatives License 4.0 (CCBY-NC-ND), where it is permissible to download and share the work provided it is properly cited. The work cannot be changed in any way or used commercially without permission from the journal.

Medicine (2019) 98:19(e15325)

Received: 24 November 2018 / Received in final form: 14 March 2019 /

Accepted: 25 March 2019

<http://dx.doi.org/10.1097/MD.00000000000015325>

1. Introduction

Progressive weakness and atrophy of the shoulder girdle and upper extremity are the most prevalent in patients with idiopathic brachial neuritis.^[1] This neuritis may be caused by infection, vaccination, or trauma at a remote site, triggering the brachial plexus or its branches within the limb.^[2] The current therapies for idiopathic brachial neuritis include medication and transcutaneous electrical nerve stimulation. However, most patients remain dissatisfied with the outcomes of such treatments. Medication side effects, such as gastrointestinal problems, metabolic disease, and adverse cardiovascular events, have been frequently observed in patients with idiopathic brachial neuritis.^[3,4]

Acupuncture originates from traditional Chinese medicine. It has been used to reduce neuropathic pain and improve nerve conduction velocity.^[5–7] It also prevents joint contracture and muscle atrophy in patients with peripheral nerve injury.^[8] Electrical stimulation therapy for injured nerves in animal and human models has resulted in satisfactory recovery.^[9–11]

In the medical field, ultrasound is mainly used to visualize muscles, tendons, and many internal organs and to capture their size, structure, location, depth, and any pathological lesions by using real-time tomographic images.

To date, in the English literature, published reports have not described an appropriate method for accurately identifying the location and depth of the injured nerve beneath the acupoints. Here, we report a patient with idiopathic brachial neuritis treated with ultrasound-guided electroacupuncture.

2. Patient case presentation

A 26-year-old male patient had left shoulder pain and weakness after tetanus, diphtheria, and pertussis vaccination on October 26, 2015. Few hours after the injection, pain developed over the left deltoid area, and on the next day, he felt muscle shrinkage over the left shoulder. After 2 days, the pain and weakness could be exaggerated by laterally raising the shoulder; therefore, the patient could barely abduct his left shoulder. He felt weakness when pushing things forward, and this feeling influenced him to flex his left shoulder. On physical examination, atrophy of the left supraspinatus and deltoid muscles was noted. The assessment of muscle strength revealed grade 3,^[12] and the visual analog scale (VAS) score was 6 during abduction. Since a very young age, he had right acromioclavicular joint instability. Hence, his right shoulder was not as strong as his left. However, 2 months after the vaccination, compared with the right side, his left shoulder was weaker and shrunken. The patient took clonazepam, diclofenac, prednisone, and ibuprofen, but the therapeutic effect was poor. Considering the side effects, the patient stopped the medications on March 15, 2016.

The symptoms persisted for a year and a half, during which the patient received no medical care. During this period, the VAS score decreased to 4, but the muscle strength remained at grade 3. Therefore, the patient was examined at the Division of Rehabilitation Medicine on October 27, 2017. After the diagnosis (see Section 3), the patient was prescribed prednisone, diclofenac, and steroid along with 50% sugar water injection. However, considering the side effects, the patient opted for acupuncture.

3. Diagnosis

Nerve conduction studies (NCS) showed decreased amplitude over the left supraspinatus and deltoid muscles. Electromyography (EMG) showed increased giant waves and polyphasic waves with reduced recruitments in the left deltoid muscle and increased giant waves with reduced recruitment in the left supraspinatus muscle. These reinnervation signs implied that muscle atrophy was caused by nerve injury. The aforementioned condition indicated chronic neuritis in the left shoulder girdle that involved axillary and suprascapular nerves, which is compatible with vaccination sequela. On the basis of physical examination, a physiatrist made the diagnosis of idiopathic brachial neuritis.

4. Therapeutic intervention

The patient was treated with ultrasound-guided electroacupuncture combined rehabilitation of functional training. Direct electrical stimulation was transmitted using 4 acupuncture needles, 2 inserted at the quadrangular space and 2 at the suprascapular notch, which were applied along the site of the injured axillary and suprascapular nerves (Fig. 1). For therapeutic

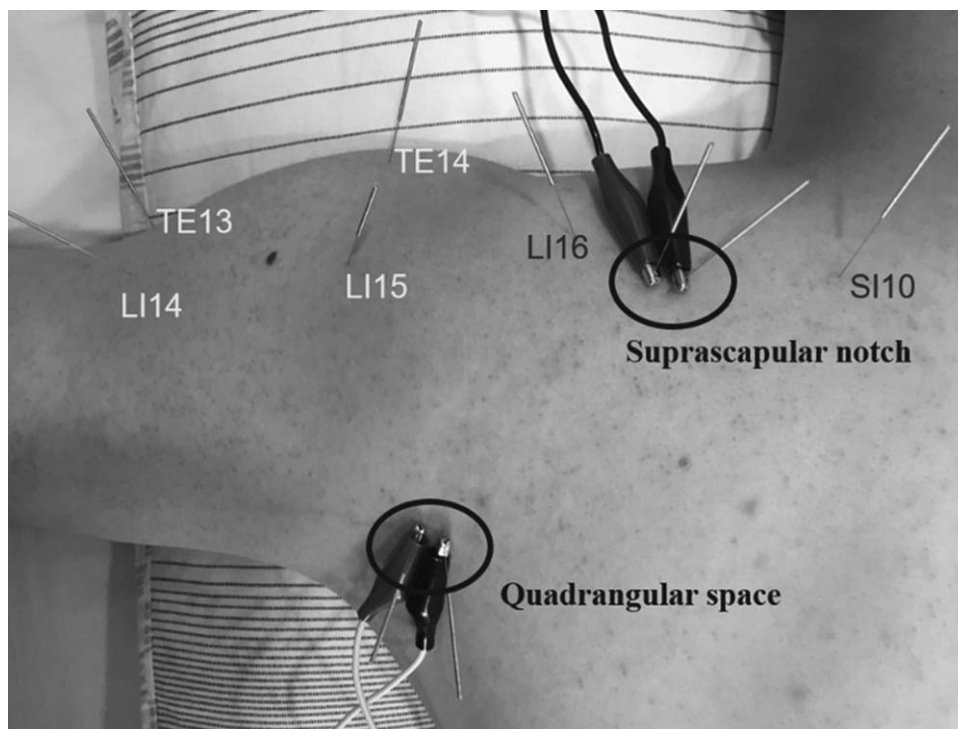


Figure 1. Direct electrical stimulation on the site of injured axillary and suprascapular nerves transmitted by 4 acupuncture needles inserted at the quadrangular space and the suprascapular notch. Six other needles were placed at the origins and insertions of the deltoid and supraspinatus muscles innervated by axillary and suprascapular nerves.

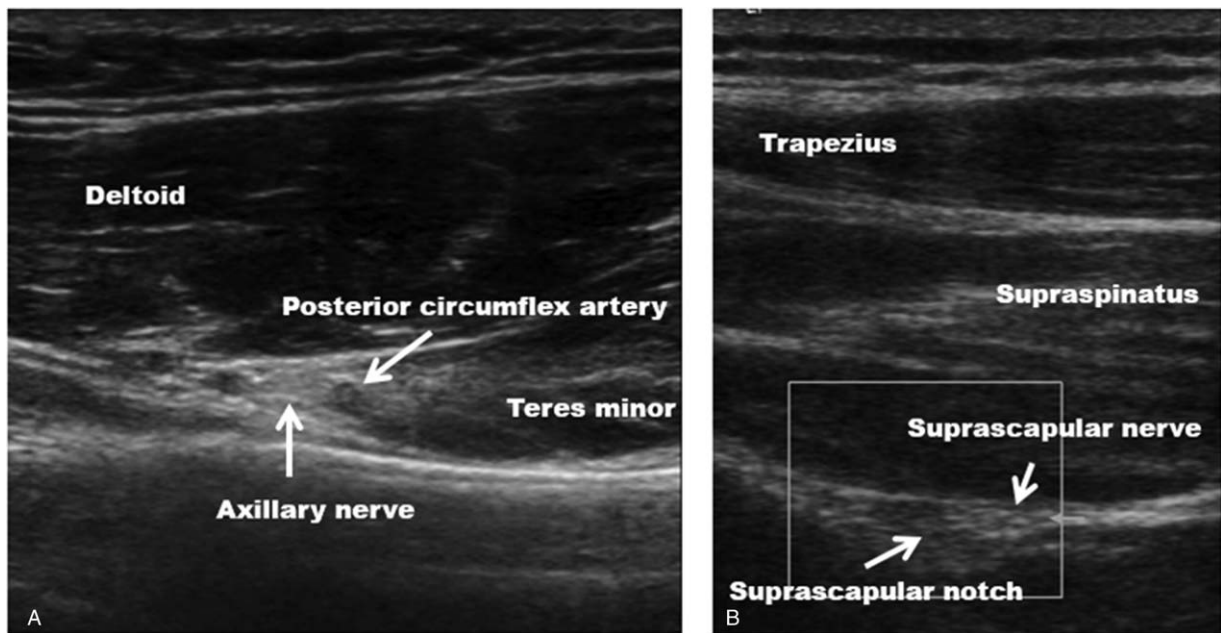


Figure 2. Ultrasound-guided images. (A) The axillary nerve traveled through the quadrangular space, with the posterior circumflex artery innervating deltoid and teres minor muscles. (B) The suprascapular nerve passed through the suprascapular notch beneath supraspinatus, innervating the supraspinatus muscle.

effects and safety, the needles should not only be placed as close to the injured nerve as possible but also be prevented from penetrating the nerves and causing pneumothorax; therefore, this procedure was conducted under ultrasound guidance (Fig. 2) (see Supplemental Video 1, <http://links.lww.com/MD/C958>, which demonstrates the procedure at quadrangular space under ultrasound guided electroacupuncture, and Supplemental Video 2, <http://links.lww.com/MD/C959>, which demonstrates the procedure at suprascapular notch under ultrasound guided electroacupuncture). Considering therapeutic and safety aspects, all 4 needles were connected to the electrical stimulator in a sparse-dense wave with 10Hz frequency under 6mA.^[13] We observed supraspinatus, deltoid, and teres minor muscles contraction under electrical stimulation, and the patient may also have experienced spreading sensation over the shoulder girdle innervated by axillary and suprascapular nerves. Six other needles were placed at acupoints TE13, TE14, LI14, LI15, LI16, and SI10 located in the lateral and posterior parts of the deltoid and supraspinatus muscles innervated by axillary and suprascapular nerves and affected by the injury (Fig. 1).

We executed the procedures once a week. Rehabilitation activities, such as abduction of the left shoulder with a dumbbell, were conducted twice a day.

5. Follow-up and outcomes

We followed up the patient by using shoulder pain and disability index (SPADI)^[14] and disability of the arm, shoulder, and hand (DASH) scores^[15] once a month and NCS and EMG once every 3 months regularly. We considered results on the first day of the intervention as baseline. The patient received treatment for 6 months without interruption. All the evaluation outcomes, including SPADI, DASH scores, muscle strength, NCS, and EMG reports, are shown in the Supplemental table (<http://links.lww.com/MD/C957>), which illustrates results of the intervention

measured using SPADI, DASH scores, muscle strength, NCS, and EMG.

6. Result

At baseline, the total SPADI score was 49.23%, and the scores of pain and disability domains were almost equal. After the first month of the intervention, the scores of both pain and disability domains improved and maintained stable declining thereafter. According to amplitude data from NCS, in the initial state, the left axillary nerve presented an amplitude of only 0.6mV; however, after the intervention, the injured axillary nerve showed remarkable improvement in the third month and was in a near-normal state in the sixth month, whereas the injured suprascapular nerve had unremarkably improved. According to the muscle strength test, the patient's muscle strength began to improve in the fourth month, which was in accordance with the results of DASH scores (declined from 60 to 23.3). This finding implied that the injured axillary and suprascapular nerves reinnervated the deltoid and supraspinatus muscles. Eventually, the results of all the subjective and objective assessments indicated significant improvement in the patient's condition. Adverse or unanticipated events were not observed during the treatment or outcome periods.

7. Discussion

Idiopathic brachial neuritis is a disorder of unknown etiology; it shows asymmetric involvement of the brachial plexus. It usually affects young adults, and affected individuals present with severe pain across the shoulder and upper arm. Within a few hours or days, weakness, atrophy, and paralysis of the shoulder may occur. This condition may lead to paralysis of the affected areas for months or years.^[16] Conventional management strategies include short courses of corticosteroids or nonsteroidal anti-

inflammatory drugs and pain control therapy followed by physical therapy, but these strategies may have side effects such as gastrointestinal problems, metabolic disease, and adverse cardiovascular events.^[3,4] In typical cases, patients recover from painless paresis of the shoulder slowly but gradually in a few months.^[1] The most important element for diagnosing idiopathic brachial neuritis is studying the history and physical examination results of the patient, with special emphasis on the chronological development of symptoms and signs. Although electrophysiological studies, such as EMG or NCS, and magnetic resonance imaging are not required to be conducted, they can support the diagnosis and be useful to eliminate other conditions that present similar symptoms and signs.

Many studies have focused on the effect of electroacupuncture for promoting nerve regeneration and reinnervation. A clinical study by Tang et al^[17] showed that direct electroacupuncture at the injured ulnar nerve can accelerate nerve regeneration and muscle reinnervation. Hoang et al^[18] showed that electroacupuncture exerts a positive effect on motor recovery and is effective for pain control. A case series by Dimitrova^[19] showed that electroacupuncture can reduce neuropathic pain and is beneficial for treating numbness or paresthesias in peripheral neuropathy. Thus, electroacupuncture can promote nerve regeneration and reinnervation in atrophied muscles.

We should also focus on the safety aspects and side effects of electroacupuncture in addition to its therapeutic effect. On the basis of electrophysiology, the optimum electric current and frequency should be determined. The current used for therapeutic electrical stimulation ranges from approximately 0.5 to 20 mA, and a current of approximately 50 mA may cause cardiac arrest through ventricular fibrillation.^[13] Regarding the frequency of electrical stimulation, a study by Gordon et al^[20] indicated that brief stimulation at the frequency of less than 20 Hz can accelerate nerve regeneration and target muscle reinnervation. According to anatomy, the location of the suprascapular notch is over the lung, and the depth of nerves varies in different people; therefore, during acupuncture, pneumothorax or penetration of the nerves and other soft tissues may occur. The best method of avoiding dry needle injury is to conduct the procedure under ultrasound guidance.

In our case, the patient had shoulder pain, weakness, and muscle atrophy after vaccination. After conventional medical care, VAS decreased but was present, and muscle atrophy still existed. This condition persisted for 2 years; therefore, we started another type of intervention, namely ultrasound-guided electroacupuncture at an intensity of 6 mA depending on the patient's tolerance and at a frequency of 10 Hz for 20 minutes once a week according to the patient's physical status and viewpoints from the aforementioned studies.

In this study, to quantify the patient's improvement after the intervention, we used SPADI and DASH scores to measure pain levels, disability levels, and the performance of activities of daily living. Additionally, due to implicit subjectivity, patient reports of nerve recovery may be inaccurate. Objective manual muscle (e.g., shoulder abduction) testing results may vary depending on the consistency of the examiner, and such tests rarely isolate a single muscle; therefore, it becomes difficult to assign weakness to a single affected muscle. Patients' compensatory movement patterns may also obscure the true strength deficit. Feinberg et al^[21] used electrodiagnostic testing to more precisely identify the individual nerves, rule out potential concurrent conditions that may impact recovery, and prognosticate overall recovery

time frames and thereby optimize patient management. Hence, in our case, we used NCS and EMG to follow up the status of injured axillary and suprascapular nerves in the course of the treatment.

Thus, ultrasound-guided electroacupuncture can improve the healing of idiopathic brachial neuritis and promote the recovery of muscle strength, and it has minimal adverse effects. Ultrasound-guided electroacupuncture was based on anatomical correlations between nerves, muscles, and acupoints and on electrical stimulation theories. The outcomes were based on the subjective questionnaires SPADI and DASH score and the objective electrodiagnostic assessments NCS and EMG. To the best of our knowledge, this is the first report to present a patient with idiopathic brachial neuritis who was successfully treated with ultrasound-guided electroacupuncture. However, additional sample-randomized and double-blinded controlled trials with larger samples are needed to verify this finding and to optimize treatment protocols for idiopathic brachial neuritis.

Acknowledgments

The authors thank Dr. Chien-Hung Lai and Dr. Wei Li for their help operate the ultrasound guidance as well as interpret the meaning of the data from a solid physical medicine and rehabilitation theoretical basis.

Author contributions

Conceptualization: Po-Hsuan Su.

Data curation: Po-Hsuan Su.

Investigation: Po-Hsuan Su.

Project administration: Chen-Jei Tai.

Resources: Po-Hsuan Su.

Supervision: Chen-Jei Tai.

Validation: Po-Hsuan Su, Chen-Jei Tai.

Visualization: Chen-Jei Tai.

Writing – original draft: Po-Hsuan Su, Chen-Jei Tai.

Writing – review & editing: Chen-Jei Tai.

References

- [1] Gonzalez-Alegre P, Recober A, Kelkar P. Idiopathic brachial neuritis. *Iowa Orthop J* 2002;22:81–5.
- [2] Sierra A, Prat J, Bas J, et al. Blood lymphocytes are sensitized to brachial plexus nerves in patients with neuralgic amyotrophy. *Acta Neurol Scand* 1991;83:183–6.
- [3] Rostom A, Dube C, Wells G, et al. Prevention of NSAID-induced gastroduodenal ulcers. *Cochrane Database Syst Rev* 2002;4:CD002296.
- [4] Hasselgren PO, Alamdari N, Aversa Z, et al. Corticosteroids and muscle wasting: role of transcription factors, nuclear cofactors, and hyperacetylation. *Curr Opin Clin Nutr Metab Care* 2010;13:423–8.
- [5] Dimitrova A, Murchison C, Oken B. Acupuncture for the treatment of peripheral neuropathy: a systematic review and meta-analysis. *J Altern Complement Med* 2017;23:164–79.
- [6] Khosrawi S, Moghtaderi A, Haghghat S. Acupuncture in treatment of carpal tunnel syndrome: a randomized controlled trial study. *J Res Med Sci* 2012;17:1–7.
- [7] Yang CP, Hsieh CL, Wang NH, et al. Acupuncture in patients with carpal tunnel syndrome: a randomized controlled trial. *Clin J Pain* 2009;25:327–33.
- [8] Willand MP, Holmes M, Bain JR, et al. Sensory nerve cross-anastomosis and electrical muscle stimulation synergistically enhance functional recovery of chronically denervated muscle. *Plast Reconstr Surg* 2014; 134:736e–45e.
- [9] Gordon T, Brushart TM, Chan KM. Augmenting nerve regeneration with electrical stimulation. *Neurol Res* 2008;30:1012–22.

- [10] Schroder S, Liepert J, Rempis A, et al. Acupuncture treatment improves nerve conduction in peripheral neuropathy. *Eur J Neurol* 2007;14: 276–81.
- [11] He GH, Ruan JW, Zeng YS, et al. Improvement in acupoint selection for acupuncture of nerves surrounding the injury site: electro-acupuncture with Governor vessel with local meridian acupoints. *Neural Regen Res* 2015;10:128–35.
- [12] James MA. Use of the Medical Research Council muscle strength grading system in the upper extremity. *J Hand Surg Am* 2007;32: 154–6.
- [13] Cummings M. Safety aspects of electroacupuncture. *Acupunct Med* 2011;29:83–5.
- [14] Breckenridge JD, McAuley JH. Shoulder Pain and Disability Index (SPADI). *J Physiother* 2011;57:197.
- [15] Gummesson C, Atroshi I, Ekdahl C. The disabilities of the arm, shoulder and hand (DASH) outcome questionnaire: longitudinal construct validity and measuring self-rated health change after surgery. *BMC Musculoskelet Disord* 2003;4:11.
- [16] Sumner AJ. Idiopathic brachial neuritis. *Neurosurgery* 2009;65(4 Suppl): A150–2.
- [17] Tang YJ, Wu MH, Tai CJ. Direct electrical stimulation on the injured ulnar nerve using acupuncture needles combined with rehabilitation accelerates nerve regeneration and functional recovery – a case report. *Complement Ther Med* 2016;24:103–7.
- [18] Hoang NS, Sar C, Valmier J, et al. Electro-acupuncture on functional peripheral nerve regeneration in mice: a behavioural study. *BMC Complement Altern Med* 2012;12:141.
- [19] Dimitrova A. Introducing a standardized acupuncture protocol for peripheral neuropathy: a case series. *Med Acupunct* 2017;29:352–65.
- [20] Gordon T, Amirjani N, Edwards DC, et al. Brief post-surgical electrical stimulation accelerates axon regeneration and muscle reinnervation without affecting the functional measures in carpal tunnel syndrome patients. *Exp Neurol* 2010;223:192–202.
- [21] Feinberg JH, Nguyen ET, Boachie-Adjei K, et al. The electrodiagnostic natural history of parsonage-turner syndrome. *Muscle Nerve* 2017;56: 737–43.