

Large Aneurysmal Rupture of Coronary-Pulmonary Artery Fistula After Buffalo Goring

Authors' Contribution:
Study Design A
Data Collection B
Statistical Analysis C
Data Interpretation D
Manuscript Preparation E
Literature Search F
Funds Collection G

ABDEF 1 **Natnicha Pongbangli**
BDE 1 **Sasivimon Jai-ae**
BDE 2 **Metus Ketwong**
BDE 2 **Sukit Doikean**
EF 3 **Wanwarang Wongcharoen**
EF 3 **Arintaya Phrommintikul**

1 Division of Cardiology, Department of Internal Medicine, Chiang-Rai Prachanukroh Hospital, Chiang-Rai, Thailand
2 Division of Cardiovascular Thoracic Surgery, Department of Surgery, Chiang-Rai Prachanukroh Hospital, Chiang-Rai, Thailand
3 Division of Cardiology, Department of Internal Medicine, Faculty of Medicine, Chiang Mai University, Chiang Mai, Thailand

Corresponding Author: Natnicha Pongbangli, e-mail: bobo843bell@hotmail.com
Conflict of interest: None declared

Patient: Female, 55-year-old
Final Diagnosis: Large aneurysmal rupture of coronary pulmonary artery fistula
Symptoms: Chest discomfort
Medication: —
Clinical Procedure: Exclusion of aneurysm • ligation and closure of fistula, with coronary artery bypass graft
Specialty: Cardiology

Objective: Congenital defects/diseases





Background: Coronary-to-pulmonary artery fistulas are congenital coronary anomalies that are often incidentally found and no hemodynamic significance. They are abnormal vessels originating from the coronary artery and terminating into the pulmonary artery, with a tortuous pathway. However, coronary-pulmonary artery fistula associated with coronary artery aneurysm is a rare condition that can cause cardiac death.

Case Report: A 55-year-old Thai woman diagnosed with traumatic aortic injury after being gored by a buffalo was incidentally found by computed tomography (CT) to have a coronary arteriovenous fistula with large aneurysm. One week after urgent thoracic endovascular aortic repair (TEVAR), she had a cardiac tamponade. Median sternotomy was performed for diagnosis and treatment. The final diagnosis was rupture of a large aneurysm of the coronary-pulmonary artery fistula (CPAF). No complications were found and the patient was discharged 2 weeks after surgery.

Conclusions: CPAF associated with rupture of a giant coronary aneurysm is a rare and life-threatening condition. Prompt diagnosis and emergency surgery are essential to treatment of these patients.

MeSH Keywords: Aorta, Thoracic • Cardiac Tamponade • Coronary Aneurysm • Coronary Vessel Anomalies

Full-text PDF: <https://www.amjcaserep.com/abstract/index/idArt/918838>

 958  —  4  17



Background

Coronary-to-pulmonary artery fistula (CPAF) was initially defined by Krause in 1865 [1]. CPAF is an uncommon congenital coronary anomaly in which there is an abnormal termination of the coronary vessel draining to the pulmonary artery. Most patients with coronary-to-pulmonary artery fistulas are asymptomatic and are incidentally diagnosed by coronary angiography (CAG) or computed tomography angiography (CTA). Its serious complications included myocardial ischemia, heart failure, and cardiac tamponade from rupture of vessels, which is associated with sudden cardiac death [2].

We report a rare case of congenital coronary fistula originating from the left coronary system (left anterior descending artery [LAD]) and terminating into the pulmonary great vessel (pulmonary artery [PA]). The patient presented with acute cardiac tamponade due to rupture of a large coronary aneurysm after being gored by a buffalo. We describe the case, discussing intraoperative findings and clues to diagnosis.

Case Report

A 55-year-old Thai woman patient presented with chest pain after being gored by a buffalo. She had no previous

medical problems. A CT scan of the chest demonstrated a traumatic pseudoaneurysm at the superior wall of the aortic arch just distal to the left subclavian artery origin. A peri-aortic hematoma compatible with traumatic aortic injury was noted. A large cyst-like lesion suspected to be a coronary arteriovenous (AV) fistula was incidentally found. No pericardial effusion was detected. An echocardiogram showed a good left ventricular function without structural abnormalities. The patient had undergone the urgent thoracic endovascular aortic repair (TEVAR), and the procedure was uneventful. Three days after the TEVAR procedure, CT coronary angiography (CTA) was performed to evaluate coronary fistula, revealing a large group of multiple tortuous serpiginous vessels about 5.4 cm in size, compatible with a coronary-pulmonary artery fistula (Figure 1A, 1B). In addition, a giant aneurysm originating from the left anterior descending artery (Figure 2) connecting to the pulmonary trunk was also demonstrated.

One week after TEVAR, the patient developed acute respiratory distress and hemodynamic collapse. A rapid bedside echocardiogram showed pericardial effusion with signs of cardiac tamponade. Figure 3 shows the chest X-ray. Open heart surgery was immediately performed. We found a ruptured coronary aneurysm of the left anterior descending artery proximal to the diagonal branch, which was connected to the pulmonary artery (Figure 4). We then performed coronary artery bypass

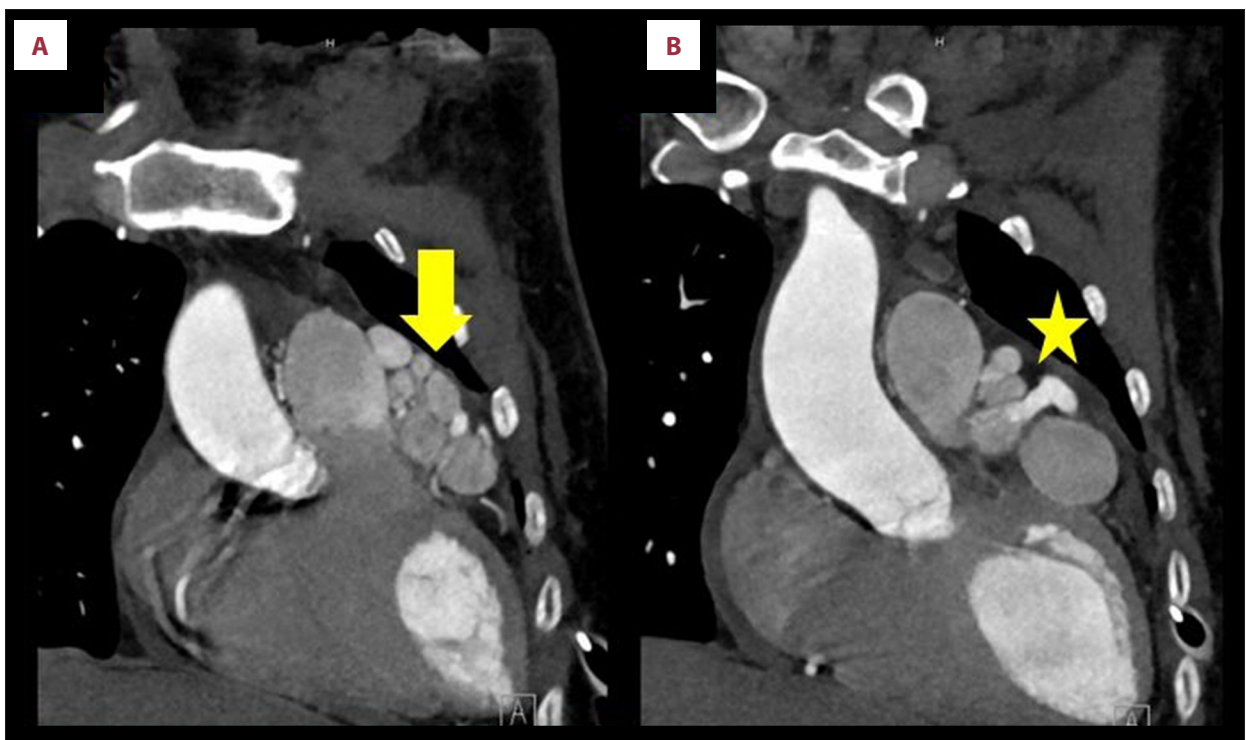


Figure 1. (A) Multiple serpiginous vessels with tortuous aneurysm (arrow), compatible with coronary arteriovenous fistula. (B) A coronary arteriovenous fistula originating from left anterior descending artery (LAD) draining into pulmonary artery (asterisk).

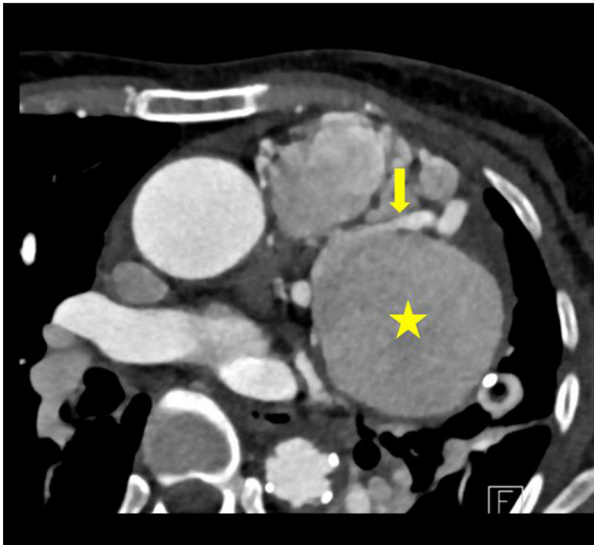

Figure 2. Giant aneurysm arising from left anterior descending artery. (Arrow demonstrates left anterior descending artery, asterisk demonstrates giant aneurysm).

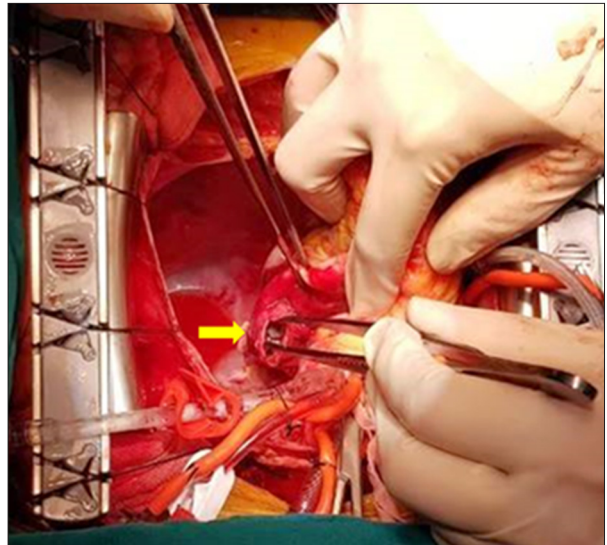

Figure 4. Intraoperative findings demonstrated the rupture site of coronary aneurysm (arrow).

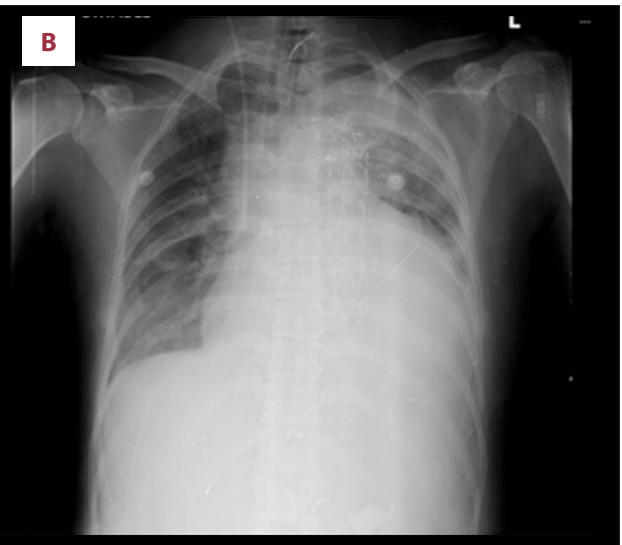
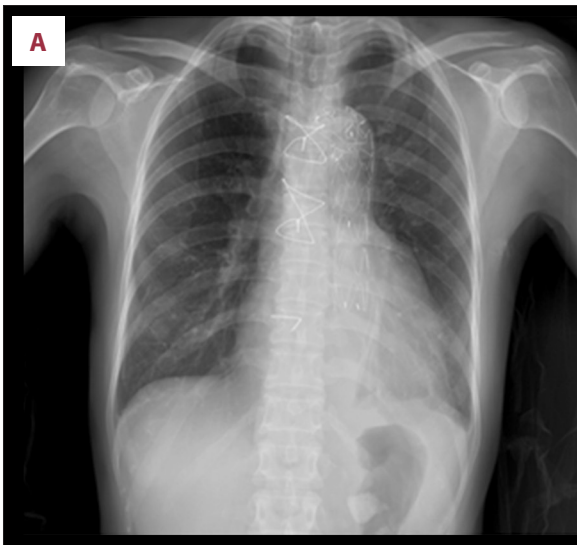


Figure 3. Chest X-ray on 3 days after TEVAR (A) and 7 days after TEVAR (B) showing the increased cardiothoracic ratio suggesting the presence of pericardial effusion.

graft (CABG) surgery with a saphenous vein graft to the diagonal branch. The surgery was uneventful and the patient was discharged 2 weeks later.

Discussion

Coronary artery aneurysm (CAA) is defined as coronary artery segments that have a diameter 1.5 times greater in diameter than the normal reference vessel diameter and involving <50% of the total length of the vessel [3,4]. Coronary artery aneurysms are quite rare, occurring in 1.5–5% of patients

undergoing coronary angiography [3]. In general, because of the high risk for rupture, active treatment is recommended if the size of the aneurysm is >30 mm [5].

Atherosclerosis is the most common cause of CAA in adults. Other underlying conditions include Kawasaki disease, connective tissue disease, arteritis, and coronary arteriovenous fistula (CAVF) [6,7], defined as an abnormal communication between a coronary artery and a cardiac chamber or great vessel.

Congenital anomalies of the coronary arteries affecting about 1% of the general population [2]. Coronary artery fistula is a very rare

congenital anomaly accounting for approximately 0.2% to 0.4% of all cases of congenital heart diseases [8]. The most common site of drainage is the right ventricle (41%), followed by the right atrium (26%) and the pulmonary artery (17%) [9,10]. A fistula between the left anterior descending artery and the main pulmonary artery, referred to as a coronary-pulmonary artery fistula (CPAF), as described in this case, is a very unusual finding [11,12].

The reported incidence of CPAF is 0.1% to 0.2%. Generally, this condition is incidentally found from diagnostic coronary angiography because most patients with CPAF are asymptomatic [7]. It has been reported that the factors affecting the prognosis of CPAF are the size of the communication, the volume of blood drainage, the support of the receiver vessel or chamber, and evidence of myocardial ischemia due to the coronary steal phenomenon [2]. In addition, rupture of an aneurysm of a CPAF, resulting in cardiac tamponade, is a life-threatening complication associated with CPAF [7,13,14].

In general, because of the high risk for rupture, active treatment is recommended if the aneurysm is larger than 30 mm [5]. Apart from aneurysm size, the risk factors for coronary artery aneurysm rupture consist of female sex, saccular aneurysm, Asian ethnicity, and origin of the aneurysmal fistula in the left coronary artery [15]. Notably, all of these risk factors were observed in our patient.

The rupture of an aneurysm of a CPAF has been described previously in several case reports. All of the reported cases had a spontaneous CPAF rupture without any history of chest injury.

References:

1. Albeyoglu S, Aldag M, Ciloglu U et al: Coronary arteriovenous fistulas in adult patients: surgical management and outcomes. *Braz J Cardiovasc Surg*, 2017; 32(1): 15–21
2. Zeina AR, Blinder J, Rosenschein U, Barneir E: Coronary-pulmonary artery fistula diagnosed by multidetector computed tomography. *Postgrad Med J*, 2006; 82(969): e15
3. ElGuindy MS, ElGuindy AM: Aneurysmal coronary artery disease: An overview. *Glob Cardiol Sci Pract*, 2017; 2017: e201726
4. Li D, Wu Q, Sun L et al: Surgical treatment of giant coronary artery aneurysm. *J Thorac Cardiovasc Surg*, 2005; 130(3): 817–21
5. Kawano M, Wada T, Anai H et al: A case of ruptured aneurysm of coronary-pulmonary artery fistula diagnosed after emergency thoracotomy. *Surg Case Rep*, 2018; 4(1): 24
6. Holinski S, Dohmen PM, Lembcke A, Konertz W: Surgical management of multiple coronary artery aneurysms, including the giant form. *Texas Heart Inst J*, 2009; 36(3): 238–40
7. Shomura Y, Mizumoto T, Fujinaga K et al: Cardiac tamponade due to rupture of a giant coronary artery aneurysm with a coronary arteriovenous fistula: A case report. *Surg Case Rep*, 2019; 5(1): 40
8. Malcic I, Bertic M, Eicken A et al: [Congenital coronary artery fistulas: Clinical and therapeutic consideration]. *Lijec Vjesn*, 2014; 136(9–10): 261–68 [in Croatian]
9. Papadopoulos DP, Perakis A, Votreas V, Anagnostopoulou S: Bilateral fistulas: A rare cause of chest pain. Case report with literature review. *Hellenic J Cardiol*, 2008; 49(2): 111–13
10. Dadkhah-Tirani H, Salari A, Shafighnia S et al: Coronary artery to pulmonary artery fistula. *Am J Case Rep*, 2013; 14: 486–88
11. Papadopoulos DP, Bourantas CV, Ekonomou CK, Votreas V: Coexistence of atherosclerosis and fistula as a cause of angina pectoris: A case report. *Cases J*, 2010; 3: 70
12. Tacyo G, Ebinc H, Onal B et al: Congenitally severe tortuous circumflex artery fistula draining into the coronary sinus: Transcatheter closure with Guglielmi detachable coils via different delivery system. *J Cardiol*, 2009; 54(2): 317–21
13. Kimura S, Miyamoto K, Ueno Y: Cardiac tamponade due to spontaneous rupture of large coronary artery aneurysm. *Asian Cardiovasc Thorac Ann*, 2006; 14(5): 422–24
14. Harada Y, Mori A, Abiko T et al: Cardiac tamponade due to the rupture of the coronary artery fistula. *Cardiovasc Diagn Ther*, 2013; 3(2): 105–7
15. Said SA, Schroeder-Tanka JM, Mulder BJ: Female gender and the risk of rupture of congenital aneurysmal fistula in adults. *Congenital Heart Dis*, 2008; 3(1): 63–68
16. Erbel R, Aboyans V, Boileau C et al: 2014 ESC Guidelines on the diagnosis and treatment of aortic diseases: Document covering acute and chronic aortic diseases of the thoracic and abdominal aorta of the adult. The Task Force for the Diagnosis and Treatment of Aortic Diseases of the European Society of Cardiology (ESC). *Eur Heart J*, 2014; 35(41): 2873–926
17. Society of Thoracic Surgeons Task Force on Resuscitation After Cardiac Surgery: The Society of Thoracic Surgeons Expert Consensus for the resuscitation of patients who arrest after cardiac surgery. *Ann Thorac Surg*, 2017; 103(3): 1005–20

To the best of our knowledge, this is the first reported of a case of rupture of a CPAF aneurysm occurring after blunt chest injury (in this case, from buffalo goring). Interestingly, the cardiac tamponade due to CPAF in our case was observed after TEVAR surgery of an aortic dissection [16,17]. This case demonstrates the importance of recognition of this rare condition as one of the causes of cardiac tamponade apart from TEVAR-related complications.

Prompt diagnosis and emergency management are crucial in this condition. The complete surgical repair, including exclusion of the large aneurysm, ligation and closure of fistula, with coronary artery bypass graft, was performed uneventfully in our case.

Conclusions

CPAF associated with rupture of a giant coronary aneurysm is a rare condition and is associated with life-threatening conditions. Prompt diagnosis and emergency surgery are essential in treatment of these patients.

Acknowledgements

We are grateful to the patient for providing consent for publication.

Conflict of interest

None.