



ELSEVIER

Contents lists available at ScienceDirect

Leukemia Research Reports

journal homepage: www.elsevier.com/locate/lrr

Acute myeloid leukemia in a patient with constitutional 47,XXY karyotype

Marla M. Jalbut^a, Aliyah R. Sohani^b, Paola Dal Cin^c, Robert P. Hasserjian^b,
Jenna A. Moran^b, Andrew M. Brunner^b, Amir T. Fathi^{b,*}

^a Tufts University School of Medicine, Boston, MA, United States

^b Massachusetts General Hospital, Harvard Medical School, Boston, MA, United States

^c Brigham and Women's Hospital, Harvard Medical School, Boston, MA, United States

ARTICLE INFO

Article history:

Received 2 February 2015

Accepted 2 April 2015

Available online 22 April 2015

Keywords:

Acute myeloid leukemia

Klinefelter syndrome

Constitutional chromosomal abnormality

ABSTRACT

Klinefelter syndrome (KS), a 47,XXY chromosomal abnormality, has been shown to be associated with a number of malignancies, but has not been linked to acute leukemias to date. We present a case of a 54-year-old male diagnosed with acute myeloid leukemia (AML) with monocytic differentiation, whose cytogenetic and subsequent FISH analyses revealed a constitutional 47,XXY karyotype. We also review and discuss relevant prior literature.

© 2015 The Authors. Published by Elsevier Ltd. This is an open access article under the CC BY-NC-ND license (<http://creativecommons.org/licenses/by-nc-nd/4.0/>).

1. Introduction

Klinefelter syndrome (KS), first described in 1942, is characterized by male infertility, gynecomastia, and hypogonadism, and is associated with the sex chromosome abnormality 47,XXY [1]. Patients with KS are known to be at an increased risk for developing malignancy, including breast cancer, germ cell tumors, non-Hodgkin lymphomas, and lung cancer [2]. Nevertheless, no clear association between constitutional 47,XXY and acute leukemias has yet been established [3]. We here report on a case of a patient with constitutional 47,XXY and a diagnosis of acute myeloid leukemia (AML), followed by a review of the relevant literature.

2. Case

A 54-year-old male with a medical history of non-insulin dependent diabetes mellitus, hypertension, and gastroesophageal reflux, initially presented to his dentist with left-sided gum pain. Due to persistence of the pain, he was then evaluated by his primary care physician, who noted a marked leukocytosis. He was subsequently referred to the emergency room, where he was found to have a white blood cell count (WBC) of 33,500/mm³, of which 2% were blasts, a hematocrit of 22.2%, and a platelet count of 131,000/mm³. He also had renal insufficiency, with a creatinine of 1.74 mg/dL, and there was concern for tumor lysis syndrome,

with a uric acid of 10.1 mg/dL. On examination, he was obese and appeared mildly uncomfortable. He was not hypoxic, and his heart and lung exam were benign. Gynecomastia was present. He had no family history of hematologic malignancy. He had one brother and one sister, both of whom were reported to be healthy. He lived with his wife and had no children. He previously worked in construction, but was currently not working.

Given these abnormal laboratory results, a bone marrow biopsy and aspirate were performed. The biopsy was hypercellular (95% cellularity) and was replaced by sheets of blasts (Fig. 1A). On the aspirate smear, there were 76% monoblasts (Fig. 1B), confirmed by flow cytometric immunophenotyping. Bone marrow karyotype was abnormal, with all metaphases (20 of 20) containing an additional X chromosome as the sole aberration (Fig. 1C). Given that a 47, XY, +X abnormality would be unusual for AML, a monolayer culture of non-neoplastic bone marrow stromal cells was studied to obtain a constitutional karyotype. Although no metaphases were obtained from the monolayer culture, interphase FISH analysis revealed that all scored nuclei contained two copies of the X and one copy of the Y chromosome, confirming that this patient's constitutional karyotype was 47,XXY (Fig. 1D). Subsequent molecular genetic analysis revealed an *NPM1* mutation at exon 12, but no *FLT3* or *CEBPA* mutations. The final diagnosis was acute myeloid leukemia with mutated *NPM1*.

The patient was hospitalized, treated for hyperuricemia, and initiated on remission induction chemotherapy with cytarabine and idarubicin (the "7+3" regimen). His clinical course was complicated by worsening tumor lysis, renal failure, volume overload, and pneumonia. He required hemodialysis, vasopressor support, intubation, and mechanical ventilation for a period of

* Correspondence to: Massachusetts General Hospital, Zero Emerson Place, Suite 118, Boston, MA 02114, United States. Tel.: +1 617 724 1124; fax: +1 617 724 1126.
E-mail address: afathi@mgh.harvard.edu (A.T. Fathi).

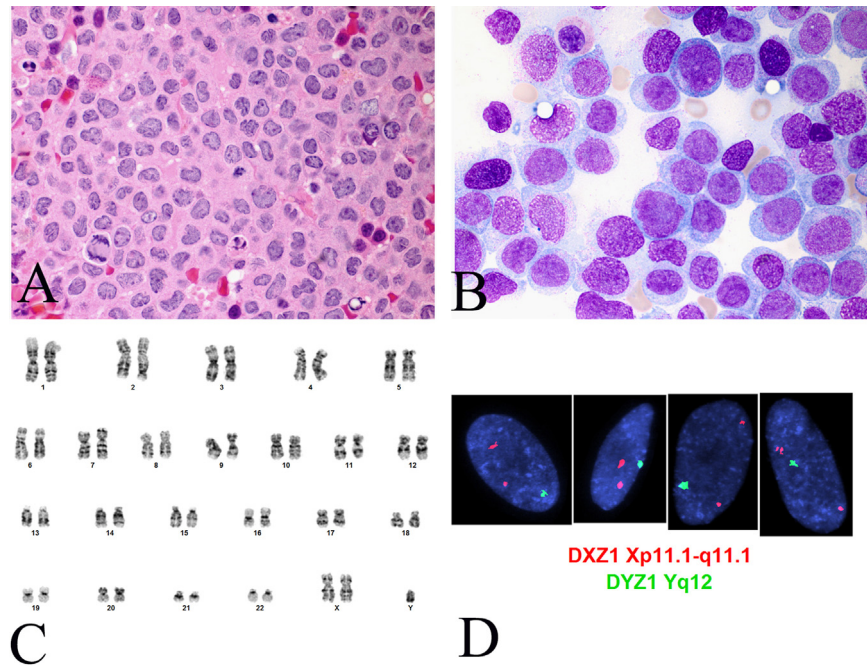


Fig. 1. (A) Bone marrow clot section shows sheets of large blasts with irregular nuclei and abundant eosinophilic cytoplasm (Hematoxylin & Eosin, 100 ×). (B) Bone marrow aspirate smear contains numerous monoblasts with oval and folded nuclei (Wright-Giemsa, 100 ×). (C) Conventional cytogenetics of bone marrow showed a 47,XXY karyotype in all 20 metaphases analyzed. (D) Interphase FISH study of monolayer cultured bone marrow stromal cells using probes for DXZ1 (chromosome X alpha satellite DNA) and DYZ1 (chromosome Y satellite DNA) (Abbott Molecular) showed an XXY hybridization pattern in all 50 nuclei analyzed.

approximately 10 days. His clinical status improved gradually, with resolution of renal failure and pneumonia, and a mid-treatment marrow biopsy at day 14 revealed an ablated marrow without morphologic evidence of leukemia (less than 5% cellularity with no increase in monoblasts). The remainder of his hospitalization was complicated by *Clostridium difficile* colitis, which was treated with antibiotics. He experienced normal peripheral blood count recovery and was discharged from the hospital in good condition.

A bone marrow biopsy subsequently confirmed complete remission 32 days after the start of induction therapy. Given the relatively favorable prognostic risk associated with an isolated *NPM1* mutation, the patient has gone on to receive cycles of consolidation chemotherapy with high dose cytarabine. He remains in remission, now five months after his initial diagnosis.

3. Discussion

Cases of AML have been reported in patients with Klinefelter syndrome since the 1960s [4], and there has been an interest in investigating a potential association between a 47,XXY chromosomal abnormality and myeloid malignancies. Certain constitutional chromosomal abnormalities are known to be associated with malignancy. For example, children with trisomy 21 (Down syndrome) have a 10–20 fold higher risk of developing acute leukemia than other children [5]. Additional hematological malignancies have been reported in patients with other constitutional chromosomal abnormalities (Table 1).

A 2002 review by Keung and colleagues summarized cases of hematologic malignancy in patients with KS reported between 1961 and 2002 [3]. They described 12 cases of AML in KS in the literature during that time period. Based on the review of the current literature, we found approximately 10 additional cases of AML in patients with constitutional 47,XXY. Overall, this is a rather small number of reported cases over a period of greater than 5 decades, and studies to date have not definitively established an epidemiological link [3,6].

Table 1

Reported congenital syndromes associated with hematological malignancies.

Congenital syndrome	Associated hematological malignancy	References
47,XXY (Klinefelter)	AML, MDS, ALL	[3,4,11]
45, XO (Turner)	AML, T-LGL, CLL	[12]
Trisomy 21 (Down)	AML, ALL, TMD	[13]
Trisomy 8 mosaicism	MDS, ALL, IF	[14,15]

TMD=Transient Myeloproliferative Disorder.

T-LGL=T-cell Large Granular Lymphocytic Leukemia.

IF=Idiopathic myelofibrosis.

Intriguingly, almost half the cases of AML with KS occurred in the pediatric population (≤ 18 years old at diagnosis) [3,7,8]. No cases were diagnosed over the age of 64 [4,9,10]. This is noteworthy given that the median age of AML at diagnosis is above 65, and that the majority of AML cases are diagnosed in older patients. These observations raise the question of whether KS, like certain other constitutional abnormalities, may predispose to an earlier onset of AML.

Additionally, in all but two cases in the reported literature, the diagnosis of KS was made at the time of AML diagnosis. This would suggest that an epidemiological association between the two conditions may be overstated, as KS may be under-diagnosed in the general population due to its range of phenotypic manifestation. Larger and more comprehensive studies would be needed to study the possibility of an epidemiological link between AML and Klinefelter syndrome, an association that may shed light on disease genetics and mechanisms, and possibly further guide monitoring and treatment in this population.

Authors' contributions

MMJ and ATF conceptualized the case, carried out the review and analysis, and wrote the manuscript.

ARS, PD, and RPH interpreted the pathology and created Figures.

JAM and AMB contributed to patient care, reviewed the manuscript and provided edits.

Acknowledgments

MMJ is supported by the Betty Lea Stone Fellowship from the American Cancer Society.

References

- [1] Jacobs PA, Strong JA. A case of human intersexuality having a possible XXY sex-determining mechanism. *Nature* 1959;183(4657):302–3.
- [2] Swerdlow AJ, Higgins CD, Schoemaker MJ, Wright AF, Jacobs PA. Cancer incidence and mortality in men with Klinefelter syndrome: a cohort study. *J Natl Cancer Inst* 2005;97(16):1204–10.
- [3] Keung YK, Buss D, Chauvenet A, Pettenati M. Hematologic malignancies and Klinefelter syndrome. a chance association? *Cancer Genet Cytogenet* 2002;139(1):9–13.
- [4] Mamunes P, Lapidus PH, Abbott JA, Roath S. Acute leukaemia and Klinefelter's syndrome. *Lancet* 1961;2(7192):26–7.
- [5] Xavier AC, Ge Y, Taub JW. Down syndrome and malignancies: a unique clinical relationship: a paper from the 2008 william beaumont hospital symposium on molecular pathology. *J Mol Diagn* 2009;11(5):371–80.
- [6] Horsman DE, Pantzar JT, Dill FJ, Kalousek DK. Klinefelter's syndrome and acute leukemia. *Cancer Genet Cytogenet* 1987;26(2):375–6.
- [7] Hiramatsu H, Morishima T, Nakanishi H, Mizushima Y, Miyazaki M, Matsubara H, et al. Successful treatment of a patient with Klinefelter's syndrome complicated by mediastinal germ cell tumor and AML(M7). *Bone Marrow Transpl* 2008;41(10):907–8.
- [8] Roberti MC, La Starza R, Surace C, Sirleto P, Pinto RM, Pierini V, et al. RABGAP1L gene rearrangement resulting from a der(Y)t(Y;1)(q12;q25) in acute myeloid leukemia arising in a child with Klinefelter syndrome. *Virchows Arch* 2009;454(3):311–6.
- [9] Lim G, Kim SY, Cho SY, Lee HJ, Suh JT, Yoon HJ, et al. A novel case of acute myeloid leukemia with RUNX1/RUNX1T1 rearrangement in Klinefelter syndrome. *Leuk Res* 2010;34(9):e259–60.
- [10] Slavcheva V, Lukanov T, Balatsenko G, Angelova S, Antonov A, Bogdanov L, et al. Clinical case of acute myeloblastic leukemia with t(8;21)(q22;q22) in a patient with Klinefelter's syndrome. *Hematol Rep* 2010;2(1):e11.
- [11] Machatschek JN, Schrauder A, Helm F, Schrappe M, Claviez A. Acute lymphoblastic leukemia and Klinefelter syndrome in children: two cases and review of the literature. *Pediatr Hematol Oncol* 2004;21(7):621–6.
- [12] Manola KN, Sambani C, Karakasis D, Kalliakosta G, Harhalakis N, Papaioannou M. Leukemias associated with Turner syndrome: report of three cases and review of the literature. *Leuk Res* 2008;32(3):481–6.
- [13] Rabin KR, Whitlock JA. Malignancy in children with trisomy 21. *Oncologist* 2009;14(2):164–73.
- [14] Hasle H, Clausen N, Pedersen B, Bendix-Hansen K. Myelodysplastic syndrome in a child with constitutional trisomy 8 mosaicism and normal phenotype. *Cancer Genet Cytogenet* 1995;79(1):79–81.
- [15] Seghezzi L, Maserati E, Minelli A, Dellavecchia C, Addis P, Locatelli F, et al. Constitutional trisomy 8 as first mutation in multistep carcinogenesis: clinical, cytogenetic, and molecular data on three cases. *Genes Chromosomes Cancer* 1996;17(2):94–101.