



Since January 2020 Elsevier has created a COVID-19 resource centre with free information in English and Mandarin on the novel coronavirus COVID-19. The COVID-19 resource centre is hosted on Elsevier Connect, the company's public news and information website.

Elsevier hereby grants permission to make all its COVID-19-related research that is available on the COVID-19 resource centre - including this research content - immediately available in PubMed Central and other publicly funded repositories, such as the WHO COVID database with rights for unrestricted research re-use and analyses in any form or by any means with acknowledgement of the original source. These permissions are granted for free by Elsevier for as long as the COVID-19 resource centre remains active.



## Correspondence

## Adjunctive corticosteroid treatment for organizing pneumonia in COVID-19 patients with persistent respiratory failure

## ARTICLE INFO

## Keywords

Corticosteroids. COVID-19. organizing pneumonia

## ABSTRACT

Since the beginning of COVID-19 pandemic, clinical, radiological and histopathological features consistent with viral-induced organizing pneumonia (OP) have been reported as hallmark characteristics of the disease. Here, we describe the case of ten patients with severe COVID-19 pneumonia treated with methylprednisolone 1mg/kg for showing clinical and radiological features suggestive of OP at least 20 days after symptom onset and despite standard treatment for COVID-19.

## To the editor

Organizing pneumonia (OP) is a well-known condition which reflects one type of inflammatory process resulting from a non-specific lung injury, such as virus-related interstitial pneumonias [1]. Since the beginning of COVID-19 pandemic, radiological and histopathological patterns consistent with viral-induced OP have been reported as hallmark features of later stages of the disease [2,3], and clinical features like “silent hypoxemia” are well recognized characteristics of this syndrome [4]. In this regard, there is evidence suggesting that the protocol adopted by the Recovery trial may not be sufficient to control symptoms in all patients with COVID-19 pneumonia, both in early [5], and later stages of the disease [6]. Here, we describe the case of ten patients admitted at our centre between the 2nd of November to the 2nd of December 2020 for severe COVID-19 pneumonia, who were treated with methylprednisolone 1mg/kg for showing clinical and radiological features consistent with OP despite standard treatment.

The median age of the study population was 73.1 years old, and 7 (70%) patients were males. The most common underlying conditions were hypertension (50%), coronary artery disease (20%), chronic obstructive pulmonary disease (20%) and chronic kidney disease (20%). All subjects presented with fever and fatigue, while 4 patients reported cough or shortness of breath and one patient reported a syncope, and they all were diagnosed of COVID-19 infection using RT-PCR assay on nasopharyngeal swabs. At hospital admission, all patients had evidence of bilateral ground glass opacities on chest CT scan and required oxygen supplementation for hypo/normocapnic respiratory failure. According to local guidelines, the patients received intermediate-dose anticoagulation (enoxaparin 40mg BID) plus a first steroid treatment course with dexamethasone 6mg/die for 10 days. Four patients who were admitted within 10 days from symptoms onset were treated with a 5-day course of remdesivir. Nine patients received supplemental oxygen therapy with high-flow nasal cannula, and four patients were admitted to intensive care unit where they underwent non-invasive ventilation.

Despite conventional treatment, at the time of methylprednisolone initiation, all patients had persistent respiratory failure (defined as a PaO<sub>2</sub>/FiO<sub>2</sub> < 300 mmHg at least 20 days after symptom onset) requiring supplemental oxygen therapy. Thus, a follow-up chest CT scan

was performed, which showed radiological findings suggestive of viral-induced OP. All subjects provided informed consent for data and sample collection. Methylprednisolone was administered intravenously in two daily doses, starting with a 1mg/kg dose which was then gradually tapered every three days until interruption. Median time from hospitalization to treatment start was 14.5 days (interquartile range [IQR], 10-19).

At treatment start, median PaO<sub>2</sub>/FiO<sub>2</sub> ratio was 198.5 mmHg (IQR 169 - 217), improving to 253 (IQR 235 - 321) at one week from steroid beginning. Changes from baseline of PaO<sub>2</sub>/FiO<sub>2</sub> before and after methylprednisolone initiation are shown in Fig. 1. Of note, the gain in PaO<sub>2</sub>/FiO<sub>2</sub> experienced by patients, as determined by serial blood gas analyses, was larger in the week after the adjunctive steroid treatment (median difference 51 mmHg, IQR 35-114) as compared to the week before (median difference 29 mmHg, IQR 3-51), although the observed difference did not reach statistical significance at the Wilcoxon signed-rank test ( $p = 0.051$ ). Furthermore, one week after methylprednisolone initiation, median C-reactive protein levels went from a baseline of 34.2 mg/L (IQR, 11.5-46.5), to 7 mg/L (IQR, 1.5-9.55). Eight patients were weaned from oxygen therapy and discharged from the hospital within two weeks since treatment start. No major side effects were observed. Two patients, one of whom had a known diagnosis of diabetes, showed a transient increase in fasting glucose levels, and 2 patients developed uncomplicated urinary-tract infection. Of note, three months after hospital discharge, 3 patients repeated a chest CT scan, which showed substantial resolution of the radiographic alterations suggestive of OP.

The main limitations of this case series are the low number of patients and the absence of a control group. Yet, all patients showed clinical and radiological findings consistent with secondary organizing pneumonia and, in the majority of the study population, we observed an improvement in the lung function short after the treatment start. As such, our experience corroborates the need for a better understanding of the role of OP in the pathophysiology of COVID-19. In this view, we suggest that patients affected by COVID-19 pneumonia may benefit of a more personalised approach to the corticosteroid treatment [8] even in the later stages of the disease. To our knowledge, this is the first study

<https://doi.org/10.1016/j.rmed.2021.106571>

Received 12 July 2021; Accepted 6 August 2021

Available online 10 August 2021

0954-6111/© 2021 Elsevier Ltd. All rights reserved.

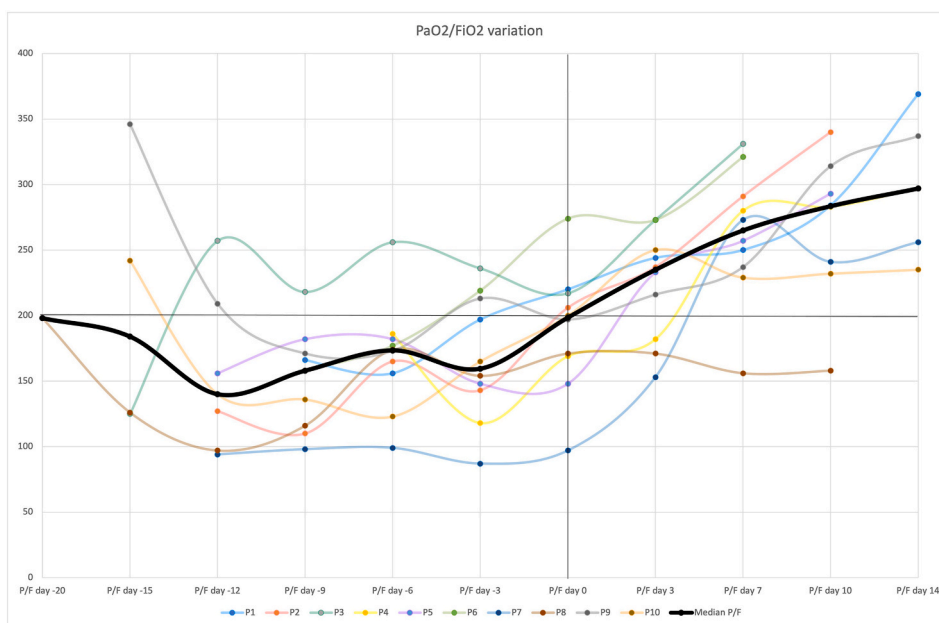


Fig. 1. Changes from baseline of PaO<sub>2</sub>/FiO<sub>2</sub> before and after initiation of methylprednisolone 1mg/kg (Day 0). Thick line represents changes of the median PaO<sub>2</sub>/FiO<sub>2</sub>.

reporting the impact of an adjunctive steroid therapy for COVID-related OP. Further clinical trials may be needed to define the risk benefit ratio of different corticosteroid regimens in patients presenting with radiological findings suggestive of OP and persistent respiratory failure despite standard treatment.

#### Authors' contributions

FVS, LB, AP, MN, EN and GS designed the study, FVS and FS collected the data, FVS, FS, MN and GS analysed the data, FVS drafted the manuscript, GS, AP, RM and MF critically revised the manuscript, RM and MF approved the version to be submitted, FVS, MF and GS are the guarantors of the paper, taking responsibility for the integrity of the work as a whole.

#### Declaration of competing interest

The authors declare no conflict of interest

#### References

- [1] J.F. Cordier, Organising pneumonia, *Thorax* 55 (4) (2000 Apr) 318–328, <https://doi.org/10.1136/thorax.55.4.318>.
- [2] M.P. Revel, A.P. Parkar, H. Prosch, M. Silva, N. Sverzellati, F. Gleeson, A. Brady, European society of radiology (ESR) and the European society of thoracic imaging (ESTI). COVID-19 patients and the radiology department - advice from the European society of radiology (ESR) and the European society of thoracic imaging (ESTI), *Eur. Radiol.* (2020), <https://doi.org/10.1007/s00330-020-06865-y>.
- [3] S.B. Polak, I.C. Van Gool, D. Cohen, J.H. von der Thüsen, J. van Paassen, A systematic review of pathological findings in COVID-19: a pathophysiological timeline and possible mechanisms of disease progression, *Mod. Pathol.* 33 (11) (2020 Nov) 2128–2138, <https://doi.org/10.1038/s41379-020-0603-3>. Epub 2020 Jun 22.
- [4] P. Kory, J.P. Kanne, SARS-CoV-2 organising pneumonia: 'Has there been a widespread failure to identify and treat this prevalent condition in COVID-19?', *BMJ Open Respir Res* 7 (1) (2020 Sep), e000724 <https://doi.org/10.1136/bmjresp-2020-000724>.
- [5] M. Edalatfard, M. Akhtari, M. Salehi, Z. Naderi, A. Jamshidi, S. Mostafaei, S. R. Najafzadeh, E. Farhadi, N. Jalili, M. Esfahani, B. Rahimi, H. Kazemzadeh, M. Mahmoodi Aliabadi, T. Ghazanfari, M. Sattarian, H. Ebrahimi Louyeh, S.

R. Raeeskarami, S. Jamalimoghdamshahkhalil, N. Khajavirad, M. Mahmoudi, A. Rostamian, Intravenous methylprednisolone pulse as a treatment for hospitalised severe COVID-19 patients: results from a randomised controlled clinical trial, *Eur. Respir. J.* 56 (6) (2020 Dec 24), 2002808, <https://doi.org/10.1183/13993003.02808-2020>.

- [6] K.J. Myall, B. Mukherjee, A.M. Castanheira, J.L. Lam, G. Benedetti, S.M. Mak, R. Preston, M. Thillai, A. Dewar, P.L. Molyneaux, A.G. West, Persistent post-COVID-19 inflammatory interstitial lung disease: an observational study of corticosteroid treatment, *Ann Am Thorac Soc* (2021), <https://doi.org/10.1513/AnnalsATS.202008-1002OC> (Epub ahead of print).

Francesco Vladimiro Segala\*

*Infectious Diseases Unit, Catholic University of the Sacred Heart, Rome, Italy*

Giacomo Sgalla

*Unità Operativa Complessa di Pneumologia, Fondazione Policlinico A. Gemelli IRCCS, Rome, Italy*

Federica Salvati

*Infectious Diseases Unit, Catholic University of the Sacred Heart, Rome, Italy*

Ludovica Berardini

*Unità Operativa Complessa di Pneumologia, Fondazione Policlinico A. Gemelli IRCCS, Rome, Italy*

Marcantonio Negri, Elisabetta Nardella, Annalisa Potenza  
*Istituto di Medicina Interna e Gastroenterologia, Fondazione Policlinico Universitario A. Gemelli IRCCS, Rome, Italy*

Rita Murri, Massimo Fantoni

*Division of Infectious Diseases, Department of Laboratory Sciences and Infectious Diseases, Fondazione Policlinico Universitario A. Gemelli IRCCS, Rome, Italy*

\* Corresponding author. Infectious Diseases Unit, Catholic University of the Sacred Heart, Largo Francesco Vito 1, 00168, Rome, Italy.  
E-mail address: [fvsegala@gmail.com](mailto:fvsegala@gmail.com) (F.V. Segala).