

# Injury of leg somatotopy of corticospinal tract at corona radiata by ventriculoperitoneal shunt

## A case report

Sung Ho Jang, MD, Younghyeon Kwon, BS\*

### Abstract

**Rationale:** A 45-year-old right-handed female patient suffered head trauma after being hit by a truck that ran into a house.

**Patient concerns:** The patient lost consciousness for 1 hour and experienced posttraumatic amnesia for 1 month after the accident.

**Diagnoses:** She underwent conservative management for a subdural hematoma in the left frontotemporal lobes and intracerebral hematoma in the left frontal lobe.

**Interventions:** The patient's Glasgow Coma Scale score was 11. She underwent a VP shunt operation, approached through the right posterior parietal area of the brain, at 4 months after onset. Approximately, 6 months after onset, she was admitted to the rehabilitation department of a university hospital. She presented with moderate weakness of the left leg: Medical Research Council scores: hip flexor; 3, knee extensor; 3+, ankle dorsiflexor; 3-. Brain magnetic resonance imaging revealed a leukomalactic lesion in the right posterior corona radiata along the shunt.

**Outcomes:** On 6-month (2 months after the shunt operation) diffusion tensor tractography, the left CST showed partial injury in the posterior portion compared with the right CST. On 6-month transcranial magnetic stimulation study, the motor-evoked potential obtained at the left tibialis anterior muscle revealed lower amplitude than that on the right side.

**Lessons:** Injury of leg somatotopy of a CST was demonstrated in a patient with leg weakness following a VP shunt operation.

**Abbreviations:** APB = abductor pollicis brevis, CST = corticospinal tract, DTI = diffusion tensor imaging, DTT = diffusion tensor tractography, FACT = fiber assignment continuous tracking, MEP = motor-evoked potential, ROI = region of interest, TA = tibialis anterior, TMS = transcranial magnetic stimulation, VP = ventriculoperitoneal.

**Keywords:** corticospinal tract, diffusion tensor tractography, transcranial magnetic stimulation, ventriculo-peritoneal shunt

## 1. Introduction

Hydrocephalus is a common complication of brain injury, and a shunt operation is a common neurosurgical procedure for the management of hydrocephalus.<sup>[1]</sup> Although a successful shunt operation for hydrocephalus can be a turning point in the recovery of patients with brain injury, there is a rare possibility of

complications.<sup>[2,3]</sup> These complications include infection, hemorrhage, shunt displacement, and neural injury.<sup>[2,3]</sup>

Diffusion tensor tractography (DTT), derived from diffusion tensor imaging (DTI) data, allows three-dimensional visualization and estimation of neural tracts.<sup>[4]</sup> A few previous studies using DTT have demonstrated injury of neural tracts including the corticospinal tract (CST), the superior longitudinal fasciculus and cingulum, and the corticoreticulospinal tract following shunt surgery.<sup>[5-8]</sup> Further detailed description of such injury is useful in the management of patients following shunt operation.

In this case study, we report on injury of the leg somatotopy of the CST by a ventriculoperitoneal (VP) shunt in a patient with hydrocephalus following a traumatic brain injury.

## 2. Case report

A 45-year-old right-handed female patient suffered a head trauma after being hit by a truck that ran into a house. At the neurosurgery department of a hospital, she underwent conservative management for subdural and intracerebral hemorrhages in the left frontoal lobe, and intraventricular hemorrhage (Fig. 1A). The patient lost consciousness for 1 hour and experienced posttraumatic amnesia for 1 month after the accident. The patient's Glasgow Coma Scale score was 11. She underwent a VP shunt operation, approached through the right posterior parietal area of the brain, at 4 months after onset. Approximately, 6 months after onset (2 months after the VP shunt operation), she was admitted to the rehabilitation department of a university

Editor: N /A.

This work was supported by the Medical Research Center Program (2015R1A5A2009124) through the National Research Foundation of Korea (NRF) funded by the Ministry of Science, ICT, and Future Planning. Disclosures: Financial disclosure statements have been obtained, and no conflicts of interest have been reported by the authors or by any individuals in control of the content of this article.

Department of Physical Medicine and Rehabilitation, College of Medicine, Yeungnam University, Daemyungdong, Namku, Daegu, Republic of Korea.

\* Correspondence: Younghyeon Kwon, Department of Physical Medicine and Rehabilitation, College of Medicine, Yeungnam University 317-1, Daemyungdong, Namku, Daegu, 705-717, Republic of Korea (e-mail: kyh7648764@daum.net).

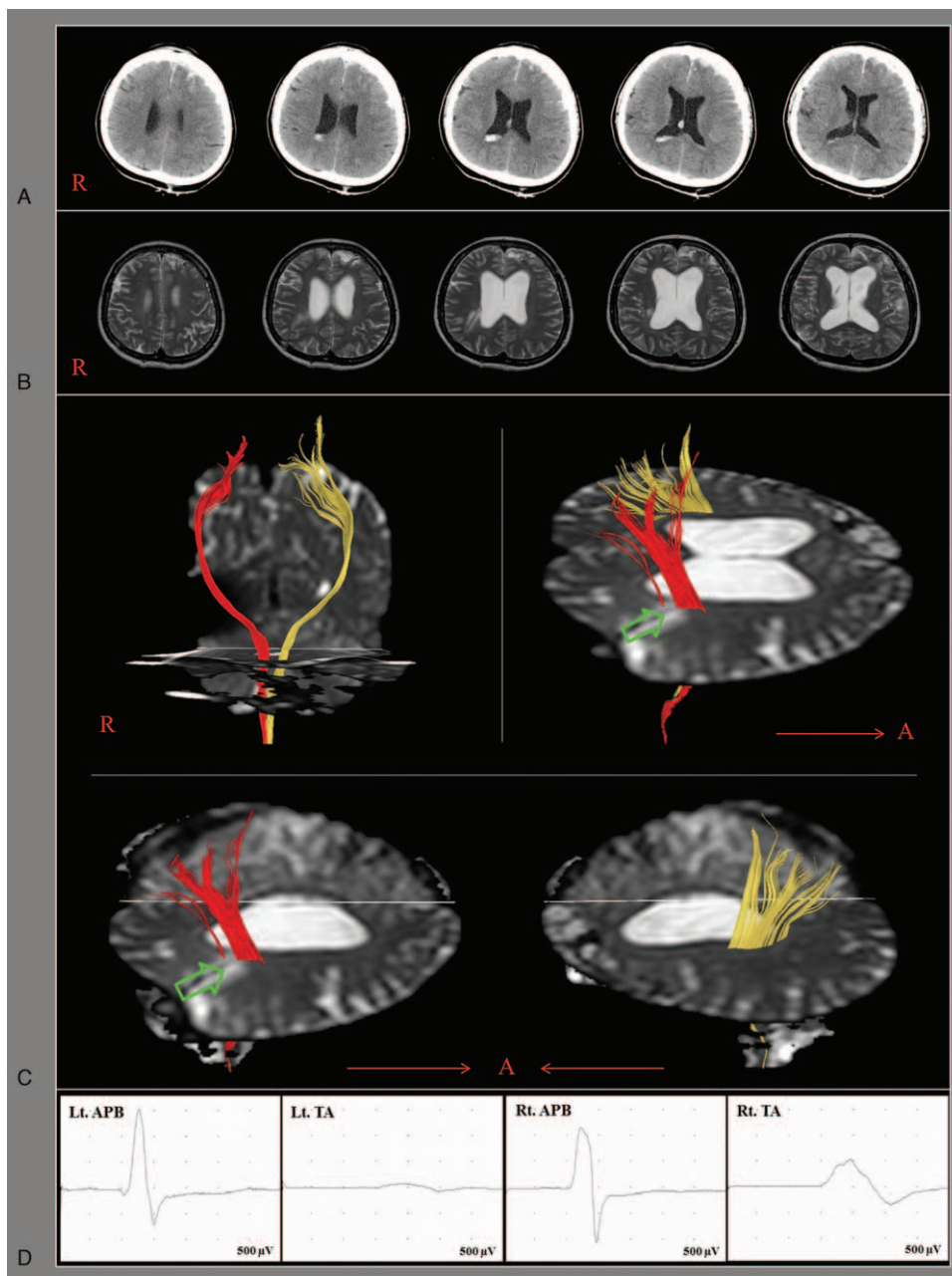
Copyright © 2018 the Author(s). Published by Wolters Kluwer Health, Inc. This is an open access article distributed under the terms of the Creative Commons Attribution-Non Commercial-No Derivatives License 4.0 (CCBY-NC-ND), where it is permissible to download and share the work provided it is properly cited. The work cannot be changed in any way or used commercially without permission from the journal.

Medicine (2018) 97:10(e9983)

Received: 3 September 2017 / Received in final form: 5 January 2018 /

Accepted: 31 January 2018

<http://dx.doi.org/10.1097/MD.0000000000009983>



**Figure 1.** (A) Brain computed tomography images at onset show subdural and intracerebral hemorrhages in the left frontal lobe, and intraventricular hemorrhage. (B) Brain magnetic resonance taken at 6 months after onset (2 months after shunt operation) show leukomalactic lesion (arrow) in the right posterior corona radiata along the shunt. (C) Diffusion tensor tractography for the corticospinal tract (CST). The right CST shows partial injury in the posterior portion (arrows) but no injury in the left CST. (D) Motor-evoked potentials obtained at the left tibialis anterior muscle revealed a low amplitude (arrow) compared with that in the right tibialis anterior muscle. The abductor pollicis brevis muscles latencies were 20.1/20.0 ms and amplitudes were 2300/2300  $\mu$ V, whereas the tibialis anterior muscles and latencies of 29.0/29.9 ms and amplitudes of 900/200  $\mu$ V.

hospital. She presented with moderate weakness of the left leg: Medical Research Council (hip flexor; 3, knee extensor; 3+, ankle dorsiflexor; 3-). The shunt had been placed in the posterior corona radiata, which is the location of the CST.<sup>[9]</sup> On DTT, injury to the posterior portion of the right CST, the somatotopic area for the left leg, was observed (Fig. 1B).<sup>[9,10]</sup> This result on DTT coincided with the low amplitude of motor-evoked potential (MEP) obtained in the left leg muscle compared with the right leg muscle, and indicated the total amount of CST fibers for the left leg muscle (Fig. 1C).<sup>[11]</sup> Brain magnetic resonance imaging showed leukomalactic lesion in the right posterior

corona radiata along the shunt (Fig. 1B). The patient provided signed, informed consent and our institutional review board approved the study protocol.

### 3. Diffusion tensor tractography

DTI data were acquired 6 months after onset (2 months after the shunt operation) by using a 6-channel head coil on a 1.5 T Philips Gyroscan Intera (Philips, Best, the Netherlands) with single-shot echo-planar imaging. For each of the 32 non-collinear diffusion sensitizing gradients, we acquired 70 contiguous slices parallel to

the anterior commissure–posterior commissure line. Imaging parameters were as follows: acquisition matrix=96 × 96, reconstructed matrix=192 × 192, field of view=240 mm × 240 mm, TR=10,398 ms, TE=72 ms, parallel imaging reduction factor (SENSE factor)=2, echo planar imaging factor=59, and  $b=1000 \text{ s/mm}^2$ , NEX=1, slice gap=0 mm, and slice thickness=2.5 mm. Fiber tracking was performed by applying a fiber assignment continuous tracking (FACT) algorithm implemented within the DTI task card software (Philips Extended MR WorkSpace 2.6.3). Each of the DTI replications was intra-registered to the baseline “b0” images to correct for residual eddy-current image distortions and head motion effects by using a diffusion registration package (Philips Medical Systems) with a threshold fractional anisotropy of 0.15 and an angle of 27°. For reconstruction of the CST, the first region of interest (ROI) was placed on the anterior blue portion of the upper pons on the axial image of the color map, and the second ROI was placed on the anterior blue portion of the lower pons on the axial image of the color map.<sup>[4,12]</sup> The right CST showed a partial injury in the posterior portion, whereas no injury was detected in the left CST (Fig. 1C).

#### 4. Transcranial magnetic stimulation

On the same day as DTI data were obtained, a Magstim Novamatrix 200 magnetic stimulator with a 9-cm mean diameter circular coil (Novamatrix Inc. Wallingford, CT) to perform transcranial magnetic stimulation (TMS). Cortical stimulation was performed with the coil held tangentially over the vertex. Stimulation of the left hemisphere was provided by a counter-clockwise current, and stimulation of the right hemisphere was provided by a clockwise current. Four MEPs were obtained from both abductor pollicis brevis (APB) and tibialis anterior (TA) muscles while in a relaxed state. Stimulation intensity was set at 100% of maximum stimulator output. One hemisphere was stimulated 4 times at a minimum interval of 10 seconds. The MEP with the shortest latency and the largest amplitude was adopted. The MEP obtained at the left TA muscle revealed a lower amplitude than that of the right side TA muscle. The APB muscles had latencies of 20.1/20.0 ms and amplitudes of 2300/2300  $\mu\text{V}$ , whereas the TA muscles had latencies of 29.0/29.9 ms and amplitudes of 900/200  $\mu\text{V}$  (Fig. 1D).<sup>[11]</sup>

#### 5. Discussion

We observed coincidence among the patient’s motor weakness, DTT results, and TMS results, and concluded that the patient’s left leg weakness could be ascribed to partial injury of the leg somatotopy of the right CST as a result of the placement of the VP shunt.

Since the introduction of DTI, several studies have reported on injuries of various neural tracts in the brain following shunt surgery.<sup>[5–8]</sup> In 2008, Gold et al,<sup>[8]</sup> based on DTT results, reported on a patient who presented with direct injury of almost the entire CST and limbic system following revision of a VP shunt. In 2015, Jang and Seo<sup>[6]</sup> reported on a patient that developed hemiparesis and gait difficulty after VP shunt, and injuries of a corticoreticulospinal tract and the anterior portion of a CST were detected on DTT. In this case report, we have demonstrated injury of leg somatotopy of a CST by using DTT and TMS.

In conclusion, injury of the leg somatotopy of a CST was demonstrated using DTT and TMS in a patient with leg weakness following a VP shunt operation. We found that DTT and TMS is a suitable technique to detect underlying injury of the CST after shunt operation. Further studies into the prevention or minimization of neural injury during invasive neurosurgical procedures should be encouraged.<sup>[13]</sup>

#### References

- [1] Greenberg MS. *Handbook of Neurosurgery*. 7<sup>th</sup> ed. Greenberg Graphics, Tampa, FL:2010.
- [2] Chai FY, Farizal F, Jegan T. Coma due to malplaced external ventricular drain. *Turk Neurosurg* 2013;23:561–3.
- [3] Cadena G, Wiedeman J, Boggan JE. Ventriculoperitoneal shunt infection with mycobacterium fortuitum: a rare offending organism. *J Neurosurg Pediatr* 2014;14:704–7.
- [4] Mori S, Crain BJ, Chacko VP, et al. Three-dimensional tracking of axonal projections in the brain by magnetic resonance imaging. *Ann Neurol* 1999;45:265–9.
- [5] Kwon HG, Jang SH. Cingulum injury by ventriculoperitoneal shunt. *Eur Neurol* 2012;67:63–4.
- [6] Jang SH, Seo JP. Injury of corticoreticular pathway and corticospinal tract caused by ventriculoperitoneal shunting. *Neural Regen Res* 2015;10:1874–5.
- [7] Jang SH, Lee HD. Injury of the superior longitudinal fasciculus by ventriculo-peritoneal shunt. *Neural Regen Res*, in press.
- [8] Gold MM, Shifteh K, Valdberg S, et al. Brain injury due to ventricular shunt placement delineated by diffusion tensor imaging (DTI) tractography. *Neurologist* 2008;14:252–4.
- [9] Kwon HG, Yang JH, Park JB, et al. Anatomical location and somatotopic organization of the corticospinal tract in the corona radiata of the normal human brain: a diffusion tensor tractography study. *Neuroreport* 2014;25:710–4.
- [10] Han BS, Hong JH, Hong C, et al. Location of the corticospinal tract at the corona radiata in human brain. *Brain Res* 2010;1326:75–80.
- [11] Rossini PM, Barker AT, Berardelli A, et al. Non-invasive electrical and magnetic stimulation of the brain, spinal cord and roots: basic principles and procedures for routine clinical application. Report of an IFCN committee. *Electroencephalogr Clin Neurophysiol* 1994;91:79–92.
- [12] Jang SH. Somatotopic arrangement and location of the corticospinal tract in the brainstem of the human brain. *Yonsei Med J* 2011;52:553–7.
- [13] Jang SH, Kwon HG. Relative anterior safe area for invasive procedures in the human brain: diffusion tensor tractography. *Minim Invasive Ther Allied Technol* 2014;23:247–51.