

CASE REPORT

Inevitable hemodialysis for treating resistant hypertension in a patient with Leriche syndrome

Murvet Yilmaz,^I Ozlem Harmankaya Kaptanogullari,^I Can Caliskan,^{II} Ayse Sinangil Arar,^{III} Cuneyt Akgol,^{III} Kayhan Erturk,^I Abdulkadir Unsal^{III}

^IBakirkoy Dr. Sadi Konuk Training and Research Hospital, Department of Nephrology, Istanbul, Turkey. ^{II}Sisli Etfal Training and Research Hospital, Department of Radiology, Istanbul, Turkey. ^{III}Sisli Etfal Training and Research Hospital, Istanbul, Department of Nephrology, Turkey.

Email: murvetyilmaz@hotmail.com
Tel.: 90 532 6469726

INTRODUCTION

Leriche syndrome, also referred to as aortoiliac occlusive disease, results from thrombotic occlusion of the abdominal aorta immediately above the site of its bifurcation (1). The characteristic symptoms include intermittent bilateral claudication with ischemic pain and absent or diminished femoral pulses, along with pallor, coldness and fatigue of both lower extremities, and inability to maintain penile erection (1). Risk factors include hyperlipidemia, hypertension, diabetes mellitus, and smoking (2). Physical examination reveals weak or absent femoral and distal pulses. Pathologically, the most common cause of Leriche syndrome has been found to be luminal narrowing of the abdominal aorta and/or iliac arteries by atherosclerotic obstruction (3).

The syndrome typically begins at the distal aorta or common iliac artery origins and slowly progresses proximally and distally over time (4), rarely affecting the visceral or renal arteries (5).

In this paper, we report a patient with Leriche syndrome who suffered from bilateral renal artery occlusion-induced resistant hypertension and could not be treated by revascularization procedures or angiotensin-converting enzyme (ACE) blockade. Eventually, maintenance hemodialysis (HD) was initiated, with accompanying renin-angiotensin blockers, to control the hypertension.

CASE DESCRIPTION

A 53-year-old male patient was admitted to the outpatient clinic with a history of uncontrolled hypertension despite antihypertensive treatment, consisting of diltiazem 120 mg qd, amlodipine 10 mg qd, and doxazosin 4 mg qd. The patient stated that he suffered from bilateral calf and buttock claudications with a 100-m walk as well as erectile dysfunction. He had been a heavy smoker (40 pack-years) but never experienced angina. He did not suffer from diabetes or hypercholesterolemia.

The patient's brachial, radial, ulnar, and femoral pulses were palpable bilaterally; however, his dorsalis pedis, tibialis posterior and popliteal pulses were absent. There was no evidence of atrophic or ischemic changes in the lower extremities. Carotid bruits were heard on both sides of the neck, and an audible bruit was noted over the left renal artery. His blood pressure was 190/90 mmHg, and grade-2 hypertensive retinopathy was found.

Blood chemistry analysis revealed a urea level of 108 mg/dl and a creatinine level of 3.6 mg/dl; serum triglycerides, cholesterol, glucose, HbA1c, and other biochemical parameters were within normal limits. The tests for AT III and proteins C and S were negative. Ultrasonography revealed that the right kidney was 95.6 mm, with a cortex width of 13.8 mm; the left kidney was 69.9 mm, with a cortex width of 8.8 mm. The echogenicity was increased in both kidneys. Color Doppler ultrasonography did not detect blood flow in either renal artery. A 40-60% carotid stenosis was diagnosed bilaterally. Doppler ultrasonography revealed high resistance and normal triphasic waveforms in the bilateral subclavian, axillary, brachial, radial and ulnar arteries.

Magnetic resonance angiography (MRA) revealed aortoiliac occlusive disease (Leriche syndrome), concurrent with severe bilateral stenosis of the renal and common iliac arteries. MRA also demonstrated significant collateral circulation (Figure 1).

Tc99m DTPA perfusion scintigraphy revealed a delay in the initiation of perfusion and a deterioration of function in both kidneys, particularly in the left kidney (Figure 2).

A two-dimensional transthoracic echocardiography revealed mild left atrial enlargement (LAd: 4.3 cm) and concentric left ventricular hypertrophy.

Clinical course

The patient was hospitalized due to uncontrolled hypertension. A balloon angioplasty and stenting procedure via the axillary artery was attempted. However, the aortography revealed complete occlusion of the abdominal aorta immediately below the superior mesenteric artery (SMA), and the renal arteries could not be observed (Figure 3). An attempt to introduce the catheter into the renal arteries using a 0.035 inch nitinol guide was unsuccessful; thus, the procedure was terminated. By-pass grafting was discussed with the patient, with an emphasis on the high risk of the procedure and the potentially limited beneficial effects.

Valsartan (at a dosage of 80 mg/day) was added to the current antihypertensive therapy. A very close follow-up was indicated. A dramatic drop in blood pressure was

Copyright © 2012 CLINICS – This is an Open Access article distributed under the terms of the Creative Commons Attribution Non-Commercial License (<http://creativecommons.org/licenses/by-nc/3.0/>) which permits unrestricted non-commercial use, distribution, and reproduction in any medium, provided the original work is properly cited.

No potential conflict of interest was reported.

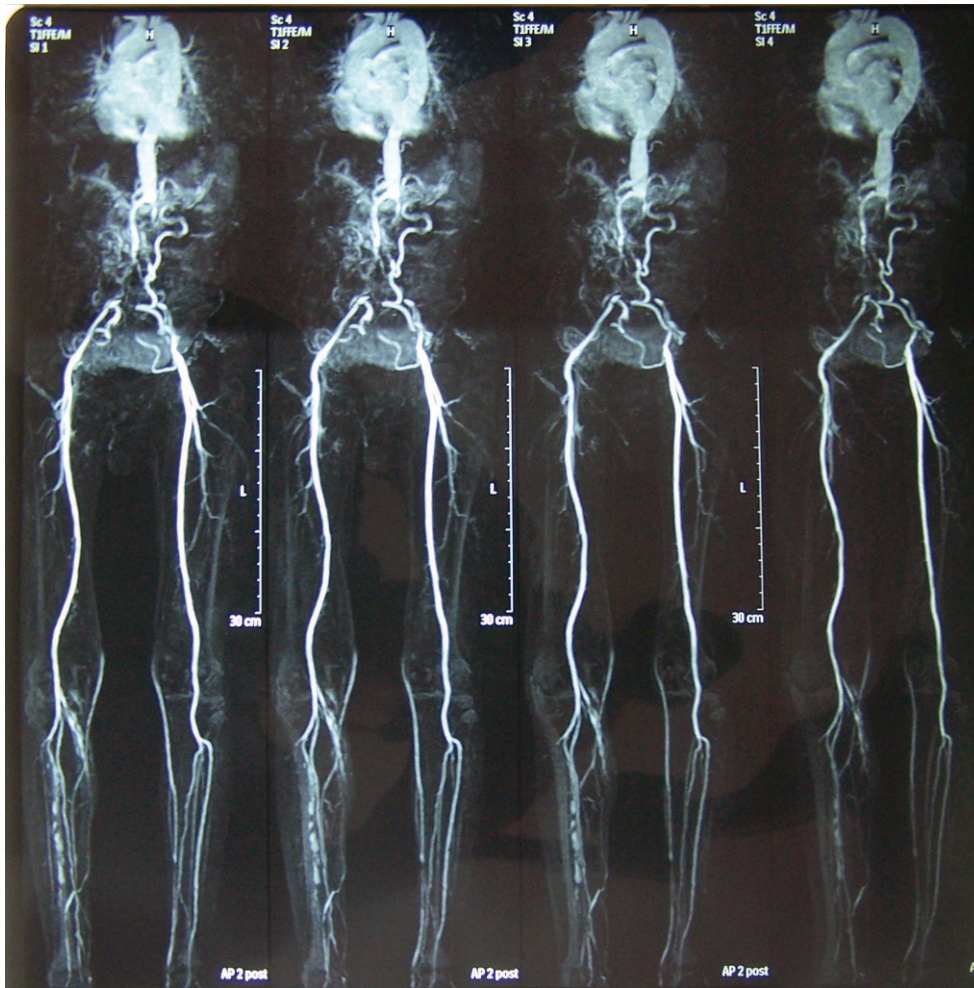

Figure 1 - Magnetic resonance angiography of the abdominal vessels, which reveals total occlusion of the abdominal aorta just below superior mesenteric artery. The lower extremities and the abdomen are perfused by means of the collateral arteries.

observed the next day; however, the renal function continued to deteriorate, with urea and creatinine levels escalating up to 298 and 8.5 mg/dl, respectively. The valsartan was withdrawn, which resulted in a decrease in urea and creatinine levels to 234 and 4.6 mg/dl, respectively. As soon as the valsartan was stopped, the patient's blood pressure again increased up to 200/110 mmHg, despite conventional anti-hypertensive treatment without ACE blockade.

Considering that ACE blockade improved the patient's uncontrolled hypertension but deteriorated kidney function, the patient was enrolled in a maintenance hemodialysis program. An ACE-inhibitor (ramipril 2.5 mg/day) was initiated, which resulted in a dramatic improvement in blood pressure. He was discharged in good clinical condition with no subjective complaints and was placed on a thrice-weekly hemodialysis regimen.

DISCUSSION

Leriche syndrome, which is characterized by the triad of claudication, decreased pulses due to aortoiliac occlusion and impotence, mostly occurs in men and is generally diagnosed between 40 and 60 years of age (6,7). The occlusion is usually due to atherosclerotic plaques in the aorta with associated thrombi.

Because the progression of the disease is slow and collaterals develop, limb-threatening ischemic disease does not tend to occur (8). In our patient, because arterial perfusion of the lower extremities was achieved via arterial collaterals, there were no atrophic or ischemic changes in the lower extremities.

Leriche syndrome typically begins at the distal aorta or common iliac artery origins and slowly progresses proximally and distally over time. This progression is quite variable but may ultimately extend to the level of the renal arteries or result in complete aortic occlusion (4). Proximal propagation of an occlusive distal aortic thrombus to the suprarenal level is rare (9). Bergen and Trippel (10) suggested that aortic thrombosis may progress to involve one or both renal arteries in 3-15% of patients with distal aortic occlusion. As it progresses, the thrombosis may gradually encroach upon a renal artery and cause increasingly severe hypertension. The patient in this case had uncontrolled blood pressure and bilateral renal artery occlusion, with an occlusion of the abdominal aorta below the SMA.

MRA was indicated for imaging the renal vasculature; however, the risk of nephrogenic systemic fibrosis was quite high for this patient. The possible benefits and drawbacks were first discussed extensively among the attending doctors, and it was decided that the potential benefits outweighed the risks. Afterward, the risks were discussed with the patient, and only after having his verbal consent,

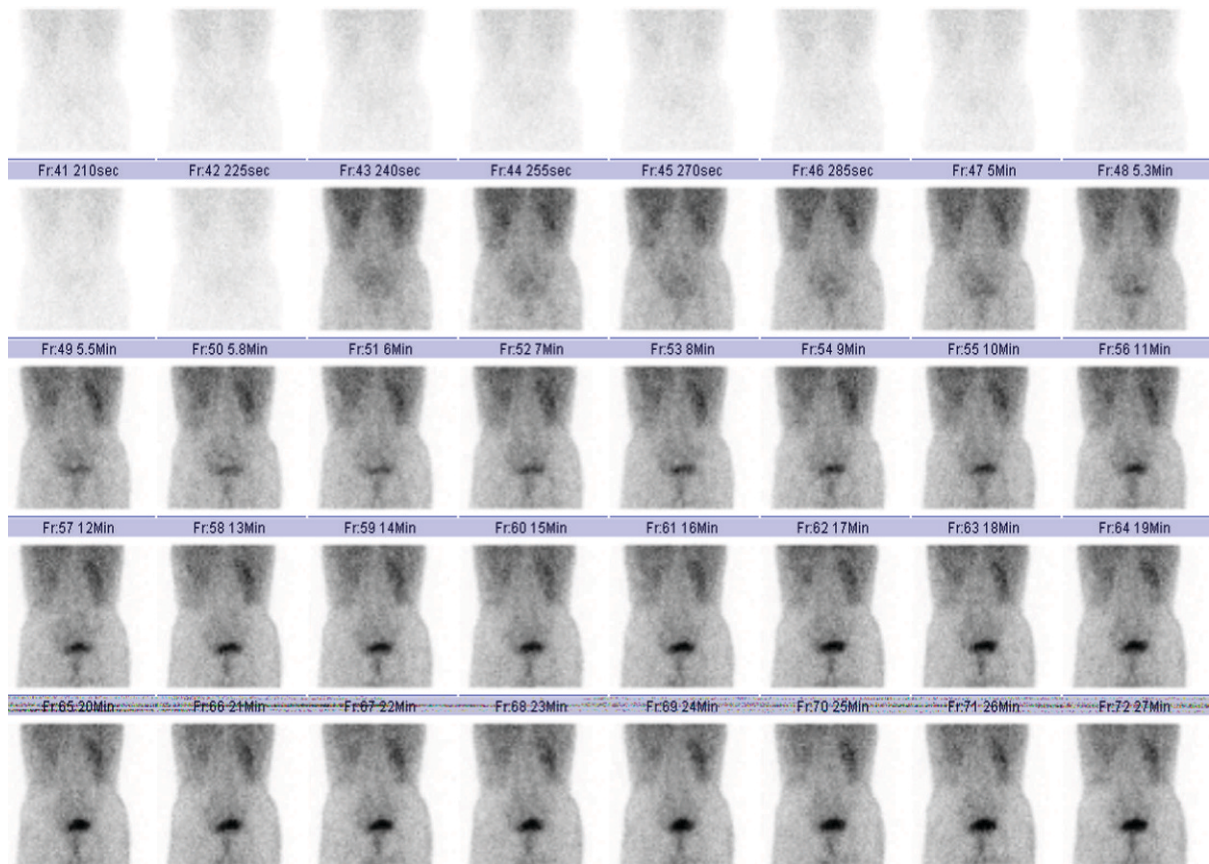


Figure 2 - A Tc99m DTPA perfusion scintigraphy revealed a delay in the initiation of perfusion and deterioration of function for both kidneys, affecting left kidney particularly.

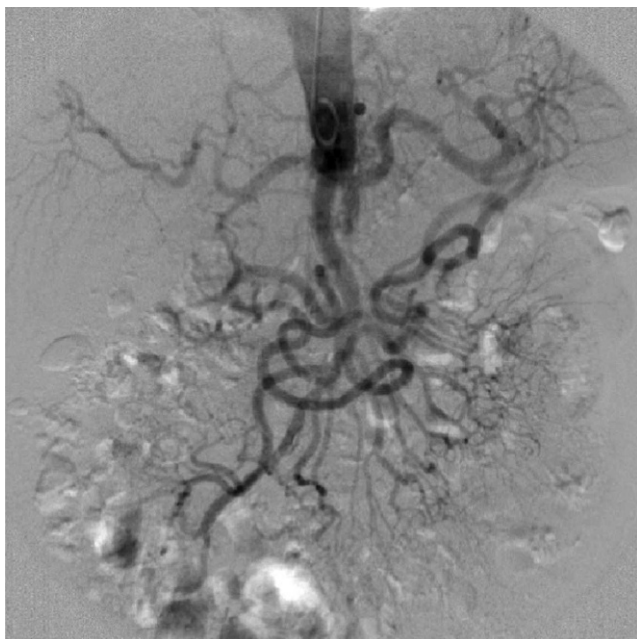


Figure 3 - An AP view of the abdominal aorta by aortography. The distal portion of the a. mesenterica superior (SMA) is completely occluded. The proximal of the SMA, the coeliac truncus and its branches can be seen clearly.

the MRA was performed using Dotarem (gadoterate meglumine), which is least likely to cause nephrogenic systemic fibrosis (11).

Revascularization of the renal arteries should be considered a radical treatment modality in all cases of renal artery stenosis; renal angioplasty combined with stenting is the preferred procedure (12-14). Because successful revascularization via the brachial or axillary artery has been reported in the literature (15-17), we attempted to place a stent in the renal arteries bilaterally via the axillary artery; however, the procedure was unsuccessful because the catheter could not be introduced into the occluded segment. Another option may be to place a by-pass graft between the proximal and distal segments of the stenotic region. However, this option was abandoned because the patient did not give consent for the intervention when he was informed about the risks of the operation.

At this time point, we were faced with the dilemma of either leaving the patient with the risks of hypertension, which was resistant to conventional antihypertensive medications, or administering an ACE blockade medication, despite the risks of acute kidney injury superimposed on chronic renal failure. After discussing the options with the patient, we decided to administer the angiotensin-II receptor blocker valsartan at a dosage of 80 mg/day. His blood pressure decreased rapidly to 110/70 mmHg; however, acute renal function deterioration superimposed on chronic renal failure developed. This acute renal dysfunction could be due to nonspecific effects of hypotension,

which may have caused a sudden deterioration in kidney perfusion. In contrast, the dysfunction may have been due to ACE inhibition-related acute renal failure due to bilateral renal artery stenosis. The incidence of significant azotemia complicating ACE inhibition therapy in patients with renovascular disease is uncertain. ACE inhibitor-induced renal failure has been reported in 23% of patients with bilateral renal artery stenosis and in 38% of patients with only one kidney with a stenotic artery (18).

This problem is usually reversed by stopping the ACE blockade, although some patients may suffer from permanent renal failure. After stopping the valsartan, the previous clinical/laboratory findings (i.e., hypertension and moderately high levels of serum urea and creatinine) reversed. At this time point, the initiation of maintenance hemodialysis was inevitable. This strategy provided the opportunity to control volume overload while also applying an ACE blockade to satisfactorily control blood pressure.

This patient deserves special mention because the only way to manage his condition was to initiate HD and prescribe an ACE inhibitor. The patient was discharged with well-controlled hypertension, but he would need thrice-weekly HD for the rest of his life.

In conclusion, in patients with Leriche syndrome and bilateral renal artery occlusion, hemodialysis accompanied by antihypertensive therapy with a renin-angiotensin blocker may be inevitable if renal revascularization is not an option.

AUTHOR CONTRIBUTIONS

Yilmaz M followed up and treated the patient and drafted the manuscript. Kaptanogullari OH and Erturk K performed data collection and wrote the manuscript. Caliskan C performed the radiological examinations. Arar AS, Akgol C, and Unsal A followed-up and treated the patient.

REFERENCES

1. Lee WJ, Cheng YZ, Lin HJ. Leriche syndrome. *Int J Emerg Med.* 2008;1(3):223.

2. Frederick M, Newman J, Kohlwes J. Leriche syndrome. *J Gen Intern Med.* 2010;25(10):102-4.

3. Patel M, Waxman P, Rozenblit A, Tafreshi M, Alexander LL. An unusual angiographic appearance of aorto-iliac disease presenting as the Leriche syndrome. *J Natl Med Assoc.* 1985;77(1):57-61.

4. Takigawa M, Akutsu K, Kasai S, Tamori Y, Yoshimuta T, Higashi M, et al. Angiographic documentation of aortoiliac occlusion in Leriche's syndrome. *Can J Cardiol.* 2008;24(7):568.

5. Ferral Hector, Lorenz Jonathan. *Interventional Radiology (RadCases).* NY. 2010;105-6.

6. Erskine JM, Gerbode FL, French SW 3rd, Hood RM. Surgical treatment of thrombotic occlusion of aorta and iliac arteries; the Leriche syndrome. *AMA Arch Surg.* 1959;79(1):85-93, <http://dx.doi.org/10.1001/archsurg.1959.04320070089015>.

7. Leriche R, Morel A. The syndrome of thrombotic obliteration of the aortic bifurcation. *Ann Surg.* 1948;127(2):193-206, <http://dx.doi.org/10.1097/0000658-194802000-00001>.

8. www.learningradiology.com/archives06/COW%20201-Leriche%20Syndrome/lerichecorrect.htm - 26k.

9. Sequera JC, Beckmann CF, Levin DC. *AJR.* 1979;132(5):773-6.

10. Bergan JJ, Trippel OH. Management of juxtra-renal aortic occlusion. *Arch Surg.* 1963;87:230-8, <http://dx.doi.org/10.1001/archsurg.1963.01310140038010>.

11. Nortier JL, del Marmol V. Nephrogenic systemic fibrosis—the need for a multidisciplinary approach. *Nephrol Dial Transplant.* 2007;22(11):3097-101, <http://dx.doi.org/10.1093/ndt/gfm430>.

12. Dorros G, Jaff M, Mathiak L, Dorros II, Lowe A, Murphy K, et al. Four-year follow-up of Palmaz-Schatz stent revascularization as treatment for atherosclerotic renal artery stenosis. *Circulation.* 1998;98(8):642-7, <http://dx.doi.org/10.1161/01.CIR.98.7.642>.

13. Morganti A. Renal angioplasty: better for treating hypertension or for rescuing renal function? *J Hypertens* 1999;17(12Pt 1):1659-65, <http://dx.doi.org/10.1097/00004872-199917120-00001>.

14. Ilkay E, Günel IA, Yavuzkir M, Dağlı N, Karaca I, Celiker H, et al. Effect of renal artery stenting on renal function in patients with ischemic nephropathy. *Jpn Heart J.* 2004;45(4):637-45, <http://dx.doi.org/10.1536/jhj.45.637>.

15. Shiraishi J, Higaki Y, Oguni A, Inoue M, Tatsumi T, Azuma A, et al. Transradial renal artery angioplasty and stenting in a patient with Leriche syndrome. *Int Heart J.* 2005;46(3):557-62, <http://dx.doi.org/10.1536/ihj.46.557>.

16. Jian W, Tajima H, Murata S, Abe Y, Hakozaiki K, Kumazaki T, et al. Renal artery stenosis in a patient with Leriche syndrome: brachial artery access for stent placement. *Radiat Med.* 2004;22(1):49-51.

17. Kaukanen ET, Manninen HI, Matsi PJ, Söder HK. Brachial artery access for percutaneous renal artery interventions. *Cardiovasc Intervent Radiol.* 1997;20(5):353-8, <http://dx.doi.org/10.1007/s002709900167>.

18. Hricik DE, Dunn MJ. Angiotensin-converting enzyme inhibitor-induced renal failure: causes, consequences, and diagnostic uses. *J Am Soc Nephrol.* 1990;1(6):845-58.