



Infections of the hand: an overview

Dimitrios A. Flevas¹
Sophia Syngouna²
Emmanouel Fandridis²
Sotirios Tsiodras³
Andreas F. Mavrogenis¹

- Infections of the hand are common entities that are frequently encountered by orthopaedic surgeons and primary care physicians.
- A high clinical suspicion and a thorough medical history with information about the social and working history of the patients, correct identification of the type and cause of the infection, and prompt initiation of appropriate treatment by the infectious diseases physicians and orthopaedic surgeons are required.
- Late diagnosis and inappropriate treatment may be a significant cause of morbidity for the hand and mortality for the patients. This article reviews the clinical spectrum and microbiology of the most common infections of the hand, and discusses the current concepts for their treatment. The aim is to increase the awareness of the treating physicians of the diagnosis and management of infections in the hand.

Keywords: felon; granuloma; hand; infections; necrotizing fasciitis; osteomyelitis; paronychia; septic arthritis

Cite this article: *EFORT Open Rev* 2019;4:183-193.
DOI: 10.1302/2058-5241.4.180082

Introduction

Infections of the hand are common entities that are frequently encountered by orthopaedic surgeons and primary care physicians in the emergency room.¹ In 1993, Brown and Young suggested that major metropolitan hospitals should expect 25–50 admissions annually for serious hand infections.² Acute infections of the hand are considered to be a significant cause of morbidity and mortality; when left untreated, they can lead to tissue destruction and loss of function or even permanent disability.^{3,4}

In order for health professionals to prevent substantial morbidity, correct identification of the cause of the infection and prompt initiation of appropriate treatment are

required.¹ Treatment requires a multifaceted approach combining proper antimicrobial therapy, immobilization, oedema control, and adequate surgical therapy.^{1,3} Because of the potential for serious morbidity and complications, a combination of aggressive operative and medical therapy should be applied following an early identification in a timely fashion.^{1,5} If any further information about the aetiology of the infection is needed, consultation from an infectious diseases specialist is useful in deciding on the appropriate antimicrobial regimen.^{1,3}

The treatment of hand infections is becoming more challenging for the treating physicians due to the increased virulence of some microorganisms, antibiotics resistance, and delayed medical treatment because of the reduced economical means and access to hospital care of the patients. Consequently, in order to achieve the best practice management, appropriate diagnostic tools, understanding of and familiarity with the unique anatomical and functional complexity of the hand and proper antibiotic selection in collaboration with infectious diseases specialists are required.¹

The spectrum of hand infections varies significantly from finger infections to deep-space infections, and from viral to bacterial and fungal. This article reviews the clinical spectrum and microbiology of the most common infections of the hand, and discusses the current concepts for their treatment. The aim is to increase the awareness of the treating physicians on the diagnosis and management of infections in this anatomic location.

Epidemiology

Patients with hand infections are usually manual workers such as farmers, breeders, builders, fishermen, and athletes of water sports. Medical professionals such as dentists and surgeons are also exposed to hand infections, as well as manual workers with inappropriate protection of their hands with poor quality equipment, currently often because of the financial crisis.^{1,6,7} Additionally, hand and

upper-extremity infections are associated with injuries under special circumstances such as human or animal bites, fight injuries, nail or teeth wounds, and occupational exposure.^{8,9} Certain groups of patients, such as diabetics, intravenous drug abusers, patients on long-term steroid treatment and those with acquired immunodeficiency syndrome, are more susceptible to infection than others when their medical history is considered.^{8,10} Patients' age is an important factor for hand infections. Elderly patients with degenerated vessels, poor perfusion and weakened skin barrier are more likely to present in the medical cabinet with an infected upper limb. Newborns are also prone to hand infections due to their undeveloped immune systems and their sharp nail-ends that can injure their fingertips.¹¹

Anatomy

Hand infections may involve the fingers, the palm and its deep spaces.¹ Common finger infections include paronychia, felon, herpetic whitlow, and pyogenic flexor tenosynovitis.¹ The deep spaces of the hand include the dorsal subaponeurotic, the thenar, the midpalmar, Parona's quadrilateral, and interdigital subfascial web space; infections of these spaces usually result from contiguous spread of infection from other areas of the hand, trauma, or, rarely, from hematogenous spread.¹ The structures that confine the dorsal subaponeurotic space of the hand include the extensor tendons on the dorsal side and the metacarpals and interosseous muscles volarly.¹² On the volar side of the hand, the limits of the thenar space are the adductor pollicis dorsally, the index finger flexor tendon volarly, the adductor pollicis insertion on the proximal phalanx radially, and the midpalmar septum ulnarly.⁴ The dorsal borders of the midpalmar space are the long and ring finger metacarpals and the interosseous muscles; the volar borders are the flexor tendons and the lumbrical muscles. Radially, the midpalmar space is bordered by the midpalmar septum, and ulnarly by the hypothenar muscles.¹² An infection in Parona's space may result from spread of an infection from either the radial or ulnar bursa.¹

Microbiology

Most hand infections result from injuries occurring at home or in the workplace and involve Gram-positive organisms. *Staphylococcus aureus* is the most common isolate associated with hand infections (up to 80%).^{5,13–16} *Staphylococcus aureus* is the most common pathogen infecting clean surgical procedures, while *Staphylococcus epidermidis* is more commonly associated with implants.^{4,17}

There is an increasing incidence of community-acquired methicillin-resistant *Staphylococcus aureus* (MRSA) in hand

infections over the past 15 years.^{1,18} Currently, MRSA has been reported to account for as much as 65% of *Staphylococcus aureus* infections.³ Particularly, MRSA has been reported to be the most commonly cultured isolate in urban medical centers.^{5,14–16} Most complications in patients with hand infections, healthcare costs, hospital stays and treatment failure rates have been associated with MRSA hand infections.^{16,19–22}

MRSA first appeared one year after the introduction of the methicillin penicillin class as a nosocomial infection.²³ Patients at increased risk of MRSA infections are those with a history of diabetes mellitus, or past use of antibiotics, the immunocompromised, intravenous drug users, those who participate in contact sports, military recruits, children enrolled in daycare, prison inmates, and homeless individuals.^{23–25} Risk factors for development of nosocomial MRSA infections include intensive care unit hospitalization, long-term antibiotic treatment, surgical procedures, lengthy hospitalization, and close proximity to hospitalized patients who are colonized or infected with MRSA.²⁴

Other common pathogens associated with hand infections are *Streptococcus species*, Gram-negative organisms and viruses. Infections associated with farm injuries, bite wounds, intravenous drug abuse, or immunocompromise including diabetes mellitus and human immunodeficiency virus often are polymicrobial.^{6,8,13,18,26} Open and contaminated wounds are more commonly associated with Gram-negative, anaerobic, fungal or mixed infections.⁴

Occasional and sporadic cases of many microorganisms and viruses have been reported including fungus spp, mycobacteria, viruses and other atypical isolates, most of which are more common in immunocompromised patients.^{8,13}

Types of hand infections

The most common types of hand infections are bite wounds,^{27–36} paronychia,^{37–42} felons,^{43–47} flexor tenosynovitis,^{48–58} septic arthritis,^{59–70} osteomyelitis,^{71–83} necrotizing fasciitis,^{84–95} and cellulitis.^{96,97}

Bite wounds

Bite wounds are associated with a variety of pathogens depending on the type of the bite. Human bite wounds to the hand consist of approximately 2% of bite wounds.²⁷ Both aerobic and anaerobic bacteria are involved because they represent the normal oral flora.⁴ Although more than 40 bacterial strains have been isolated from human bite wounds,^{1,18} the most common include *Staphylococcus aureus*, α -haemolytic and β -haemolytic *Streptococci species*, *Eikenella corrodens*, *Neisseria species* and various anaerobic bacteria.^{28,29} Viral transmission remains also possible in human bite wounds.^{1,18} Two types of human bite wounds to the hand are the clenched fist injuries



Fig. 1 Clenched fist bite wound at the dorsum of the hand after a fight injury.

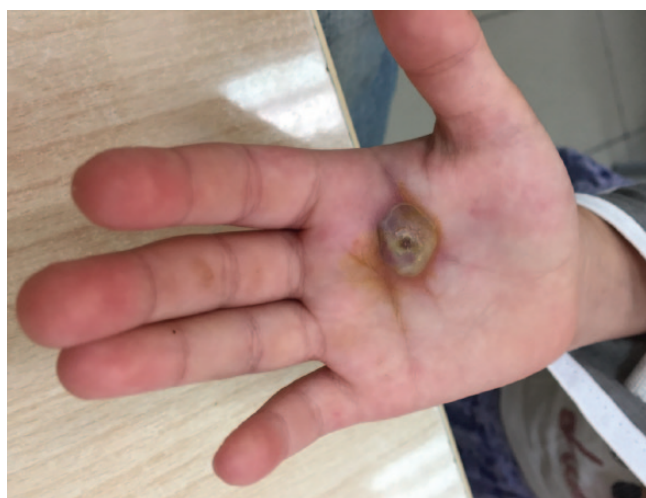

Fig. 2 Infected dog bite wound at the palm.

(Fig. 1) and the true bite injuries.^{1,30} Clenched fist injuries might seem simple at presentation and usually can be misleading. Occult clenched fist injuries may include a traumatic arthrotomy, open metacarpal fracture, or an underlying broken tooth part.^{1,6,13,30,31} Any patient with an open wound at the knuckles should be carefully examined with the hand in the position that the injury occurred because, due to the mobility of the skin on the dorsal aspect of the hand, the exact position of a deeper injury might be missed.³⁰

Dog bite wounds (Fig. 2) are more common than cat bite wounds. Both are more commonly associated with *Pasteurella* species and other aerobic bacteria such as *Streptococci*, *Moraxella* and *Neisseria*. Anaerobic bacteria such as *Fusobacterium*, *Bacteriodes*, *Porphyromonas* and

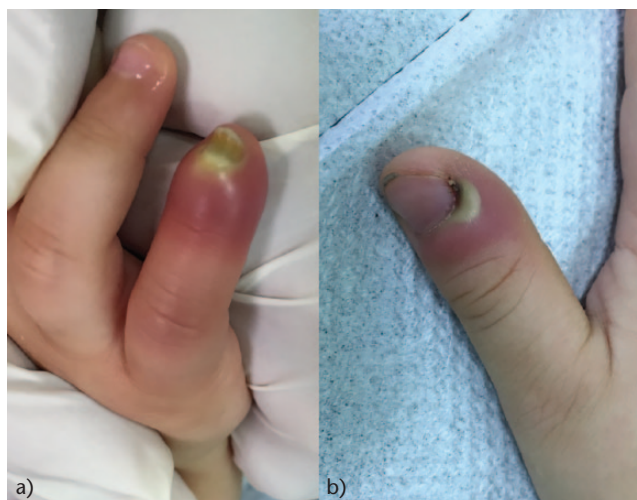

Fig. 3 Acute paronychia requiring drainage in (a) a child and (b) an adult.

Prevotella have also been isolated.^{4,32,33} *Pasteurella canis* is the most common pathogen isolated in dog bite wounds,³³ while in cat bite wounds the most common is *Pasteurella multocida* and subspecies.^{33,34}

Bite wounds to the hand have more chance to become infected compared to other parts of the body because of many small compartments and thin soft tissue coverage.³⁵ Dog bite wounds become infected in many fewer cases compared to cat bite wounds (approximately 4% and 50%, respectively).³⁶ This difference in infection rates between dog and cat bite wounds is attributed to the different anatomy and mechanism of biting between the two animals; while dogs cause large wounds with a crushing and tearing mechanism that allows infection agents to drain out, cats' teeth create small punctures on the skin that heal quickly and trap the bacteria inside.¹

Paronychia

Paronychia is the inflammation of the tissue that immediately surrounds the nail.³⁷ It is the most common infection of the hand and it occurs after disruption of the seal between the nail fold and the nail plate due to penetrating trauma, nail biting, manicures or a hangnail.^{3,38,39} Infection may be acute, when duration is less than six weeks, or chronic, when duration is six weeks or more.³⁷ In acute infections, a painful swollen area with erythema develops under the nail fold and purulent drainage may develop, which usually needs surgical drainage (Fig. 3).^{1,4,37} *Staphylococcus aureus* is the most common organism responsible for the acute paronychia followed by gamma-haemolytic streptococci and *Klebsiella pneumoniae*.^{1,37,40} Chronic paronychia is often related to repeated exposure to environmental irritants that are colonized by fungal (most commonly *Candida albicans*) or bacterial pathogens, and

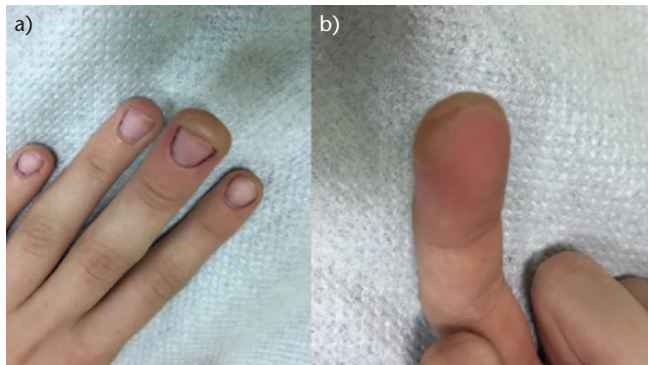


Fig. 4 (a) Dorsal and (b) palmar view of the middle finger show a felon with abscess formation.

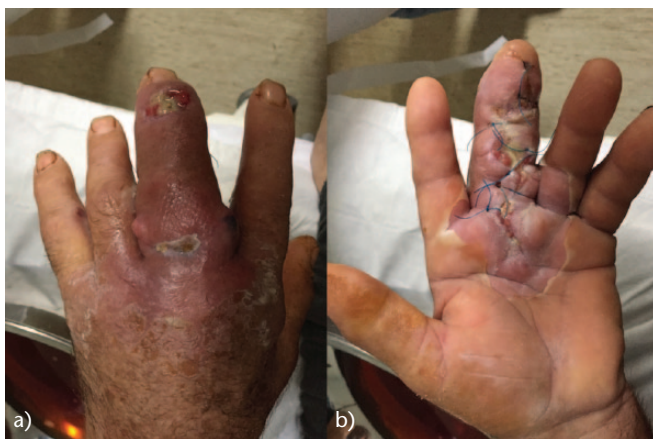

Fig. 5 (a) Dorsal and (b) palmar views of the hand show flexor tenosynovitis of the middle finger treated with open surgical drainage and debridement.

occurs after disruption of the barrier formed by the eponychium and the nail vest. Individuals with high exposure to moisture and/or chemical irritants and patients with diabetes mellitus and immunosuppression are at higher risk of developing chronic paronychia.^{1,4,37,41,42}

Felon

A felon is a closed-space infection that affects the distal finger pulp; *Staphylococcus aureus* is the most common bacterial isolate.^{1,4} At the distal phalanx, a closed space is created by multiple vertical fibrous septa that originate from the periosteum of the distal phalanx and attach to the skin creating a closed space of connective tissue.^{1,43} An abscess can easily develop after inoculation in the pulp; however, most patients present after abscess formation and surgical drainage is required (Fig. 4).^{1,4,38,44,45} Differential diagnosis should include herpes simplex virus infection^{10,46} in which surgical drainage is not recommended.^{1,4,10,46,47}

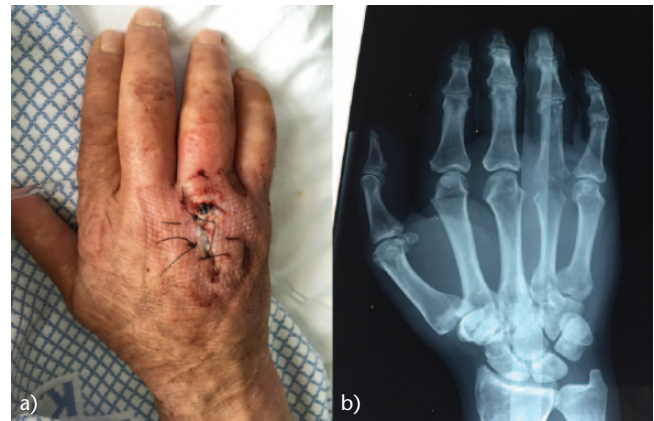

Fig. 6 (a) Clinical photograph and (b) radiograph of the hand show septic arthritis of the fourth metacarpophalangeal joint after trauma.

Flexor tenosynovitis

Flexor tenosynovitis is the bacterial infection of the flexor tendon sheath that occurs between the visceral and the parietal layer on the flexor tendons. It is most commonly associated with *Staphylococcus aureus* infection after a penetrating trauma.¹ The flexor tendon sheath communicates directly with the radial and ulnar bursae, which are in continuum with Parona's space.⁴ Therefore, infections of the flexor tendon sheaths can spread proximal to Parona's space⁴⁸ and form a large horseshoe-shaped abscess.⁴⁹

The typical signs of tenosynovial infection include exquisite tenderness over the course of the entire sheath, a semiflexed posture of the finger, pain on passive extension of the finger, and symmetrical swelling of the entire finger (Fig. 5).^{1,4,50} All four symptoms may not be present, however, when flexor tenosynovitis is clinically suspected treatment should be commenced immediately to prevent flexor-tendon adhesions or necrosis. Early treatment should include intravenous antibiotics administration, elevation, splinting and close monitoring; if symptoms do not improve within 24 hours, surgical drainage is recommended.^{51–53} Closed tendon sheath irrigation with two drainage incisions is a technique useful for treating pyogenic flexor tenosynovitis without tendon necrosis.^{51,54,55} For severe infections with tendon necrosis, open debridement is preferred.^{4,56–58}

Septic arthritis

Septic arthritis of the hand joints is not usual and most commonly results from penetrating trauma (Fig. 6) or direct inoculation from an existing infection in the neighbouring bones or soft tissues.^{4,59–62} Septic arthritis of the wrist is uncommon, with reported rates ranging from 1.5% to 5%,^{63,64} *Staphylococcus aureus*^{1,64,65} followed by *Streptococcus species* are the most common bacterial isolates.^{1,65}

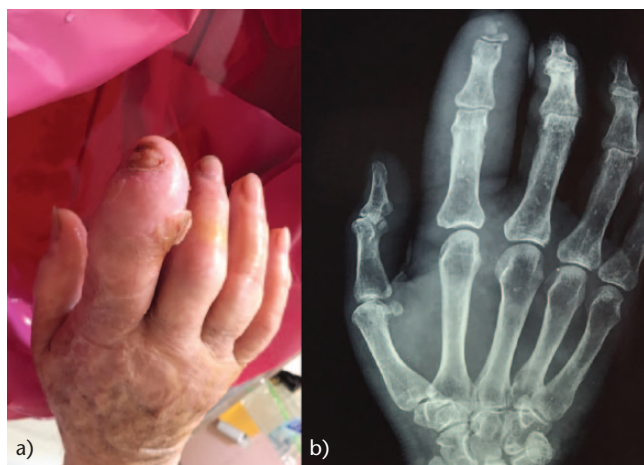

Fig. 7 (a) Clinical photograph and (b) radiograph of the hand show osteomyelitis of the distal phalanx of the index in a patient with diabetes mellitus.

Patients usually present with a swollen, erythematous and painful joint, often with an obvious adjacent penetrating trauma.^{1,4,66} When trauma is not evident, the differential diagnosis should include degenerative arthritis, inflammatory arthritis, crystalline arthropathy, cellulitis and soft tissue abscess.⁶⁷

The treatment of choice for septic arthritis of the hand is open or arthroscopic surgical debridement and antibiotics administration.^{64,66,68,69} The optimal antimicrobial regimen for patients with hand or wrist septic arthritis is unclear.⁶⁵ Guidelines suggest courses from ten days to many weeks depending on the bacterial isolate and clinical improvement of the infection.^{59,65,66,70}

Osteomyelitis

Osteomyelitis of the hand is relatively uncommon^{1,4,71} because of the hand's extensive blood supply.^{3,72} It accounts for 1% to 6% of all hand infections, and approximately 10% of all cases of osteomyelitis.^{73–76} It most commonly results from direct inoculation from an open fracture, contiguous spread after trauma,⁷⁶ and after internal fixation of fractures in the hand (0% to 2.5%).^{74,77} Hematogenous spread is also possible in children but it is rare in adults.¹ In most cases (approximately 70%), a single bone is involved that most commonly is the distal phalanx (38%) followed by the proximal phalanx and the metacarpal.^{76,78} The most common associated pathogens are *Staphylococcus aureus* and *Streptococcus species*.^{1,4,71} Atypical isolates such as Gram-negative, anaerobic and mycobacterial, or polymicrobial infections are often encountered in immunocompromised patients, patients with diabetic mellitus (Fig. 7) and those with crush or blast injuries of the hand and injuries in moist and contaminated environments.^{76,79,80}

The clinical presentation includes pain, swelling, erythema at the infected area, and functional impairment of the hand. Chronic infections may present with a draining sinus;^{1,4,71} systemic symptoms are rare but may occur.⁴ Radiographs show osteolysis (70%) followed by osteopenia (10%), osteosclerosis (10%), periosteal reaction (10%) and sequestrum/involucrum formation (5%).⁷⁶ Routine laboratory studies are rarely helpful for the diagnosis of osteomyelitis of the hand.^{71,76}

Early diagnosis and treatment is important to avoid debilitating consequences for the hand.^{76,81,82} Although some authors suggest that osteomyelitis of the hand in its very early stages can be managed with antibiotics administration alone,^{71,83} it is recommended that the optimal treatment is surgical drainage and debridement before starting antibiotic therapy.^{1,79} Antibiotic therapy is typically recommended for at least four to six weeks (intravenous and/or oral); however, the increased vascularity and the reduced load bearing of the hand favour successful treatment.⁷¹

Necrotizing fasciitis

Necrotizing fasciitis is a medical emergency that may lead to loss of limb or even death.^{1,4} It is a bacterial infection of the subcutaneous tissues that surround muscles, nerves, fat, and blood vessels.⁸⁴ It may occur after small or large trauma and usually affects the extremities.^{47,85} Individuals at risk include intravenous drug abusers (> 60% of infections), diabetics, alcoholics, and patients who suffer from peripheral vascular disease.^{11,81,85–89} The most common bacterial isolates include *Streptococcus pyogenes* (group A), polymicrobial infections,⁸⁹ anaerobes, *Aeromonas*, *Clostridium species*, *Streptococcus species* and *Staphylococcus species* with an increasing incidence of MRSA infections.^{1,85,89,90}

Symptoms and signs of necrotizing fasciitis include severe pain, non-pitting oedema, violaceous bullae, cutaneous haemorrhage, skin sloughing, skin anaesthesia (late finding), rapid progression, and crepitus due to gas formation in the infected tissue.⁹⁰ Initially, infection may appear benign and often presentation signs can be delayed.^{1,4} Strong signs of necrotizing fasciitis, including skin necrosis, bullae, crepitus, appearance of gas on imaging studies and haemodynamic instability, may not always be present.⁹¹ Definite diagnosis of the infection is carried out with histological documentation of the necrotic fascia.¹

Intraoperatively, the fascia appears swollen and dull with areas of necrosis.^{47,92} Other typical findings include 'dishwater pus', that is, thin and foul smelling pus found along fascial planes,⁸³ subcutaneous vessel thrombosis, and skin, fat and rarely muscle involvement.⁴⁷ Necrotizing fasciitis should be considered in patients with haemodynamic instability accompanied by a seemingly unimpressive soft tissue infection.⁸⁹ A laboratory risk indicator for

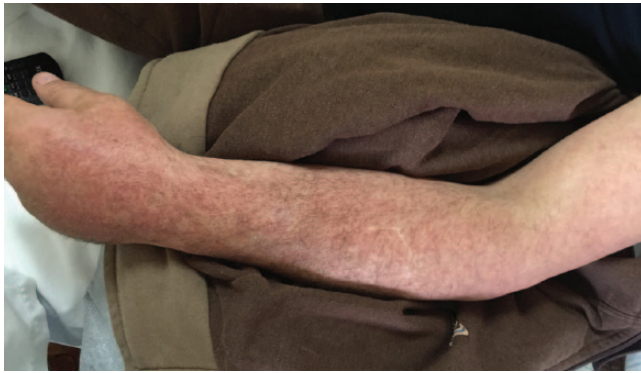


Fig. 8 Cellulitis of the upper extremity.

necrotizing fasciitis (LRINEC) has been reported;⁹³ however, its value has been questioned, especially in infections from atypical pathogens such as vibrio bacteria.⁹⁴

The treatment of choice for necrotizing fasciitis includes urgent and aggressive surgical debridement combined with intravenous antibiotics.^{1,4,83,95} In order to achieve adequate debridement, longitudinal incisions along the extremity must be performed followed by excision of all necrotic tissues.⁸⁹ Repeated debridements every 24 to 48 hours may be required in order to control the infection.^{1,83} Survival rate for upper-extremity necrotizing fasciitis is reported to be more than 90% if early and adequate debridement and broad-spectrum antibiotics administration is undertaken.⁸⁹ The outcome is not optimal in patients older than 50 years, those with chronic illnesses or diabetes mellitus, and those with involvement of the trunk.^{85,89}

Cellulitis

Cellulitis is a relatively common infection of the hand characterized by a spreading, diffuse inflammation of the skin with leukocyte infiltration without underlying abscess formation (Fig. 8).^{1,83} The most common organisms associated with cellulitis are *Staphylococcus aureus* and *Streptococcus pyogenes*.¹ Radiographic examination to exclude a foreign body (Fig. 9), fracture or dislocation and osteomyelitis should be carried out. The treatment of choice for cellulitis includes broad-spectrum oral or intravenous antibiotics administration,^{1,83,96,97} immobilization, elevation of the hand and close observation.¹²³

Atypical infections

Although most hand infections are caused by common skin bacteria, hand surgeons should be aware of the possibility of infections caused by less usual microorganisms. These include mycobacteria, viruses or fungi. Such infections will not respond to broad-spectrum antibiotics and are especially common in immunocompromised

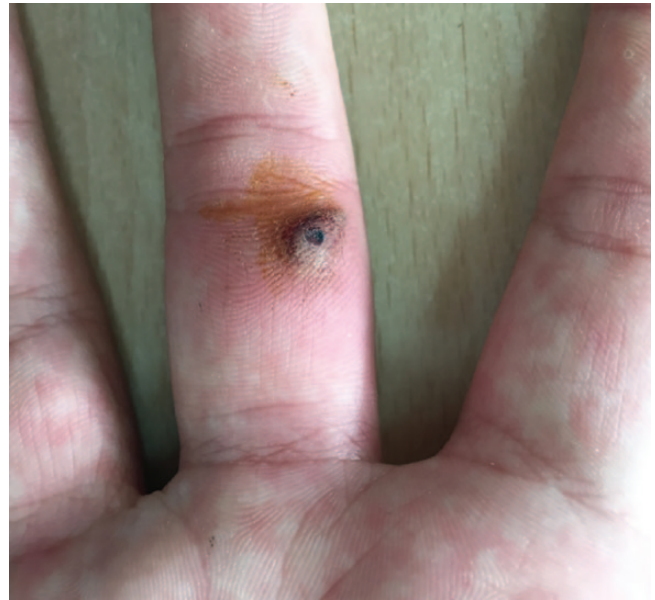

Fig. 9 Granuloma formation after a foreign body at the middle finger.

patients.¹⁰ Atypical mycobacteria, tuberculosis and fungi can cause chronic infections that may be difficult to recognize and can often be mistreated as gout, rheumatoid arthritis, or low-grade pyogenic infections.⁴

Mycobacterial infections

Although tuberculosis was once showing a marked decline, recently it has been observed with rising incidence in immunocompromised patients, especially those suffering from AIDS.¹⁰ Mycobacterium tuberculosis is more commonly related with pulmonary disease. In the hand, tuberculous infections may present in three ways: synovial infection, osteomyelitis or septic arthritis and dactylitis (also known as spin ventosa).^{98,99} Dactylitis is characterized by enlargement of the fingers and radiographic appearance of proliferation of subperiosteal reaction of the phalanges and/or the metacarpals.^{4,98} Diagnosis of tuberculosis can be made by open biopsy and cultures.^{4,10,98}

Mycobacterium species other than tuberculosis (MOTT) can cause hand infections, which, although rare, are relatively resistant. The Runyon classification categorizes MOTT into four types: I) photochromogens, II) scotochromogens, III) nonchromogens, and IV) rapid growers.^{10,98,100} Each type includes several mycobacteria types. *Mycobacterium marinum* (a photochromogen) is the most common mycobacterium to cause hand infections.^{10,101} The annual incidence of infections due to *M. marinum* is reported at between 0.05 to 0.27 infections/100,000 patients; they most commonly occur in aquatic environments from direct skin inoculation.^{10,102}

The second most common mycobacterium after *M. marinum* that is involved in upper-extremity infection is *Mycobacterium avium-intraeculare* (MAC).¹⁰ MAC (a nonchromogen) is the most prevalent of the MOTT group and is the most common mycobacterium isolate when deep tissues are involved in the infection.^{10,103} MAC causes granulomatous tenosynovitis in immunocompromised patients, and may also lead to systemic infections in this patient group.¹⁰⁴ Treatment of MAC hand infections includes combined medical and surgical treatment.¹⁰⁵

Leprosy or Hansen's disease is a rare disease caused by *Mycobacterium leprae*. The disease has two main forms (paucibacillary and multibacillary)¹⁰⁶ and initially affects Schwann cells, subepidermal cells and perivascular skin macrophages. In the upper extremity, the ulnar nerve is involved most commonly followed by the median and radial nerves.¹⁰ Five stages of nerve involvement have been described from mild disease to completely fibrotic and permanent loss of nerve function.¹⁰⁷

Fungal infections

Fungal infections of the hand include four types: cutaneous, subcutaneous, deep and systemic.¹⁰⁸ Cutaneous fungal infections or tinea infections involve the skin, hair and nails. They are among the most common hand infections.¹⁰ They are caused by three dermatophytes that utilize keratin:¹⁰⁸ *Trichophyton*, *Microsporum* and *Epidermophyton species*. The dermatophytes are keratinophilic saprophytes that are found at the dead stratum corneum of the skin, nails and hair. The inflammatory response to their metabolic products results to the clinical disease.¹⁰ Onychomycosis is more common in middle-aged women and is usually caused by *Trichophyton rubrum*, but can also be caused by *Candida species*. Furthermore, *Candida species* are responsible for chronic or recurrent paronychia that is more prevalent in women working in moist environments and those patients who work under water. Cutaneous dermatophytosis of the hand (tinea manus) is commonly caused by *Trichophyton mentagrophytes* or *Trichophyton rubrum*. *Exophiala werneckii* causes tinea nigra that is a lesion mimicking melanoma.¹⁰ Five genera of dematiaceous fungi (*Phialophora*, *Cladosporium*, *Wangiella*, *Exophiala* and *Fonsecaea*) cause infections called chromomycoses that are characterized by the formation of superficial lesions on the upper extremity after thorns injuries.¹⁰⁶

The most common subcutaneous infection of the hand is sporotrichosis, a fungal infection caused by *Sporothrix schenckii* that is found in plants and soil.^{10,108,109} This subcutaneous infection almost exclusively occurs in the upper extremity after thorn injuries from plants, especially roses.¹ Initially, an ulcer is created at the injury site and then the local lymph nodes (most commonly the epitrochlear lymph nodes) become involved.^{1,10,109} Eventually, the

involved lymph nodes may ulcerate and drain seropurulent fluid.¹¹⁰

Deep fungal infections are less common and are often seen in immunosuppressed patients by either virulent or opportunistic fungi.¹ They may occur after direct inoculation of fungus into deep soft tissues¹⁰⁸ or via haematogenous spread.¹ Systemic fungal infections including histoplasmosis, blastomycosis and coccidiomycosis can be divided into those that occur in healthy individuals and those that occur in immunocompromised patients.^{10,108} In healthy individuals the disease usually begins with a pulmonary infection.¹⁰ In systemic fungal infections the fungi convert from their saprophytic mycelia into the parasitic form. Fungal infections by *Cryptococcus* and *Aspergillus species* and *mucomycosis* cause opportunistic fungal infections in immunocompromised patients.^{10,108}

In the hand, histoplasmosis may cause tenosynovial granulomatous infection.^{111,112} Blastomycosis may cause cutaneous lesions that may evolve into draining fistulae with bone involvement (osteomyelitis and septic monoarthritis).¹⁰ Coccidiomycosis can cause tenosynovitis in adults and osteomyelitis of the bones of the hand in children.¹¹³

Aspergillus has been reported as an opportunistic pathogen in immunocompromised children with acute leukaemia and it is common in patients with AIDS and low CD4 counts. The infection may manifest as a primary cutaneous lesion of the hand.^{10,114} *Cryptococcus* may cause skin infection and tenosynovitis in the hand.^{10,115,116} Necrotizing fasciitis has also been reported.¹¹⁷ Mucormycosis is caused by the fungi *Mucor*, *Rhizopus* and *Absidia*, and most commonly involves the cutaneous and subcutaneous tissues. It appears more commonly in patients with trauma contaminated by soil or water, and may evolve to gangrenous tissue necrosis.¹⁰ Mucormycosis has also been reported in immunocompromised patients, patients with diabetes, and immunocompetent individuals after corticosteroid injections.^{118–120}

Candida species infection (candidiasis) involves the joints or the tenosynovium, and occurs most commonly in immunocompromised patients.^{121,122} Superficial infections are the most common.¹⁰ Extracutaneous deep infections caused by *Sporothrix species* are rare; however, sporotrichal arthritis of the wrist, osteomyelitis, olecranon bursitis and extensor tendon rupture caused by sporotrichal extensor tenosynovitis have been described.^{10,123,124}

Viral infections

Herpes simplex virus (HSV) infection is the most common viral infection of the hand.¹⁰ The infection is caused after local contact with the virus and it is considered an occupational hazard for individuals who handle oral-tracheal secretions such as dentists, dental hygienists, anesthesiologists, nurses and other healthcare workers,^{1,10} as well as

being common in immunocompromised patients.⁴ Herpetic whitlow is a painful cutaneous infection caused by HSV-1 or HSV-2 and most commonly affects the distal phalanx of the fingers. Most cases in children are due to autoinoculation of HSV-1, while in adults herpetic whitlow tends to be due to autoinoculation of HSV-2.¹²⁵ After the virus' inoculation, infection presents as vesicles and then the virus might migrate via a nerve until it reaches a dorsal root ganglion corresponding to the primary area of skin infected by the virus.¹ The infection often causes a tingling sensation in the involved fingertip and tends to mimic a felon. However, the pulp space remains soft and that differentiates HSV infection from a felon.^{10,46} Incision and drainage is not recommended because it has been associated with bacterial infection, or may lead to systemic dissemination of HSV.^{1,4,10,46,47} There is a potential of multiple recurrences after initial treatment because the virus remains in a latent state in the nervous ganglia after the initial infection is cleared.^{126,127}

Papillomavirus causes a specific variety of cutaneous warts. The most common way of transmission for hand infection is self-inoculation; the incidence of the infection is increased in poultry and meat handlers.¹⁰ Parapoxvirus causes hand infection in animal handlers. The lesions are self-limited, they start as erythematous papules and progress to a maculopapular stage which is followed by a papillomatous stage.^{10,128}

Differential diagnosis

Mimicking entities of hand infections include crystal deposit diseases, and viral infections.^{4,46} Crystal deposit diseases (gout and pseudogout) tend to present with joint swelling, erythema, pain with motion, and fever.⁴ The diagnosis of such a condition is confirmed after aspiration of the joint and observation of crystals with polarizing microscopy. Herpetic virus infections may mimic a felon. However, in herpetic infections, the patients usually experience a 24-to-72 hour period of prodromal burning pain before developing skin changes. Differential diagnosis in such cases is important because, unlike felons, herpetic whitlow should not be drained.⁴⁶

Conclusions

Practicing physicians, hand surgery fellows and surgeons may encounter a wide variety of hand infections regarding not only the type of the infections but also the anatomic characteristics in the hand and their aetiology. Some are associated with substantial morbidity for the hand or the patient. Therefore, high clinical suspicion and a thorough medical history with information about the social and working history of the patient are necessary. Prompt diagnosis and early appropriate surgical

management and antibiotic administration is crucial for all patients with hand infections; those that require immediate treatment include necrotizing soft tissue infections, flexor tenosynovitis, deep hand-space infections, and septic arthritis. The orchestrated and properly designed treatment for hand infections by the infectious diseases physicians and orthopaedic surgeons has reduced complications and morbidity.

AUTHOR INFORMATION

¹First Department of Orthopaedics, National and Kapodistrian University of Athens, School of Medicine, Athens, Greece.

²Department of Upper Extremity Surgery and Microsurgery, KAT Hospital, Athens, Greece.

³Fourth Department of Internal Medicine, National and Kapodistrian University of Athens, School of Medicine, Athens, Greece.

Correspondence should be sent to: Andreas F. Mavrogenis, First Department of Orthopaedics, National and Kapodistrian University of Athens, School of Medicine, 41 Ventouri Str. 15562, Athens, Greece.
Email: afm@otenet.gr

ICMJE CONFLICT OF INTEREST STATEMENT

The author declares no conflict of interest relevant to this work.

FUNDING STATEMENT

No benefits in any form have been received or will be received from a commercial party related directly or indirectly to the subject of this article.

LICENCE

© 2019 The author(s)

This article is distributed under the terms of the Creative Commons Attribution-Non Commercial 4.0 International (CC BY-NC 4.0) licence (<https://creativecommons.org/licenses/by-nc/4.0/>) which permits non-commercial use, reproduction and distribution of the work without further permission provided the original work is attributed.

REFERENCES

1. McDonald LS, Bavaro MF, Hofmeister EP, Kroonen LT. Hand infections. *J Hand Surg Am* 2011;36:1403–1412.
2. Brown DM, Young VL. Hand infections. *South Med J* 1993;86:56–66.
3. Türker T, Capdarest-Arest N, Bertoch ST, Bakken EC, Hoover SE, Zou J. Hand infections: a retrospective analysis. *Peer J* 2014;2:e513.
4. Ong YS, Levin LS. Hand infections. *Plast Reconstr Surg* 2009;124:225e–233e.
5. Kistler JM, Thoder JJ, Ilyas AM. MRSA incidence and antibiotic trends in urban hand infections: a 10-year longitudinal study. *Hand (NY)* 2018;1:1558944717750921.
6. Chuinard RG, D'Ambrosia RD. Human bite infections of the hand. *J Bone Joint Surg Am* 1977;59:416–418.
7. Young-Afat DA, Dayicioglu D, Oeltjen JC, Garrison AP. Fishing-injury-related flexor tenosynovitis of the hand: a case report and review. *Case Rep Orthop* 2013;5:87176.
8. Reyes FA. Infections secondary to intravenous drug abuse. *Hand Clin* 1989;5:629–633.

9. Raval P, Khan W, Haddad B, Mahapatra AN. Bite injuries to the hand: review of the literature. *Open Orthop J* 2014;8:204–208.
10. Elhassan BT, Eynn SW, Gonzalez MH. Atypical infections of the hand. *J Hand Surg Am* 2004;4:42–49.
11. Gafur OA, Copley LA, Hollmig ST, et al. The impact of the current epidemiology of pediatric musculoskeletal infection on evaluation and treatment guidelines. *J Pediatr Orthop* 2008;28:777–785.
12. Burkhalter WE. Deep space infections. *Hand Clin* 1989;5:553–559.
13. Hausman MR, Lisser SP. Hand infections. *Orthop Clin North Am* 1992;23:171–185.
14. Bach HG, Steffn B, Chhadia AM, Kovachevich R, Gonzalez MH. Community-associated methicillin-resistant *Staphylococcus aureus* hand infections in an urban setting. *J Hand Surg Am* 2007;32:380–383.
15. Fowler JR, Greenhill D, Schaffer AA, Thoder JJ, Ilyas AM. Evolving incidence of MRSA in urban hand infections. *Orthopedics* 2013;36:796–800.
16. Tosti R, Samuelsen BT, Bender S, et al. Emerging multidrug resistance of methicillin-resistant *Staphylococcus aureus* in hand infections. *J Bone Joint Surg Am* 2014;96:1535–1540.
17. Gästrin B, Lövestad A. Postoperative wound infection: relation to different types of operation and wound contamination categories in orthopaedic surgery. *J Hosp Infect* 1989;13:387–393.
18. Goldstein EJ, Citron DM, Wield B, et al. Bacteriology of human and animal bite wounds. *J Clin Microbiol* 1978;8:667–672.
19. Houshian S, Seyedipour S, Wedderkopp N. Epidemiology of bacterial hand infections. *Int J Infect Dis* 2006;10:315–319.
20. Lodise TP Jr, McKinnon PS. Burden of methicillin-resistant *Staphylococcus aureus*: focus on clinical and economic outcomes. *Pharmacotherapy* 2007;27:1001–1012.
21. Shorr AF. Epidemiology and economic impact of methicillin-resistant *Staphylococcus aureus*: review and analysis of the literature. *Pharmacoeconomics* 2007;25:751–768.
22. Shorr AF. Epidemiology of staphylococcal resistance. [Review]. *Clin Infect Dis* 2007;45:S171–S176.
23. O'Malley M, Fowler J, Ilyas AM. Community-acquired methicillin-resistant *Staphylococcus aureus* infections of the hand: prevalence and timeliness of treatment. *J Hand Surg Am* 2009;34:504–508.
24. Salgado CD, Farr BM, Calfee DP. Community-acquired methicillin-resistant *Staphylococcus aureus*: a meta-analysis of prevalence and risk factors. *Clin Infect Dis* 2003;36:131–139.
25. Wilson PC, Rinker B. The incidence of methicillin-resistant *Staphylococcus aureus* in community-acquired hand infections. *Ann Plast Surg* 2009;62:513–516.
26. Arons MS, Fernando L, Polayes IM. *Pasteurella multocida*—the major cause of hand infections following domestic animal bites. *J Hand Surg Am* 1982;7:47–52.
27. Callahan ML. Human and animal bites. *Adv Emerg Nurs J* 1982;4:1–15.
28. Faciszewski T, Coleman DA. Human bite wounds. *Hand Clin* 1989;5:561–569.
29. Taplitz RA. Managing bite wounds: currently recommended antibiotics for treatment and prophylaxis. *Postgrad Med* 2004;116:49–52, 55–56, 59.
30. Raval P, Khan W, Haddad B, Mahapatra AN. Bite injuries to the hand: review of the literature. *Open Orthop J* 2014;8:204–208.
31. Gonzalez MH, Papierski P, Hall RF Jr. Osteomyelitis of the hand after a human bite. *J Hand Surg Am* 1993;18:520–522.
32. Goldstein EJC. Bite wounds and infection. *Clin Infect Dis* 1992;14:633–638.
33. Talan DA, Citron DM, Abrahamian FM, Moran GJ, Goldstein EJ; Emergency Medicine Animal Bite Infection Study Group. Bacteriologic analysis of infected dog and cat bites. *N Engl J Med* 1999;340:85–92.
34. Westling K, Farra A, Cars B, et al. Cat bite wound infections: a prospective clinical and microbiological study at three emergency wards in Stockholm, Sweden. *J Infect* 2006;53:403–407.
35. Morgan M, Palmer J. Dog bites. *BMJ* 2007;334:413–417.
36. Aghababian RV, Conte JE Jr. Mammalian bite wounds. *Ann Emerg Med* 1980;9:79–83.
37. Shafritz AB, Coppage JM. Acute and chronic paronychia of the hand. *J Am Acad Orthop Surg* 2014;22:165–174.
38. Canales FL, Newmeyer WL III, Kilgore ES Jr. The treatment of felons and paronychias. *Hand Clin* 1989;5:515–523.
39. Linscheid RL, Dobyns JH. Common and uncommon infections of the hand. *Orthop Clin North Am* 1975;6:1063–1104.
40. Brook I. Paronychia: a mixed infection. Microbiology and management. *J Hand Surg [Br]* 1993;18:358–359.
41. Daniel CR III, Daniel MP, Daniel CM, Sullivan S, Ellis G. Chronic paronychia and onycholysis: a thirteen-year experience. *Cutis* 1996;58:397–401.
42. Jebson PJ. Infections of the fingertip: paronychias and felons. *Hand Clin* 1998;14:547–555, viii.
43. Kanavel AB. *Infections of the hand*. Fourth ed. Philadelphia, PA: Lea & Febiger, 1921.
44. Stern PJ. Selected acute infections. *Instr Course Lect* 1990;39:539–546.
45. Conolly WB, Kilgore ES Jr. *Hand injuries and infections: an illustrated guide*. London: Edward Arnold, 1979:138–145.
46. Louis DS, Jebson PJ. Mimickers of hand infections. *Hand Clin* 1998;14:519–529, vii.
47. Abrams RA, Botte MJ. Hand infections: treatment recommendations for specific types. *J Am Acad Orthop Surg* 1996;4:219–230.
48. Siegel DB, Gelberman RH. Infections of the hand. *Orthop Clin North Am* 1988;19:779–789.
49. Neviasser RJ. Acute infections. In: Green DP, Hotchkiss RN, Pederson WC, eds. *Operative hand surgery*. Fourth ed. New York: Churchill Livingstone, 1999:1033–1047.
50. Kanavel AB. *Infections of the hand*. Philadelphia, PA: Lea & Febiger, 1939.
51. Neviasser RJ. Closed tendon sheath irrigation for pyogenic flexor tenosynovitis. *J Hand Surg Am* 1978;3:462–466.
52. Neviasser RJ. Tenosynovitis. *Hand Clin* 1989;5:525–531.
53. Neviasser RJ, Gunther SF. Tenosynovial infections in the hand: diagnosis and management. In: Novacheck TF, ed. *Instructional course lectures*. Park Ridge, IL: American Academy of Orthopaedic Surgeons, 1980:108–128.
54. Carter SJ, Burman SO, Mersheimer WL. Treatment of digital tenosynovitis by irrigation with peroxide and oxytetracycline: review of nine cases. *Ann Surg* 1966;163:645–650.
55. Michon J. Le phlegmon des gaines [Phlegmon of the tendon sheaths]. *Ann Chir* 1974;28:277–280.
56. Boyes JH. *Bunnell's surgery of the hand*. Fifth ed. Philadelphia, PA: JB Lippincott, 1970:613–642.

57. **Entin MA.** Infections of the hand. *Surg Clin North Am* 1964;44:981–993.
58. **Flynn JE.** Modern considerations of major hand infections. *N Engl J Med* 1955;252:605–612.
59. **Mandell GL, Douglas RG, Bennett JE, Dolin R.** *Mandell, Douglas, and Bennett's principles and practice of infectious diseases.* New York: Elsevier/Churchill Livingstone, 2005:1316.
60. **Clerc O, Prod'homme G, Greub G, Zanetti G, Senn L.** Adult native septic arthritis: a review of 10 years of experience and lessons for empirical antibiotic therapy. *J Antimicrob Chemother* 2011;66:1168–1173.
61. **Mathews CJ, Kingsley G, Field M, et al.** Management of septic arthritis: a systematic review. *Ann Rheum Dis* 2007;66:440–445.
62. **Rashkoff ES, Burkhalter WE, Mann RJ.** Septic arthritis of the wrist. *J Bone Joint Surg Am* 1983;65:824–828.
63. **Skeete K, Hess EP, Clark T, Moran S, Kakar S, Rizzo M.** Epidemiology of suspected wrist joint infection versus inflammation. *J Hand Surg Am* 2011;36:469–474.
64. **Jennings JD, Zielinski E, Tosti R, Ilyas AM.** Septic arthritis of the wrist: incidence, risk factors, and predictors of infection. *Orthopedics* 2017;40:e526–e531.
65. **Kowalski TJ, Thompson LA, Gundrum JD.** Antimicrobial management of septic arthritis of the hand and wrist. *Infection* 2014;42:379–384.
66. **Murray PM.** Septic arthritis of the hand and wrist. *Hand Clin* 1998;14:579–587, viii.
67. **Yap RT, Tay SC.** Wrist septic arthritis: an 11 year review. *Hand Surg* 2015;20:391–395.
68. **Sammer DM, Shin AY.** Comparison of arthroscopic and open treatment of septic arthritis of the wrist. *J Bone Joint Surg Am* 2009;91:1387–1393.
69. **Mehta P, Schnall SB, Zalavras CG.** Septic arthritis of the shoulder, elbow, and wrist. *Clin Orthop Relat Res* 2006;451:42–45.
70. **Sinha M, Jain S, Woods DA.** Septic arthritis of the small joints of the hand. *J Hand Surg [Br]* 2006;31:665–672.
71. **Pinder R, Barlow G.** Osteomyelitis of the hand. *J Hand Surg Eur* 2016;41:431–440.
72. **Szabo RM, Spiegel JD.** Infected fractures of the hand and wrist. *Hand Clin* 1988;4:477–489.
73. **Belcher HJCR, Clare TD.** Hand infections. *Curr Orthop* 2003;17:28–43.
74. **Duncan RW, Freeland AE, Jabaley ME, Meydrech EF.** Open hand fractures: an analysis of the recovery of active motion and of complications. *J Hand Surg Am* 1993;18:387–394.
75. **McLain RF, Steyers C, Stoddard M.** Infections in open fractures of the hand. *J Hand Surg Am* 1991;16:108–112.
76. **Reilly KE, Linz JC, Stern PJ, Giza E, Wyrick JD.** Osteomyelitis of the tubular bones of the hand. *J Hand Surg Am* 1997;22:644–649.
77. **Chow SP, Pun WK, So YC, et al.** A prospective study of 245 open distal fractures of the hand. *J Hand Surg [Br]* 1991;16:137–140.
78. **Barbieri RA, Freeland AE.** Osteomyelitis of the hand. *Hand Clin* 1998;14:589–603, ix.
79. **Freeland AE, Senter BS.** Septic arthritis and osteomyelitis. *Hand Clin* 1989;5:533–552.
80. **Mann RJ, Peacock JM.** Hand infections in patients with diabetes mellitus. *J Trauma* 1977;17:376–380.
81. **Francel TJ, Marshall KA, Savage RC.** Hand infections in the diabetic and the diabetic renal transplant recipient. *Ann Plast Surg* 1990;24:304–309.
82. **Honda H, McDonald JR.** Current recommendations in the management of osteomyelitis of the hand and wrist. *J Hand Surg Am* 2009;34:1135–1136.
83. **Koshy JC, Bell B.** Hand infections. *J Hand Surg Am* 2019;44:46–54.
84. **Centers for Disease Control and Prevention.** Necrotizing fasciitis. <https://www.cdc.gov/features/necrotizingfasciitis/index.html> (date last accessed 26 August 2018).
85. **Wilkerson R, Paull W, Coville FV.** Necrotizing fasciitis. Review of the literature and case report. *Clin Orthop Relat Res* 1987;216:187–192.
86. **Jacobson JM, Hirschman SZ.** Necrotizing fasciitis complicating intravenous drug abuse. *Arch Intern Med* 1982;142:634–635.
87. **Pessa ME, Howard RJ.** Necrotizing fasciitis. *Surg Gynecol Obstet* 1985;161:357–361.
88. **Green RJ, Dafoe DC, Raffin TA.** Necrotizing fasciitis. *Chest* 1996;110:219–229.
89. **Schecter W, Meyer A, Schecter G, Giuliano A, Newmeyer W, Kilgore E.** Necrotizing fasciitis of the upper extremity. *J Hand Surg Am* 1982;7:15–20.
90. **Stevens DL, Bisno AL, Chambers HF, et al; Infectious Diseases Society of America.** Practice guidelines for the diagnosis and management of skin and soft-tissue infections. *Clin Infect Dis* 2005;41:1373–1406.
91. **Chan T, Yaghubian A, Rosing D, Kaji A, de Virgilio C.** Low sensitivity of physical examination findings in necrotizing soft tissue infection is improved with laboratory values: a prospective study. *Am J Surg* 2008;196:926–930.
92. **Ryssel H, Germann G, Kloeters O, Radu CA, Reichenberger M, Gazyakan E.** Necrotizing fasciitis of the extremities: 34 cases at a single centre over the past 5 years. *Arch Orthop Trauma Surg* 2010;130:1515–1522.
93. **Wong CH, Khin LW, Heng KS, Tan KC, Lo CO.** The LRINEC (Laboratory Risk Indicator for Necrotizing Fasciitis) score: a tool for distinguishing necrotizing fasciitis from other soft tissue infections. *Crit Care Med* 2004;32:1535–1541.
94. **Huang KC, Hsieh PH, Huang KC, Tsai YH.** Vibrio necrotizing soft-tissue infection of the upper extremity: factors predictive of amputation and death. *J Infect* 2008;57:290–297.
95. **Gonzalez MH.** Necrotizing fasciitis and gangrene of the upper extremity. *Hand Clin* 1998;14:635–645, ix.
96. **Janis JE, Hatef DA, Reece EM, Wong C.** Does empiric antibiotic therapy change hand infection outcomes? Cost analysis of a randomized prospective trial in a county hospital. *Plast Reconstr Surg* 2014;133:511e–518e.
97. **Harrison B, Ben-Amotz O, Sammer DM.** Methicillin-resistant *Staphylococcus aureus* infection in the hand. *Plast Reconstr Surg* 2015;135:826–830.
98. **Hoyen HA, Lacey SH, Graham TJ.** Atypical hand infections. *Hand Clin* 1998;14:613–634, ix.
99. **Robins RH.** Tuberculosis of the wrist and hand. *Br J Surg* 1967;54:211–218.
100. **Runyon EH.** Identification of mycobacterial pathogens utilizing colony characteristics. *Am J Clin Pathol* 1970;54:578–586.
101. **Gunther SF.** Chronic infections. *Instr Course Lect* 1990;39:547–554.
102. **Hurst LC, Amadio PC, Badalamente MA, Ellstein JL, Dattwyler RJ.** Mycobacterium marinum infections of the hand. *J Hand Surg Am* 1987;12:428–435.
103. **Kozin SH, Bishop AT.** Atypical Mycobacterium infections of the upper extremity. *J Hand Surg Am* 1994;19:480–487.
104. **Hellinger WC, Smilack JD, Greider JL Jr, et al.** Localized soft-tissue infections with Mycobacterium avium/Mycobacterium intracellulare complex in immunocompetent patients: granulomatous tenosynovitis of the hand or wrist. *Clin Infect Dis* 1995;21:65–69.

- 105. Darrow M, Foulkes G, Richmann PN, de los Reyes CL, Floyd WE III.** Deep infection of the hand with *Mycobacterium avium*-intracellulare: two case reports. *Am J Orthop (Belle Mead NJ)* 1995;24:914–917.
- 106. Floyd WE III, Foulkes GD.** Tuberculous, mycotic, and granulomatous diseases. In: Peimer C, ed. *Surgery of the hand and the upper extremity*. Philadelphia, PA: Saunders, 1996:1770–1785.
- 107. Srinivasan H.** The 19th Kellersberger Memorial Lecture, 1993. Nerve damage, disabilities and rehabilitation in leprosy. *Ethiop Med J* 1993;31:287–301.
- 108. Hitchcock TF, Amadio PC.** Fungal infections. *Hand Clin* 1989;5:599–611.
- 109. Amadio PC.** Fungal infections of the hand. *Hand Clin* 1998;14:605–612.
- 110. Carr MM, Fielding JC, Sibbald G, Freiberg A.** Sporotrichosis of the hand: an urban experience. *J Hand Surg Am* 1995;20:66–70.
- 111. Schasfoort RA, Marck KW, Houtman PM.** Histoplasmosis of the wrist. *J Hand Surg [Br]* 1999;24:625–627.
- 112. Perlman R, Jubelirer RA, Schwarz J.** Histoplasmosis of the common palmar tendon sheath. *J Bone Joint Surg Am* 1972;54:676–678.
- 113. Iverson RE, Vistnes LM.** Coccidioidomycosis tenosynovitis in the hand. *J Bone Joint Surg Am* 1973;55:413–417.
- 114. Epstein MD, Segalman KA, Mulholland JH, Orbegoso CM.** Successful treatment of primary cutaneous *Aspergillus flavus* infection of the hand with oral itraconazole. *J Hand Surg Am* 1996;21:1106–1108.
- 115. Worland RG.** Cryptococcal hand infection: a case report. *J Hand Surg Am* 1994;19:609–610.
- 116. Tsai E, Louis DS.** *Cryptococcus* infection of the hand. *J Hand Surg Am* 1994;19:813–814.
- 117. Marcus JR, Hussong JW, Gonzalez C, Dumanian GA.** Risk factors in necrotizing fasciitis: a case involving *Cryptococcus neoformans*. *Ann Plast Surg* 1998;40:80–83.
- 118. al-Qattan MM, al Mazrou AM.** Mucormycosis of the upper limb. *J Hand Surg [Br]* 1996;21:261–262.
- 119. Jain JK, Markowitz A, Khilanani PV, Lauter CB.** Localized mucormycosis following intramuscular corticosteroid: case report and review of the literature. *Am J Med Sci* 1978;275:209–216.
- 120. Palmer DL, Weitzner S, Simpson JC.** Progressive gangrene of an extremity due to mucormycosis in a diabetic patient. *Diabetes* 1970;19:881–883.
- 121. al-Qattan MM.** Opportunistic mycotic infections of the upper limb: a review. *J Hand Surg [Br]* 1996;21:148–150.
- 122. Yuan RT, Cohen MJ.** *Candida albicans* tenosynovitis of the hand. *J Hand Surg Am* 1985;10:719–722.
- 123. Janes PC, Mann RJ.** Extracutaneous sporotrichosis. *J Hand Surg Am* 1987;12:441–445.
- 124. Chang AC, Destouet JM, Murphy WA.** Musculoskeletal sporotrichosis. *Skeletal Radiol* 1984;12:23–28.
- 125. Wu IB, Schwartz RA.** Herpetic whitlow. *Cutis* 2007;79:193–196.
- 126. Fowler JR.** Viral infections. *Hand Clin* 1989;5:613–627.
- 127. Gonzalez MH, Nikoleit J, Weinzeig N, Pulvirenti J.** Upper extremity infections in patients with the human immunodeficiency virus. *J Hand Surg Am* 1998;23:348–352.
- 128. Shelley WB, Shelley ED.** Farmyard pox: parapox virus infection in man. *Br J Dermatol* 1983;108:725–727.