

Case Report

An Interesting Case of Intramuscular Myxoma with Scapular Bone Lysis

Jérôme Tirefort,¹ Frank C. Kolo,² and Alexandre Lädermann^{1,3,4}

¹Division of Orthopaedics and Trauma Surgery, Department of Surgery, Geneva University Hospitals, Geneva, Switzerland

²Rive Droite Radiology Center, Geneva, Switzerland

³Faculty of Medicine, University of Geneva, Geneva, Switzerland

⁴Division of Orthopaedics and Trauma Surgery, La Tour Hospital, Geneva, Switzerland

Correspondence should be addressed to Alexandre Lädermann; alexandre.laedermann@gmail.com

Received 30 September 2016; Revised 12 December 2016; Accepted 28 December 2016; Published 17 January 2017

Academic Editor: Akio Sakamoto

Copyright © 2017 Jérôme Tirefort et al. This is an open access article distributed under the Creative Commons Attribution License, which permits unrestricted use, distribution, and reproduction in any medium, provided the original work is properly cited.

Introduction. Intramuscular myxoma is a rare benign primitive tumor of the mesenchyme founded at the skeletal muscle level; it presents itself like an unpainful, slow-growing mass. Myxomas with bone lysis are even more rare; only 7 cases have been reported in the English literature, but never at the shoulder level. *Case Presentation.* We describe an 83-year-old patient with a growing mass in the deltoid muscle with unique scapular lysis, without any symptom. Magnetic resonance imaging (MRI) and a biopsy were performed and the diagnosis of intramuscular myxoma has been retained. In front of this diagnosis of nonmalignant lesion, the decision of a simple follow-up was taken. One year after this decision, the patient was still asymptomatic. *Conclusion.* In the presence of an intramuscular growing mass with associated bone lysis, intramuscular myxoma as well as malignant tumor should be evoked. MRI has to be part of the initial radiologic appraisal but biopsy is essential to confirm the diagnosis. By consensus, the standard treatment is surgical excision but conservative treatment with simple follow-up can be an option.

1. Introduction

Myxoma is a rare benign primitive tumor of the mesenchyme [1]; it presents itself like an unpainful, slow-growing mass. It is even more rare at the skeletal muscle level [2] and is named in this case “intramuscular myxoma.” We describe here an exceptional case of intramuscular myxoma in the deltoid, which has the particularity to lyse the surrounding scapular bone. This bone lysis is almost unique; indeed, only 7 cases have been reported since the fifties, but never at the shoulder level.

2. Case Presentation

An 83-year-old woman presented with a slow-growing, palpable, painless mass in her left shoulder. She was known for auricular fibrillation, a type of hypothyroidism. The patient had no symptom; she just noticed the apparition of this mass two years earlier. At examination, no limitation in shoulder

range motion was found and a mass of about 6 cm diameter was palpable.

Conventional X-rays were normal. CT scan and magnetic resonance imaging (MRI) were performed and showed an important prescapular necrotic cystic-like mass measuring 9.5 × 6.0 cm (Figures 1–3) with scapular encroachment (bony erosion) (Figure 4). Finally, a guided biopsy under ultrasonographic control was performed. Four samples were taken in the periphery of the lesion. They showed a cystic lesion with necrotic debris in its center. At histological examination, a myxoid aspect with few cells was noticed. Some fusiform cells of little size, regular, elongated aspect nuclei were found, without hyperchromasia or mitotic activity. The myxoid matrix was abundant and loose. The lesion was not vascularized (Figures 5–7). The diagnosis of a benign tumor of myxoma type was retained. Simple follow-up was decided due to the lack of symptoms and the age of the patient. One year later, she was still asymptomatic.

3. Discussion

Intramuscular myxomas are localized in skeletal muscles; they represent a distinct subtype of myxomas and have been described for the first time in 1965 by Enzinger [1], constituting only 17% of all soft tissue myxoma cases in his study. They occur more frequently in females and usually affect patients between 40 and 70 years of age [2].

In terms of localization, extracardiac myxomas are rare, and they occur most commonly in the head and skin tissue [3]. Regarding intramuscular myxomas, they have been exceptionally reported in shoulder muscles, thighs, buttocks, or upper extremities [4]. In the present case, the intramuscular myxoma was in the deltoid muscle. Such localization has only been published three times [5–7], but never in conjunction with bone lysis. This bone lysis is in fact very rare, and some odontogenic myxomas with gnathic bone lysis have been described [8] but they presented more aggressive proliferation with cortical lysis and the worst prognostics. To the best of our knowledge, there are only seven cases of extragnathic myxomas associated with bone lysis described in the English literature [9–13].

Histologically, myxoma is a primitive tumor of the mesenchyme composed of undifferentiated stellate cells in a loose mucoid stroma with reticulin fibers; vascularization is poor but focal hypervascularity may be seen and an abundant myxoid matrix is present [14]. The tumor is characterized by the absence of a true capsule but only possessed an incomplete pseudocapsule [8]. These criteria were met in our case (Figures 5–7). The etiology of myxomas remains elusive. Some authors suggested a traumatic origin [2]. It is also possible that growth of polysaccharide-producing cells is implicated in the neoplastic process [1, 15].

Under MRI examination, the myxoma presented a cystic-like aspect partly solid with thick rim enhancement (Figures 1–3) [16]. Usually, intramuscular myxomas appear hypointense on T1-weighted sequences with a characteristic perilesional fat rind and an increased signal in the adjacent muscle on T2-weighted and fluid-sensitive MR sequences can be found [17]. Unfortunately, in our case, these criteria were not all present. But the final diagnosis is always retained on a biopsy, especially to differentiate a simple intramuscular myxoma from a malignant tumor.

The differential diagnosis of intramuscular myxomas includes also aggressive angiomyxoma, myxoid neurofibroma, myxoid liposarcoma, cellular or juxta-articular myxoma, and nodular fasciitis [18, 19]. Because focal areas of hypervascularity and hypercellularity may be present, it is sometimes difficult to differentiate a simple intramuscular myxoma from a malignant tumor. Immunostain for S-100 protein and GNAS 1 mutations can distinguish myxoid liposarcoma and low-grade myxofibrosarcoma from intramuscular myxomas, respectively [20, 21]. In the present case, the diagnosis was clear and additional investigations were not necessary.

Clinically intramuscular myxomas usually present as a painless slow-growing mass; symptoms are due to the compression of surrounding structures [1]. In case of multiple intramuscular myxomas, the Mazabraud syndrome and the

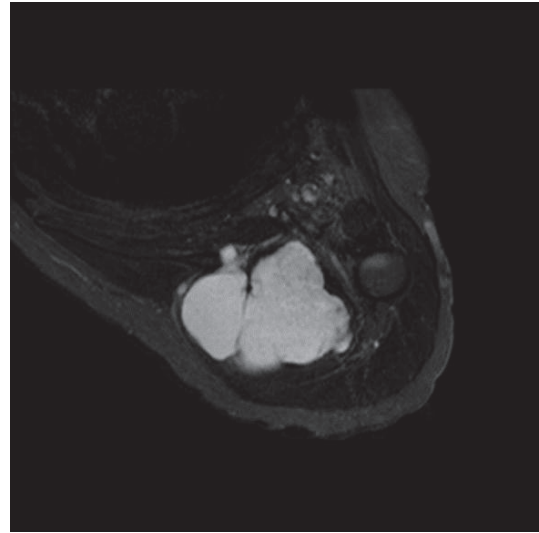


FIGURE 1: STIR and T2-weighted transverse MRI. Observe the huge cystic-like hyperintense mass growing inside the deltoid muscle and invading the scapula. The mass contains some septations but there is no apparent solid component.

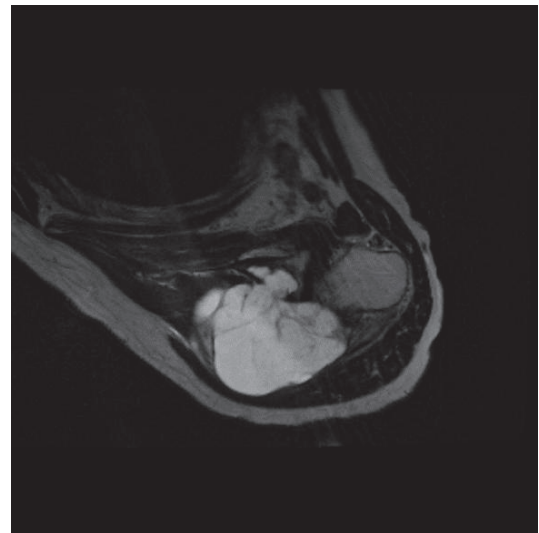


FIGURE 2: STIR and T2-weighted transverse MRI. Observe the huge cystic-like hyperintense mass growing inside the deltoid muscle and invading the scapula. The mass contains some septations but there is no apparent solid component.

McCune-Albright syndrome should be considered, but the first is associated with fibrous dysplasia and the second with polyostotic bone dysplasia, café-au-lait spots, and precocious puberty [22, 23], conditions not present in our patient.

By consensus, the recommended treatment of intramuscular myxomas is surgical excision. However, the recurrence of intramuscular myxomas is rare, restricted to isolated cases, and more commonly associated with syndromes [24–26]. In our case, the decision of a conservative treatment was taken

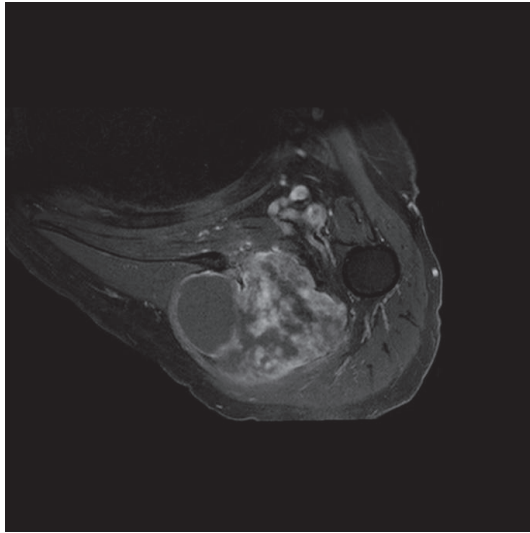


FIGURE 3: T1 transverse image with fat saturation after intravenous gadolinium injection. Note the enhancement indicating the presence of a solid component inside the mass which in consequence is a pseudocystic mass.

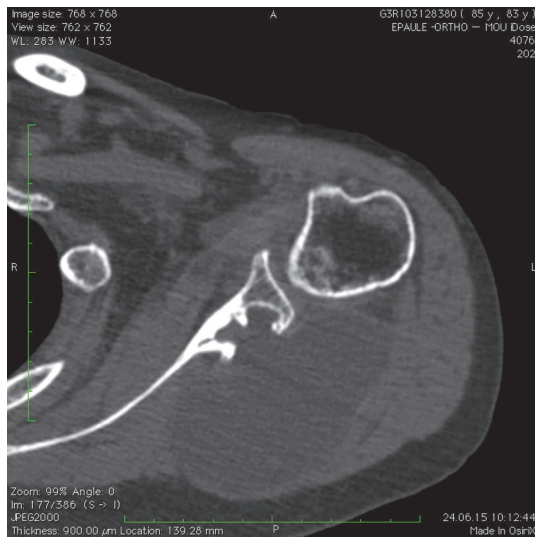


FIGURE 4: CT scan confirming the invasion of the scapula by the mass.

regarding age and lack of symptoms in our patient. One year after the biopsy, the patient was still asymptomatic.

4. Conclusion

In the presence of an intramuscular growing mass with associated bone lysis, myxoma as well as malignant neoplasm must be evoked. MRI with gadolinium injection and biopsy should be part of the initial appraisal to obtain a clear diagnosis. Surgical excision is the recommended treatment but every case should be discussed, and conservative treatment with simple follow-up can be an option for this benign tumor.

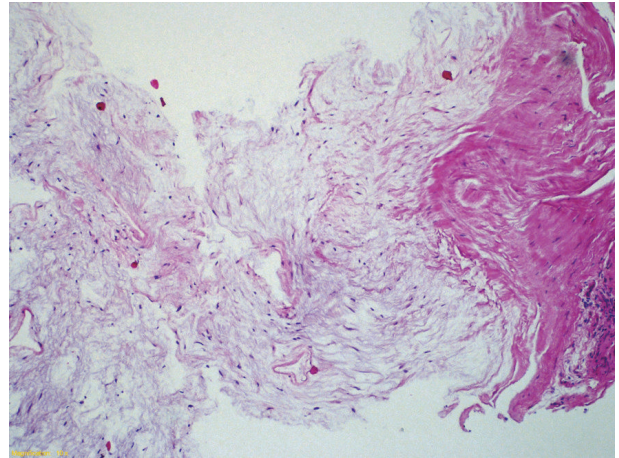


FIGURE 5: On histological examination, abundant myxoid matrix with few cells is observed. Notice the poor vascularization. Normal adjacent skeletal muscle is present on the left side of Figure 4.

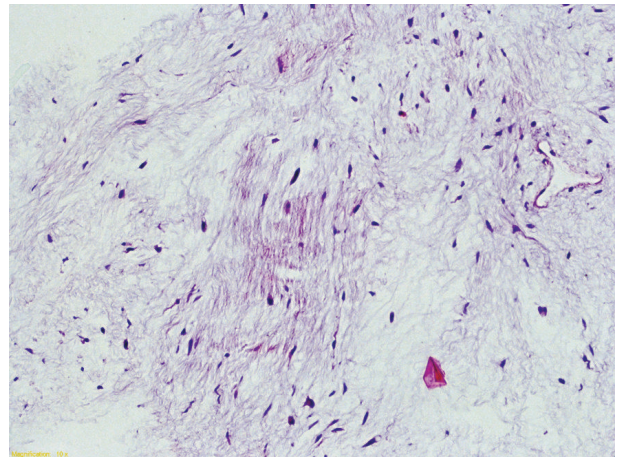


FIGURE 6: On histological examination, abundant myxoid matrix with few cells is observed. Notice the poor vascularization. Normal adjacent skeletal muscle is present on the left side of Figure 4.

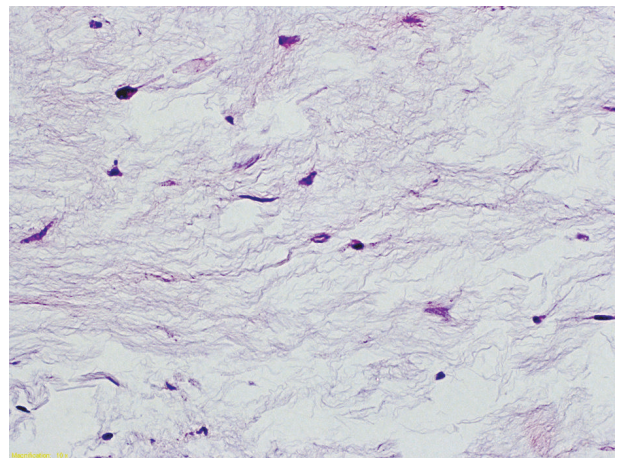


FIGURE 7: At higher magnification, fusiform cells of little size and regular shape are seen. Elongated aspect nuclei are present, without mitotic activity.

Competing Interests

The authors certify that they or any members of their immediate families have no funding or commercial associations (consultancies, stock ownership, equity interest, patent/licensing arrangements, etc.) that might pose a conflict of interests in connection with the submitted article.

References

- [1] F. M. Enzinger, "Intramuscular myxoma; a review and follow-up study of 34 cases," *American Journal of Clinical Pathology*, vol. 43, pp. 104–113, 1965.
- [2] S. Rachidi, A. J. Sood, T. Rumboldt, and T. A. Day, "Intramuscular myxoma of the paraspinal muscles: a case report and systematic review of the literature," *Oncology Letters*, vol. 11, no. 1, pp. 466–470, 2016.
- [3] A. P. Stout, "Myxoma, the tumor of primitive mesenchyme," *Annals of surgery*, vol. 127, no. 4, pp. 706–719, 1948.
- [4] P. W. Allen, "Myxoma is not a single entity: a review of the concept of myxoma," *Annals of Diagnostic Pathology*, vol. 4, no. 2, pp. 99–123, 2000.
- [5] B. Kemah, M. S. Soylemez, B. Ceyran, S. Şenol, S. Mutlu, and K. Özkan, "A case of intramuscular myxoma presenting as a swollen shoulder: a case report," *Journal of Medical Case Reports*, vol. 8, no. 1, article no. 441, 2014.
- [6] D. Costamagna, S. Erra, and R. Durando, "Intramuscular myxoma of the deltoid muscle: report of a case," *BMJ Case Reports*, vol. 2009, 2009.
- [7] S. Monga, S. K. Shukla, S. Bhargava, and L. S. Bhatnagar, "Intramuscular myxoma of deltoid—a case report," *Indian Journal of Pathology and Microbiology*, vol. 20, no. 3, pp. 189–190, 1977.
- [8] Z. Chaudhary, P. Sharma, S. Gupta, S. Mohanty, M. Naithani, and A. Jain, "Odontogenic myxoma: report of three cases and retrospective review of literature in Indian population," *Contemporary Clinical Dentistry*, vol. 6, no. 4, pp. 522–528, 2015.
- [9] W. H. Bauer and A. Harell, "Myxoma of bone," *The Journal of Bone and Joint Surgery. American Volume*, vol. 36, no. 2, pp. 263–266, 1954.
- [10] S. S. Santhanam, V. Goni, B. Saibaba, and A. Das, "Myxoma of the femur: an unusual site of origin," *BMJ Case Reports*, vol. 2015, 2015.
- [11] D. K. McClure and D. C. Dahlin, "Myxoma of bone; report of three cases," *Mayo Clinic Proceedings*, vol. 52, no. 4, pp. 249–253, 1977.
- [12] P. B. Chacha and K. K. Tan, "Periosteal myxoma of the femur. A case report," *Journal of Bone and Joint Surgery A*, vol. 54, no. 5, pp. 1091–1094, 1972.
- [13] J. A. Hill, T. A. Victor, W. J. Dawson, and J. W. Milgram, "Myxoma of the toe: a case report," *Journal of Bone and Joint Surgery A*, vol. 60, no. 1, pp. 128–130, 1978.
- [14] A. Luna, S. Martinez, and E. Bossen, "Magnetic resonance imaging of intramuscular myxoma with histological comparison and a review of the literature," *Skeletal Radiology*, vol. 34, no. 1, pp. 19–28, 2005.
- [15] D. C. R. Ireland, E. H. Soule, and J. C. Ivins, "Myxoma of somatic soft tissues: a report of 58 patients, 3 with multiple tumors and fibrous dysplasia of bone," *Mayo Clinic Proceedings*, vol. 48, no. 6, pp. 401–410, 1973.
- [16] M. D. Murphey, G. A. McRae, J. C. Fanburg-Smith, H. T. Temple, A. M. Levine, and A. J. Abouafia, "Imaging of soft-tissue myxoma with emphasis on CT and MR and comparison of radiologic and pathologic findings," *Radiology*, vol. 225, no. 1, pp. 215–224, 2002.
- [17] L. W. Bancroft, M. J. Kransdorf, D. M. Menke, M. I. O'Connor, and W. C. Foster, "Intramuscular myxoma: characteristic MR imaging features," *American Journal of Roentgenology*, vol. 178, no. 5, pp. 1255–1259, 2002.
- [18] P. Gavriilidis, G. Balis, A. Giannouli, and A. Nikolaidou, "Intramuscular myxoma of the soleus muscle: a rare tumor in an unusual location," *American Journal of Case Reports*, vol. 15, pp. 49–51, 2014.
- [19] A. Lädermann, P. Kindynis, S. Taylor et al., "Articular nodular fasciitis in the glenohumeral joint," *Skeletal Radiology*, vol. 37, no. 7, pp. 663–666, 2008.
- [20] S. Okamoto, M. Hisaoka, M. Ushijima, S. Nakahara, S. Toyoshima, and H. Hashimoto, "Activating Gs α mutation in intramuscular myxomas with and without fibrous dysplasia of bone," *Virchows Archiv*, vol. 437, no. 2, pp. 133–137, 2000.
- [21] D. Delaney, T. C. Diss, N. Presneau et al., "GNAS1 mutations occur more commonly than previously thought in intramuscular myxoma," *Modern Pathology*, vol. 22, no. 5, pp. 718–724, 2009.
- [22] L. Faivre, A. Nivelon-Chevallier, M. L. Kottler et al., "Mazabraud syndrome in two patients: clinical overlap with McCune-Albright syndrome," *American Journal of Medical Genetics*, vol. 99, no. 2, pp. 132–136, 2001.
- [23] A. Diaz, M. Danon, and J. Crawford, "McCune-Albright syndrome and disorders due to activating mutations of GNAS1," *Journal of Pediatric Endocrinology and Metabolism*, vol. 20, no. 8, pp. 853–880, 2007.
- [24] M. Szendrői, P. Rahóty, I. Antal, and J. Kiss, "Fibrous dysplasia associated with intramuscular myxoma (Mazabraud's syndrome): a long-term follow-up of three cases," *Journal of Cancer Research and Clinical Oncology*, vol. 124, no. 7, pp. 401–406, 1998.
- [25] R. L. Caballes, "Fibromyxoma of bone," *Radiology*, vol. 130, no. 1, pp. 97–99, 1979.
- [26] M. Kamiyoshihara, T. Hirai, O. Kawashima, S. Ishikawa, and Y. Morishita, "Fibromyxoma of the rib: report of a case," *Surgery Today*, vol. 29, no. 5, pp. 475–477, 1999.