

Multidisciplinary treatment of non-syndromic oligodontia

Canan Bural¹
Evren Oztas²
Sukru Ozturk³
Gulsen Bayraktar¹

ABSTRACT

Oligodontia is the agenesis of 6 or more teeth, excluding third molars. The etiology of congenital absence of teeth is believed to be rooted in heredity or developmental anomalies. The absence of teeth in patients can cause aesthetic, functional, and psychological problems, particularly if the anterior region is involved. This case report describes the multidisciplinary treatment approach toward a patient 17 years of age with non-syndromic oligodontia, with absence of 11 permanent teeth. Genetic counseling revealed non-syndromic, autosomal-recessive-linked oligodontia. The objectives of the first phase of therapy were pre-prosthetic orthodontic space opening for proper positioning of the missing teeth and correction of inter-maxillary relations, as a prerequisite for proper prosthetic restoration. The second phase of therapy was prosthetic restoration of the missing teeth and provision of occlusion with full-mouth porcelain fused to metal crowns and bridges after increasing occlusal vertical dimension by 2 mm. (Eur J Dent 2012;6:218-226)

Key words: Oligodontia; severe hypodontia; non-syndromic autosomal-recessive-linked oligodontia; prosthetic therapy; pre-prosthetic orthodontic therapy

INTRODUCTION

Agenesis of teeth is one of the most common of human developmental anomalies.¹⁻³ Hypodontia is the congenital agenesis of 5 or fewer permanent

teeth, excluding third molars; oligodontia (also called severe hypodontia^{1,4}) is the congenital agenesis of 6 or more permanent teeth, excluding third molars;^{1,5} and anodontia is the congenital agenesis of all deciduous and/or permanent teeth.⁶

The prevalence of oligodontia has been reported as 0.3%.^{1,7} It affects females more often than males, with a gender ratio of 3:2.⁸ It can be isolated or as a part of a syndrome^{2,5,6,9,10} such as ectodermal dysplasia,^{2,3,5,10} Rieger's syndrome,¹¹ oto-palato-digital syndrome,¹⁰ Witkop syndrome (tooth and nail syndrome),¹² oro-facial-digital syndrome,¹³ oculo-facial-cardio-dental syndrome^{10,14} or incontinentia pigmenti.^{10,15} When part of a syndrome, there are usually concomitant abnormalities in

- ¹ Department of Prosthodontics, Faculty of Dentistry, Istanbul University, Istanbul, TURKIYE
- ² Department of Orthodontics, Faculty of Dentistry, Istanbul University, Istanbul, TURKIYE
- ³ Department of Internal Medicine, Division of Medical Genetics, Istanbul Medical Faculty, Istanbul University, Istanbul, TURKIYE
- Corresponding author: Dr. Canan Bural
Istanbul Universitesi, Dishekimligi Fakultesi, Protetik Dis Tedavisi AD., 34093, Capa, Istanbul, TURKIYE
Tel: +90 212 4142020 int. 30256
Fax: +90 212 5253585
Email: cbural@istanbul.edu.tr

the skin, nails, eyes, ears or skeleton.^{2,10,12-15} Congenitally absent maxillary lateral incisors, maxillary second premolars, and mandibular central incisors are most often seen in oligodontia cases,³ while the agenesis of maxillary central incisors, maxillary or mandibular canines, or first permanent molars is rare.¹

In addition to the clinical finding of congenitally missing teeth, several dental and oral symptoms are frequently found in individuals with oligodontia, including reduction in size and form of teeth and alveolar processes, delayed eruption of teeth, persistent deciduous teeth, anomalies of the enamel, increased free-way space and cleft lip/palate, false diastema, and deep overbite.^{1,5,7,9} Residual teeth can vary in size, shape, and rate of development, and the permanent dentition is more affected than the primary dentition.¹⁶ Speech and masticatory functional disorders occur most frequently; however, aesthetic, physiological, and psychological problems may also arise beginning at an early age.

Treatment plans can include orthodontic space opening or closure before prosthetic therapy, using adhesive restorative techniques, removable or fixed partial dentures, implant-supported restorations, or combinations of this approaches.¹

This case report describes a multidisciplinary treatment approach toward a patient 17 years of age with non-syndromic oligodontia, with absence of 11 permanent teeth.

CASE REPORT

Pre-treatment evaluation

A female patient, 17 years of age, was referred to Istanbul University, Faculty of Dentistry, Department of Removable Prosthodontics, for unpleasant smile and replacement of missing teeth (Figure 1).

Extra-orally, frontal and profile examination revealed a facial asymmetry and a mild decrease in lower facial height, along with a flat profile. The nasolabial angle was within normal limits, and the lower lip was full and slightly protruded relative to the upper lip at closure. A deep mentolabial sulcus was present and increased activity of the mentalis muscle was visible in the skin overlying the chin upon lip closure.

Intra-oral examination revealed that missing of 11 permanent teeth were not due to extraction and were absent since childhood. The missing teeth were maxillary lateral incisors, maxillary second premolars, mandibular central incisors, mandibular right and left first and second premolars, and right second molar with bilateral cross-bite of the maxillary first molars, which were restored previously but presented with secondary caries. The third molars were clinically absent. The maxillary deciduous second molars, mandibular left deciduous second molar and mandibular deciduous central incisors were present in dental arches (Figure 2a-e).

Diagnostic records included an orthopantomogram (Figure 3a), a lateral cephalogram (Figure 3b), and study models. Orthopantomogram

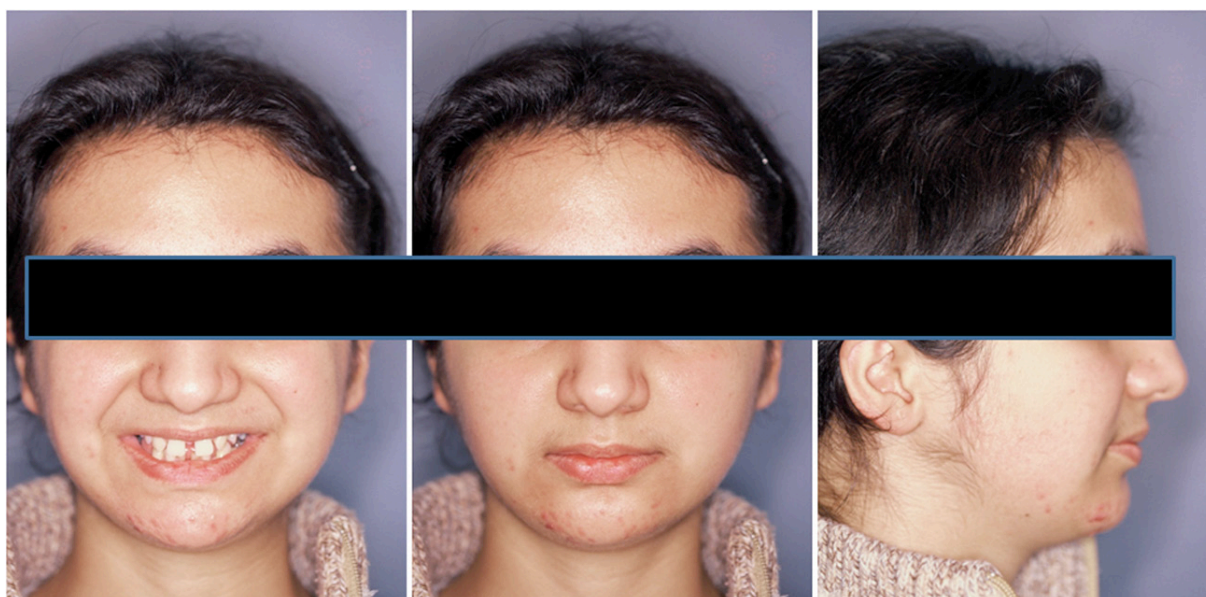

Figure 1. Extra-oral view.

showed missing maxillary lateral incisors, maxillary second premolars, mandibular central incisors, mandibular first and second premolars, right second molar, and all third molars.

The maxillary first premolars were of marked conical shape and mesiodistal diameters of the teeth crowns were reduced. Orthopantomogram also revealed that the maxillary first molars were endodontically treated.

Genetic counseling

The patient was referred to genetic counseling. The patient is the second child of 5 from a non-

consanguineous marriage (Case III:2). One of the patient's brothers (Case III:4) showed oligodontia (Figure 4). The patient's medical history consisted of a surgical operation because of imperforate hymen. The patient's neuromotor development appeared normal and there was no specific finding on physical examination to suggest any syndrome. Ophthalmic examination and skeletal X-ray indicated normal findings.

Since oligodontia is a frequent finding in ectodermal dysplasia, this syndrome was evaluated in the differential diagnosis. Sweating was normal and patient's nails and skin appeared normal,

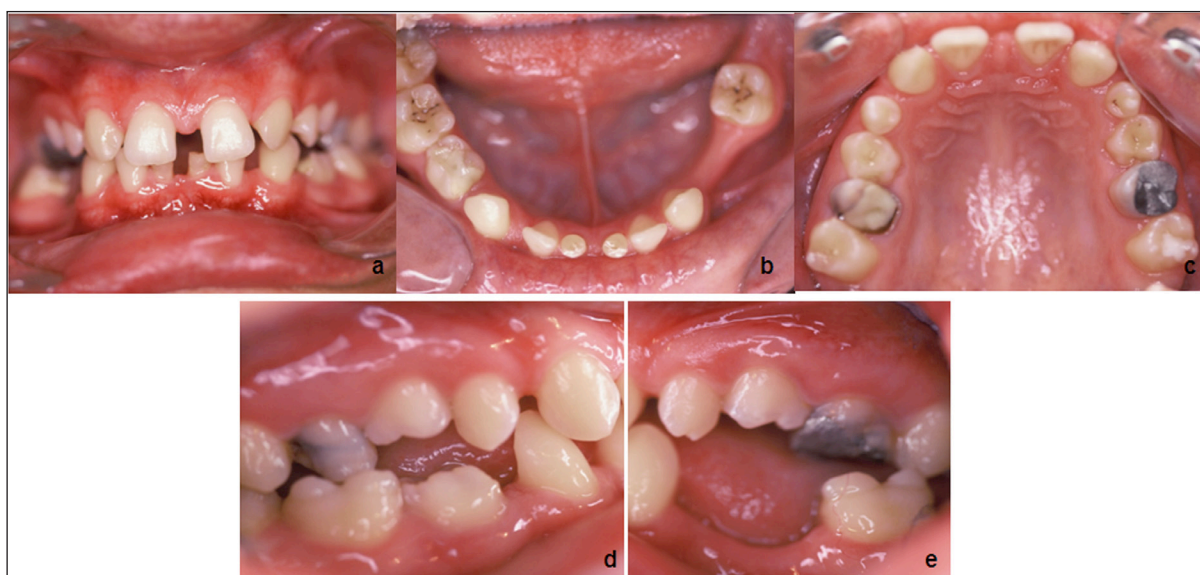


Figure 2. Intra-oral view: a) occlusal view b) maxillary arch c) mandibular arch d & e) lateral views of occlusion at premolar site.

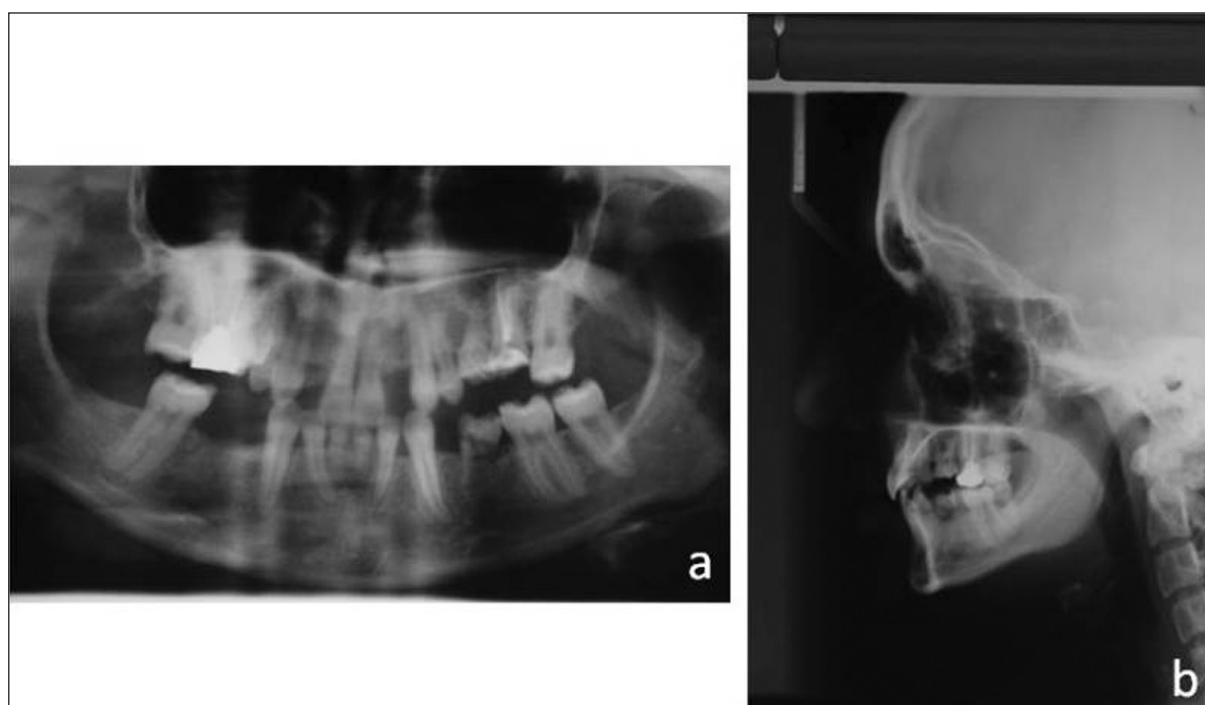


Figure 3. a) Orthopantomogram b) lateral cephalogram.

thus ectodermal dysplasia was excluded. Because of familiar missing teeth in the patient's brother, oligodontia might be autosomal-recessive-linked. In the literature, there is no reported syndrome for severe hypodontia and imperforate hymen observed in combination. Imperforate hymen is therefore considered coincident in this case.

Treatment plan

Multiple missing teeth, deep overbite, upper midline diastema of 3 mm, 50% overbite, 80% incisor display at smile, and deep mentolabial sulcus were listed as orthodontic problems. Frenulum labii was within normal limits. At rest position, freeway space was measured as 3 to 4 mm with lips closed. Lateral cephalogram showed orthognathic maxilla and mandible and Class I skeletal pattern (ANB = 1°) with normal growth pattern (SN-GoGn = 32°) (Figure 3b). The case was discussed in association with a prosthodontist.

The treatment plan comprised 2 phases. Phase I consisted of pre-prosthetic orthodontic therapy with the following objectives: 1) space opening for proper prosthetic restoration of the missing teeth, 2) correction of cross-bite while improving incisal relation and lip support. After orthodontic therapy

was completed, mandibular deciduous incisors and all remaining deciduous second molars were designated for extraction due to poor crown-to-root ratio. Phase II consisted of prosthetic therapy to provide function and aesthetics.

Treatment progress

Phase I-orthodontic therapy

Orthodontic therapy was initiated after oral prophylaxis was settled. Pre-adjusted edgewise appliance (0.022" Roth Prescription) was placed on upper and lower permanent teeth. Initial alignment used 0.014" NiTi arch wire. Spaces were consolidated on 0.017"×0.025" SS arch wire with the help of open coil springs and elastic chains. Rigid 0.019"×0.025" SS arch wire was then installed for retention. Maxillary midline diastema was closed and a necessary maxillary lateral incisor space was opened (Figure 5a-b). Lip position also improved. After retaining the achieved results (Figure 5a-e) for 3 months with night-time wearing of maxillary and mandibular Essix retainers, prosthetic therapy was initiated.

The mandibular deciduous incisors and deciduous second molars were extracted prior to initiation of prosthetic therapy.

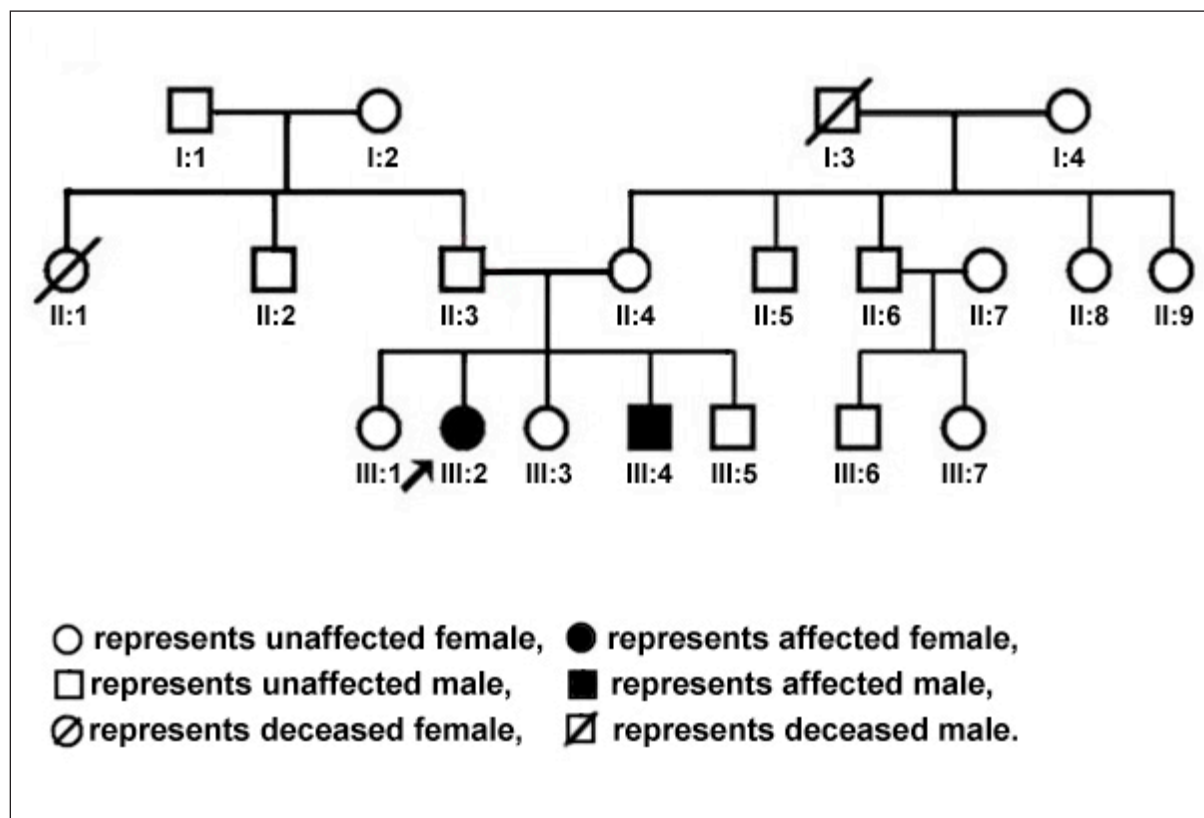


Figure 4. Case pedigree: Patient (III:2) is second child of 5 from non-consanguineous marriage (II:3-father, II:4-mother). Absence of oligodontia in previous generations and presence of oligodontia in 2 siblings (Case III:2 and III:4) suggest autosomal-recessive-linked inheritance.

Phase II—prosthetic therapy

Prosthetic therapy included replacement of missing anterior teeth and other missing teeth with full-mouth fixed restorations to improve function and aesthetics.

An endodontically treated maxillary left first molar tooth had surgical crown lengthening on the palatal side due to insufficient crown height. After 3 weeks of gingival healing, a cast nickel-chrome alloy (Heraeus, Heraenium NA, Heraeus Kulzer GmbH, Hanau, Germany), post-core restoration

was fabricated. Maxillary canines, central incisors, second premolars and molars, mandibular canines, and lateral incisors and molars were also prepared. Maxillary and mandibular impressions were made using a putty-wash technique with a condensation-type polyvinyl siloxane silicone impression material (Zetaplus putty, Oranwash L light hydrocompatible, C-silicone impression material, Zhermack Clinical, Badia Polesine, Italy). The impressions were poured using Type II dental Stone (Moldano, Heraeus Kulzer GmbH, Hanau,

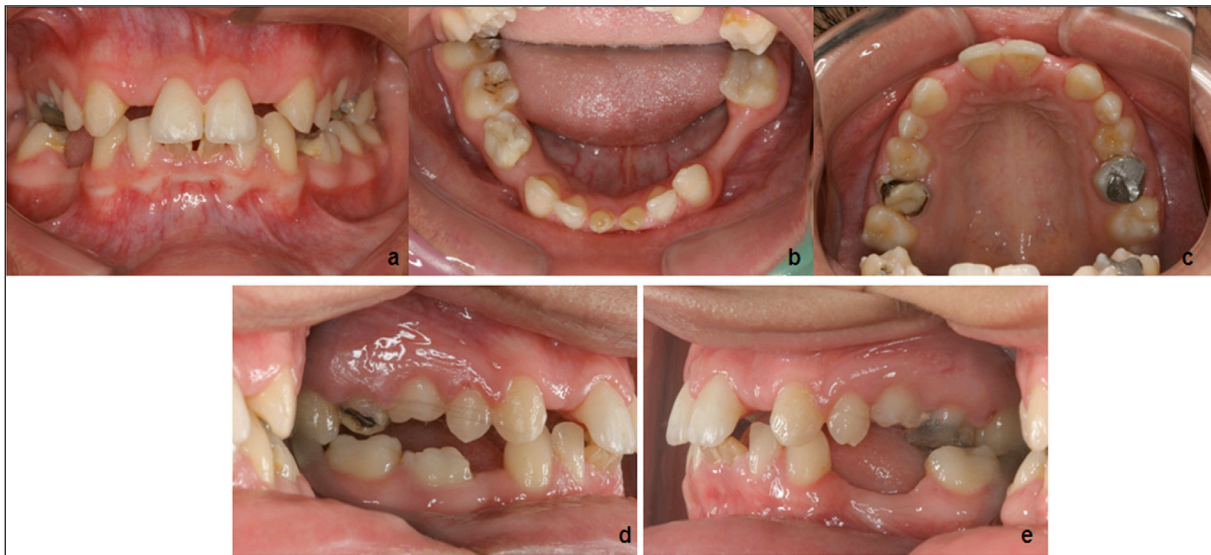

Figure 5. Orthodontic therapy completed: a & b) maxillary arch: closed diastema in central incisors and opened spaces for missing lateral incisors, c) mandibular arch, d & e) sagittal view of the occlusion.

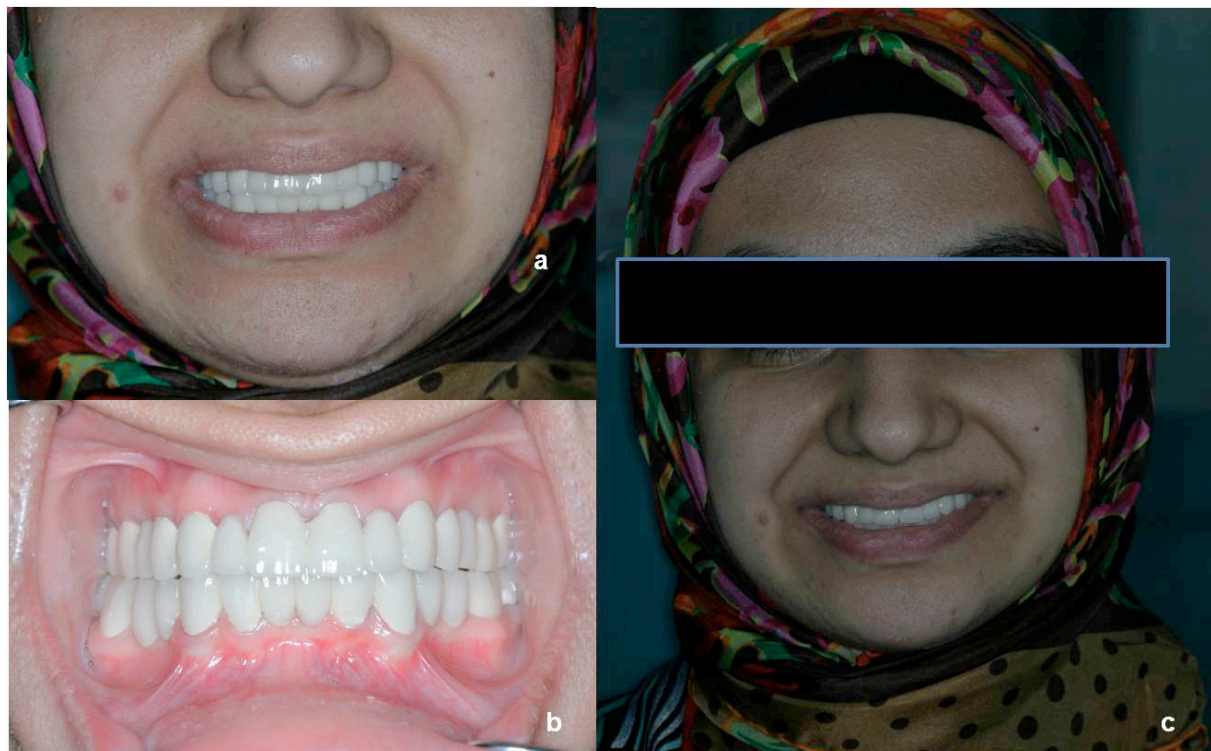

Figure 6. Prosthetic therapy completed with full-mouth restorations for maxilla and mandible: a) extra-oral view, b) intra-oral view, c) smile profile.

Germany). Casts were mounted on the articulator with 2 mm of increased occlusal vertical dimension (OVD). A 2-mm increase in OVD was decided to facilitate placement of a fixed prosthetic restoration and to improve facial aesthetics on the anterior dentition (Figure 5d–e). The mandibular cast was mounted with a silicone-based interocclusal record material (Futar D, Kettenbach GmbH, Eschenburg, Germany) using a centric relation record (CR) obtained by bilateral manipulation. Full mouth provisional restorations were fabricated at the newly established OVD. The restorations were fitted and adjusted in the mouth. After provisional cementing, restorations were maintained intra-orally for 2 months before final impressions were made. During this period, periodic recalls at 1 day and at intervals of 1 to 4 weeks were performed to evaluate the increased OVD. The patient adapted well to the newly established OVD; function, aesthetics, and speech were improved with the help of provisional restorations. For the final restorations, maxillary and mandibular impressions were made with putty wash impression technique using addition-type polyvinyl siloxane silicone impres-

sion material (Affinis heavy body, Affinis wash material, Coltene Whaledent, UK). Full-mouth porcelain fused to metal (Wiron 99, Bego, Bremen, Germany; VMK, Vita Zahnfabrik, Bad Säckingen, Germany) restorations were fabricated (Figure 6). Canine-guidance was developed to reduce lateral forces on the posterior dentition. The restorations were provisionally cemented (Provicol, Voco, Cuxhaven, Germany) and the patient was examined over 1 additional week. Facial soft-tissue appearance did not markedly change following OVD increase (Figure 7a–b). After detecting no pathological signs or symptoms in the orofacial structures, the restorations were finally cemented using polycarboxylated cement (Adhesor Carbofine, Spofa Dental, Frankfurt, Germany).

Treatment results

At the time of preparation of this report, the patient has been well functioning with her restorations for 22 months and she is pleased with the treatment outcome. The patient reported that her self-esteem and quality of life have improved.

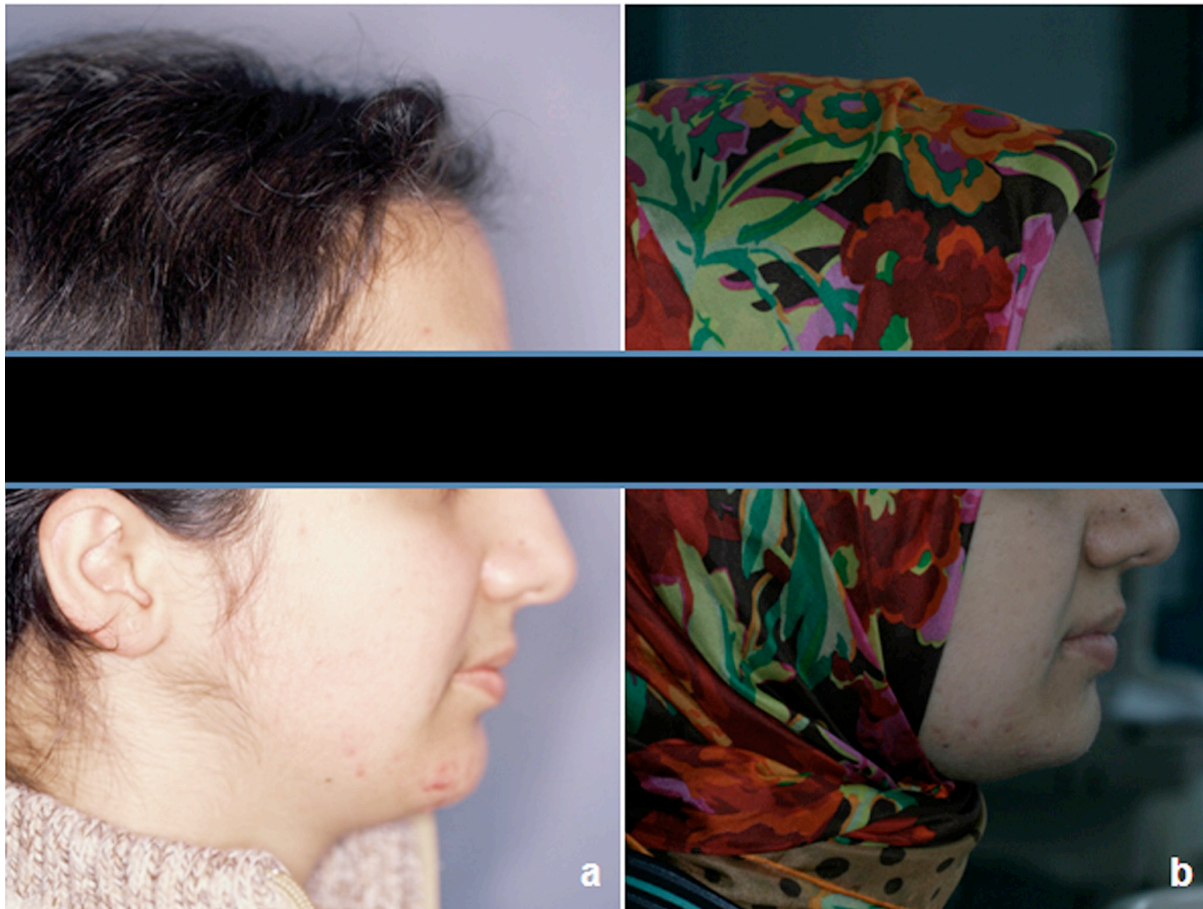

Figure 7. Facial soft-tissue profile: a) before therapy, b) after increased OVD by 2 mm.

DISCUSSION

The etiology of congenital absence of teeth is believed to be rooted in heredity or developmental anomalies.^{2,5,10} Although oligodontia is genetically conditioned, the presence of external and internal factors, such as X-ray therapy, particular medications, infectious diseases, traumas, and endocrine and intrauterine disorders, cannot be excluded. Familial tooth agenesis can occur as an isolated anomaly or as part of a genetic syndrome^{2,5,9} and is transmitted as an autosomal dominant, recessive, or X-linked condition.^{10-12,14,16-19}

Studies have shown that *MSX1* and *PAX9* genes play a role in early tooth development.^{17,18} *PAX9* plays a role in the absence of wisdom teeth in some human populations²⁰ and mutations in *MSX1* have been associated with non-syndromic cleft lip with/without cleft palate²¹ and autosomal dominant hypodontia¹¹. *MSX1*-associated oligodontia typically includes missing maxillary and mandibular second premolars and maxillary first premolar. A distinguishing feature of *MSX1*-associated oligodontia is the frequent absence of maxillary first premolars, while *PAX9*-associated oligodontia is associated with an absence of the maxillary and mandibular second molars.¹⁹

Treatment of oligodontia generally requires multidisciplinary teamwork, including an orthodontist and a prosthodontist. In some cases, a maxillofacial surgeon may also be required. Patient age plays a significant role in selecting and planning treatment. Other factors that must be evaluated include number and condition of present teeth, number of missing teeth, presence of carious teeth, condition of supporting tissues, occlusion, and inter-occlusal rest space.^{1,9,22,23}

Pre-prosthetic orthodontic therapy is frequently required for proper positioning of the teeth to achieve improved biomechanical, functional, and aesthetic results prior to final prosthetic therapy. Orthodontic therapy of patients with congenitally missing laterals is controversial with respect to whether to close spaces left by the missing lateral incisors orthodontically, or to open or maintain the spaces for fixed prosthetic replacement or dental implants. In patients with congenitally missing permanent teeth, reduced height, width, and quality of the alveolar bone can also be present. In adult patients with missing teeth and inadequate alveolar bone, when bone grafting and dental im-

plants are planned, delivery of final restorations is delayed due to the time required for osseointegration and graft maturation. Retention of the persistent deciduous teeth in oligodontia patients may help to preserve the alveolar bone during orthodontic therapy. However, attrition of the persistent teeth, especially in mandibular central incisors, can occur; this can result in over-eruption of the maxillary central incisor teeth.⁴ In the present patient, the persistent mandibular central incisors with extreme attrition were retained during orthodontic therapy to take advantage of their prevention of ridge resorption, although dental implant-supported restorations were not planned.

Congenitally missing maxillary lateral incisors are replaced via 3 main treatment modalities: canine substitution, tooth-supported restoration, and single-tooth implant. Selecting the appropriate treatment option depends on the malocclusion, the anterior relationship, specific space requirements, the degree of flattening of the facial profile, and the condition of the adjacent teeth.^{4,24,25} The small size and often conical form of the permanent teeth, together with asymmetries of the teeth and jaws,⁷ can make prosthetic treatment and acceptable aesthetic results more difficult to obtain in oligodontia cases. In the present case, for biomechanical purposes, the canines had to be used as abutment teeth under fixed partial dentures. Reasonably stable and well accepted results, i.e., no impairment to temporomandibular joint function or periodontal health, with orthodontic space closure have been reported.²⁶ Management of oligodontia patients with dental implants is difficult, because the congenital absence of teeth can result in lack of sufficient alveolar ridge for successful implant placement.^{4,22} Nevertheless, oral rehabilitation of oligodontia patients via dental implants is regarded as an efficient and successful treatment.²³ Considering the prosthetic rehabilitation with 11 missing permanent teeth, the present patient selected full-mouth, tooth-supported restorations over implant-supported restorations; this is because implant-supported restorations would require preparation of almost all the permanent teeth with crown and bridge restorations to replace the missing teeth and to restore occlusion and OVD.

Subtle visual differences in facial soft-tissue profiles have been reported when OVD is increased

by 2 to 6 mm with fixed restorations.²⁷ The facial soft-tissue appearance of the present case was not markedly changed after OVD was increased by 2 mm. The patient was well-adapted to the increased OVD and showed no signs and symptoms of temporomandibular joint disorders during the 2 months with provisional restorations.

CONCLUSION

The consequences of missing teeth are numerous and depend on the number and type of teeth missing. Speech, masticatory functional disorders, and aesthetic problems caused by disturbed growth and development of the orofacial area, can occur frequently in oligodontia cases. A multidisciplinary approach that includes orthodontic and prosthetic therapy is often necessary for dental management of young oligodontia patients. Considering the level of complexity in the management of oligodontia patients, treatment should begin with early diagnosis to prevent future functional and aesthetic problems.

REFERENCES

- Dhanrajani PJ. Hypodontia: etiology, clinical features, and management. *Quintessence Int* 2002;33:294-302.
- Gorlin RJ, Cohen M Jr, Leven L, eds. Syndromes of the head and neck. 3rd ed. New York: Oxford University Press, 1990.
- Polder BJ, Van't Hof MA, Van der Linden FP, Kuijpers-Jagtman AM. A meta-analysis of the prevalence of dental agenesis of permanent teeth. *Community Dent Oral Epidemiol* 2004;32:217-226.
- Jepson NJ, Nohl FS, Carter NE, Gillgrass TJ, Meechan JG, Hobson RS, Nunn JH. The interdisciplinary management of hypodontia: restorative dentistry. *Br Dent J* 2003;194:299-304.
- Schalk-van der Weide Y, Beemer FA, Faber JA, Bosman F. Symptomatology of patients with oligodontia. *J Oral Rehabil* 1994;21:247-261.
- Hall RK. Congenitally missing teeth—a diagnostic feature in many syndromes of the head and neck. *Int Ass Dent Child* 1983;14:69-75.
- Schalk-van der Weide Y, Steen WH, Bosman F. Distribution of missing teeth and tooth morphology in patients with oligodontia. *ASDC J Dent Child* 1992;59:133-140.
- Dermaut LR, Goeffers KR, De Smit AA. Tooth agenesis correlated with jaw relationship and crowding. *Am J Orthod Dentofac Orthop* 1986;90:204-210.
- Kotsiomiti E, Kassa D, Kapari D. Oligodontia and associated characteristics: assessment in view of prosthodontic rehabilitation. *Eur J Prosthodont Restor Dent* 2007;15:55-60.
- Bailleul-Forestier I, Berdal A, Vinckier F, de Ravel T, Fryns JP, Verloes A. The genetic basis of inherited anomalies of the teeth. Part 2: syndromes with significant dental involvement. *Eur J Med Genet* 2008;51:383-408.
- Prabhu NT, John R, Munshi AK. Rieger's syndrome: a case report. *Quintessence Int* 1997;28:749-752.
- Jumlongras D, Bei M, Stimson JM, Wang WF, DePalma SR, Seidman CE, Felbor U, Maas R, Seidman JG, Olsen BR. A nonsense mutation in MSX1 causes Witkop syndrome. *Am J Hum Genet* 2001;69:67-74.
- Gurrieri F, Franco B, Toriello H, Neri G. Oral-facial-digital syndromes: review and diagnostic guidelines. *Am J Med Genet A* 2007;143A:3314-3323.
- McGovern E, Al-Mudaffer M, McMahon C, Brosnahan D, Fleming P, Reardon W. Oculo-facio-cardio-dental syndrome in a mother and daughter. *Int J Oral Maxillofac Surg* 2006;35:1060-1062.
- Minić S, Novotny GE, Trpinac D, Obradović M. Clinical features of incontinentia pigmenti with emphasis on oral and dental abnormalities. *Clin Oral Investig* 2006;10:343-347.
- Mostowska A, Kobiela A, Trzeciak WH. Molecular basis of non-syndromic tooth agenesis: Mutations of MSX1 and PAX9 reflect their role in patterning human dentition. *Eur J Oral Sci* 2003;111:365-370.
- Mostowska A, Biedziak B, Trzeciak WH. A novel mutation in PAX9 causes familial form of molar oligodontia. *Eur J Hum Genet* 2006;14:173-179.
- Lammi L, Halonen K, Pirinen S, Thesleff I, Arte S, Nieminen P. A missense mutation in PAX9 in a family with distinct phenotype of oligodontia. *European J Hum Genet* 2003;11:866-871.
- Kim JW, Simmer JP, Lin BP, Hu JCC. Novel MSX1 Frame-shift causes autosomal-dominant oligodontia. *J Dent Res* 2006;85:267-271.
- Pereira TV, Salzano FM, Mostowska A, Trzeciak WH, Ruiz-Linares A, Chies JA, Saavedra C, Nagamachi C, Hurtado AM, Hill K, Castro-de-Guerra D, Silva-Júnior WA, Bortolini MC. Natural selection and molecular evolution in primate PAX9 gene, a major determinant of tooth development. *Proc Natl Acad Sci U S A* 2006;103:5676-5681.
- van den Boogaard MJ, Dorland M, Beemer FA, van Amstel HK. MSX1 mutation is associated with orofacial clefting and tooth agenesis in humans. *Nat Genet* 2000;24:342-343.
- Imirzalioglu P, Uckan S, Haydar SG. Surgical and prosthodontic treatment alternatives for children and adolescents with ectodermal dysplasia: a clinical report. *J Prosthet Dent* 2002;88:569-572.

23. Finnema KJ, Raghoobar GM, Meijer HJ, Vissink A. Oral rehabilitation with dental implants in oligodontia patients. *Int J Prosthodont* 2005;18:203-209.
24. Bani M, Tezkirecioglu AM, Akal N, Tuzuner T. Ectodermal dysplasia with anodontia: a report of two cases. *Eur J Dent* 2010 Apr;4:215-222.
25. Kinzer GA, Kokich VO Jr. Managing congenitally missing lateral incisors. Part II: tooth-supported restorations. *J Esthet Restor Dent* 2005;17:76-84.
26. Robertsson S, Mohlin B. The congenitally missing upper lateral incisor. A retrospective study of orthodontic space closure versus restorative treatment. *Eur J Orthod* 2000;22:697-710.
27. Gross MD, Nissan J, Ormianer Z, Dvori S, Shifman A. The effect of increasing occlusal vertical dimension on face height. *Int J Prosthodont* 2002;15:353-357.