

[CASE REPORT]

Inflammatory Myopathy Associated with Anti-mitochondrial Antibody Presenting Only with Respiratory Failure

Shintaro Fujii¹, Kazuhiro Horiuchi¹, Yuki Oshima¹, Katsuki Eguchi², Azusa Nagai²,
Ikuko Iwata², Masaaki Matsushima² and Ichiro Yabe²

Abstract:

A 56-year-old woman presenting with type II respiratory failure was transferred to our hospital. She did not exhibit muscle weakness or elevated serum myogenic enzymes, but needle electromyography revealed myogenic changes in the limb muscles, and her blood tests were positive for anti-mitochondrial antibodies (AMA). Muscle histopathological findings included immune-mediated necrotizing myopathy, so she was diagnosed with inflammatory myopathy associated with AMA. After treatment with corticosteroids and noninvasive positive pressure ventilation, her symptoms improved. If a diagnosis of type II respiratory failure is difficult, inflammatory myopathy associated with AMA should be considered as a differential diagnosis.

Key words: anti-mitochondrial antibodies, inflammatory myopathy, type II respiratory failure, immune-mediated necrotizing myopathy, immunotherapy

(Intern Med 60: 3801-3804, 2021)

(DOI: 10.2169/internalmedicine.7448-21)

Introduction

Anti-mitochondrial antibodies (AMA) are a type of serum autoantibody that are specific for primary biliary cirrhosis (PBC) but have also been linked to myositis (1, 2). It has been reported that inflammatory myopathy associated with AMA manifests as limb muscle weakness, with more prominent myocardial damage, respiratory muscle damage, and skeletal muscle atrophy than with typical myositis but a different clinical picture.

There have been no reports of cases of inflammatory myopathy associated with AMA that present with respiratory failure alone without limb muscle weakness or elevated myogenic enzymes. Therefore, we herein report the first case of inflammatory myopathy associated with AMA presenting with type II respiratory failure alone that was improved by corticosteroid therapy and noninvasive positive pressure ventilation (NPPV) therapy.

Case Report

A 56-year-old woman presenting with the type II respiratory failure was transferred to our hospital. She had never been diagnosed with any cardiac or respiratory disease and had no episodes of respiratory distress. However, she reported that she was having difficulty breathing and was admitted to the cardiology department of another hospital. She presented with CO₂ narcosis and respiratory acidosis due to excessive oxygen administration and was treated with a ventilator. After two days, her acidosis has improved, and she was weaned off of the ventilator and no longer required oxygen therapy. However, hypercapnia was prolonged. This one seemed to be due to chronic hypercapnia, for which she was being compensated. A cardiological examination did not reveal the cause, but neuromuscular disease was suspected of being involved. Therefore, she was transferred to our hospital.

She had no medical history and no family history of neuromuscular disorders. She had no history of drinking alcohol or allergies and smoked one pack per day. Her growth

¹Department of Neurology, Hakodate Municipal Hospital, Japan and ²Department of Neurology, Faculty of Medicine and Graduate School of Medicine, Hokkaido University, Japan

Received: February 28, 2021; Accepted: April 12, 2021; Advance Publication by J-STAGE: June 5, 2021

Correspondence to Dr. Shintaro Fujii, f.shintaro9164@gmail.com

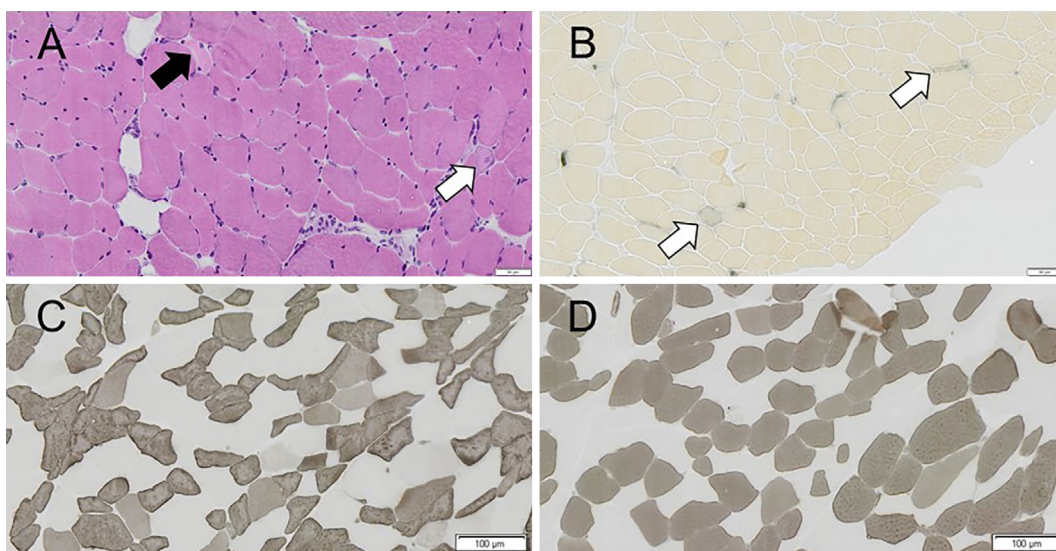


Figure 1. Microscopic findings of the muscle biopsy specimen from the left biceps brachii. On Hematoxylin and Eosin staining (A), there was no detectable inflammatory cell infiltration, but variation in fiber size and some necrotic fibers (black arrow) and regenerating fibers (white arrow) were noted. Perifascicular atrophy was not seen. On alkaline phosphatase (ALP) staining (B), there were some regenerating fibers (arrows). On ATPase pH 10.9 (C) and pH 4.3 (D), fiber type grouping was not seen. A large number of type 2C fibers (stained with C and D) were observed.

and development were normal.

She was 142.8 cm tall and weighed 34.2 kg. Upon admission, her oxygen saturation was 93% room air; other vital signs were normal. She had few symptoms of respiratory distress, but an arterial blood gas analysis showed an elevated PaCO₂ level (70.2 mmHg) and a decreased PaO₂ level (57.0 mmHg), which were signs of type II respiratory failure. Manual muscle testing of the limb and neck revealed a full range of motion. Neither muscle atrophy nor myalgia was observed. Peripheral blood tests showed a normal creatine kinase (CK) level at 60 U/L, and the aldolase level was 5.3 U/L. Serum levels of the C-reactive protein, transaminase, lactate dehydrogenase, thyroid hormone, lactic acid, pyruvic acid, angiotensin-converting enzyme, and soluble interleukin-2 receptor were within normal range. A dried blood spot test to screen for Pompe disease was negative. Anti-nuclear antibody, anti-aminoacyl tRNA synthetase (ARS) antibody, anti-Jo 1 antibody, anti-DNA antibody, anti-Smith (Sm) antibody, anti-Sjögren's-syndrome-related antigen (SS)-A antibody, anti-SS-B antibody, anti-ribonucleoprotein (RNP) antibody, anti-Scl-70 antibody, and anti-neutrophil cytoplasmic antibody were negative, but AMA (40×) and antimitochondrial antibody type 2 (AMA-M2) (233 U/mL) were positive. The anti-signal recognition particle (anti-SRP) antibody and anti-3-hydroxy 3-methylglutaryl coenzyme A reductase (anti-HMGCR) antibody were not assayed.

Body computed tomography (CT) showed mild atrophy of the paraspinal muscles but no obvious atrophy of other muscles, no bilateral hilar lymphadenopathy suggestive of sarcoidosis, and no findings of interstitial pneumonia or malignancy. Muscle magnetic resonance imaging on short TI in-

version recovery imaging of the proximal lower limbs showed no intensity changes suggestive of muscle edema or inflammation. However, needle electromyography (EMG) performed on the right biceps brachii and right rectus femoris muscles showed a myogenic pattern of low amplitude, short duration, polyphasic motor unit potentials, and preserved interference at both sites. A repetitive nerve stimulation study yielded negative results. The electrophysiological and radiological findings on the diaphragm or intercostal muscles were not assessed. Chest X-ray showed mild cardiac enlargement, but ECG showed no arrhythmia, and echocardiography showed no systolic dysfunction or asynergy. Thus, we considered there to be no active cardiopathy. Body CT showed no bilateral hilar lymphadenopathy suggestive of sarcoidosis and no findings of interstitial pneumonia or malignancy.

Although there was no muscle weakness or elevated levels of serum myogenic enzymes, needle electromyography (EMG) revealed myogenic changes in the limb muscles, and blood tests were positive for AMA. Therefore, considering the possibility of inflammatory myopathy associated with AMA as the cause of type II respiratory failure, a muscle biopsy of the left biceps brachii was performed.

A muscle biopsy examination showed no detectable inflammatory cell infiltration but did reveal variations in fiber size and necrotic and regenerating fibers. ATPase staining revealed a large number of type 2C fibers (Fig. 1). On modified Gomori trichrome (mGT) staining, no ragged-red fiber, fibers with rimmed vacuoles, or nemaline rods were seen. On cytochrome c oxidase (COX)/succinate dehydrogenase (SDH, complex II) staining, COX-negative fibers were not seen. The histopathological findings showed muscular

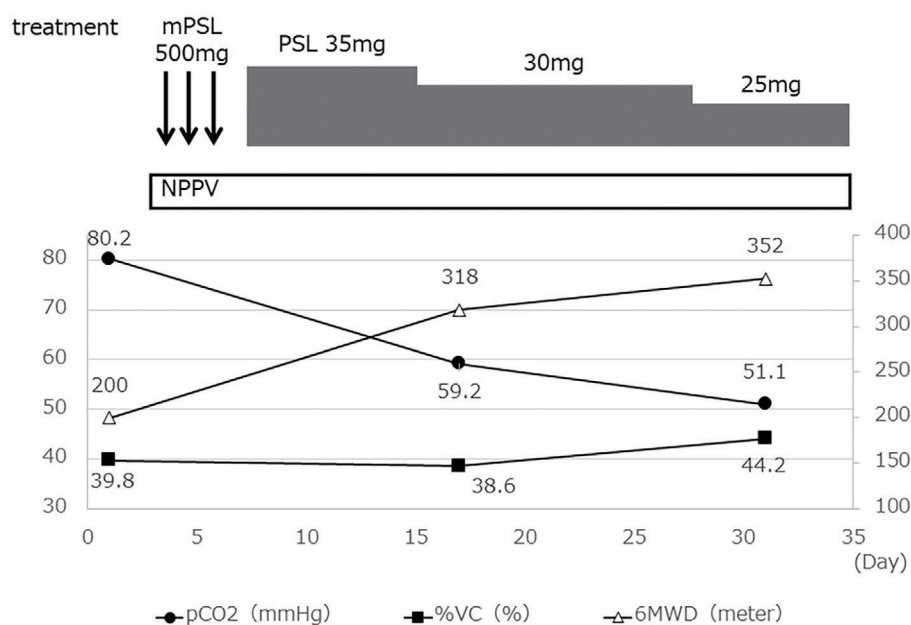


Figure 2. Clinical course of the patient. mPSL: methylprednisolone, PSL: prednisolone, NPPV: noninvasive positive pressure ventilation, %VC: % vital capacity, 6MWD: 6-minute walking distance

necrosis and regeneration, which are consistent with the findings of previous reports of inflammatory myopathy associated with AMA (3).

We considered differential diagnoses characterized by histological abnormalities of variations in fiber size and necrotic and regenerating fibers, such as mitochondrial myopathies, muscular dystrophies, and anti-SRP and anti-HMGCR myopathy. The serum levels of lactic acid and pyruvic acid were within the normal range, and neither ragged-red fiber nor COX-negative fibers were seen on muscle specimen, so it was not likely a mitochondrial myopathy (4). There was no remarkable family history, no muscle atrophy of limbs, and no other symptoms characteristic of muscular dystrophy. In anti-SRP myopathy and anti-HMGCR myopathy, there is a marked increase in serum CK levels, but in the present case, the values were within the normal range (5). Various tests were negative for other diseases, and a diagnosis of inflammatory myopathy associated with AMA was made.

Against our recommendation, the patient opted to be discharged from our hospital without treatment; however, she was readmitted 5 months later due to worsening respiratory distress with a high PaCO₂ level (80.2 mmHg) and hypoxia (92% oxygen saturation; oxygen at a flow rate of 0.5 L/min through the nasal cannula). On day 4 of hospitalization, she was treated with methylprednisolone (mPSL) at a dose of 500 mg/day×3 days. She was then treated with oral prednisolone at a dose of 35 mg/day (1 mg/kg/day) and placed on NPPV during sleep. On day 17, she no longer required oxygen therapy. On day 31, the PaCO₂ level on a blood gas analysis, % vital capacity (%VC), and 6-minute walking distance (6MWD) had improved (Fig. 2). Corticosteroid therapy and NPPV were considered to have been successful for treating respiratory failure caused by inflammatory myopathy associated with AMA, and she was discharged on day

38. The patient was seen on an outpatient basis, and prednisolone was tapered to 15 mg/day, with no worsening of symptoms.

Discussion

In cases of respiratory failure of an unknown cause, neuromuscular diseases may be the underlying cause. Therefore, it is important to perform tests to determine whether or not the cause is neuromuscular disease. There are many neuromuscular diseases that can cause respiratory failure, including central nervous system diseases (e.g., encephalitis), motor neuron diseases (e.g., amyotrophic lateral sclerosis), peripheral neuropathies (e.g., Guillain-Barre syndrome), neuromuscular junction diseases (e.g., myasthenia gravis), and muscle diseases (e.g., myositis) (6). Among these, muscle diseases are often associated with muscle weakness, myalgia, and elevated myogenic enzymes, but depending on the type of muscle disease, these signs may not be present. Inflammatory myopathy associated with AMA is such a condition where obvious signs of muscle disease are lacking.

AMA is an autoantibody specific for PBC and is positive in more than 90% of PBC cases (1). However, cases of PBC combined with inflammatory myopathy have been reported (2), and it has become clear that there are many cases for which only AMA are positive, without PBC positivity (3). The typical clinical course, pathological findings, and treatment of inflammatory myopathy associated with AMA have not been established due to a lack of accumulated cases. In a study of 212 patients with inflammatory myopathy in Japan, 24 (11.3%) were diagnosed with inflammatory myopathy associated with AMA (3). In the present study, inflammatory myopathy associated with AMA developed in a chronic course, with predominantly skeletal mus-

cle atrophy, cardiac dysfunction, and respiratory dysfunction. Our patient had no episodes of respiratory distress. However, while she had significant hypercapnia, her vital signs and consciousness were stable, suggesting that she had chronic type II respiratory failure.

Like other inflammatory myopathies, serum CK levels are commonly elevated in inflammatory myopathy associated with AMA. However, some patients diagnosed with inflammatory myopathy associated with AMA may have normal or only slightly elevated serum CK levels. Maeda et al. reported that 3 of 24 patients with inflammatory myopathy associated with AMA had serum CK levels below 200 U/L, whereas Hou et al. reported that 2 of 7 patients had normal CK levels (3, 7). In the present case, there was no increase in the serum CK level during the disease course, but this factor was not enough to rule out inflammatory myopathy associated with AMA.

The characteristics of histopathological findings in inflammatory myopathy associated with AMA have been reviewed in various studies. A variety of pathologies have been reported, including marked inflammatory cell infiltration, perifascicular atrophy, and granulomatous inflammation, but the common denominator in most cohorts is the high incidence of multiple necrotic and regenerative muscular fibers (3, 4, 7). The histopathological findings of this case showed necrotic and regenerative fibers with poorly infiltrated inflammatory lymphocytes, which are consistent with previous reports.

Our research revealed no reports of inflammatory myopathy associated with AMA with type II respiratory failure as the main symptom but without muscle weakness or elevated serum CK levels. However, inflammatory myopathy associated with AMA is more likely than other inflammatory myopathies to present with respiratory dysfunction. In addition, a muscle biopsy revealed the histopathological findings of necrosis and regeneration, while various tests were negative for other neuromuscular diseases, including immune-mediated necrotizing myopathy (IMNM), which can cause type II respiratory failure. Therefore, this case was diagnosed as inflammatory myopathy associated with AMA.

There is no established treatment for inflammatory myopathy associated with AMA, but like other inflammatory myopathies, it is commonly treated with immunotherapy. In cases of IMNM, corticosteroid monotherapy is insufficient to control the disease in most patients, so combination with other immunosuppressive agents is recommended (8). However, in cases of inflammatory myopathy associated with AMA, corticosteroid therapy (methylprednisolone pulse therapy or oral prednisolone therapy) has been selected as the first line in many cases and has been shown to improve muscle strength and normalize the CK levels (3).

Although there have been few reports on the therapeutic effects of corticosteroids on respiratory dysfunction, there

are a number of cases in which the symptoms improved with the combination of immunotherapy and respiratory support therapy (9-11). In the present case, corticosteroid therapy and NPPV only at night resulted in an improvement in the %VC, hypercapnia, and 6MWD.

In conclusion, inflammatory myopathy associated with AMA may present with respiratory failure alone. Immunotherapy and respiratory support therapy may improve symptoms, so the early diagnosis is critical for the patient's prognosis. Therefore, if the diagnosis of type II respiratory failure is difficult, this disease should be considered as a differential diagnosis.

The authors state that they have no Conflict of Interest (COI).

References

1. Van de Water J, Cooper A, Surh CD, et al. Detection of autoantibodies to recombinant mitochondrial proteins in patients with primary biliary cirrhosis. *N Engl J Med* **320**: 1377-1380, 1989.
2. Uhl GS, Baldwin JL, Arnett FC. Primary biliary cirrhosis in systemic sclerosis (scleroderma) and polymyositis. *Johns Hopkins Med J* **135**: 191-198, 1974.
3. Maeda MH, Tsuji S, Shimizu J. Inflammatory myopathies associated with anti-mitochondrial antibodies. *Brain* **135**: 1767-1777, 2012.
4. Albayda J, Khan A, Casciola-Rosen L, Corse AM, Paik JJ, Christopher-Stine L. Inflammatory myopathy associated with anti-mitochondrial antibodies: a distinct phenotype with cardiac involvement. *Semin Arthritis Rheum* **47**: 552-556, 2018.
5. Watanabe Y, Uruha A, Suzuki S, et al. Clinical features and prognosis in anti-SRP and anti-HMGCR necrotizing myopathy. *J Neurol Neurosurg Psychiatry* **87**: 1038-1044, 2016.
6. Rezaian K, Goldenberg FD, White S. Neuromuscular disorders and acute respiratory failure: diagnosis and management. *Neurol Clin* **30**: 161-185, 2012.
7. Hou Y, Liu M, Luo YB, et al. Idiopathic inflammatory myopathies with anti-mitochondrial antibodies: clinical features and treatment outcomes in a Chinese cohort. *Neuromuscul Disord* **29**: 5-13, 2019.
8. Kassardjian CD, Lennon VA, Alfugham NB, Mahler M, Milone M. Clinical features and treatment outcomes of necrotizing autoimmune myopathy. *JAMA Neurol* **72**: 996-1003, 2015.
9. Matsui K, Aizawa Y, Inoue K, Yaguchi H, Toda G. Polymyositis with marked paravertebral muscle atrophy in patients with primary biliary cirrhosis. *Rinsho Shinkeigaku* **40**: 694-700, 2000 (in Japanese, Abstract in English).
10. Kasuga K, Sato A, Kanazawa M, Kobayashi H, Tanaka K, Nishizawa M. A case with severe respiratory muscle weakness due to chronic myositis associated with PBC. *Rinsho Shinkeigaku* **44**: 280-285, 2004 (in Japanese, Abstract in English).
11. Terada J. Alveolar hypoventilation with obvious sleep disordered breathing: an analysis of three cases. *J Jpn Soc Respir Care Rehab* **27**: 294-300, 2018 (in Japanese, Abstract in English).

The Internal Medicine is an Open Access journal distributed under the Creative Commons Attribution-NonCommercial-NoDerivatives 4.0 International License. To view the details of this license, please visit (<https://creativecommons.org/licenses/by-nc-nd/4.0/>).