



Original Article

Does facet joint morphology affect the development of spondylolysis?

HAYATO ISHITANI, PhD, RPT¹⁾

¹⁾ Department of Rehabilitation, Funabashi Orthopaedic Hospital Nishifuna Clinic: 2-351 Katsushika-cyo Funabashi-shi, Chiba 273-0032, Japan

Abstract. [Purpose] This study aimed to clarify the contribution of the morphology of the facet joint in spondylolysis. [Participants and Methods] A total of 68 junior athletes with lower back pain were evaluated. They were classified into groups B (bilateral spondylolysis), U (unilateral spondylolysis), and C (without spondylolysis). The same observer measured the sagittal orientation of the L4/L5 and L5/S1 facet joint angles from the axial sections, using computed tomography. Facet joint angles were statistically compared for differences among groups B, UL (the spondylolysis side in group U), UN (the normal side in group U), and C. [Results] The L4/L5 facet joint angles were significantly more coronally oriented in groups B and UL than in group C, while the L5/S1 facet joint angles showed no significant differences among the four groups. [Conclusion] The results of this study suggest that a more coronal orientation of the L4/L5 facet joint may increase the point loading through the L5 pars interarticularis in extension and rotation. Therefore, if the L4/L5 facet joint is more coronally orientated, the patient may be at the risk of spondylolysis. This observation may aid in predicting patients with increased possibility of developing spondylolysis.

Key words: Spondylolysis, Facet joint, Junior athlete

(This article was submitted Jun. 25, 2020, and was accepted Sep. 9, 2020)

INTRODUCTION

Many junior athletes have experienced low back pain¹⁾. Lumbar spondylolysis is one of the most common sports injuries in adolescents. Lumbar spondylolysis is a defect in the pars interarticularis separating the vertebral arch into the ventral and dorsal parts, either unilaterally or bilaterally^{2, 3)}. Strong heredity, repeated trauma and stress, and lumbar hyperlordosis are possible causative factors⁴⁻⁶⁾. Masharawi reported that individuals with more frontally oriented facets in the lower lumbar vertebrae incorporated with facet tropism are at a greater risk of developing isthmic spondylolysis at L5⁷⁾. However, only few reports have described the morphology of the facet joint associated with unilateral and bilateral spondylolysis in adolescents. This study was performed to clarify whether the morphology of the facet joint in adolescents contributes to the development of unilateral and bilateral spondylolysis.

PARTICIPANTS AND METHODS

The participants were 68 junior athletes who visited the Funabashi Orthopedic Hospital because of lower back pain between April 2012 and June 2014. They underwent computed tomography (CT) and magnetic resonance imaging (MRI) scans. Patients with multivertebral spondylolysis and previous lumbar surgery were excluded. They were classified into three groups according to CT and MRI findings as follows: group B, those with L5 bilateral spondylolysis; group U, those with L5 unilateral spondylolysis; and group C, those without spondylolysis and whose low back pain eventually disappeared. Group B included 22 athletes (18 males and 4 females); group U, 27 athletes (21 males and 6 females); and group C, 19 athletes (13

Corresponding author. Hayato Ishitani (E-mail: hayato2020@gmail.com)

©2020 The Society of Physical Therapy Science. Published by IPEC Inc.



This is an open-access article distributed under the terms of the Creative Commons Attribution Non-Commercial No Derivatives (by-nc-nd) License. (CC-BY-NC-ND 4.0: <https://creativecommons.org/licenses/by-nc-nd/4.0/>)

males and 6 females). The mean ages in groups B, U, and C were 14.1 ± 2.3 , 14.7 ± 2.1 , and 15.0 ± 1.5 years, respectively, showing no significant differences between the groups (Table 1).

By using multislice CT, the same observer measured the sagittal orientation of the L4/L5 and L5/S1 facet joint angles from the axial sections (Figs. 1 and 2). The central slice between the vertebra within the 15 lines of 1.0-mm thickness parallel to the inferior endplate of the vertebra was selected (Fig. 1). For measurements of the facet joint angle (Fig. 2), a sagittal line was drawn perpendicular to the vertebral body from the spinous process (line 1). Subsequently, a line was drawn through the anterior and posterior ends of the inferior articular process (line 2). Finally, the facet joint angle (angle 3) formed by the two lines (lines 1 and 2) was measured. Group U was reclassified into two groups, one with a spondylolysis side (UL group) and the other with a normal side (UN group; Fig. 3). In groups B and C, no significant differences were found between the left and right measurements; therefore, all the measurements are presented as a mean.

Table 1. Participants' data

	Group B	Group U	Group C
n	22	27	19
Age (years)	14.1 ± 2.3	14.7 ± 2.1	15.0 ± 1.5
Male	18	21	13
Female	4	6	6

No significant differences were found among the three groups.

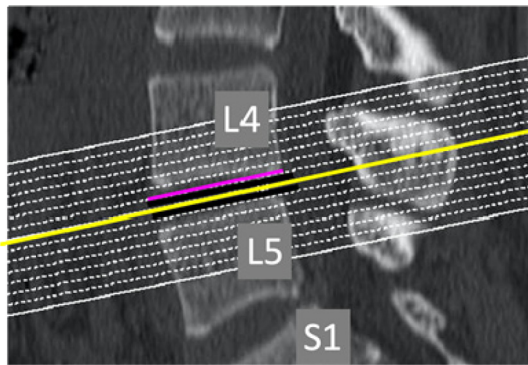


Fig. 1. Slice selection.

The central slice between the vertebra within the 15 lines of 1.0-mm thickness parallel to the inferior endplate of the vertebra is selected.

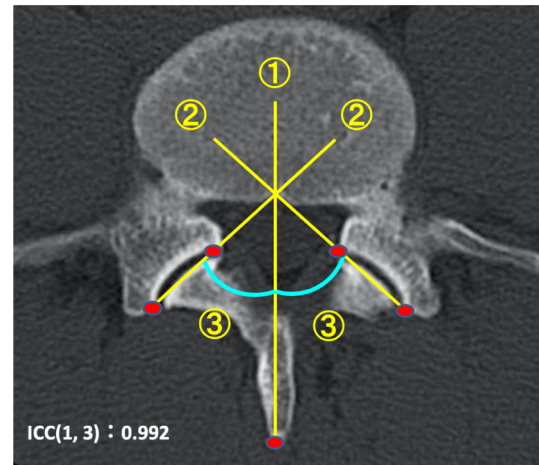


Fig. 2. Measurement of the facet joint angle.

1) The sagittal line is drawn perpendicular to the vertebral body from the spinous process. 2) A line is drawn through the anterior and posterior ends of the inferior articular process. 3) The facet joint angle formed by lines 1) and 2) is measured.

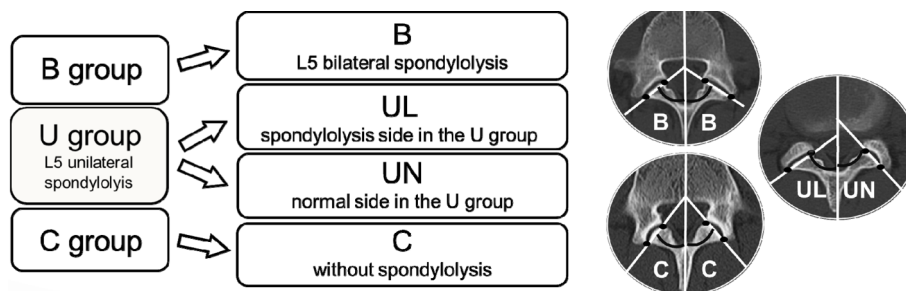


Fig. 3. Reclassification.

In groups B and C, no significant differences were found between the left and right measurements; therefore, all the measurements are presented as mean values.

The facet joint angles at both the L4/5 and L5/S1 levels were statistically compared using a Tukey test for differences among groups B, UL, UN, and C. A p value of <0.05 was considered statistically significant. For statistical analysis, R (version 3.6.2)⁸⁾ was used. All the patients were informed about the use of the data and underwent a CT examination with their consent. In addition, because this was a retrospective study and carefully conducted with the identity of participants anonymized, it did not require the approval of the ethics committee.

RESULTS

The mean L4/L5 facet joint angles in groups B, UL, UN, and C were $53.1^\circ \pm 7.5^\circ$, $52.7^\circ \pm 7.9^\circ$, $51.4^\circ \pm 8.5^\circ$, and $46.2^\circ \pm 7.8^\circ$, respectively (Table 2). The L4/L5 facet joint angles were significantly more coronally orientated in groups B and UL than in group C ($p < 0.05$). However, no significant differences in L4/L5 facet joint angle were found between groups B and UL, B and UN, UL and UN, and UN and C. The mean L5/S1 facet joint angles in groups B, UL, UN, and C were $50.6^\circ \pm 8.0^\circ$, $54.5^\circ \pm 10.1^\circ$, $53.3^\circ \pm 9.4^\circ$, and $51.5^\circ \pm 9.9^\circ$, respectively (Table 2). No significant differences in L5/S1 facet joint angle were found among groups B, UL, UN, and C.

DISCUSSION

Several reports have described the morphology of the facet joint in spondylolysis. Previous studies that used radiographic images reported that in patients with spondylolysis, the distance of the facet joint in the lower lumbar was reduced^{9, 10)}. This shows an increased load on the pars interarticularis. Eroglu et al.¹¹⁾ measured angles of the facet joints in patients with bilateral spondylolysis using CT. The orientations of the facet joints in the bilateral spondylolysis group were significantly different from those in the control group. The authors reported that asymmetry of the facet joints was a causative factor of spondylolysis. Rankine et al.¹²⁾ performed measurements using the software installed in the scanner and reported that the facet joint angles of 38 patients aged 10 to 37 years were significantly more coronally orientated on the spondylolysis side than in the intact pars at both levels of the L4/5 and L5/S1. Furthermore, they suggested that a facet joint of a more coronal orientation is likely to increase the stress on the vertebral arch during lumbar hyperextension. Meanwhile, this study targeted adolescent junior athletes with unilateral and bilateral spondylolysis and performed measurements without software. All the measurements were repeated three times, and the facet joint angles were averaged by the same observer. A strength of the measurement method used in this study is that it enables measurement of the angle of the facet joint surface accurately by manually marking the irregularities of the facet joint, which is difficult with software. The L4/L5 facet joint angle was significantly more coronally orientated in groups B and UL than in group C. Therefore, a more coronal orientation of the L4/L5 facet joint is likely to increase the stress on the vertebral arch of L5 during trunk extension movements as compared with a normal orientation (Fig. 4). Therefore, if an adolescent junior athlete has a coronally orientated L4/L5 facet joint, unilateral spondylolysis at L5 may occur on the more coronally oriented side, and the other coronally oriented side may be at risk of L5 spondylolysis. This might aid in identifying which adolescent junior athletes are more likely to develop spondylolysis, which would lead to the prevention of the development of spondylolysis by limiting athletic activity in patients with more coronally oriented facet joints. The present author believes that early examinations are important for the prevention of spondylolysis in adolescence.

Funding and Conflict of interest

The author has no conflict of interest to disclose.

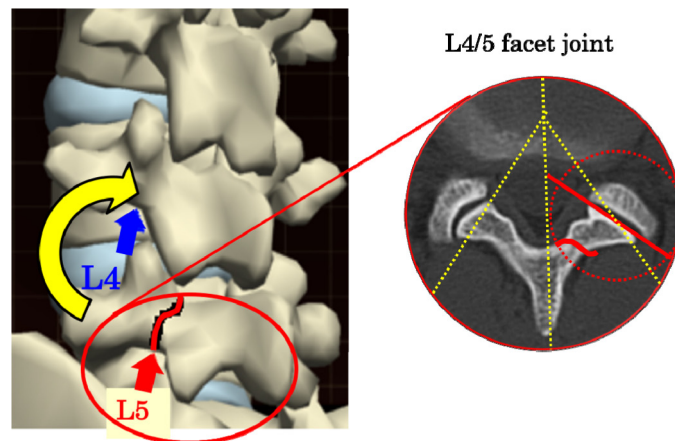
ACKNOWLEDGMENTS

My sincere gratitude goes to all the athletes who cooperated in conducting this research. I also thank Editage (www.editage.com) for the English language editing.

Table 2. Facet joint angles

	B	UL	UN	C
L4/L5 facet joint angle	$53.1^\circ \pm 7.5^\circ$ ^a	$52.7^\circ \pm 7.9^\circ$ ^a	$51.4^\circ \pm 8.5^\circ$	$46.2^\circ \pm 7.8^\circ$ ^a
L5/S1 facet joint angle	$50.6^\circ \pm 8.0^\circ$	$54.5^\circ \pm 10.1^\circ$	$53.3^\circ \pm 9.4^\circ$	$51.5^\circ \pm 9.9^\circ$

^aThe L4/L5 facet joint angles were significantly more coronally orientated in groups B and UL than in group C ($p < 0.05$). No significant differences in L5/S1 facet joint angle were found among groups B, UL, UN, and C.



Partially modified the figure by "teamLabBody ·3D Motion Human Anatomy", <https://www.teamlabbody.com/>

Fig. 4. Morphological mechanism of load on the L5 pars interarticularis. A more coronal orientation of the L4/L5 facet joint is likely to increase the point loading through the L5 pars interarticularis during trunk extension movements as compared with a normal orientation.

REFERENCES

- 1) Calvo-Muñoz I, Gómez-Conesa A, Sánchez-Meca J: Prevalence of low back pain in children and adolescents: a meta-analysis. *BMC Pediatr*, 2013, 13: 14. [[Medline](#)] [[CrossRef](#)]
- 2) Merbs CF: Incomplete spondylolysis and healing. A study of ancient Canadian Eskimo skeletons. *Spine*, 1995, 20: 2328–2334. [[Medline](#)] [[CrossRef](#)]
- 3) Standaert CJ, Herring SA: Spondylolysis: a critical review. *Br J Sports Med*, 2000, 34: 415–422. [[Medline](#)] [[CrossRef](#)]
- 4) Wiltse LL, Widell EH Jr, Jackson DW: Fatigue fracture: the basic lesion is isthmic spondylolisthesis. *J Bone Joint Surg Am*, 1975, 57: 17–22. [[Medline](#)] [[Cross-Ref](#)]
- 5) Ward CV, Latimer B: Human evolution and the development of spondylolysis. *Spine*, 2005, 30: 1808–1814. [[Medline](#)] [[CrossRef](#)]
- 6) Labelle H, Roussouly P, Berthonnaud E, et al.: Spondylolisthesis, pelvic incidence, and spinopelvic balance: a correlation study. *Spine*, 2004, 29: 2049–2054. [[Medline](#)] [[CrossRef](#)]
- 7) Masharawi YM, Alperovitch-Najenson D, Steinberg N, et al.: Lumbar facet orientation in spondylolysis: a skeletal study. *Spine*, 2007, 32: E176–E180. [[Medline](#)] [[CrossRef](#)]
- 8) Ihaka R, Gentleman R: A language for data analysis and graphics. *J Comput Graph Stat*, 1996, 5: 299–314.
- 9) Zehnder SW, Ward CV, Crow AJ, et al.: Radiographic assessment of lumbar facet distance spacing and pediatric spondylolysis. *Spine*, 2009, 34: 285–290. [[Medline](#)] [[CrossRef](#)]
- 10) Ward CV, Latimer B, Alander DH, et al.: Radiographic assessment of lumbar facet distance spacing and spondylolysis. *Spine*, 2007, 32: E85–E88. [[Medline](#)] [[CrossRef](#)]
- 11) Eroğlu A, Sarı E, Cüce F, et al.: The investigation of the role of the facet joint angle in the development of L5–S1 spondylolysis in young men. *Turk J Phys Med Rehabil*, 2017, 63: 253–258. [[Medline](#)] [[CrossRef](#)]
- 12) Rankine JJ, Dickson RA: Unilateral spondylolysis and the presence of facet joint tropism. *Spine*, 2010, 35: E1111–E1114. [[Medline](#)] [[CrossRef](#)]