

Video available on:
www.e-tjo.org

Access this article online

Quick Response Code:



Website:
www.e-tjo.org

DOI:
10.4103/tjo.tjo_13_20

Perfluorocarbon liquid-assisted inverted inner limiting membrane-flap for large macular hole after recurrent rhegmatogenous retinal detachment

Luigi Sborgia¹, Alfredo Niro^{2*}, Francesco D'Oria¹, Giancarlo Sborgia¹,
Alessandra Sborgia², Claudio Furino¹, Gianluigi Giuliani¹, Luisa Micelli Ferrari¹,
Francesco Boscia¹, Nicola Recchimurzo¹, Giovanni Alessio¹

Abstract:

A 45-year-old Caucasian myopic woman with a severe vision impairment (20/320) in the left eye due to a macula-off rhegmatogenous retinal detachment (RRD) underwent vitrectomy with silicone oil tamponade followed by an inferior relaxing retinectomy with heavy silicone oil tamponade during the second procedure for recurrence of RRD due to proliferative vitreoretinopathy. Four weeks after the second surgery, visual acuity was 20/200 and the patient complained metamorphopsia in the same eye due to a large full-thickness macular hole. A perfluorocarbon liquid-assisted inverted inner limiting membrane-flap technique was performed. Visual acuity improved to 20/80 after closing of macular hole and partial recovery of outer retinal layers at 3 months from the last surgery.

Keywords:

Inverted inner limiting membrane-flap, large macular hole, perfluorocarbon liquid, proliferative vitreoretinopathy, rhegmatogenous retinal detachment

Introduction

The development of a full-thickness macular hole (FTMH) after vitrectomy for rhegmatogenous retinal detachment (RRD) repair is a rare occurrence. FTMH occurrence after vitrectomy for RRD may be associated with epiretinal membrane (ERM), macular-off RRD, recurrent RRD, and high myopia.^[1-3] These macular holes appear to be different from idiopathic macular holes in terms of etiology, visual, and anatomical outcomes.

Although successful closure of those holes, in the particular large macular hole (LMH), has been reported using traditional inner limiting membrane (ILM) peeling, the visual outcome is usually poor.^[4] Several papers

have suggested that an inverted ILM flap technique may be better for the treatment of LMHs considering morphologic and functional outcomes.^[5,6] However, a spontaneous retroversion of the ILM flap can occur frequently in up to 14%–20% of cases during the fluid-air exchange, leading to a surgical failure.^[7,8] We present the surgical management of FTMH occurred after a recurrent RRD due to proliferative vitreoretinopathy (PVR) in a myopic eye using perfluorocarbon liquid (PFCL)-assisted inverted ILM flap technique.

Case Report

A 45-year-old Caucasian woman presented to our department with a 1-week history of decreased vision in the left eye. Myopic refractive status with an axial length of

This is an open access journal, and articles are distributed under the terms of the Creative Commons Attribution-NonCommercial-ShareAlike 4.0 License, which allows others to remix, tweak, and build upon the work non-commercially, as long as appropriate credit is given and the new creations are licensed under the identical terms.

For reprints contact: WKHLRPMedknow_reprints@wolterskluwer.com

How to cite this article: Sborgia L, Niro A, D'Oria F, Sborgia G, Sborgia A, Furino C, *et al.* Perfluorocarbon liquid-assisted inverted inner limiting membrane-flap for large macular hole after recurrent rhegmatogenous retinal detachment. Taiwan J Ophthalmol 2021;11:193-6.

¹Department of Medical Science, Neuroscience and Sense Organs, Eye Clinic, Bari, Italy, ²Eye Clinic, Hospital "S. G. Moscati", ASL TA, Taranto, Italy

*Address for correspondence:

Dr. Alfredo Niro,
Via per Martina Franca,
74010 Statte, Taranto,
Italy.
E-mail: alfred.nir@tiscali.it

Submission: 09-12-2019
Accepted: 23-02-2020
Published: 27-05-2020

26.8 mm was recorded. Visual acuity was 20/320. Intraocular pressure was 13 mmHg. A slit-lamp evaluation revealed mild cataract. Funduscopy revealed a RRD involving the macular site, as showed by optical coherence tomography (OCT), [Figure 1] with proliferative vitreous retinopathy (PVR) grade B, and retinal tears at 3-5-6 and 12 O'clock.

Phacoemulsification and intraocular lens implantation were performed to allow an adequate vitreous base shaving. After core vitrectomy and induction of posterior vitreous detachment (PVD), peripheral vitrectomy was performed. After a fluid-air exchange, silicone oil 1000 centistokes was used as tamponade. The patient was instructed to adopt a facedown position. Visual acuity improved to 20/200 after 4 weeks.

At 7-week follow-up the patient developed an inferior recurrent retinal detachment with PVR grade C and visual acuity was limited to 20/250. The patient underwent 25-gauge silicone oil extraction and a vitrector-assisted relaxing retinotomy. After PFCL-air exchange and endolaser were performed, a heavy silicone oil was used.

Four weeks after the surgery, visual acuity was 20/200 and the patient complained metamorphopsia. OCT revealed a large FTMH [Figure 2] with the peripheral retina reattached. Hence, the patient underwent a silicon oil extraction and using a 25G blunt cannula, the bubble of PFCL was precisely delivered at the site of FTMH. After ILM staining, the inverted ILM flap technique was performed. Fovea-sparing ILM peeling was performed, preserving a ring-shaped ILM island around the hole edges. ILM outside the parafoveal area was peeled to the arcade. The ILM around the hole was then partially detached. The ILM-flap attached at the edge of the hole was inverted to cover the hole and the PFCL-air exchange was performed [Figure 3]. Then, short-acting gas (SF₆) at 24% was injected. [Video 1] available at the link:

<https://drive.google.com/file/d/1ae2h72QDPwD4gC80vRT4TD81eawek7uX/view?usp=sharings>

The patient was instructed to remain in the prone position for 3 days after the surgery. At 1-month follow-up, OCT showed ILM-flap filling the hole [Figure 4]. At 2-month follow-up, OCT showed a completely closed FTMH with partial recovery of the outer retinal layers [Figure 5]. Visual acuity improved to 20/80 at 3 months after the last surgery.

Discussion

The incidence of FTMH following RRD repair using different techniques has been reported to be between 0.24 and 1.9%.^[4,9,10] More than 50% of those cases were affected by macula-off RRD and high myopia.^[1] At the same time, the use of heavy silicone oil tamponade could be associated with ERM formation, ocular inflammation, and cystoid macular edema^[11] that could be involved in macular hole occurrence. Macular cystoid degeneration was proposed as a subtle break of ILM resulted in hydration of the fovea in RRD. Following the reattachment of the macula, the edematous retina was then stretched and weakened, leading to FTMH.^[10] Byon *et al.* assumed previous PVD and macula-off RRD causing fragility of the foveal tissue and following phagocytosis of damaged foveal tissue result in macular hole formation.^[12] It is not known whether PVR may play a role in subsequent FTMH after recurrent RRD. The PVR may have contributed to the residual tractional forces following vitrectomy for RRD repair that may have been responsible for macular hole formation. It is plausible that the presence of ERMs related to PVR induces additional tangential forces, which may play a role in the occurrence of FTMH after RRD, and their removal increases the success of hole closure.^[13] However, in a recent and unique randomized clinical trial, which was conducted by Eissa *et al.*^[14] and enrolled

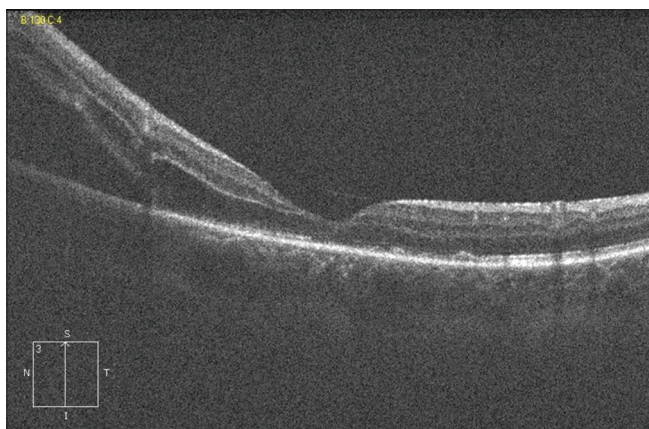


Figure 1: Optical coherence tomography showed a retinal detachment involving the macular site

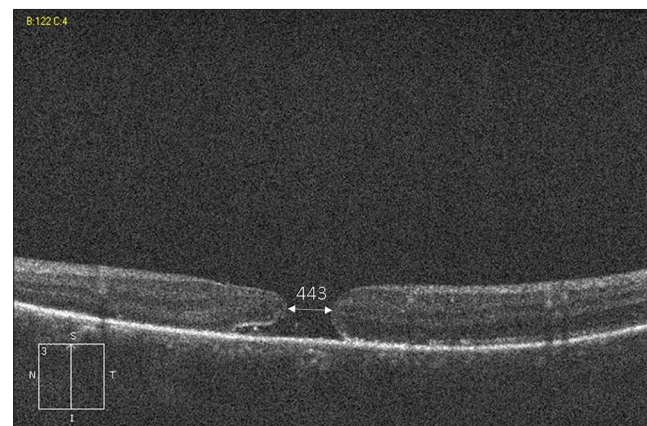


Figure 2: Optical coherence tomography showed a large full-thickness macular hole (minimum diameter, 443 μ m) with round edges and minimal subretinal fluid. An epiretinal membrane can be seen

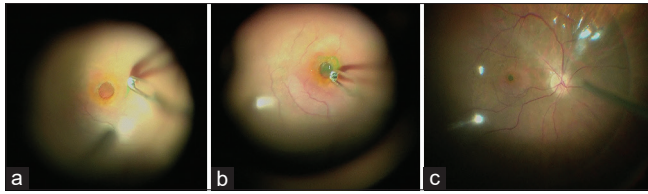


Figure 3: (a) Fovea-sparing inner limiting membrane peeling was performed, preserving a ring-shaped inner limiting membrane island around the hole edges. The inner limiting membrane around the hole was then partially detached. (b) The inner limiting membrane -flap attached at the edge of the hole was inverted to cover the hole. (c) Then perfluorocarbon liquid was removed and an air exchange was performed

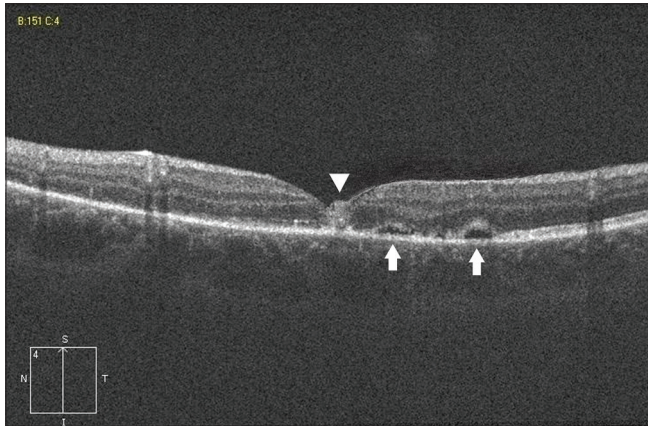


Figure 4: Optical coherence tomography scan showed the inverted inner limiting membrane -flap filling the hole with a hyperreflective tissue (arrowhead), and two small subretinal detachments at the parafoveal site (arrows)

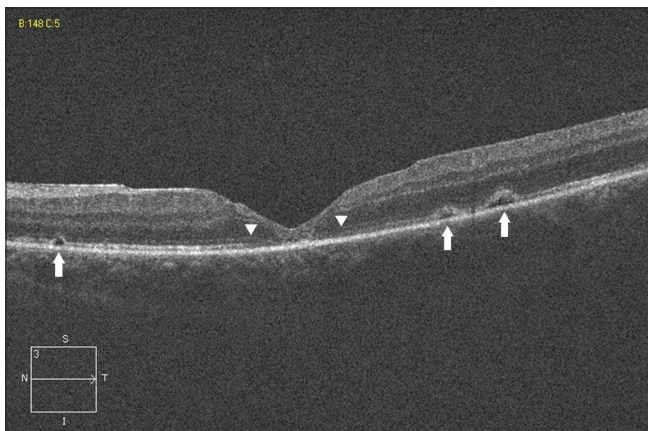


Figure 5: Optical coherence tomography scan passing through the macula showed a completely closed macular hole with a V shape pattern and a thin fovea centralis. Partial restoration of outer retinal layers can be seen (arrowheads). Small subretinal detachments at the parafoveal site were shown (arrows)

only uncomplicated macula-off RRD cases, ILM peeling, although prevented ERM, it resulted in poorer visual outcome, and might be reserved only for complicated cases. ILM peeling in myopic eyes with FTMH after recurrent RRD may be more challenging than in idiopathic macular hole because of the friability of the ILM and possible iatrogenic trauma during previous vitrectomies. ILM peeling may remove the scaffold for cellular proliferation, eliminate any traction components

and increase the flexibility of the retina to facilitate the closure of the hole. However, in myopic eyes, the ILM could appear thin, sticky, and strongly adhered to the retinal surface. Hence, the ILM peeling results difficult and dangerous with a higher risk of iatrogenic retinal breaks and the extension of ILM peeling is a matter of controversy.^[15] Thus, a smaller ILM peeling might be more respectful of the integrity of the inner retinal layers.^[16] On the other hand, a wider peeling might be useful to reduce the complex tractional forces in the myopic retina. Macula-off RRD followed by a large FTMH occurrence could lead to a poor visual prognosis because of progressive outer retinal layers loss. The influence of ILM-flap over the hole on functional recovery is not yet well understood. Indeed, the flap working as a scaffold and basement membrane for tissue proliferation should provide an environment to instruct the photoreceptors to assume the correct position during the reconstruction process and finally to improve the postoperative visual acuity.^[7] Inverted ILM flap technique is the gold standard for LMH surgery, also in myopic eyes, since it may induce glial cell proliferation, resulting in the macular hole filling with proliferating cells that enhance closure.^[7] We covered the hole with a multiple-layers flap using the spared ILM around the edges. To date, there are no significant differences in hole closure rate and outer retinal layers reconstitution between monolayer inverted flap technique and other approaches that may create a multiple-layers flap using the spared ILM surrounding the hole. Takai *et al.*, analyzing the safety and efficacy of a single-layer flap technique, speculated that gradual foveal deformation after MH closure might occur in the cases of MHs associated with ERMs, as in this case, due to cell repopulation on the unpeeled ILM around the edges of the hole.^[17] A monolayer flap covering the hole seemed to promote regular glial cells proliferation. Differently, a multiple-layers flap filling the hole may ostacolate outer retinal layers restoration.^[18] However, our OCT findings, as previously observed,^[18-20] suggest that the process of gliosis may be characterized by the early appearance of a hyperreflective material and/or ILM in the MH that gradually diminishes and finally becomes insignificant with the closing of the hole, the smoothing of the foveal profile and the partial restoration of the outer retinal layers. So, these processes could occur regardless that a single-layer or multiple-layers inverted ILM-flap was performed. Good visual outcome could be explained by the integrity of the detached photoreceptor layer in the perifoveal area at the edges of the hole, and by the partial recovery of outer retinal layers at the foveal site. For ILM-flap manipulation and positioning, different techniques have been described to prevent the flap dislocation during the fluid-air exchange or in the postoperative period. These techniques include the use of PFCL that delivered at the site of the hole may be necessary during the surgery in these eyes to secure the

flap in position until the air-gas tamponade exchange is applied.^[18-20] In our opinion, the efficacy of this technique could be related to perform the fluid-air exchange slowly to avoid the displacement of the PFCL bubble and take few minutes so that the liquid evaporates completely at the end of the fluid-air exchange. Hence, in a rare case of large FTMH occurred after recurrent RRD previously involving the macular site, inverted ILM flap technique assisted by PFCL might further anatomical success and visual acuity recovery.

Declaration of patient consent

The authors certify that they have obtained all appropriate patient consent forms. In the form, the patient has given her consent for her images and other clinical information to be reported in the journal. The patient understands that her name and initials will not be published and due efforts will be made to conceal their identity, but anonymity cannot be guaranteed.

Financial support and sponsorship

Nil.

Conflicts of interest

The authors declare that there are no conflicts of interests of this paper.

References

1. Medina CA, Ortiz AG, Relhan N, Smiddy WE, Townsend JH, Flynn HW Jr. Macular hole after pars Plana vitrectomy for rhegmatogenous retinal detachment. *Retina* 2017;37:1065-72.
2. Khurana RN, Wykoff CC, Bansal AS, Akiyama K, Palmer JD, Chen E, *et al.* The association of epiretinal membrane with macular hole formation after rhegmatogenous retinal detachment repair. *Retina* 2017;37:1073-8.
3. Fabian ID, Moisseiev E, Moisseiev J, Moroz I, Barak A, Alhalel A. Macular hole after vitrectomy for primary rhegmatogenous retinal detachment. *Retina* 2012;32:511-9.
4. Garcia-Arumi J, Boixadera A, Martinez-Castillo V, Zapata MA, Fonollosa A, Corcostegui B. Macular holes after rhegmatogenous retinal detachment repair: Surgical management and functional outcome. *Retina* 2011;31:1777-82.
5. Manasa S, Kakkar P, Kumar A, Chandra P, Kumar V, Ravani R. Comparative evaluation of standard ILM peel with inverted ILM flap technique in large macular holes: A prospective, randomized study. *Ophthalmic Surg Lasers Imaging Retina* 2018;49:236-40.
6. Kannan NB, Kohli P, Parida H, Adenuga OO, Ramasamy K. Comparative study of inverted internal limiting membrane (ILM) flap and ILM peeling technique in large macular holes: A randomized-control trial. *BMC Ophthalmol* 2018;18:177.
7. Michalewska Z, Michalewski J, Adelman RA, Nawrocki J. Inverted internal limiting membrane flap technique for large macular holes. *Ophthalmology* 2010;117:2018-25.
8. Kuriyama S, Hayashi H, Jingami Y, Kuramoto N, Akita J, Matsumoto M. Efficacy of inverted internal limiting membrane flap technique for the treatment of macular hole in high myopia. *Am J Ophthalmol* 2013;156:125-310.
9. Lee SH, Park KH, Kim JH, Heo JW, Yu HG, Yu YS, *et al.* Secondary macular hole formation after vitrectomy. *Retina* 2010;30:1072-7.
10. Schlenker MB, Lam WC, Devenyi RG, Kertes PJ. Understanding macular holes that develop after repair of retinal detachment. *Can J Ophthalmol* 2012;47:435-41.
11. Heimann H, Stappler T, Wong D. Heavy tamponade 1: A review of indications, use, and complication. *Eye* 2008;22:1342-59.
12. Byon IS, Kwon HJ, Park GH, Park SW, Lee JE. Macular hole formation in rhegmatogenous retinal detachment after scleral buckling. *Korean J Ophthalmol* 2014;28:364-72.
13. Yoshida M, Kishi S. Pathogenesis of macular hole recurrence and its prevention by internal limiting membrane peeling. *Retina* 2007;27:169-73.
14. Eissa MG, Abdelhakim MA, Macky TA, Khafagy MM, Mortada HA. Functional and structural outcomes of ILM peeling in uncomplicated macula-off RRD using microperimetry en-face OCT. *Graefes Arch Clin Exp Ophthalmol* 2018;256:249-57.
15. Balducci N, Morara M, Veronese C, Torrazza C, Pichi F, Ciardella AP. Retinal nerve fiber layer thickness modification after internal limiting membrane peeling. *Retina* 2014;34:655-63.
16. Steel DH, Chen Y, Latimer J, White K, Avery PJ. Does internal limiting membrane peeling size matter? *J Vitreo Retinal Dis* 2017;1:27-33.
17. Takai Y, Tanito M, Sugihara K, Ohira A. The role of single-layered flap in temporal inverted internal limiting membrane flap technique for macular holes: Pros and cons. *J Ophthalmol* 2019;2019:5737083.
18. Gilhotra MK, Park KH, Park SW, Byon IS, Lee JE. Perfluoro-n-octane-assisted single-layered inverted internal limiting membrane flap technique for macular hole surgery. *Retina* 2014;34:1905-10.
19. Park SW, Pak KY, Park KH, Kim KH, Byon IS, Lee JE. Perfluoro-n-octane assisted free internal limiting membrane flap technique for recurrent macular hole. *Retina* 2015;35:2652-6.
20. Pak KY, Park JY, Park SW, Byon IS, Lee JE. Efficacy of the perfluoro-n-octane-assisted single-layered inverted internal limiting membrane flap technique for large macular holes. *Ophthalmologica* 2017;238:133-8.