

# Chronic and Recurrent Rectus Femoris Central Tendon Ruptures in Athletes



## Clinical Picture, MRI Findings, and Results of Surgical Treatment

Lasse Lempainen,<sup>\*†</sup> MD, PhD, Jussi Kosola,<sup>†</sup> MD, PhD, Xavier Valle,<sup>‡</sup> MD, Jordi Puigdellivol,<sup>‡</sup> MD, Juha Ranne,<sup>†</sup> MD, PhD, Sakari Orava,<sup>†</sup> MD, PhD, and Ricard Pruna,<sup>‡</sup> MD, PhD

*Investigation performed at the Sports Trauma Research Unit, Hospital Mehiläinen NEO, Turku, Finland*

**Background:** Severe rectus femoris central tendon rupture is an uncommon sports-related injury. Most rectus femoris central tendon injuries can be treated by nonoperative means, but some tend to reinjure, resulting in chronic symptoms. Physicians treating athletes with rectus femoris injuries should be aware of this clinical condition and know that surgical treatment could be beneficial to the athlete if the rectus femoris central tendon rupture becomes chronic.

**Purpose:** To describe the clinical picture, magnetic resonance imaging (MRI) findings, and surgical treatment results of rectus femoris central tendon injuries.

**Study Design:** Case series; Level of evidence, 4.

**Methods:** This study included 12 patients who underwent successful repair of recurrent rectus femoris central tendon rupture. Presurgical MRI scans were obtained and compared with the surgical findings. The time of return to play was recorded, and the outcome of surgical treatment was evaluated with validated Subjective Patient Outcome for Return to Sports (SPORTS) criteria: good = full return to preinjury level of sports without any symptoms; moderate = return to preinjury level of sports with some residual symptoms (mild discomfort during sports); and poor = did not return to preinjury level of sports.

**Results:** Overall, 10 patients had a good outcome (83%), and 2 had a moderate outcome (17%). All athletes included in the study were able to return to sport at their preinjury levels 2.5 to 4 months postoperatively. Presurgical MRI scans correlated well with the surgical findings.

**Conclusion:** The surgical treatment of rectus femoris central tendon rupture seems to be a good option in chronic and recurrent cases. After surgery and successful rehabilitation, the athlete is expected to continue sports at the preinjury level.

**Keywords:** rectus femoris; central tendon rupture; surgical treatment; sports injury; soccer

Most rectus femoris injuries are strains or contusions and treated through nonoperative means with good results.<sup>10,13</sup> However, there are also surgical indications for severe rectus femoris injuries. According to recently published studies, complete proximal rectus femoris avulsions and complete midsubstance muscle ruptures often need surgical treatment, especially when they occur in high-performance athletes.<sup>10,12,15</sup>

Muscle tissue injuries usually heal well and without complications.<sup>13</sup> If the injury also affects tendon tissue, the healing process can be more demanding and require more

time.<sup>4</sup> The tendon tissue has poorer biology to regenerate from injury; therefore, this needs to be taken into account when the return to play of an athlete is being decided. If a reinjury occurs during the healing process of the central tendon, then the outcome in nonoperative treatment can be poor.<sup>4,5</sup> Rectus femoris muscle has a near complete intramuscular structure extending throughout the entire length of the muscle belly.<sup>4</sup> This structure has been introduced as a central tendon of rectus femoris,<sup>4</sup> and it can be seen by imaging such as sonography and magnetic resonance imaging (MRI).<sup>1,4</sup> Injuries involving the central tendon structure tend to be more severe than typical muscle strains involving only muscle tissue.<sup>1,4,5</sup>

While more information has been recently published about the surgical treatment of biceps femoris central

The Orthopaedic Journal of Sports Medicine, 9(2), 2325967120984486

DOI: 10.1177/2325967120984486

© The Author(s) 2021

This open-access article is published and distributed under the Creative Commons Attribution - NonCommercial - No Derivatives License (<https://creativecommons.org/licenses/by-nc-nd/4.0/>), which permits the noncommercial use, distribution, and reproduction of the article in any medium, provided the original author and source are credited. You may not alter, transform, or build upon this article without the permission of the Author(s). For article reuse guidelines, please visit SAGE's website at <http://www.sagepub.com/journals-permissions>.

tendon injury, there is scarce information in the literature regarding rectus femoris central tendon injuries.<sup>1,4,5,11</sup> The main goals of this study are to increase the knowledge of this special rectus femoris injury type and present the results of surgical treatment in rectus femoris central tendon ruptures. The clinical picture of rectus femoris central tendon injury, typical MRI findings, and surgical technique are clarified as well.

## METHODS

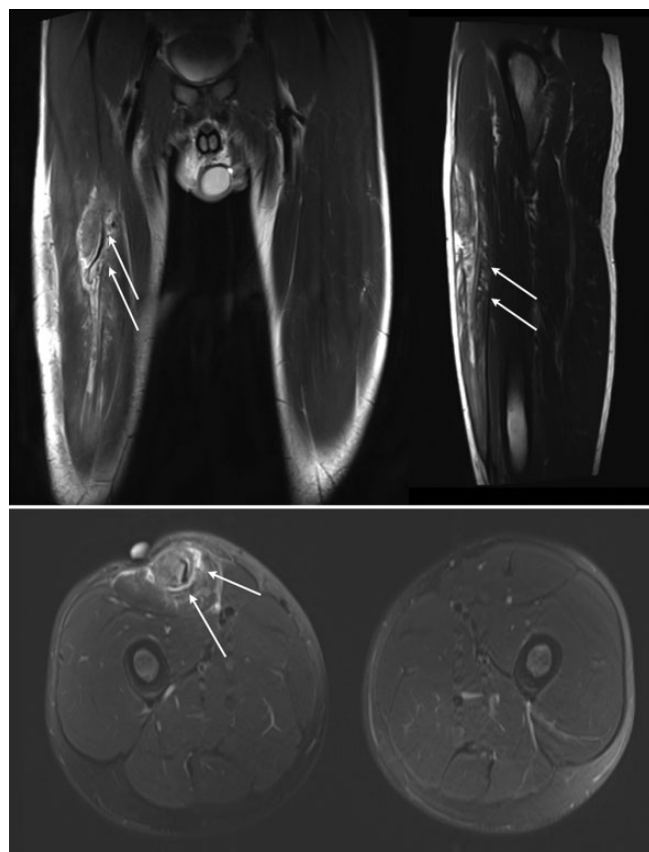
This study was approved by the investigational review board of our institution, and we followed ethical standards according to the guidelines for sport and exercise science research.<sup>8</sup> In the years 2016 to 2019, a total of 12 competitive and professional athletes were surgically treated at our hospital for rectus femoris central tendon rupture. Most were referred to our center from other hospitals and soccer teams from abroad after the failure of nonoperative treatments.

The indications for surgery were injured rectus femoris central tendon seen on MRI scans (Figures 1 and 2) with prolonged chronic symptoms (career disability >4 months): blunt/sharp pain, discomfort, ache, and tightness while performing sports. The mechanism of injury was shooting the ball (soccer, dominant foot) or a similar eccentric strong contraction. Clinical examination showed pain and often palpable hard prominence at the injured area, which was provoked by performing knee extension against resistance. The central tendon injury was typically located at the upper part of the middle third of the anterior thigh. Outcomes were evaluated per the Subjective Patient Outcome for Return to Sports (SPORTS) criteria<sup>2,3</sup> (Table 1).

The athletes who underwent surgery were monitored postoperatively by their team doctors and physical therapists or at our outpatient clinic. During the first 3 to 4 months, there were monthly routine visits. After that, visits were scheduled only as they were necessary. Additional long-term follow-ups were scheduled for study purposes. All patients were monitored for at least 12 months. At the most recent follow-up, the patients were asked about possible symptoms (pain, weakness, and stiffness), overall satisfaction, and their return to preinjury level of sport performance.

## Surgical Technique

The illustration of the surgical technique is shown in Figure 3. The patient was placed in a supine position for the surgery. A vertical incision was made over the injured area, and a fasciotomy was then made in the line of the skin



**Figure 1.** Magnetic resonance images of chronic rectus femoris central tendon rupture of an 18-year-old soccer player. (Arrows indicate the ruptured area.)

incision. If the lateral femoral cutaneous nerve was identified at the operative area, it was carefully liberated and bluntly shifted away from the injury site. The ruptured central rectus femoris tendon was identified inside the rectus femoris muscle. The injured tendon structure was repaired so that the tendon continuity and the optimal length inside the muscle were restored. However, it is important to avoid excessive tightness of the central tendon during the repair. The appropriate tension was determined by manual palpation and restoring the tendon anatomy similarly, such as the tendon diameter and width of the healthy central tendon parts located proximally and distally of the injured area. If the surgical finding was a fibrotic and tight scarred central tendon, the excessive scar was removed, and the injured tendon was repaired and released with a gliding Z-plasty and sutures (No. 3-0 or 0 polydioxanone absorbable sutures; Ethicon). The wound

\*Address correspondence to Lasse Lempainen, MD, PhD, [www.finnorthopaedics.com](http://www.finnorthopaedics.com), Turku, Finland (email: [lasse.lempainen@utu.fi](mailto:lasse.lempainen@utu.fi)).

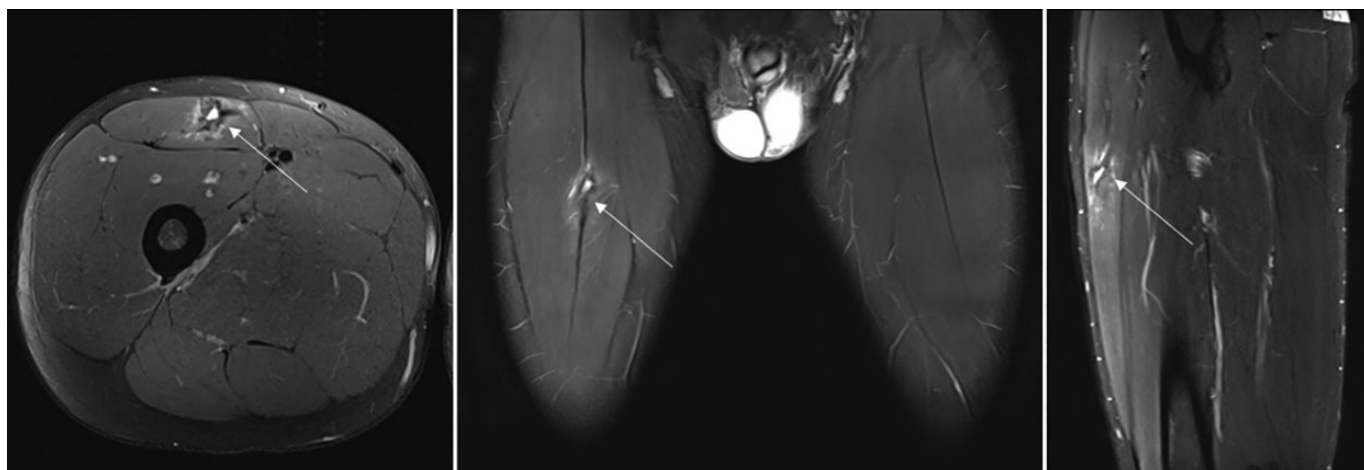
<sup>†</sup>Sports Trauma Research Unit, Hospital Mehiläinen NEO, Turku, Finland.

<sup>‡</sup>FC Barcelona, Medical Services, FIFA Center of Excellence, Barcelona, Spain.

Final revision submitted July 12, 2020; accepted August 31, 2020.

The authors declared that there are no conflicts of interest in the authorship and publication of this contribution. AOSSM checks author disclosures against the Open Payments Database (OPD). AOSSM has not conducted an independent investigation on the OPD and disclaims any liability or responsibility relating thereto.

Ethical approval for this study was obtained from Hospital Mehiläinen NEO.



**Figure 2.** Magnetic resonance image of recurrent rectus femoris central tendon rupture (white arrow). Axial view demonstrates a bull's-eye sign and the discontinuity of the central tendon.

**TABLE 1**  
SPORTS Score<sup>2a</sup>

SPORTS Score	Category	Definition	Evaluation of Athletic Performance
10	Unlimited effort, unlimited performance, no pain	Perform same sport at same level of effort and performance as before onset of impairment and with no pain	Good
9	Unlimited effort, unlimited performance, some pain	Perform same sport at same level of effort and performance as before onset of impairment but with pain	Moderate
6	Unlimited effort, limited performance	Perform same sport at same level of effort but reduced performance level vs before onset of impairment	Poor
3	Limited effort, limited performance	Perform same sport but at reduced levels of effort and performance vs before onset of impairment	Poor
0	Disabled	Unable to return to same sport	Poor

<sup>a</sup>SPORTS, Subjective Patient Outcome for Return to Sports.

was irrigated. Subcutaneous tissues were closed with absorbable sutures while the skin closure was made with nonabsorbable suture. This Z-plasty technique is demonstrated by schematic drawings in an earlier study dealing

with recurrent biceps femoris central tendon ruptures.<sup>11</sup> An active stretching program to the operated anterior thigh was avoided for 2 to 3 weeks to allow the repaired area to heal properly. No hip or knee braces were used, and the patient was allowed immediate mobilization with weight-bearing as tolerated with crutches.

### Postoperative Rehabilitation

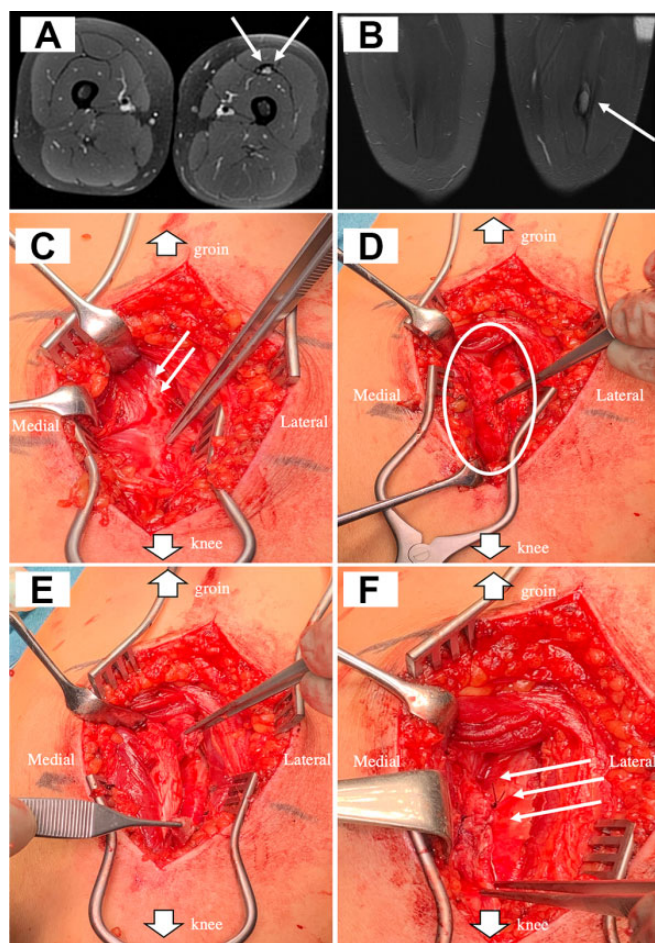
Table 2 shows the stages of postoperative rehabilitation and the timeline on which the athletes progressed to the level of preinjury performance. No brace or orthoses were used. Limitations to knee flexion are recommended for the first 4 weeks to avoid excessive stretching and tension of the repaired area. This step-by-step progressive plan to return to play was performed individually per patient and supervised by lower extremity physical therapists.

### RESULTS

Of the 12 patients, 10 (83%) had good results, and in only 2 (17%) patients was the result graded moderate (Table 3). All athletes returned to their preinjury levels of sports within 2.5 to 4 months.

The median age of surgically treated patients was 24.5 years (range, 18-29 years), and the time to undergo surgery after the primary injury was 7 months (range, 4-12 months). Of 12 patients, 10 (83%) were soccer players. In some cases, the long period between the primary injury and surgery did not prevent the athlete's return to sports afterward. MRI findings correlated well with the surgical findings (Figures 1 and 2). Furthermore, all athletes felt that they had clearly benefited from the surgery and that their athletic performance had improved after the operation. All athletes said that they would undergo surgery again.

The case example was a 26-year-old male professional soccer player (left foot dominant) who had several rectus femoris central tendon tears (left side) during a 2-year



**Figure 3.** Magnetic resonance and perioperative images of the repair of the complete chronic rectus femoris central tendon rupture. Magnetic resonance images show the chronic rupture of rectus femoris central tendon (arrows): (A) T2-weighted axial images and (B) T1-weighted coronal images. (C) Forceps show the chronic and scarred rectus femoris central tendon; double arrows indicate healthy and elastic central tendon structure within muscle.<sup>1</sup> (D) Scarred and thickened central tendon structure is prepared and liberated from the surrounding muscle tissue (white circle). (E) After debridement, the gliding Z-plasty has been done to the tight central tendon (with forceps holding the central tendon ends). (F) The continuity of the central tendon is restored by suture with Z-plasty fashion without tightness (white arrows).

period. A sharp and disabling pain surfaced regularly during the performance of sports. The pain inhibited his return to play, even when adequate physical therapy was performed. He underwent uneventful surgery for rectus femoris central tendon injury, and the rehabilitation protocol is presented in Table 2 and the Appendix Video. Seven months after rehabilitation and return to competitive play, he had rectus femoris muscle tissue strain on the right side (ie, contralateral) according to MRI, which also showed the healed central tendon of rectus femoris on the left side (Figure 4).

**TABLE 2**  
Anticipated Schedule for Return-to-Play After Surgical Treatment of Rectus Femoris Central Tendon

Postoperative Rehabilitation	Postoperative Weeks
Use of crutches and pain-free walking	1-2
Pool training	3-4
Isometric exercise	3-4
Stationary biking	3-5
Light jogging, ball exercises, deep squatting	5-6
Weight training	6-10
Ball training with kicking, sprinting, jumping, and dynamic agility exercises	10-12
Full training and return to play	12-14

**TABLE 3**  
Characteristics and Outcomes of 12 Athletes After Surgical Treatment of Chronic Rectus Femoris Central Tendon Rupture<sup>a</sup>

Patient	Age, y	Sport	Primary Injury to Surgery, mo	Outcome (SPORTS Score)
1	18	Soccer	5 <sup>b</sup>	Good (10)
2	18	Soccer	7	Good (10)
3	19	Soccer	6	Good (10)
4	19	Soccer	9 <sup>b</sup>	Moderate (9)
5	20	Soccer	5	Good (10)
6	24	Soccer	8	Good (10)
7	25	Soccer	6	Good (10)
8	26	Soccer	12 <sup>b</sup>	Good (10)
9	27	Soccer	4	Good (10)
10	28	Soccer	11 <sup>b</sup>	Good (10)
11	29	Long jump	6 <sup>b</sup>	Moderate (9)
12	29	Baseball	12 <sup>b</sup>	Good (10)

<sup>a</sup>SPORTS, Subjective Patient Outcome for Return to Sports.

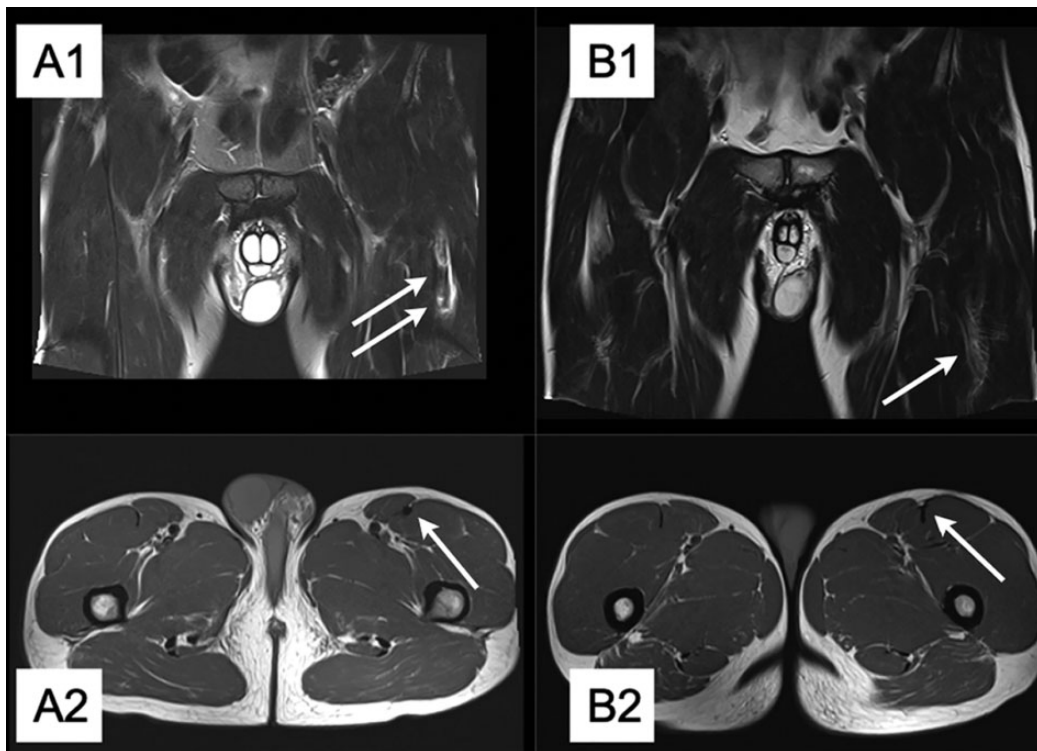
<sup>b</sup>Recurrent injury (second, third, or more injuries before surgery at our hospital).

## DISCUSSION

The main finding of this study was that, after well-carried surgery with structured rehabilitation, all injured athletes with chronic and/or recurrent rectus femoris injuries were able to return to play at their preinjury levels of performance. It is important to increase knowledge about this surgical indication for chronic and recurrent rectus femoris central tendon injuries. Furthermore, physicians treating these injuries should bear in mind that central tendon injuries take more time to heal and could develop a tendency to become chronic.<sup>4</sup>

Rectus femoris central tendon injuries were first introduced in 1995 by Hughes et al<sup>9</sup> and classified as incomplete and intrasubstance strains. In this study, 2 patients were treated surgically. According to this study, it is important to know that this special injury type can be similar to a soft tissue tumor.<sup>16</sup> If a clinical suspicion toward a soft tissue tumor has risen, the diagnosis should always be verified by MRI.





**Figure 4.** Case example of rectus femoris central tendon healing. (A) This soccer player had a left-side recurrent rectus femoris central tendon injury (arrows show the injured area). (B) Seven-month postoperative magnetic resonance images show a healed central tendon at the left.

In a previous and well-acknowledged study dealing with ultrasound findings of central tendon rectus femoris injuries, this central tendon structure was named a “muscle within muscle” structure.<sup>1</sup> According to our clinical, hands-on experience, we propose that this name be abandoned and that “tendon within muscle” (ie, central tendon) be used instead.

MRI is a useful tool for analyzing the magnitude of the tendon injuries, and it can recognize tendon rupture with high sensitivity.<sup>6</sup> Findings such as bull’s-eye signs or the lack of continuity of the central tendon are typical in rectus femoris injuries involving the central tendon structure.<sup>4,13</sup> The central tendon injury may not be easily detected if MRI scans are taken right after the injury, owing to the formation of a hematoma. Therefore, follow-up MRI should be considered after 2 weeks of the central tendon injury if clinical symptoms continue and severe central tendon injury is suspected.<sup>11</sup>

The physician should look for the central tendon injury to evaluate the return-to-play time and the rehabilitation protocol; thus, injuries involving the tendon take more time to heal than typical rectus femoris muscle tissue injuries.<sup>4</sup> So far, there have been no surgical treatment indications for chronic and recurrent rectus femoris central tendon ruptures. Good results after surgery have been reported for rectus femoris proximal avulsions and midsubstance complete ruptures, mainly among high-performance athletes.<sup>7,10,12,15</sup> More research

should be performed to clarify the central tendon injury treatment methods. It is still not clear which central tendon injuries benefit from more aggressive therapy, including surgery.<sup>4,5</sup> Based on our experience as well as the present study, surgical treatment should at least be considered if the athlete is not able to return to play and symptoms have continued for 4 to 5 months after rectus femoris central tendon injury. Interestingly, “Why wasn’t a surgical option offered before?” was a common question asked by athletes with recurrent injuries and continuous unsuccessful nonoperative treatment in the present study.

Shimba et al<sup>14</sup> also reported good results from the surgical treatment of rectus femoris central tendon injuries in 2 cases. These 2 athletes returned to normal sports activity after 4 and 5 months, respectively. In the present case series of 12 athletes, return to play was achieved between 2.5 and 4 months.

This study had certain limitations. As a consequence of the retrospective nature, results after surgery were evaluated by the ability of the athlete to return to sports and by analyzing the subjective symptoms of each athlete. The central tendon rupture of the rectus femoris is a rare injury; therefore, comparison groups are not gathered at present. The rehabilitation program did not include systematic strength measurements, which should be taken into consideration for future prospective studies to better understand the course of return to play after surgery. Furthermore, we

were unable to include a group of nonsurgically treated athletes for comparison control. In our opinion, however, when considering high-performance professional sports, collected individual case series should also be acknowledged retrospectively. By sharing our knowledge and experience in the treatment of rectus femoris central tendon injuries, we can help an athlete whose sports career would otherwise be over at a professional level.

## CONCLUSION

Rectus femoris central tendon rupture is a poorly known and understood injury. More challenging and recurrent cases with chronic symptoms seem to benefit from surgery. The present study shows that 10 of 12 athletes returned to sport with a good outcome after surgical treatment and a thoroughly carried-out rehabilitation.

A Video Supplement for this article is available at <http://journals.sagepub.com/doi/suppl/10.1177/2325967120984486>.

## REFERENCES

- Balius R, Maestro A, Pedret C, et al. Central aponeurosis tears of the rectus femoris: practical sonographic prognosis. *Br J Sports Med.* 2009;43(11):818-824.
- Blonna D, Castoldi F, Delicio D, et al. Validity and reliability of the SPORTS score. *Knee Surg Sports Traumatol Arthrosc.* 2012;20(2):356-360.
- Blonna D, Lee GC, O'Driscoll SW. Arthroscopic restoration of terminal elbow extension in high-level athletes. *Am J Sports Med.* 2010;38(12):2509-2515.
- Brukner P, Connell D. "Serious thigh muscle strains": beware the intramuscular tendon which plays an important role in difficult hamstring and quadriceps muscle strains. *Br J Sports Med.* 2016;50(4):205-208.
- Comin J, Malliaras P, Baquie P, Barbour T, Connell D. Return to competitive play after hamstring injuries involving disruption of the central tendon. *Am J Sports Med.* 2013;41(1):111-115.
- Cross TM, Gibbs N, Houang MT, Cameron M. Acute quadriceps muscle strains: magnetic resonance imaging features and prognosis. *Am J Sports Med.* 2004;32(3):710-719.
- Dean CS, Arbeloa-Gutierrez L, Chahla J, Pascual-Garrido C. Proximal rectus femoris avulsion repair. *Arthrosc Tech.* 2016;5(3):e545-e549.
- Harriss DJ, Macsween A, Atkinson G. Ethical standards in sport and exercise science research: 2020 update. *Int J Sports Med.* 2019;40(13):813-817.
- Hughes C IV, Hasselman CT, Best TM, Martinez S, Garrett WE Jr. Incomplete, intrasubstance strain injuries of the rectus femoris muscle. *Am J Sports Med.* 1995;23(4):500-506.
- Lempainen L, Kosola J, Niemi P, Orava S, Pruna R. Complete mid-substance rectus femoris ruptures: a series of 27 athletes treated operatively. *Muscles Ligaments Tendons J.* 2018;8(2):276-282.
- Lempainen L, Kosola J, Pruna R, et al. Central tendon injuries of hamstring muscles: case series of operative treatment. *Orthop J Sports Med.* 2018;6(2):2325967118755992.
- Lempainen L, Kosola J, Pruna R, Puigdemivol J, Ranne J, Orava S. Operative treatment of proximal rectus femoris injuries in professional soccer players: a series of 19 cases. *Orthop J Sports Med.* 2018;6(10):2325967118798827.
- Maffulli N, Oliva F, Frizziero A, et al. ISMuLT guidelines for muscle injuries. *Muscles Ligaments Tendons J.* 2014;3(4):241-249.
- Shimba LG, Latorre GC, Pochini AC, Astur DC, Andreoli CV. Surgical treatment of rectus femoris injury in soccer playing athletes: report of two cases. *Rev Bras Ortop.* 2017;52(6):743-747.
- Sonnery-Cottet B, Barbosa C, Tuteja S, et al. Surgical management of rectus femoris avulsion among professional soccer players. *Orthop J Sports Med.* 2017;5(1):2325967116683940.
- Temple HT, Kuklo TR, Sweet DE, Gibbons CL, Murphey MD. Rectus femoris muscle tear appearing as a pseudotumor. *Am J Sports Med.* 1998;26(4):544-548.