

Stenting of the right ventricular outflow tract in a symptomatic newborn with tetralogy of Fallot

Paweł Dryżek, Tomasz Moszura, Sebastian Góreczny, Krzysztof W. Michalak

Department of Cardiology, Polish Mother Memorial Hospital Research Institute, Lodz, Poland

Postępy Kardiologii Interwencyjnej 2015; 11, 1 (39): 44–47
DOI: 10.5114/pwki.2015.49184

Abstract

This case describes a successful percutaneous stent implantation to critical stenosis of the right ventricle outflow tract in a female neonate with tetralogy of Fallot. At the time of the procedure she had poor development of the pulmonary arteries (McGoon and Nakata index 1.45 and 120, respectively). Stent implantation ensured an immediate increase in oxygen saturation level, and the physiological pulsating blood inflow caused good development of the pulmonary arteries during 12 months of follow up (McGoon 2.5; Nakata Index 436). After this time she was qualified for surgery and underwent surgical correction without using a patch or conduit implantation.

Key words: right ventricle outflow tract stenting, catheterisation, interventions, stent implantation.

Introduction

Tetralogy of Fallot (ToF) comprises diverse anatomical variants that manifest with different clinical courses and haemodynamic conditions. The degree of right ventricle outflow tract (RVOT) obstruction and stenosis of pulmonary arteries determine the severity of cyanosis. Forms with fully developed pulmonary arteries are less common, and various degrees of underdevelopment of pulmonary vessels are usually present. An example of the latter group is critical stenosis of RVOT with hypoplasia of pulmonary arteries. In this setting, percutaneous RVOT stenting could serve as an alternative treatment to surgically placed systemic-to-pulmonary artery shunt or ductal stenting [1, 2].

We report on interventional treatment of a 7-day-old infant, who underwent stent implantation to the RVOT and surgical correction 1 year later.

Case report

A female baby was born at 40 weeks of gestation and with 3200 g of birth weight. The patient received continuous prostaglandin infusion and was stabilised with oxygen saturation approaching 80%. Echocardiogram revealed enlargement of the right ventricle, large ventricular septal defect (8.4 mm), dextroposition of the

aorta (50%), and severe RVOT with predominant subvalvular stenosis (PG 70 mm Hg). Pulmonary blood flow was secured mainly by wide ductus arteriosus. Additionally, microphthalmos was suspected, and corneal opacity and 22q11.2 microdeletion were diagnosed. The patient was qualified for right heart catheterisation with the intention of implanting a stent into the RVOT.

On the 7th day of life, under general anaesthesia with standard antibiotic prophylaxis, the femoral vein was punctured and one dose of heparin (100 IU/kg) was administered. Subsequently, a 4 Fr NIH catheter (Cook) was introduced into the right ventricle. Angiogram showed severe RVOT obstruction and narrow main pulmonary artery (5 mm) with stenosis at the subvalvular and valvular level and pulmonary arteries of 4.8 mm in diameter (Figure 1). It corresponded to McGoon and Nakata index 1.45 and 120, respectively. Wide ductus arteriosus supporting pulmonary blood was also noticed. After placement of a soft coronary guidewire 0.014 inch (0.356 mm) (Terumo) in the right pulmonary artery, pulmonary valvuloplasty was performed with a Tyshak II 6 × 20 mm balloon (NuMed). The original guidewire was replaced with a Teflon-coated 0.032 inch (0.812 mm) guidewire (Cordis), and a Palmaz-Genesis 7 × 18 mm stent (Cordis) was implanted below the pulmonary valve (Figure 2).

Corresponding author:

Krzysztof W. Michalak MD, PhD, Department of Cardiology, Polish Mother Memorial Hospital Research Institute, 281/289 Rzgowska St, 93-338 Lodz, Poland, phone: +48 600 096 007, e-mail: krzysiekmichalak@interia.pl

Received: 10.10.2014, **accepted:** 8.01.2015.

Control rotational angiography from the right ventricle showed correct stent localisation with a minimal diameter of 6.8 mm and unobstructed blood flow (Figure 3). While oxygen saturation increased to 95%, prostaglandin infusion was stopped. For the next 3 days the patient received low molecular heparin once daily followed by acetylic acid (3 mg/kg). Control echocardiographic study showed turbulent flow through the RVOT with a maximal velocity of 3.6 m/s. Leaflets of the pulmonary valve were mobile, and mild insufficiency was noted as well. After 10 days of hospitalisation the patient was discharged home with oxygen saturations approaching 90%.

During follow-up the baby slowly gained weight, presumably due to genetic syndrome, with stable oxygen saturations remaining in the mid-80s. Microphthalmos was ruled out, and corneal opacity subsided gradually. In consecutive control echocardiography, maximal flow through the stent of up to 4 m/s was noticed. In the 12th month of life angio-computed tomography (CT) was performed to visualise pulmonary vessels prior to planned corrective surgery. The main pulmonary artery (15 mm) and both pulmonary arteries (10 mm each) were well developed, corresponding to satisfactory indices of pulmonary vessel growth (Mc Goon 2.5; Nacata Index 436). Under cardiopulmonary bypass the stent was excised

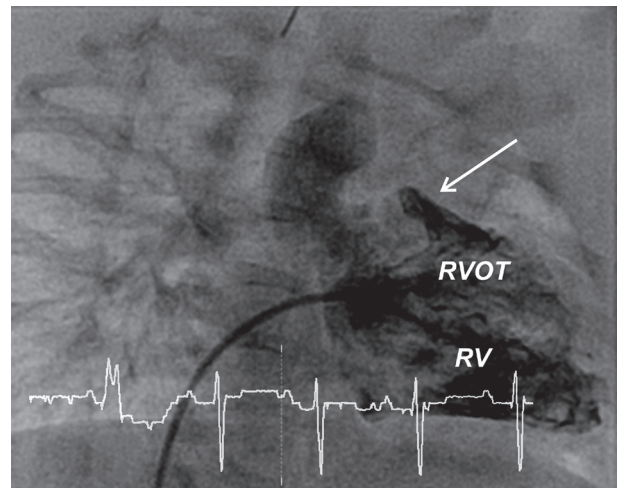


Figure 1. Angiography before procedure; catheter is placed in the right ventricle (RV). Critical stenosis of the right ventricle outflow tract (RVOT), arrow shows the site of future stent implantation – subvalvular stenosis

and the right ventricle outflow tract was reconstructed without using a patch or conduit implantation. The post-operative course was uneventful, and the patient was discharged home after 14 days.

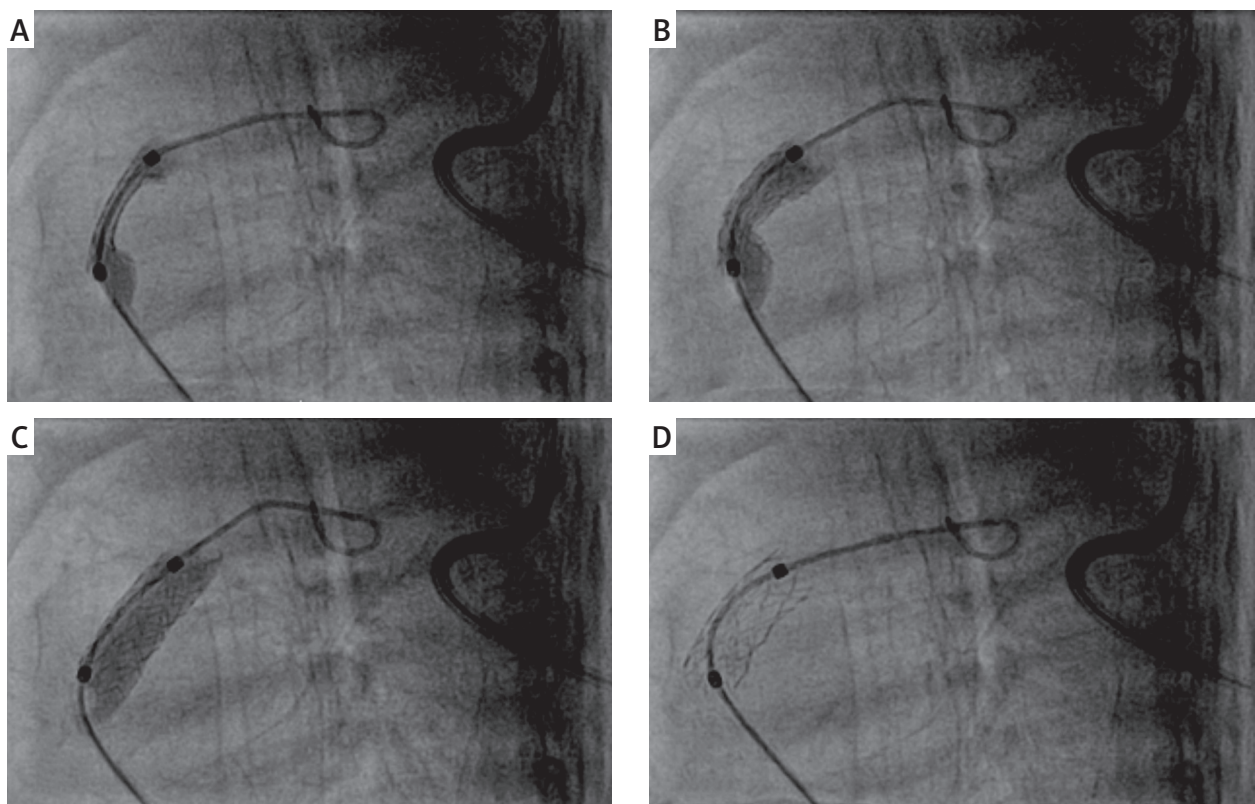


Figure 2. Staged stent implantation into the critical RVOT stenosis in fluoroscopy. **A** – Early phase of balloon inflation and Palmaz-Genesis 7 × 18 mm stent (Cordis) expansion. **B** – Late phase of balloon inflation with only local incision in balloon shape – the site of main stenosis of the RVOT. **C** – Fully expanded Palmaz-Genesis 7 × 18 mm stent with the inflated balloon inside. **D** – Stent after implantation procedure

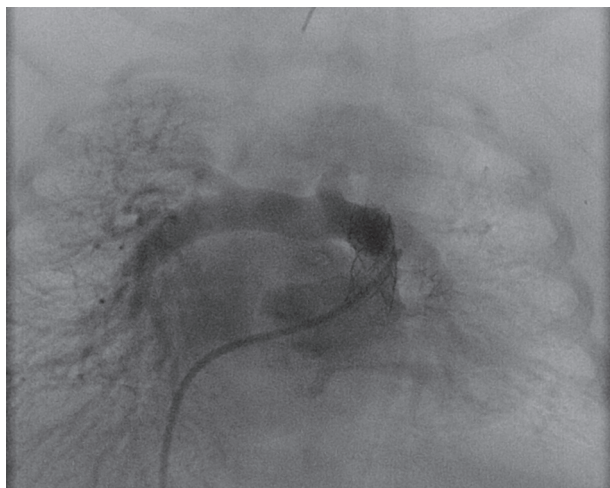


Figure 3. Angiography from the right ventricle shows unobstructed blood flow through RVOT, the pulmonary artery, and its main branches

Discussion

Both surgical and interventional treatment can be successfully applied for treatment of ToF with critical stenosis of the RVOT [3–5]. Stent implantation to the RVOT could be an alternative treatment to surgically placed systemic-to-pulmonary shunt or stenting of ductus arteriosus, especially in patients with severe under development of pulmonary arteries. Surgical systemic-to-pulmonary shunt in this group carries a high risk of thrombosis or distal pulmonary stenosis, and hence there is a need for reintervention [6, 7]. A further disadvantage of surgical shunt is the possibility of asymmetric growth of pulmonary arteries, which can also be an issue after ductal stenting if the duct takes off more distally from a pulmonary branch.

Stenting of the RVOT secures the physiological direction of pulsating blood flow and enables symmetric growth of both branch arteries and the main pulmonary artery. This approach is more commonly utilised in patients with restenosis after surgical reconstruction of the RVOT [8–10]. It can also be performed as an additional treatment in unstable patients with hypoplastic pulmonary arteries, despite a surgically placed systemic-to-pulmonary shunt to augment pulmonary blood flow, increase oxygen saturation, and stabilise the patient's general condition [9].

It is crucial in this type of intervention to place the stent below valve leaflets in order not to hinder its movement and induce insufficiency. Appropriate stent length and meticulous positioning are of outmost importance. If a stent is chosen with too small a diameter, there is the risk of stent instability and embolisation, especially during balloon withdrawal. This risk can be reduced with placement of a long introducing sheath into the right ventricle outflow tract. Patent ductus arteriosus provides continuous pulmonary blood flow during stent introduction and balloon inflation and therefore gives more time

for proper stent positioning without causing desaturation and bradycardia [1, 2].

Restenosis within the stent, stent fracture, or insufficient blood flow due to patent growth can complicate the clinical course. In the presented patient repeated echocardiographic studies showed a gradual increase in the maximal velocity through the stent, up to 4 m/s, with oxygen saturations slowly declining to 80%. In echo- and angio-CT no stent fragmentation was noticed, which was confirmed during surgical excision of the stent.

Stenting of the RVOT in patients with ToF and critical subpulmonary stenosis has been reported previously [1, 2]. However, in most cases the time interval between the percutaneous intervention and the surgery was shorter. In the presented patient corrective surgery was performed after 12 months, which was related to gradual weight gain, concomitant anomalies (genetic syndrome, corneal opacity) with stable and acceptable oxygen saturations (above 80%).

Conclusions

Early neonatal stenting of the right ventricle outflow tract allowed for augmentation of pulmonary blood flow in a physiological direction with correct pulsating inflow resulting in an immediate increase in oxygen saturations and patient stabilisation. During follow-up, such intervention results in symmetric growth of pulmonary arteries and creates better conditions for surgical correction.

Conflict of interest

The author declare no conflict of interest.

References

1. Sunhee B, Hong KK, Jeong JY, et al. Right ventricular outflow tract stenting in a low birth weight infant born with tetralogy of Fallot and prostaglandin E1 dependency. *Korean Circ J* 2011; 41: 744-6.
2. Dohlen G, Chaturvedi RR, Benson LN, et al. Stenting of the right ventricular outflow tract in the symptomatic infant with tetralogy of Fallot. *Heart* 2009; 95: 142-7.
3. Kaza AK, Lim HG, Dibardino DJ, et al. Long-term results of right ventricular outflow tract reconstruction in neonatal cardiac surgery: options and outcomes. *J Thorac Cardiovasc Surg* 2009; 138: 911-6.
4. Korbmacher B, Heusch A, Sunderdiek U, et al. Evidence for palliative enlargement of the right ventricular outflow tract in severe tetralogy of Fallot. *Eur J Cardiothorac Surg* 2005; 27: 945-8.
5. Seipelt RG, Vazquez-Jimenez JF, Sachweh JS, et al. Antegrade palliation for diminutive pulmonary arteries in tetralogy of Fallot. *Eur J Cardiothorac Surg* 2002; 21: 721-4.
6. Santoro G, Palladino MT, Capozzi G, et al. Pulmonary artery growth following arterial duct stenting in congenital heart disease with duct-dependent pulmonary. *Circulation Catheter Cardiovasc Interv* 2009; 74: 1072-6.
7. Santoro G, Capozzi G, Caianiello G, et al. Pulmonary artery growth after palliation of congenital heart disease with duct-dependent pulmonary circulation: arterial duct stenting versus surgical shunt. *J Am Coll Cardiol* 2009; 54: 2180-6.

8. Shenoy AR, Padmakumar P, Subashchandra V. Right ventricular outflow tract stenting in tetralogy of Fallot with restrictive ventricular septal defect. *J Invasive Cardiol* 2006; 18: 59-60.
9. Dryżek P, Mazurek-Kula A, Moszura T, et al. Right ventricle outflow tract stenting as a method of palliative treatment of severe tetralogy of Fallot. *Cardiol J* 2008; 15: 376-9.
10. Zeidenweber CM, Kim DW, Vincent RN. Right ventricular outflow tract and pulmonary artery stents in children under 18 months of age. *Catheter Cardiovasc Interv* 2007; 69: 23-7.