


CASE REPORT

Conservative management of congenital hepatic hemangioma complicated by ascites

Emmy Hoornaert¹  | Philippe Clapuyt² | Dana Dumitriu² | Olivier Niel³ |
Sophie Huybrechts³ | Isabelle Scheers¹ | Etienne Sokal¹ | Raymond Reding⁴ |
Xavier Stephenne¹

¹Division of Paediatric Gastroenterology and Hepatology, Department of Paediatrics, Cliniques Universitaires Saint Luc, Université catholique de Louvain, Brussels, Belgium

²Division of Paediatric Radiology, Department of Radiology, Cliniques Universitaires Saint Luc, Université catholique de Louvain, Brussels, Belgium

³Department of Paediatrics, Centre Hospitalier du Luxembourg, Luxembourg, Luxembourg

⁴Division of Paediatric Surgery, Department of Surgery, Cliniques Universitaires Saint Luc, Université catholique de Louvain, Brussels, Belgium

Correspondence

Emmy Hoornaert, Division of Paediatric Gastroenterology and Hepatology, Department of Paediatrics, Cliniques Universitaires Saint-Luc, Brussels 1200, Belgium.
Email: emmy.hoornaert@student.uclouvain.be

Funding information

None

Abstract

Involution of a rapidly involuting congenital hemangioma is an unknown cause of neonatal ascites. As involution phase is completed by 14 months after birth, conservative management with diuretics and drainage is possible and may avoid surgical resection.

KEYWORDS

ascites, conservative management, involution process, rapidly involuting congenital hemangioma

1 | INTRODUCTION

Neonatal ascites is an uncommon problem. Various etiologies may be found such as diseases of the genitourinary system (ovarian cyst and urinary obstruction) or the gastrointestinal system (intestinal perforation and hepatic diseases), cardiac diseases, systemic infections (TORCH or parvovirus), a chylous obstruction, an inborn error of metabolism or an idiopathic cause.^{1,2} Here, we report a case of a female infant who developed clinically significant ascites as her hepatic hemangioma started the involution process.

2 | CASE REPORT

A 2-month-old eutrophic girl was brought by her parents to the emergency room for discomfort and abdominal

bloating. Her medical history was marked by hypoglycemia at birth and left ventricular hypertrophy due to an unbalanced gestational diabetes. Prenatal ultrasound did not show any abnormalities except for a polyhydramnios. In the emergency room, abdominal ultrasound showed a significant amount of ascites and a left hepatic mass of 2.5 cm well calcified and richly vascularized compatible with an involuting hemangioma (cfr [Figure 1](#)). As the mass repressed the left hepatic vein, a venography and a measurement of the hepatic venous pressure gradient were done to exclude a Budd–Chiari syndrome. This examination did not show any abnormalities on the hepatic stage but revealed a hypoplasia of the infrarenal part of the vena cava inferior with a preferential flow to the peri-vertebral region. However, this finding cannot explain ascites as it is a retroperitoneal venous disease. Further examinations such as cardiac and renal ultrasound, metabolic

This is an open access article under the terms of the [Creative Commons Attribution-NonCommercial-NoDerivs](#) License, which permits use and distribution in any medium, provided the original work is properly cited, the use is non-commercial and no modifications or adaptations are made.

© 2022 The Authors. *Clinical Case Reports* published by John Wiley & Sons Ltd

screening, and infectious serologies were normal. Ascites analysis showed an exudate with 51% of lymphocytes excluding a chylous ascites. There were no tumoral cells but numerous red cells.

As the most common etiologies of ascites were excluded, ascites has been drained for 10 days with an abdominal drain that was inserted and diuretics were started (furosemide [lasix[®], Sanofi] and spironolactone [aldactone[®], Pfizer]) with a favorable spontaneous evolution. There was no respiratory compromise due to abdominal splinting, and no respiratory support was needed.

However, drainage of the ascites was frequently sero-bloody leading us to the question which role the liver hemangioma was playing in the ascites formation. Literature review showed us two similar cases by Klein

et al³ of large amount of ascites formation during involution of hepatic rapidly involuting congenital hemangioma (RICH).

We managed our patient with a conservative treatment and did not proceed to any surgical intervention. The patient benefited from close follow-up. Her hemangioma progressively regressed on serial imaging. Indeed, it measured only half of its initial size 2 months after hospitalization at the age of 4 months. However, at that time, ascites amount increased again needing a second short hospitalization. Drainage of ascites was not possible and it spontaneously regressed again without increasing diuretics. The patient also developed anemia (lowest hemoglobin of 7 g/dl) requiring folic acid and iron supplementation without any evidence of consumptive coagulopathy. After this episode, the evolution of the patient was favorable and the diuretics could be gradually reduced. At the age of 6 months, 4 months after her first hospitalization, ascites disappeared completely.

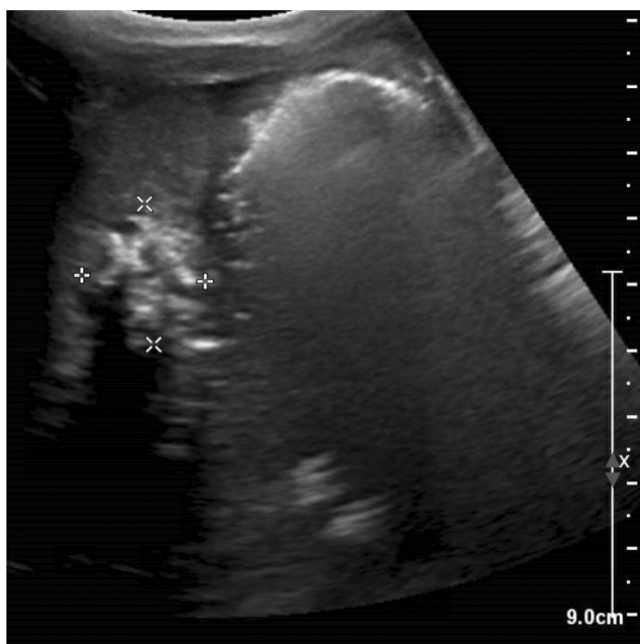

FIGURE 1 Abdominal US showing a 34 × 22 × 25 mm mass between segments II and III

3 | DISCUSSION

Congenital and infantile hemangiomas are both benign tumors but are histologically different: congenital hemangiomas are GLUT 1 negative in counter to infantile hemangiomas. They also have a different expected natural course. In fact, congenital hemangiomas are fully formed at birth whereas infantile hemangiomas initiate proliferation in the first weeks after birth.³ There are of two types of congenital hemangiomas: RICH that undergoes an accelerated involution phase completed by 14 months after birth, and the NICH (non-evolving congenital hemangioma) that maintains the same size and does not regress. However, it could be that NICH tumors are the sequelae of RICH tumors having partially regressed in utero. Biopsy helps to make definitive diagnosis of a RICH,^{4,5} it histologically shows variably

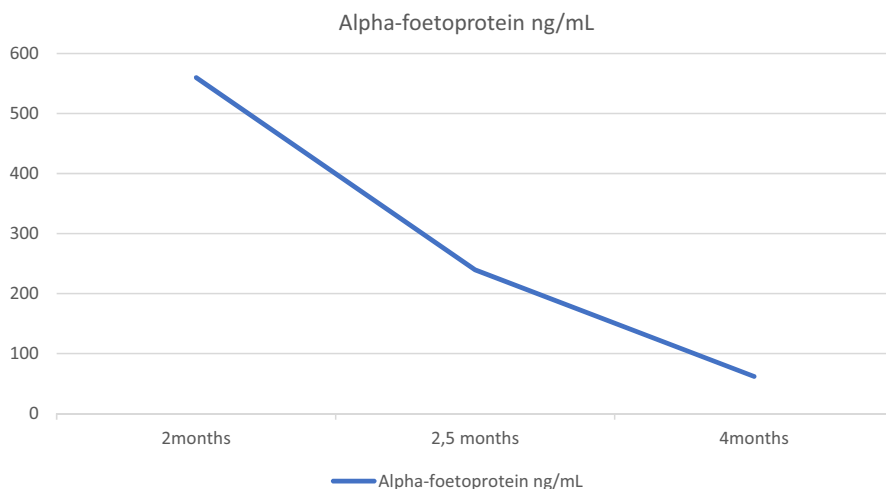


FIGURE 2 Serum alpha-fetoprotein evolution during the follow-up of the patient

sized, though usually small hemangiomas, and are GLUT 1 negative. However, biopsy is invasive and presents a significant bleeding risk, especially in the presence of thrombocytopenia or coagulopathy.⁴ In this case, we decided not to do the biopsy as we did not want to take any unnecessary risk. However, typical radiological images and serum alfa-fetoprotein (AFP) levels may also be helpful in establishing the diagnosis of a RICH tumor. In fact, serum AFP can be highly elevated in the presence of a RICH. The best way to distinguish a RICH from a hepatoblastoma is to perform serial measurements of AFP to document a falling serum AFP. In case of a hepatoblastoma, levels of AFP will continue to increase⁶ As for typical radiological images, RICH frequently appears heterogeneous on US and has frequent calcifications in counter to infantile hemangiomas.^{7,8} In this case, we diagnosed a hepatic RICH based on characteristic imaging, typical evolution, and high levels of AFP at admission that progressively decreased (cf. Figure 2). Roebuck et al suggest that biopsy is not needed if the hepatic mass has following criteria: typical imaging features of RICH, regression on serial imaging, and falling serum AFP.⁸

Hepatic RICH tumors can complicate with bleeding and rupture, consumptive coagulopathy, thrombocytopenia, abdominal pain, and in rare cases, hepatic or heart failure. Intra-lesional arteriovenous shunting can also be found. Ascites is an unknown complication of the involution of a RICH tumor. Only two cases were described in literature by Klein et al.³ The mechanism of ascites formation of RICH hemangiomas during involution is unclear. It can be secondary to inflammation caused by involution or by peritoneal irritation related to intra-abdominal blood loss.

In counter to infantile hemangiomas, RICH does not respond to corticosteroids and propranolol.⁸ As most of RICH naturally involute within 12–14 months, most of the cases may only need supportive care (transfusion in case of bleeding or thrombocytopenia). However, in some cases, surgical intervention might be indicated especially facing uncontrolled active bleeding or heart failure. Klein et al³ suggest that the formation of a large amount of ascites is a new indication for the resection of the RICH hemangioma. However, we decided not to operate and manage it conservatively with diuretics and drainage as RICH tumors involute spontaneously before 14 months and considering surgery an unnecessary risk. Indeed, Gourgiotis et al,⁹ reported based on their 15 years of experience of hepatic hemangioma surgery that the resection of the hepatic hemangioma is safe^{10,11} but indications should be carefully analyzed before embarking on such a major surgery.⁹ We managed our patient with a close follow-up by performing frequent blood tests to screen any

active bleeding and to follow the coagulation profile and platelets. A close follow-up by abdominal ultrasound was also performed in order to evaluate whether involution was progressing and the hemangioma getting smaller. Parents were made aware of the potential risk that ascites could recur.

4 | CONCLUSION

Facing neonatal ascites, it is necessary to consider the possibility of the involution of a rapidly involuting congenital hemangioma. The pathogenesis leading to the onset of ascites formation is still unclear. However, it can be secondary to inflammation caused by involution or by peritoneal irritation related to intra-abdominal blood loss. As the involution phase is completed by 14 months after birth, conservative management with diuretics and drainage is possible and may avoid surgical resection. Nevertheless, further standardization of the management of these hepatic tumors is needed as only two other cases have been described in literature and were managed surgically. Further studies including larger cohorts of patients are necessary to confirm this management.

AUTHOR CONTRIBUTIONS

Emmy Hoornaert wrote the manuscript; validated the final section of the manuscript; and made substantial contributions to conception and design, or acquisition of data, or analysis and interpretation of data. Xavier Stephenne revised the manuscript critically for important intellectual content; made substantial contributions to conception and design, or acquisition of data, or analysis and interpretation of data; was in charge of the patient; and gave final approval of the version to be published. Pr Philippe Clapuyt and Dr Dana Dumitriu performed ultrasounds during hospitalization, offered precious advices, and validated the final section of the manuscript. Dr Olivier Niel and Dr Sophie Huybrechts were in charge of the patient in Luxemburg and validated the final section of the manuscript. Pr Isabelle Scheers, Pr Etienne Sokal, and Pr Raymond Reding were in charge of the patient, offered many precious pieces of advice, and validated the final section of the manuscript. All authors provided critical feedback and helped shape the manuscript.

ACKNOWLEDGMENT

None.

CONFLICT OF INTEREST

None.

DATA AVAILABILITY STATEMENT

Data sharing is not applicable to this article as no datasets were generated or analyzed during the current study.

ETHICAL APPROVAL

This case report is in accordance with the journal's ethics and integrity policies.

CONSENT

Written informed consent was obtained from the patient to publish this report in accordance with the journal's patient consent policy.

ORCID

Emmy Hoornaert  <https://orcid.org/0000-0001-8644-1330>

REFERENCES

1. Chou YY, Huang HC, Chung MY, Huang CB. Isolated fetal and neonatal ascites: report of two cases. *Acta Paediatr Taiwan*. 2001;42(3):166-168.
2. Griscom NT, Colodny AH, Rosenberg HK, et al. Diagnostic aspects of neonatal ascites: report of 27 cases. *AJR Am J Roentgenol*. 1977;128:961-969.
3. Klein M, Chang AK, Vasudevan SA, Blatt J, Iacobas I, Lee S. Clinically significant ascites as an indication for resection of rapidly involuting congenital hepatic hemangiomas. *Pediatr Blood Cancer*. 2018;65:e27222.
4. Lewis D, Hachey K, Fitzgerald S, Vaidya R. Rapidly involuting congenital haemangioma of the liver. *BMJ Case Rep*. 2018;2018:bcr-2018.
5. Restrepo R, Palani R, Cervantes LF, Duarte AM, Amjad I, Altman NR. Hemangiomas revisited: the useful, the unusual and the new. *Pediatr Radiol*. 2011;41:895-904.
6. Sari N, Yalçın B, Akyüz C, Haliloglu M, Büyükpamukçu M. Infantile hepatic hemangioendothelioma with elevated serum alpha-fetoprotein. *Pediatr Hematol Oncol*. 2006;23:639-647.
7. Moon SB, Kwon HJ, Park KW, Yun WJ, Jung SE. Clinical experience with infantile hepatic hemangioendothelioma. *World J Surg*. 2009;33:597-602.
8. Roebuck D, Sebire N, Lehmann E, Barnacle A. Rapidly involuting congenital haemangioma (RICH) of the liver. *Pediatr Radiol*. 2012;42:308-314.
9. Gourgiotis S, Moustafellos P, Zavos A, Dimopoulos N, Vericouki C, Hadjiyannakis EI. Surgical treatment of hepatic haemangiomas: a 15-year experience. *ANZ J Surg*. 2006;76(9):792-795.
10. Dickie B, Dasgupta R, Nair R, et al. Spectrum of hepatic hemangiomas: management and outcome. *J Pediatr Surg*. 2009;44(1):125-133.
11. Yoon SS, Charny CK, Fong Y, et al. Diagnosis, management, and outcomes of 115 patients with hepatic hemangioma. *J Am Coll Surg*. 2003;197(3):392-402.

How to cite this article: Hoornaert E, Clapuyt P, Dumitriu D, et al. Conservative management of congenital hepatic hemangioma complicated by ascites. *Clin Case Rep*. 2022;10:e05938. doi:[10.1002/ccr3.5938](https://doi.org/10.1002/ccr3.5938)