



# Intracoronary ethanol ablation of ventricular premature contractions in patients with preserved left ventricular function



Alex J.A. McLellan, Anish Bhuva, Simon Sporton, Charles Knight, Constantinos O'Mahony, Mehul B. Dhinoja\*

Barts Heart Centre, St. Bartholomew's Hospital, Barts Health NHS Trust, London, UK

## ARTICLE INFO

### Article history:

Received 31 July 2016

Received in revised form

26 October 2016

Accepted 26 October 2016

Available online 5 November 2016

### Keywords:

Ventricular premature contraction

Ethanol

Ablation

Left ventricular function

Coronary

## 1. Introduction

Ventricular premature contractions (VPC) refractory to medical management may require catheter ablation for symptomatic benefit or for compromised ventricular function in the setting of a high VPC burden [1,2]. While most VPCs are amenable to catheter ablation with conventional radiofrequency or cryothermal ablation from an endocardial approach, 8% of VPCs will have an intramural origin [3]. Where endocardial and epicardial approaches have failed to eliminate the VPC, intramural sources may require alternative approaches such as intra-coronary ethanol ablation [4]. We present a novel series of three intra-coronary ethanol ablation procedures in two patients with symptomatic VPCs and normal ventricular function.

*Abbreviations:* VPC, Ventricular premature contraction; EPS, Electrophysiology study; LVEF, Left ventricular ejection fraction.

\* Corresponding author. Department of Cardiology, St Bartholomew's Hospital Barts Heart Centre, London, UK.

E-mail address: [mbdhinoja@doctors.org.uk](mailto:mbdhinoja@doctors.org.uk) (M.B. Dhinoja).

Peer review under responsibility of Indian Heart Rhythm Society.

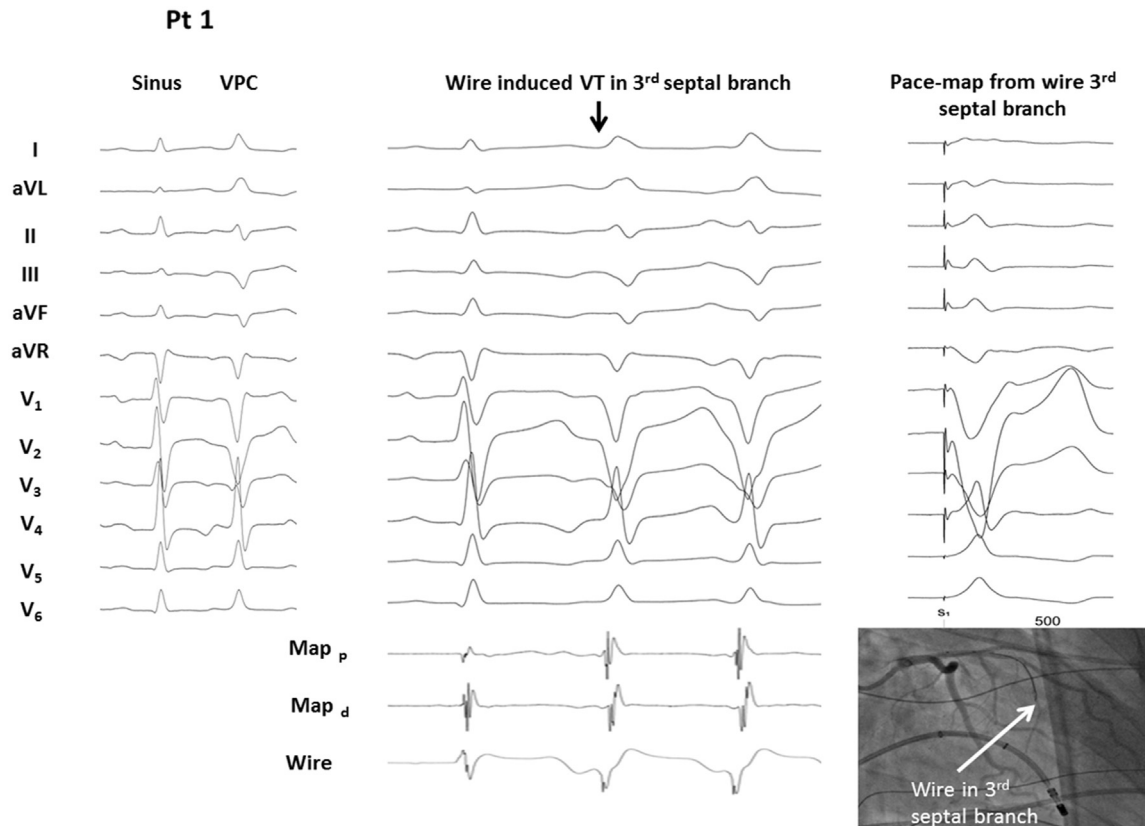
## 2. Case report

### 2.1. Patient selection & prior procedures

The two patients underwent three ethanol ablation procedures for symptomatic VPCs between November 2014 and September 2015. Prior to the ethanol ablation procedures the two patients had undergone conventional electrophysiology study (EPS) and ablation from both endocardial and epicardial approaches, and following these procedures an intramural origin was presumed in both patients. The prior EPS had been performed under conscious sedation with CARTO3, contact force sensing catheters (Thermocool SmartTouch®, Biosense Webster, Diamond Bar, CA, USA), and an Agilis sheath (St Jude Medical, St. Paul, MN, USA). Both patients had no other comorbidities and had trialled multiple anti-arrhythmic medications (three and five anti-arrhythmic medications in patients 1 and 2 respectively) to suppress the VPCs. Both patients had undergone cardiac MRI and transthoracic echocardiogram pre procedure confirming normal ventricular function (left ventricular ejection fraction of 55% and 57% in patients 1 and 2 respectively) with no late gadolinium enhancement, and had undergone serial electrocardiography and Holter monitoring demonstrating frequent monomorphic ventricular ectopy (30% and 32% burden of VPCs respectively).

### 2.2. Electrophysiology study

Both patients presented with frequent symptomatic ventricular ectopy on the day of the ethanol ablation procedure (Figs. 1 and 2). Prior to ethanol ablation, electrophysiology studies were performed under conscious sedation with local anaesthetic and anti-arrhythmic medications had been withheld for 5 half-lives before the procedure. Vascular access was obtained using ultrasound guidance, and included 7F and 8F sheaths to the right femoral vein and an 8F sheath to the right femoral artery. Therapeutic anticoagulation with heparin was administered and monitored throughout the case. Electroanatomic Mapping using CARTO3 and Thermocool SmartTouch® catheter (Biosense Webster) was performed initially via the right femoral vein for right ventricular and coronary sinus mapping and subsequently via a retrograde left



**Fig. 1.** Patient 1; left panel sinus rhythm and ventricular premature contraction morphology (VPC); middle panel wire provoked VT in the 3rd septal perforator (arrow), also note QS morphology of unipolar electrogram from wire (25 ms pre QRS); right panel shows pace-map from 3rd septal perforator; inset representative wire position on coronary angiogram with ablator at earliest endocardial site.

ventricular approach for coronary cusp and left ventricular mapping. In both patients the activation timing relative to the ectopic QRS was not significantly early at any endocardial site (Fig. 3), including within the coronary venous system selectively engaged with an SL4 sheath (St Jude Medical), Left Internal Mammary Artery (LIMA) guiding catheter and guide-wire for mapping. Subsequently intra-coronary mapping was pursued.

### 2.3. Intra-coronary mapping and ethanol ablation

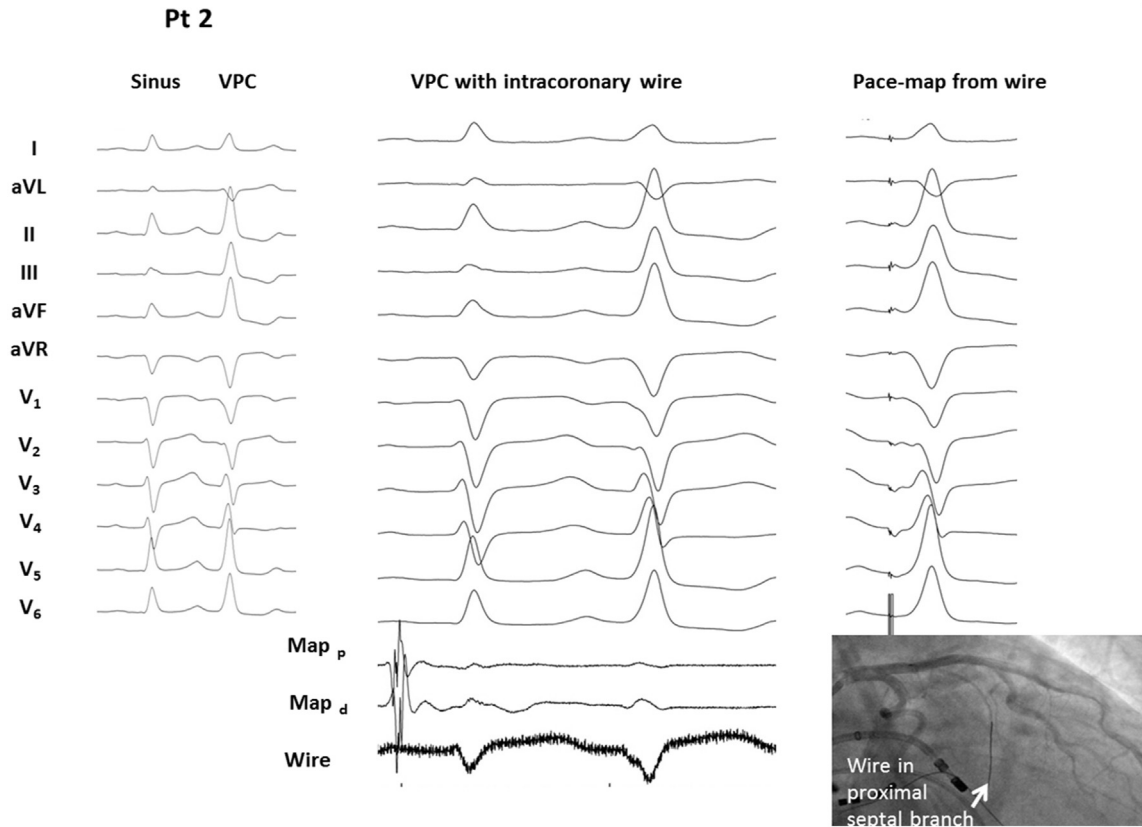
Immediately prior to intra-coronary mapping coronary angiography was performed with JL4 and JR4 catheters, demonstrating no coronary disease in both patients. A 0.014 inch Balance Middle Weight guidewire (BMW, Abbott Vascular, Illinois, USA) was advanced through the JL4 guide catheter, and an over-the-wire (OTW) balloon (1.25 × 8mm) was advanced over the BMW guidewire leaving the distal tip of the guidewire exposed. The proximal end of the BMW guidewire was connected to the positive port of a pacing module, and the negative port was connected to a quadripolar catheter placed in the inferior vena cava, creating a unipole for activation mapping. The BMW guidewire was sequentially advanced into different septal branches of the left anterior descending artery to observe activation timing during VPCs.

After a suitable septal perforator had been identified, the OTW balloon was advanced into the perforator so that its tip lay just beyond the ostium of the vessel and selective angiography was performed, confirming no backflow of contrast into the proximal left anterior descending artery and no collaterals. Cold saline (5mL) was injected down the branch to assess for suppression of the VPC. Once a suitable branch was identified, agitated gelo-plasma was

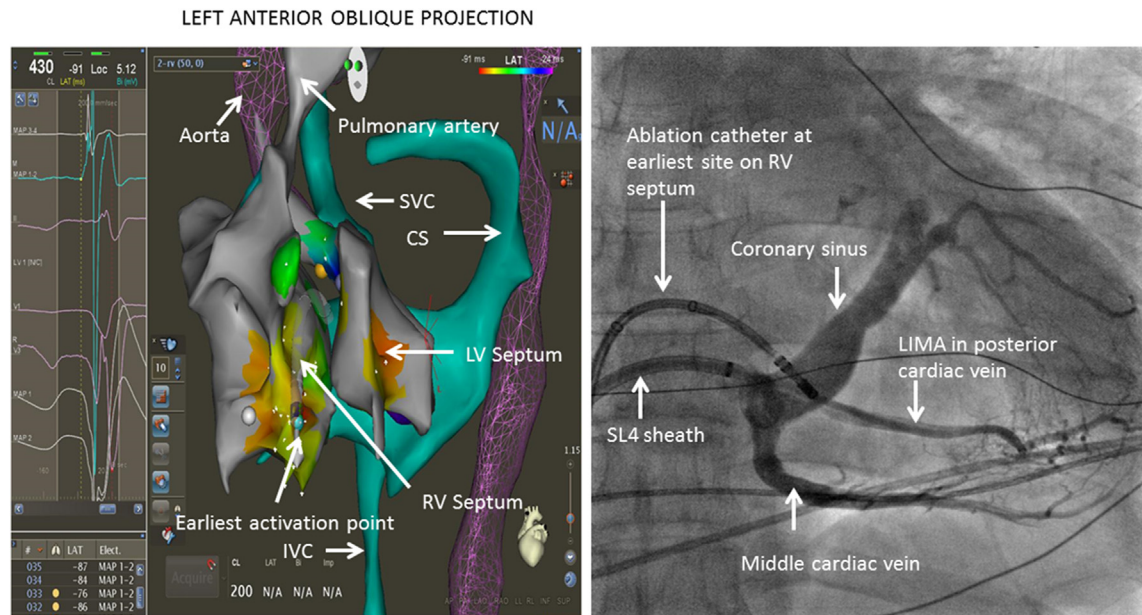
injected to highlight which region of the left ventricle was supplied by this branch on contrast echocardiography. Neat ethanol (1–1.5mL) was administered down the relevant branch with the OTW balloon inflated (to 10 atm) for 5 min before being deflated. Patients were monitored with telemetry in hospital for a further 24 hours and underwent Holter monitoring at 6 months post procedure, with clinical review at 3, 6 and 12 months.

### 2.4. Procedural details

In Patient 1 the earliest site on endocardial and coronary sinus mapping was identified at the mid-septum, but was only 5 ms pre-VPC QRS onset. The ablation catheter was left at this site as a radiographic marker. During intracoronary mapping, the first two septal perforators were not significantly early to the onset of the VPC. However, when the BMW guidewire was advanced into the 3rd septal perforator, ventricular tachycardia (VT) was induced with an excellent match to the clinical VPC. The unipolar electrogram was 25 ms pre-QRS onset with a QS morphology suggesting activation away from this site (Fig. 1). With the 1.25 × 8mm OTW balloon inflated, 5mL of cold saline injected through the balloon terminated VT. Upon deflation of the balloon and rewarming, VT recommenced and further cold saline again terminated VT. Pace mapping from the guidewire in the 3rd septal perforator gave a good match to the clinical VPC (Fig. 1). Prior to ethanol administration agitated gelo-plasma through the balloon highlighted only one segment of the LV in the mid-interventricular septum on contrast transthoracic echocardiography. With the balloon inflated, ethanol (1mL) was injected with transient ST elevation in V2 and V3. After ethanol administration the ST elevation resolved, VPCs



**Fig. 2.** Patient 2 procedure 2: left panel sinus rhythm and ventricular premature contraction morphology (VPC); middle panel VPC with intracoronary wire in proximal septal branch, note QS morphology of unipolar electrogram from wire is (50 ms) early to QRS onset; right panel shows pace-map from proximal septal perforator; inset representative wire position on coronary angiogram with ablator at earliest endocardial site.



**Fig. 3.** Electroanatomical mapping of the right and left ventricle for patient 1 (the blue sphere represents the earliest activation point and as shown in electrogram is only just (5 ms) pre QRS onset). The figure on the right depicts coronary sinus venogram with ablator at the early site.

were no longer identified and repeat angiography revealed a truncated 3rd septal perforator. The day following the procedure,

VPCs had not been detected on telemetry and repeat transthoracic echocardiography showed normal LV function. On repeat Holter

monitor six months post procedure no VPCs were identified and on clinical follow-up the patient has been asymptomatic.

In patient 2 activation mapping of the VPCs from the endocardium and within the coronary sinus revealed an earliest site in approximation to the bundle of His. However, it was only just on time with the VPC QRS onset. Coronary angiography showed normal coronary arteries and intracoronary mapping was performed. The VPC electrograms from the second septal perforator were 15 ms pre-VPC QRS onset. After inflation of the OTW balloon, 1.5mL of ethanol was injected down this branch and the balloon was left inflated for 5 min. Ethanol injection resulted in transient ST elevation in the septal leads and elimination of VPCs. The patient represented with ventricular ectopy of the same morphology within 48 hours and underwent a further EPS and intra-coronary mapping. During this procedure, when the BMW guidewire was passed down the first septal perforator, VT with a morphology identical to the clinical VPC was induced. The unipolar electrogram had a QS morphology and VT was terminated by cold saline injected down the inflated OTW balloon (Fig. 2). Pace mapping revealed a good match to the clinical ectopic (Fig. 2). After contrast injection confirmed balloon occlusion, 1.5mL of ethanol was injected and the balloon was left inflated for 5 minutes, causing transient ST elevation in the septal leads. The patient had no further ectopy and was discharged the following day. At follow-up of 16 months the patient has had no further ventricular ectopy on clinical review or Holter monitoring.

### 3. Discussion

#### 3.1. Ventricular premature contractions

A high burden of VPCs may be associated with incident reduction in left ventricular function, congestive heart failure and increased mortality [2]. Consensus guidelines recommend catheter ablation of VPCs should be considered for patients who are highly symptomatic or where a high VPC burden (at least 10% on 24hour monitoring) is associated with a reduction in ejection fraction [1]. The two patients in the present study had preserved left ventricular function despite a high burden of ventricular ectopy. The risk of VPC-induced cardiomyopathy does not have a linear relationship with VPC burden. We hypothesise that the septal site of origin (and accordingly narrow QRS duration) may in part explain the preserved ventricular function in the present study. Although 74–100% of patients are reported to have elimination of VPCs with ablation, the success rate is reduced where the VPC origin has an epicardial coronary venous origin [1] and is probably further reduced in patients with an intramural focus. The reduced success of ablation for intramural VPCs is reflected in this series as both patients had undergone failed endocardial and epicardial ablation procedures prior to ethanol ablation.

#### 3.2. Ethanol ablation

More than thirty years ago Brugada and colleagues demonstrated the utility of transcatheter ethanol ablation for patients with ventricular tachycardia. While there have been reports of ethanol ablation for VPCs in the setting of compromised LV function [5], we are unaware of a series of patients with VPCs in the setting of normal ventricular function who have required ethanol ablation due to severe symptoms coupled with an intramural VPC source.

Both of our patients had trialled multiple medications to suppress the VPCs, and this is in keeping with studies suggesting only 10–15% of patients will have >90% suppression of VPCs with medications alone [1].

#### 3.3. Success of ethanol ablation

Neither patient in the present report has had a recurrence of VPCs at follow-up of 6 and 16 months after one and two procedures respectively off anti-arrhythmic medication. Kumar et al. reported a series of 46 patients with ventricular arrhythmias where ethanol ablation was attempted (including 8 patients unsuitable for the procedure who did not receive ethanol ablation), noting that a majority of these procedures were for ventricular tachycardia [5]. The 12-month freedom from ventricular arrhythmia in that series after ethanol ablation of ventricular tachycardia was 82%. The success of ethanol ablation is dependent on identifying the perforator supplying the ectopic focus, and is well reflected in this report as the 2nd patient had an initially unsuccessful ethanol ablation procedure as the incorrect septal perforator was identified with wire mapping at first procedure.

#### 3.4. Risks of ethanol ablation

Permanent AV block has been reported in the initial reports identifying the role of this technique for treatment of ventricular tachycardia, and may occur even without prolongation of the AH interval on cold saline injection [4]. In the series by Kumar et al. 32% of patients experienced a complication, with the majority being AV block (18%), and single cases of contrast nephropathy, stroke, cholesterol embolization, hypotension requiring balloon pump and coronary vasospasm; there was one procedure related death (2.8%) [5]. Due to the significant risks of ethanol ablation the procedure should be reserved for the most symptomatic patients who have undergone unsuccessful endocardial and/or epicardial ablation.

### 4. Conclusion

Symptomatic ventricular premature contractions associated with preserved ventricular function are amenable to intracoronary ethanol ablation where attempts to map and ablate the focus from the endocardium and epicardium have been unsuccessful and suggest an intramural focus.

#### Funding sources

Dr McLellan is the recipient of a European Heart Rhythm Association/Asia Pacific Heart Rhythm Society Fellowship, an Endeavour fellowship from the Australian government and has received research support from St Jude Medical. All other authors have reported no financial relationships to disclose.

#### References

- [1] Pedersen CT, Kay GN, Kalman J, Borggrefe M, Della-Bella P, Dickfeld T, et al. EHRA/HRS/APHS expert consensus on ventricular arrhythmias. *Heart Rhythm* 2014;11:e166–196.
- [2] Dukes JW, Dewland TA, Vittinghoff E, Mandyam MC, Heckbert SR, Siscovick DS, et al. Ventricular ectopy as a predictor of heart failure and death. *J Am Coll Cardiol* 2015;66:101–9.
- [3] Yokokawa M, Jung DY, Hero III AO, Baser K, Morady F, Bogun F. Single- and dual-site pace mapping of idiopathic septal intramural ventricular arrhythmias. *Heart Rhythm* 2016;13:72–7.
- [4] Segal OR, Wong T, Chow AW, Jarman JW, Schilling RJ, Markides V, et al. Wyn Davies D: intra-coronary guidewire mapping—a novel technique to guide ablation of human ventricular tachycardia. *J Interv Card Electrophysiol* 2007;18:143–54.
- [5] Kumar S, Barbhuiya CR, Sobieszczyk P, Eisenhauer AC, Couper GS, Nagashima K, et al. Role of alternative interventional procedures when endo- and epicardial catheter ablation attempts for ventricular arrhythmias fail. *Circ Arrhythm Electrophysiol* 2015;8:606–15.