

REVIEW

Factors associated with invasive fungal sinusitis in patients with COVID-19: A systematic review and single-center case series

Maggie R. Donovan¹  | Amar Miglani MD² | Devyani Lal MD²  |
Michael J. Marino MD² 

¹University of Arizona College of Medicine, Phoenix, Arizona, USA

²Department of Otorhinolaryngology—Head and Neck Surgery, Mayo Clinic College of Medicine, Phoenix, Arizona, USA

Correspondence

Michael J. Marino, Department of
Otorhinolaryngology at Mayo Clinic Hospital,
5777 E. Mayo Blvd. Phoenix, AZ 85054, USA.
Email: marino.michael@mayo.edu

Abstract

Objective: Invasive fungal sinusitis (IFS) in patients with active or recent COVID-19 have been reported throughout the world. The primary purpose of the systematic review is to describe factors associated with IFS in patients with COVID-19. The goal of the case series was to also characterize these factors in addition to evaluating the incidence of IFS at our institution after the onset of the pandemic.

Methods: A systematic review using the preferred reporting in systematic reviews and meta-analyses (PRISMA) framework identified publications of IFS cases associated with COVID-19 (IFSAC). Search terms were “COVID-19,” “invasive,” “fungal,” and “sinusitis.” IFS cases were evaluated for COVID-19 status, fungal etiology, comorbidities, treatment, and outcome. A case series of patients at our center with IFS between December 1, 2018 to March 31, 2020 (“pre-covid”) and April 1, 2020 to August 1, 2021 (“post-covid”) was also performed with the above parameters.

Results: Fourteen studies totaling 206 cases of IFSAC were identified. Most cases came from India (140/206, 68.0%), followed by Egypt (62/206, 30.1%), and North America (4/206, 1.9%). Diabetes was the most common comorbidity (151/206, 73.3%). Recent or prolonged steroid use was noted in 65.0% of cases (134/206). In our series, five pre-covid and four post-covid cases were identified. One had recent COVID-19 infection. Acute myeloid leukemia was the most common pre-covid comorbidity (3/5, 60.0%). Diabetes was the most frequent post-covid comorbidity (2/4, 50.0%). Chronic steroid usage was noted in two pre-covid and one post-covid cases.

Conclusion: Diabetes and steroid use are common factors in reported cases of IFSAC. IFS incidence in our case series did not change appreciably after the onset of the pandemic.

Poster Presentation: American Rhinologic Society Meeting at COSM in April 2022

This is an open access article under the terms of the [Creative Commons Attribution-NonCommercial-NoDerivs](https://creativecommons.org/licenses/by-nc-nd/4.0/) License, which permits use and distribution in any medium, provided the original work is properly cited, the use is non-commercial and no modifications or adaptations are made.

© 2022 The Authors. *Laryngoscope Investigative Otolaryngology* published by Wiley Periodicals LLC on behalf of The Triological Society.

Level of Evidence: 4.

KEYWORDS

coronavirus, corticosteroids, COVID-19, diabetes, invasive fungal sinusitis, mucormycosis, otolaryngology, pandemic, review, SARS-CoV-2

1 | INTRODUCTION

Invasive fungal sinusitis (IFS) is an aggressive, rare infection that usually occurs in immunocompromised individuals. Overall mortality attributed to acute IFS is estimated at about 50%.¹

Multiple cases of IFS in patients with recent or active coronavirus disease 2019 (COVID-19) have been reported around the globe.²⁻¹⁵ Characteristics of patients with IFS associated with active or recent COVID-19 illness (IFSAC) have not been thoroughly defined. The primary aim of this systematic review was to elaborate on common host factors observed in IFSAC among reported cases. Secondary aims of this review were to describe the etiology, treatments, outcomes, and geographical distribution of IFSAC cases. These objectives may assist in identifying potential risk factors of IFSAC and aid physicians in understanding its typical presentation. Additionally, a case series of patients with IFS treated at our institution was included to investigate any significant change in the incidence of IFS during the COVID-19 pandemic compared to an equal time period before the pandemic.

2 | MATERIALS AND METHODS

2.1 | Systematic review

A systematic review of IFSAC in the published literature was performed according to the preferred reporting in systematic review and meta-analyses (PRISMA) framework.¹⁶ Publications were evaluated for COVID-19 status, fungal etiology, comorbidities, treatment, and patient outcome. Case reports, case series, and case-control studies that reported original data on IFSAC were incorporated. Publications that only reviewed literature on the topic or did not include cases of IFS with recent or concurrent COVID-19 were excluded. In publications that had cases of IFS pre-covid and post-covid, only cases that were associated with COVID-19 illness were included in the final systematic review while the pre-covid cases were excluded.

A systematic search of PubMed, Elsevier, and Cochrane COVID-19 Study Registrar databases was performed on August 17, 2021. The search included all publications in the English language that contained the terms “COVID-19,” “invasive,” “fungal,” and “sinusitis.” Two reviewers independently screened and reviewed publications from the search. Abstracts were reviewed for the forementioned eligibility criteria, and duplicated publications were removed. All abstracts that met the eligibility criteria underwent full-text reviews. Publications were removed if upon full-text review they did not meet the eligibility criteria. Additional publications not found in the initial search were

also identified by a manual screening of the reference lists of the studies that underwent full-text reviews.

Data were extracted from the source publications by using a standardized template. The origin of the publication, IFS etiologies, comorbidities, patient COVID-19 status, IFS treatments, COVID-19 therapies, surgical debridements, and patient outcome were recorded when available. Two reviewers performed the data collection. These reviewers also independently reviewed studies for risk of bias, and conflicts were resolved with consensus discussion. A level of evidence and methodological index for non-randomized studies (MINORS) score was determined for all included publications to provide an overall estimate of strength for each study design.

2.2 | Case series

The study design of this case series was submitted to the international review board (IRB) committee at our institution and was determined to be an exempt study (Mayo Clinic IRB 21-008726). A retrospective review of patients who presented to our institution with a diagnosis of IFS was performed. Patients were identified using the Advanced Text Explorer (ATE), a natural language processing tool hosted by Mayo Clinic. The search terms included “invasive,” “fungal,” and “sinusitis,” all joined by the Boolean operator “AND.” The search was performed on August 2, 2021 for medical records entered on December 1, /2018 or after. Medical records were reviewed manually to confirm the diagnosis of invasive fungal sinusitis. Any charts that did not confirm the diagnosis of IFS via histopathology were excluded. Patients diagnosed with IFS at our center between December 1, 2018 and March 31, 2020 were grouped into the “pre-covid” cohort. Diagnoses of IFS made between April 1, 2020 and August 1, 2021 were grouped into the “post-covid” cohort. IFS etiologies, comorbidities, patient COVID-19 status, IFS treatments, COVID-19 therapies, surgical debridements, and patient outcome were extracted from the medical records when available.

3 | RESULTS

3.1 | Systematic review

A total of 79 articles were identified using the defined search methods of the PubMed, Elsevier, and Cochrane databases. Of these, 10 articles were identified as duplicates among the databases and removed. Title and abstract reviews subsequently identified 15 articles for full-text

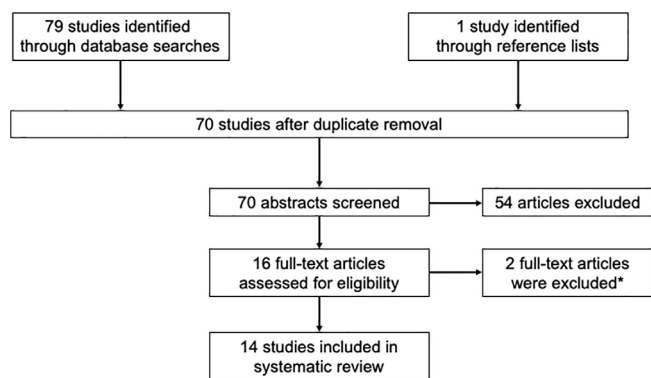


FIGURE 1 PRISMA flow diagram of article selection process.

*One article was eliminated for being a literature review on imaging findings in COVID-19-associated IFS. The other article was eliminated for not clarifying whether RT-PCR confirmed the suspected diagnosis of COVID-19.

review. An additional study was identified for inclusion from the reference lists of the articles when performing full-text reviews. Fourteen studies from these publications were determined to meet the stated search criteria (Figure 1).

The studies included in the systematic review are briefly summarized in Table 1.²⁻¹⁵ A total of 244 cases of IFS were noted from these 14 studies; however, 38 cases were not included in the final analysis as they were not associated with active or recent COVID-19 illness, leaving a total of 206 cases of IFS for analysis. Most cases came from India (140/206, 68.0%), followed by Egypt (62/206, 30.1%), and North America (4/206, 1.9%). Diabetes was the most common comorbidity identified (151/206, 73.3%) followed by hypertension (70/206, 34.0%). Only 1.5% (3/206) cases reported a history of cancer, including one patient with leukemia. Recent or prolonged steroid use was noted in 65.0% (134/206) either for COVID-19 management or treatment of a comorbidity. For IFS management, 61.2% (126/206) of cases reported amphotericin B therapy, 15.5% (32/206) cases reported azole antifungal agents, and 33.0% (68/206) did not report on whether azole or amphotericin therapies were utilized. Approximately 59.2% (122/206) cases involved surgical debridements while 33.0% (68/260) cases did not note whether debridements were performed. Most patients either survived (77/206, 37.4%) or were still being followed and treated (37/206, 18.0%) at the time of publication. About a fourth of patients were reported deceased (51/206, 24.8%) and 19.9% (41/206) had no outcome mentioned. One of the deceased patients was noted to pass away from myocarditis after initially improving from IFS treatment.

The level of evidence and MINORS score were generally low with all included studies either being case reports, series, and one retrospective case-control. The retrospective case-control was the only comparative study between pre-covid and post-covid cases of IFS identified from the systematic review. Assessment of the study design, the level of evidence, and MINORS score for each included article is presented in Table 2.^{2-15,17,18}

3.2 | Case series

A retrospective review of the patients in our institution meeting inclusion criteria for a confirmed diagnosis of IFS identified nine patients (seven men and two women, with a mean age of 46.2 years; Table 3). Of these nine, five patients were determined to be pre-covid and four as post-covid cases. One patient had a recent history of COVID-19 with confirmed testing about a week prior to presentation with IFS. History of acute myeloid leukemia (AML) was the most common pre-covid co-morbidity (3/5, 60.0%), while diabetes was the most frequent post-covid co-morbidity (2/4, 50.0%). Chronic steroid usage was noted in two pre-covid and one post-covid cases. The underlying fungal etiology was most commonly *Rhizopus* in both groups (4/5 pre-covid, 3/4 post-covid), with *Aspergillus* sp. observed in one pre-covid and one post-covid case. Amphotericin therapy was provided in all nine patients. Surgical debridements were performed in seven cases at our institution while one patient elected to not pursue surgical treatment and the other patient having underwent prior surgical intervention at an outside hospital. Four pre-covid cases survived, and one pre-covid case died. Of the post-covid patients, one survived and three passed away. Two of the post-covid deaths were related to IFS, one of which was the case of recent COVID-19 illness. The third post-covid death was related to AML, occurring several months after initial recovery from two surgical debridements.

4 | DISCUSSION

Acute IFS is a rare but deadly infection that mainly affects individuals with immunocompromising conditions or on chronic immunosuppressive therapies. With the current pandemic, many cases of IFSAC have been reported with most literature originating from India and Egypt. Identifying factors associated with IFSAC may assist physicians in prompt diagnosis and recognition of these cases.

In the present systematic review, the most common condition among patients with IFSAC was diabetes, while a surprisingly low number of patients with hematologic malignancies was noted. Literature has demonstrated that both diabetes and hematologic malignancies are common immunocompromising diseases in patients with IFS.¹⁹⁻²³ A large systematic review including 807 patients with acute IFS estimated the prevalence of diabetes to be about 48% and that of hematologic malignancy to be 39%.¹ However, the prevalence of diabetes was substantial in our target population (73.3%) especially when compared to hematologic malignancy (1.5%) and any other condition, suggesting that these recent reports of IFSAC are mainly affecting diabetic patients.

Another common comorbidity identified in our systematic review was recent or prolonged steroid use, with more than half of the cases mentioning steroid therapy. Corticosteroids have also been established as a risk factor for IFS.^{21,22} Potent steroid therapy is still a common practice for COVID-19 illness, especially severe cases.²⁴ This is at the risk of the well-known consequence of hyperglycemia with steroid therapies, especially concerning for patients with diabetes and

TABLE 1 Summary of the 14 studies included in the systematic review

| Study | Origin of study | No. of cases | Fungal etiology | No. with DM ^a | No. with steroid tx ^b | No. with antifungal tx | No. with SD | Outcome |
|---------------------|-----------------|-----------------|---|--------------------------|----------------------------------|------------------------|-------------|---|
| Kumari et al. | India | 20 | 20 Mucorales or. | 16 | 16 | 20 | 20 | 8 survived 6 ongoing care 6 deceased |
| Mishra et al. | India | 32 | 29 Mucorales or. 3 N.R. | 28 | 30 | 32 | 30 | 5 survived 23 ongoing care 4 deceased |
| Nehara et al. | India | 5 | 5 Mucorales or. | 5 | 4 1 N.R. | 5 | 1 | 1 survived 2 ongoing care 2 deceased |
| Ismail et al. | Egypt | 18 ^c | 10 Mucorales or. 6 Aspergillus sp. 2 N.R. | 8 | 7 | N.R. | N.R. | N.R. |
| Sharma et al. | India | 23 | 23 Mucorales or. | 21 | 23 | 23 | 23 | N.R. |
| Dallalzedeh et al. | USA | 2 | 1 Mucorales or. 1 N.R. | 2 | 2 | 2 | 0 | 2 deceased |
| Desai et al. | India | 50 | 50 Mucorales or. 3 Aspergillus sp. | 41 | 42 | N.R. | N.R. | 35 survived 15 deceased |
| Waisel-Haiat et al. | MX | 1 | 1 Mucorales or. | 1 | N.R. | 1 | 0 | 1 deceased |
| Sebastion et al. | India | 3 | 3 Mucorales or. 1 Aspergillus sp. | 3 | 3 | 2 | 1 | 3 deceased |
| Ashour et al. | Egypt | 8 | 6 Mucorales or. 1 Aspergillus sp. 1 N.R. | 8 | N.R. | 7 1 N.R. | 6 | 5 survived 3 deceased |
| El-Kholy et al. | Egypt | 36 | 28 Mucorales or. 11 Aspergillus sp. | 10 | N.R. | 36 | 34 | 23 survived 13 deceased |
| Mehta et al. | India | 1 | 1 Mucorales or. | 1 | 1 | 1 | 0 | 1 deceased |
| Winn et al. | USA | 1 | 1 Mucorales or. | 1 | 1 | 1 | 1 | 1 deceased |
| Sen et al. | India | 6 | 5 Mucorales or. 1 N.R. | 6 | 5 | 6 | 6 | 6 ongoing care |

Abbreviations: DM, diabetes mellitus; MX, Mexico; No., number; N.R., not reported; or., order; SD, surgical debridement; tx, treatment.

^aCo-morbidities not listed above include but not limited to hematologic malignancies, hypertension, kidney disease, liver disease, cardiac disease, and prostate cancer.

^bSpecific to chronic and/or recent use of steroid therapies.

^cTotal of 56 patients in study, 18 were post-covid with confirmed COVID-19 diagnosis. Other 38 patients were pre-covid and thus not included in the systematic review case analysis.

TABLE 2 Study design and level of evidence for studies included in the systematic review^a

| Study | Study design | Level of evidence ¹⁷ | MINORS ¹⁸ |
|---------------------|--------------|---------------------------------|----------------------|
| Kumari et al. | Case series | 4 | 10/16 |
| Mishra et al. | Case series | 4 | 12/16 |
| Nehara et al. | Case series | 4 | 11/16 |
| Ismail et al. | Case-control | 4 | 16/24 |
| Sharma et al. | Case series | 4 | 11/16 |
| Dallalzedeh et al. | Case series | 4 | 9/16 |
| Desai et al. | Case series | 4 | 12/16 |
| Waisel-Haiat et al. | Case report | 5 | 10/16 |
| Sebastion et al. | Case series | 4 | 9/16 |
| Ashour et al. | Case series | 4 | 10/16 |
| El-Kholy et al. | Case Series | 4 | 12/16 |
| Mehta et al. | Case report | 5 | 10/16 |
| Winn et al. | Case report | 5 | 10/16 |
| Sen et al. | Case series | 4 | 12/16 |

Abbreviation: MINORS, methodological index for non-randomized studies.

^aAll 14 publications were assessed using the Oxford 2009 Levels of Evidence¹⁷ criteria and the MINORS criteria.¹⁸

pre-diabetes. Steroid-induced hyperglycemia can even progress into diabetic ketoacidosis (DKA), which was observed in at least two of the cases involved in the systematic review.^{7,25} Furthermore, variations in steroid dosing has been reported during the pandemic, which may lead to certain populations having a greater risk of incurring IFSAC.^{26,27} Overall, these findings support that the well-established IFS risk factors of diabetes and prolonged steroid therapy are frequently present in the subset of IFSAC.

Recent publications have also suggested the significant interplay between corticosteroid treatment of COVID-19 in diabetic patients and IFS. A study published out of India found that among 46 patients with COVID-19 and IFS, about 96% percent had diabetes and approximately 89% percent had recent history of steroid use.²⁸ Another publication from Bangalore, India similarly found that 16 of 18 patients with maxillofacial and rhino-cerebro-orbital fungal infections were given steroids for COVID-19 treatment. Of these 16 patients, 15 had a known history of diabetes, suggesting a strong association with steroid usage in diabetic patients with COVID-19 and angioinvasive maxillofacial fungal infections.²⁹ A systematic review on 101 cases of COVID-19 and mucormycosis, not limited to rhino-cerebral sinusitis but also including pulmonary and gastro-intestinal cases, found that 80% of reported cases had diabetes and approximately 76% had received corticosteroids.³⁰ More recently, Bhattacharyya et al. performed a systematic review and meta-analysis that identified diabetes in 79% of COVID-19-associated rhino-orbital-cerebral mucormycosis. Further, 86% of the patients included in that study were reported to be on corticosteroids for the treatment of COVID-19.³¹

In our case series, we noted diabetes in two of the four post-covid patients with only one of these patients having IFS associated with COVID-19 illness. This IFSAC case was not associated with known steroid therapy; however, this patient did present with uncontrolled diabetes in DKA. At our institution, we also did not note a

substantial change in the incidence of IFS cases between the pre-covid versus the post-covid periods. It is important to note that our series is limited by a small sample size and only one case of confirmed IFSAC. Further, there is a lack of literature directly studying the incidence of IFS after the onset of the pandemic, making it difficult to confirm our findings regarding incidence with other reports. Ismail et al.'s publication was the only study from our systematic review that compared IFSAC to IFS cases prior to the pandemic at their institution in Egypt. They did find a significantly higher number of IFS cases in their COVID-19 group as well as a higher number of patients with diabetes in their COVID-19 cohort.⁵ Yet, the validity of these results is again difficult to assess without other comparative cohort studies in the current literature.

Our study has several principal limitations. First, cases of IFSAC are only discussed in case reports, series, and one retrospective case-control study (Table 2). Although these articles are relatively low levels of evidence, the findings of our systematic review are supported by similar observations in the available literature.²⁸⁻³¹ As stated previously, a second limitation is that none of the publications directly addressed or significantly evidenced any changes in IFS incidence prior to and during the pandemic. We also did not detect a significant change in incidence within our case series, which was limited by a small sample size and only one patient with confirmed IFSAC. A repeat case series with more subjects or, preferably, a national, multicenter study would allow for a larger sample size and assist in identifying potential changes in IFS cases after the onset of the pandemic. Lastly, our study was limited by the data parameters recorded in the available publications. Some parameters, such as antifungal therapies, steroid treatments, associated comorbidities, fungal etiology etc., were not reported in all of the selected articles for the systematic review. Further investigation with longitudinal cohort studies or systematic reviews of higher levels of evidence is needed to confirm our results.

TABLE 3 Case series patient data

| Pre-COVID-19 Patients (n = 5) | | | | | | | |
|--------------------------------|--------|--|---------------------------------------|--|---|-------------------|--------------------------|
| Age (yrs) | Gender | Comorbidities | Fungal etiology | Antifungals | Steroid Tx | No. of SD | Outcome |
| 28 | Male | AML | Mucorales or. Alternaria sp. | Amphotericin Caspofungin Isavuconazole | No | 4 | survived |
| 54 | Female | IBD | Aspergillus sp. | Amphotericin Caspofungin Voriconazole | Prednisone Hydrocortisone inj. (inpatient only) | 1 | survived |
| 22 | Female | AML Chronic Sinusitis | Mucorales or. Bipolaris sp. | Amphotericin Isavuconazole | No | 3 | survived |
| 63 | Male | Liver transplant Skin basal cell carcinoma | Mucorales or. | Amphotericin Posaconazole | Prednisone Methyl-prednisolone | 6 | deceased |
| 60 | Male | HTN, HLD, psoriasis | Mucorales or. | Amphotericin Voriconazole Posaconazole | No | N.R. ^a | survived |
| Post-COVID-19 Patients (n = 4) | | | | | | | |
| 44 ^b | Male | T2DM, DKA during admit, CKD III, HTN, kidney cancer s/p nephrectomy | Mucorales or. | Amphotericin | No | 1 | deceased |
| 69 | Male | Liver transplant, HTN, AFIB | Mucorales or. | Amphotericin Isavuconazole | Prednisone | 2 | survived |
| 20 | Male | AML s/p stem cell transplant | Aspergillus sp. | Amphotericin Voriconazole | No | 2 | deceased, AML-related |
| 56 | Male | T2DM, DKA on admit, ETOH dependence | Mucorales or. | Amphotericin | Prednisone (recent use, not chronic) | 0 | deceased |

Abbreviations: AFIB, atrial fibrillation; AML, acute myeloid leukemia; CKD, chronic kidney disease; DKA, diabetic ketoacidosis; ETOH, alcohol; HLD, hyperlipidemia; HTN, hypertension; IBD, inflammatory bowel disease; inj., injection; T2DM, type 2 diabetes mellitus; No., number; N.R., not reported; or., order; SD, surgical debridement, s/p, status post, sp., species, Tx, treatment; yrs = years.

^aUnclear if surgical debridement at outside hospital, patient did have right maxillectomy performed.

^bConfirmed COVID-19 via RT-PCR less than a week prior to presentation for IFS. No fever or shortness of breath at presentation but reported anosmia and ageusia.

5 | CONCLUSION

During the pandemic, there have been multiple reports of IFS in individuals with recent or concurrent COVID-19. These cases have largely been reported in India and Egypt. Our systematic review suggests that diabetes and prolonged or recent steroid therapy, well-established risk factors of IFS, predominate in the subset of patients with IFSAC. Our case series observed a stable incidence of IFS during the COVID-19 pandemic compared to an equal time period before the pandemic. However, our series' population size was small, and our results cannot be confirmed by the lack of literature on this topic. Further investigation will be needed to define whether these host factors are the main contributors to IFSAC or if the immune sequelae of COVID-19 illness contributes to the risk of IFS. Judicious corticosteroid treatment protocols and glycemic control in patients with COVID-19 and diabetes are likely important considerations for preventing acute IFS in this population.

ORCID

Maggie R. Donovan  <https://orcid.org/0000-0002-6454-6278>

Devyani Lal  <https://orcid.org/0000-0002-7593-2385>

Michael J. Marino  <https://orcid.org/0000-0002-8672-0310>

REFERENCES

- Turner JH, Soudry E, Nayak J, Hwang PH. Survival outcomes in acute invasive fungal sinusitis: a systematic review and quantitative synthesis of published evidence. *Laryngoscope*. 2013;123(5):1112-1118. doi:10.1002/lary.23912
- Kumari A, Rao NP, Patnaik U, et al. Management outcomes of mucormycosis in COVID-19 patients: a preliminary report from a tertiary care hospital. *Med J Armed Forces India*. 2021;77(Suppl 2):S289-S295. doi:10.1016/j.mjafi.2021.06.009
- Mishra Y, Prashar M, Sharma D, Akash KVP, Tilak TVSVGK. Diabetes, COVID 19 and mucormycosis: clinical spectrum and outcome in a tertiary care medical center in Western India. *Diabetes Metab Syndr*. 2021;15(4):102196. doi:10.1016/j.jsx.2021.102196
- Nehara HR, Puri I, Singhal V, Ih S, Bishnoi BR, Sirohi P. Rhinocerebral mucormycosis in COVID-19 patient with diabetes a deadly trio: case

- series from the north-western part of India. *Indian J Med Microbiol*. 2021;39(3):380-383. doi:10.1016/j.ijmmb.2021.05.009
5. Ismaiel WF, Abdelazim MH, Eldsoky I, et al. The impact of COVID-19 outbreak on the incidence of acute invasive fungal rhinosinusitis. *Am J Otolaryngol*. 2021;42(6):103080. doi:10.1016/j.amjoto.2021.103080
 6. Sharma S, Grover M, Bhargava S, Samdani S, Kataria T. Post coronavirus disease mucormycosis: a deadly addition to the pandemic spectrum. *J Laryngol Otol*. 2021;135(5):442-447. doi:10.1017/S0022215121000992
 7. Dallalzadeh LO, Ozzello DJ, Liu CY, Kikkawa DO, Korn BS. Secondary infection with rhino-orbital cerebral mucormycosis associated with COVID-19. *Orbit (London)*. 2021;1-4. doi:10.1080/01676830.2021.1903044
 8. Desai SM, Gujarathi-Saraf A, Agarwal EA. Imaging findings using a combined MRI/CT protocol to identify the "entire iceberg" in post-COVID-19 mucormycosis presenting clinically as only "the tip.". *Clin Radiol*. 2021;76(10):784.e27-784.e33. doi:10.1016/j.crad.2021.07.002
 9. Waizel-Haiat S, Guerrero-Paz JA, Sanchez-Hurtado L, Calleja-Alarcon S, Romero-Gutierrez L. A case of fatal rhino-orbital mucormycosis associated with new onset diabetic ketoacidosis and COVID-19. *Cureus*. 2021;13(2):e13163. doi:10.7759/cureus.13163
 10. Sebastian SK, Kumar VB, Gupta M, Sharma Y. Covid Associated invasive fungal sinusitis. *Indian J Otolaryngol Head Neck Surg*. 2021;1-4. doi:10.1007/s12070-021-02471-6
 11. Ashour M, Abdelaziz T, Ashour D, Askoura A, Saleh MI, Mahmoud M. Imaging spectrum of acute invasive fungal rhino-orbital-cerebral sinusitis in COVID-19 patients: a case series and a review of literature. *J Neuroradiol*. 2021;48(5):319-324. doi:10.1016/j.neurad.2021.05.007
 12. El-Kholy NA, El-Fattah AMA, Khafagy YW. Invasive fungal sinusitis in post COVID-19 patients: a new clinical entity. *Laryngoscope*. 2021;13(12):2652-2658. doi:10.1002/lary.29632
 13. Mehta S, Pandey A. Rhino-orbital Mucormycosis associated with COVID-19. *Cureus*. 2020;12(9):e10726. doi:10.7759/cureus.10726
 14. Mekonnen ZK, Ashraf DC, Jankowski T, et al. Acute invasive rhino-orbital mucormycosis in a patient with COVID-19-associated acute respiratory distress syndrome. *Ophthalmic Plast Reconstr Surg*. 2021;37(2):e40-e42.
 15. Sen M, Lahane S, Lahane TP, Parekh R, Honavar SG. Mucor in a viral land: a tale of two pathogens. *Indian J Ophthalmol*. 2021;69(2):244-252. doi:10.4103/ijo.IJO_3774_20
 16. Liberati A, Altman DG, Tetzlaff J, et al. The PRISMA statement for reporting systematic reviews and meta-analyses of studies that evaluate healthcare interventions: explanation and elaboration. *BMJ*. 2009;339:b2700. doi:10.1136/bmj.b2700
 17. Centre for Evidence-Based Medicine. The Oxford 2009 levels of evidence. <http://www.cebm.net/oxford-centreevidence-based-medicine-levels-evidence-march-2009/>. 2021.
 18. Arem Lim KS, Mile Ini EN, Amien Orestier DF, et al. Methodological index for non-randomized studies (minors): development and validation of a new instrument. *ANZ J Surg*. 2003;73(9):712-716. doi:10.1046/j.1445-2197.2003.02748.x
 19. Bakhshae M, Bojdi A, Allahyari A, et al. Acute invasive fungal rhinosinusitis: our experience with 18 cases. *Eur Arch Otorhinolaryngol*. 2016;273(12):4281-4287. doi:10.1007/s00405-016-4109-z
 20. Drakos P, Nagler A, Or R, et al. Invasive fungal sinusitis in patients undergoing bone marrow transplantation. *Bone Marrow Transplant*. 1993;12(3):203-208.
 21. Parikh SL, Venkatraman G, Delgaudio JM. Invasive fungal sinusitis: a 15-year review from a single institution. *Am J Rhinol*. 2004;18(2):75-81.
 22. Payne SJ, Mitzner R, Kunchala S, Roland L, McGinn JD. Acute invasive fungal rhinosinusitis: A15-year experience with 41 patients. *Otolaryngol Head Neck Surg*. 2016;154(4):759-764. doi:10.1177/0194599815627786
 23. Monroe MM, McLean M, Sautter N, et al. Invasive fungal rhinosinusitis: a 15-year experience with 29 patients. *Laryngoscope*. 2013;123(7):1583-1587. doi:10.1002/lary.23978
 24. Raju RVP, Biatris PS. J. SJUC. Therapeutic role of corticosteroids in COVID-19: a systematic review of registered clinical trials. *Futur J Pharm Sci*. 2021;7(1):67. doi:10.1186/s43094-021-00217-3
 25. Tamez-Pérez HE, Quintanilla-Flores DL, Rodriguez-Gutierrez R, Gonzalez-Gonzalez J. Steroid hyperglycemia: prevalence, early detection and therapeutic recommendations: a narrative review. *World J Diabetes*. 2015;6(8):1073-1081. doi:10.4239/wjcd.v6.i8.1073
 26. Jagiasi B, Nasa P, Chanchalani G, et al. Variation in therapeutic strategies for the management of severe COVID-19 in India: a nationwide cross-sectional survey. *Int J Clin Pract*. 2021;75(10):e14574. doi:10.1111/ijcp.14574
 27. Juneja D, Jain R, Singh O. Practice pattern of critical care physicians in India for use of corticosteroids in COVID-19. *J Assoc Physicians India*. 2021;69(5):50-55.
 28. Pradhan P, Shaikh Z, Mishra A, et al. Predisposing factors of rhino-orbital-cerebral mucormycosis in patients with COVID 19 infection. *Indian J Otolaryngol Head Neck Surg*. 2021;1-7. doi:10.1007/s12070-021-02875-4
 29. Moorthy A, Gaikwad R, Krishna S, et al. SARS-CoV-2, uncontrolled diabetes and corticosteroids: an unholy trinity in invasive fungal infections of the maxillofacial region? A retrospective, multi-centric analysis. *J Maxillofac Oral Surg*. 2021;20(3):418-425. doi:10.1007/s12663-021-01532-1
 30. Singh AK, Singh R, Joshi SR, Misra A. Mucormycosis in COVID-19: a systematic review of cases reported worldwide and in India. *Diabetes Metab Syndr*. 2021;15(4):102146. doi:10.1016/j.dsx.2021.05.019
 31. Bhattacharyya A, Sarma P, Kaur H, Kumar S, Bhattacharyya J, Prajapat M. COVID-19-associated rhino-orbital-cerebral mucormycosis: a systematic review, meta-analysis, and meta-regression analysis. *Indian J Pharmacol*. 2021;53(6):499-510.

How to cite this article: Donovan MR, Miglani A, Lal D, Marino MJ. Factors associated with invasive fungal sinusitis in patients with COVID-19: A systematic review and single-center case series. *Laryngoscope Investigative Otolaryngology*. 2022;7(4):913-919. doi:10.1002/lio2.833