

Received: 2010.02.19
Accepted: 2010.03.16

MRI diagnosis of diastematomyelia in a 78-year-old woman: Case report and literature review

Urszula Zaleska-Dorobisz¹, Joanna Bladowska¹, Anna Biel¹, Leszek W. Pałka², Daniel Hołownia¹

¹ Department of Radiology, Wrocław Medical University, Wrocław, Poland

² Private Medical Practice, Wrocław, Poland

Author's address: Urszula Zaleska-Dorobisz, Department of Radiology, Wrocław Medical University, Marii Skłodowskiej-Curie 58 Str., Wrocław, Poland, e-mail: ulador@rad.am.wroc.pl

Summary

Background:

Diastematomyelia is a rare congenital malformation of the spinal cord, which belongs to the group of occult spinal dysraphisms. This disorder consists in the separation of the spinal cord into two parts in the sagittal plane (hemicords). Diastematomyelia may coexist with other spinal dysraphisms, such as myelomeningocele, meningocele, spinal lipoma, neuroenteric cysts or dermal sinuses and vertebral abnormalities, such as hemivertebrae, butterfly vertebrae or scoliosis.

Case Report:

We reported a case of a woman with a congenital defect of the spinal cord, in the form of diastematomyelia, which was diagnosed at the age of 78. The patient had been complaining of back pain for many years. The X-ray radiograms showed the fusion of vertebra L3–L4, defective fusion of posterior spinal bony elements L5–S1. Moreover, abnormal hair growth (hypertrichosis) in the lumbar region was found. The separation of the spinal cord was only diagnosed in MR imaging which was performed at the age of 78.

Conclusions:

Diastematomyelia is mostly diagnosed in the prenatal period or in children; much less often in adults. This disorder has to be taken into account in differential diagnosis in patients with X-rays revealing defects of the spine in the form of hemivertebrae, butterfly vertebrae or the fusion of vertebrae, especially when there are additional skin lesions in the back area, at the level of the diagnosed osseous anomalies.

Key words:

diastematomyelia • spinal dysraphism • hypertrichosis • MRI

PDF file:

<http://www.polradiol.com/fulltxt.php?ICID=878521>

Background

Diastematomyelia is a rare dysraphic lesion of the spinal cord in which a part of the spinal cord is split in the sagittal plane into two hemicords [1–3]. Each of them includes the central canal, one dorsal and one ventral root. The splitting of the cord is caused by the presence of an osseous or a fibrocartilaginous septum. The defect is a result of an incorrect development of the notochord between the 15th and the 18th day of pregnancy [1–3].

Diastematomyelia may be accompanied by other spinal dysraphisms, such as myelomeningocele, meningocele, spinal lipoma, neuroenteric cysts or dermal sinus, as well as congenital defects of the spine, including hemivertebrae,

butterfly vertebrae, and scoliosis [1,2,4,5]. This malformation may also be accompanied by abnormalities of internal organs – kidneys, anus or reproductive organs [4]. Most authors believe that cases of an isolated diastematomyelia are connected with better prognosis [1,3,4].

We reported a case of a woman with a congenital defect of the spinal cord, in the form of diastematomyelia, which was diagnosed at the age of 78 years.

The literature presents multiple cases of diastematomyelia revealed in the prenatal period by means of USG and confirmed by MRI [1,4,6,7]. Most patients with a diagnosed diastematomyelia are children under the age of 7 [5]. In adult patients, such a spinal abnormality is diagnosed

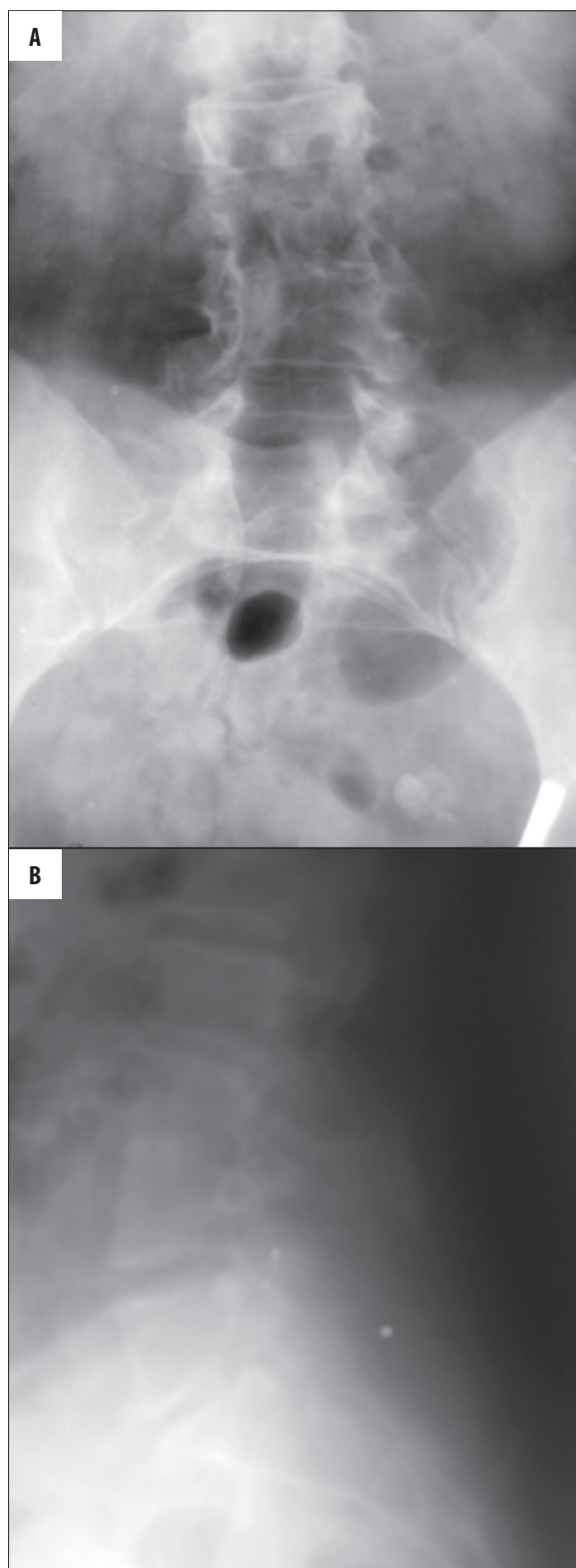


Figure 1. X-ray of the lumbar spine: anterior-posterior plane (A), lateral plane (B). Scoliosis, partial fusion of the L3–L4 bodies, and defective fusion of posterior spinal bony elements within L5–S1.

less frequently [8,9]. The available literature does not report any cases of diastematomyelia diagnosed at such an

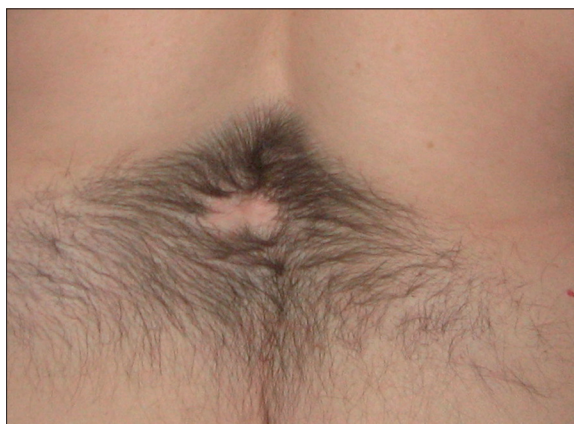

Figure 2. Picture of the lumbar region. Hypertrichosis of „faun tail” type.

advanced age and the oldest described patient was 44 years old when she was diagnosed with diastematomyelia [8].

Case Report

The 78-year-old woman, experiencing back pain for many years, presented for diagnostic procedures. Her first pain symptoms within the sacrolumbar spine appeared when she turned 30. The first diagnostic examination was an X-ray of the sacrolumbar back, performed 7 years after the first pain symptoms. The X-rays showed degenerative lesions of the lower lumbar vertebrae. There was also a fusion of the 3rd and 4th lumbar vertebrae and a flattening of the L3 vertebral body.

Due to persisting and periodically aggravating pain at the age of 46, the patient underwent another X-ray of the spine, revealing an incomplete fusion of the L3–L4 vertebrae and a defective closure of the vertebral arches from L5 to S1 (Figure 1A,B). The patient reported a significant increase in pain intensity on reaching 50 years of age. In the following years, she was undergoing only control X-rays of the L-S spine, which showed degenerative lesions and discopathies with a chronic pain syndrome of the spine.

Family history: Healthy parents. Mother died at the age of 84 years, father – 54 (unknown cause of his sudden death). Siblings – two sisters: healthy.

Gynaecological history: 2 pregnancies, 2 deliveries (spontaneous), at the age of 23 and 24; 2 children (males): the first son healthy, the second one with diastematomyelia, operated on at the age of 20 due to urine incontinence.

For the last few years, the patient has been experiencing an increasing muscle weakness in the lower limbs and progressive walking difficulty. Moreover, the examinations revealed: an ischaemic heart disease, hypertension, atrophic gastritis and anaemia.

Physical examination carried out in November 2008 revealed a compulsory standing posture, flat feet, pathological valgus of the right knee and an advanced, fixed right thoracic and left lumbar scoliosis, uncompensated,

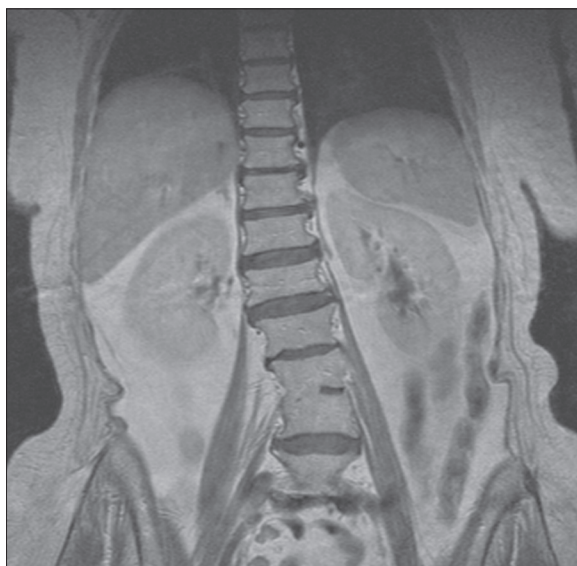
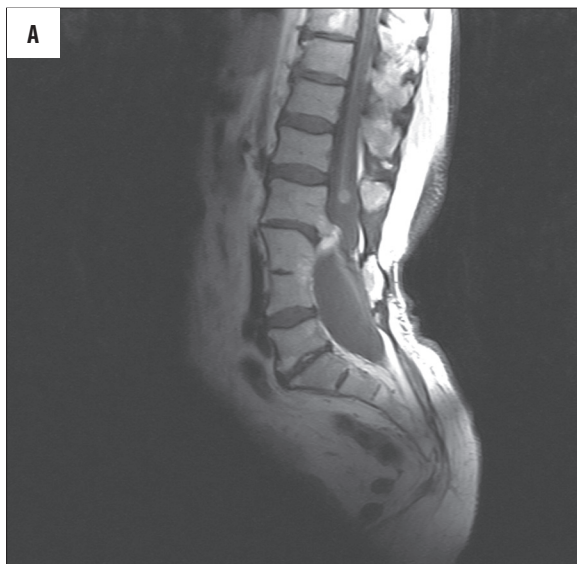

Figure 3. T1-weighted image, coronal plane. S-type scoliosis and partial fusion of the L3–L4 bodies.



with the spinal axis displaced to the right and a significantly increased kyphosis and lordosis. Within the lumbosacral spine there was a characteristic area of abnormal hair growth (hypertrichosis) (Figure 2). No other gait abnormalities were revealed; only the disturbances of articular mobility, corresponding to the described degenerative lesions and malformations. Moreover, large joints of the lower limbs were mobile, with an inhibited external rotation.

After orthopaedic consultation, the patient was referred for an MRI of the lumbosacral spine, which was performed in January 2010, in the MRI Laboratory of Wrocław Medical University. The examination was carried out with a 1.5T scanner, in FSE sequence (T1- and T2-weighted images), PD, in sagittal, transverse and coronal planes. On the basis of the performed sequences of the MRI, a left-convex rotational scoliosis and loss of lumbar lordosis was found. Moreover, there was a fusion of L3–L4 vertebral bodies

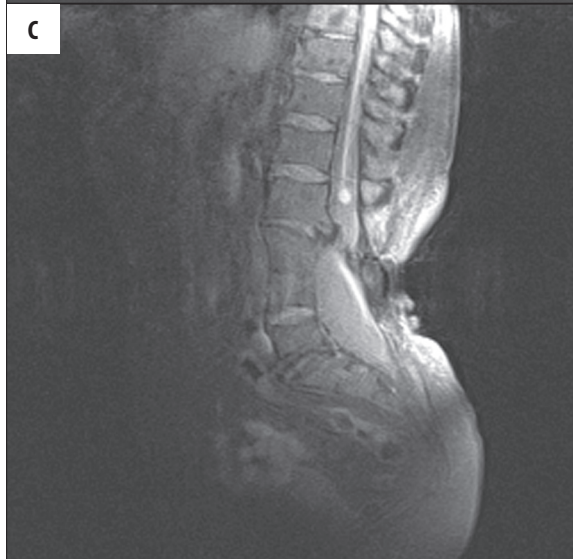
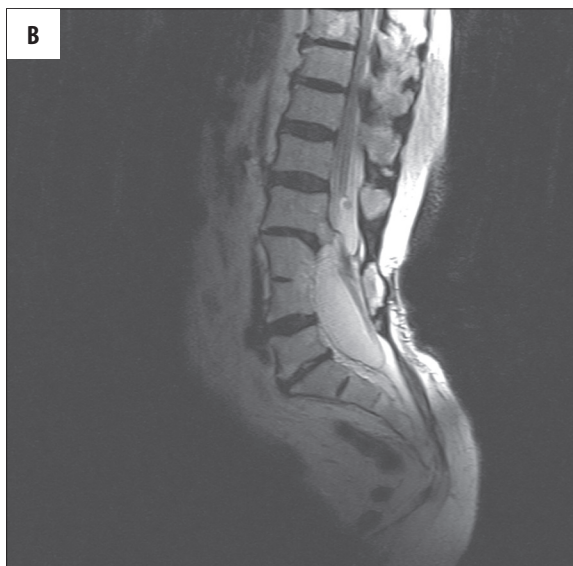
Figure 4. MR image in sagittal plane: T1-weighted image (A), T2-weighted image (B), PD-weighted image (C). Partial fusion of vertebra L3–L4, an osseocartilaginous septum on the L2–L5 level. On the L2 level, there is a round structure, possibly corresponding to an epidermoid cyst.

with a partially present intervertebral disc in the anterior part (Figures 3, 4A–C). At this level of the spine, dorsally, there subcutaneous tissue was atrophied. There were also malformations of the lumbar and sacral vertebrae, including L5 and S1 arch cleavage, as well as spinal canal widening at the level L3–S2.

The terminal cone was reaching the L5 level; no features of tethering. What is more, at the level of L1/L2 spine, the spinal cord was divided into two hemicords located in one common dural tube up to the upper part of the L3 body (Figures 5, 6). Below, there was an osseocartilaginous septum, dividing the spinal canal into two separate canals including two hemicords in separate dural tubes (Figure 7). At the level of the upper L4 border, the hemicords were again running through one common dural tube, which was significantly dilated, measuring 2.7×2.6 cm (Figure 8).

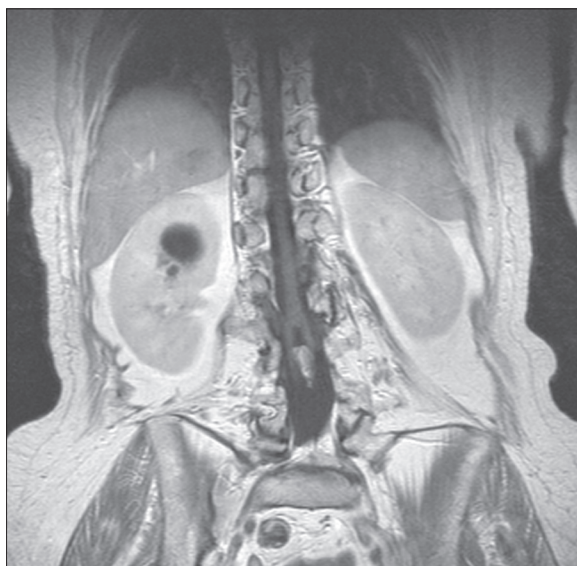


Figure 5. T1-weighted image, coronal plane. There is sagittal division of the spinal cord into two hemicords due to the presence of an osseocartilaginous septum.

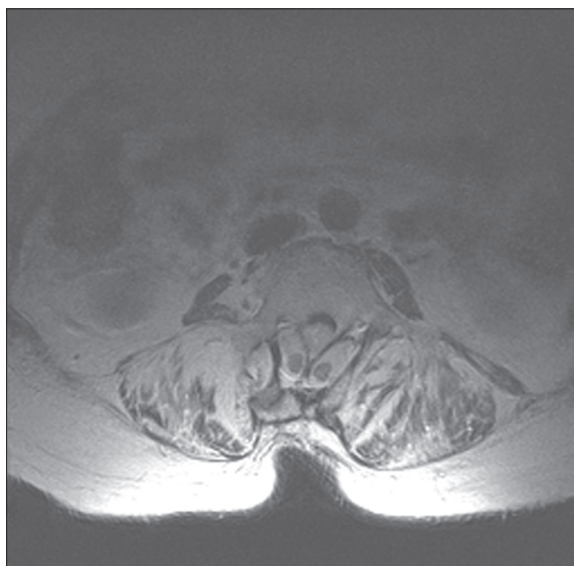


Figure 7. T2-weighted image, axial plane, level L3: two hemicords, each contained in a separate dural tube and separated by an osseocartilaginous septum.

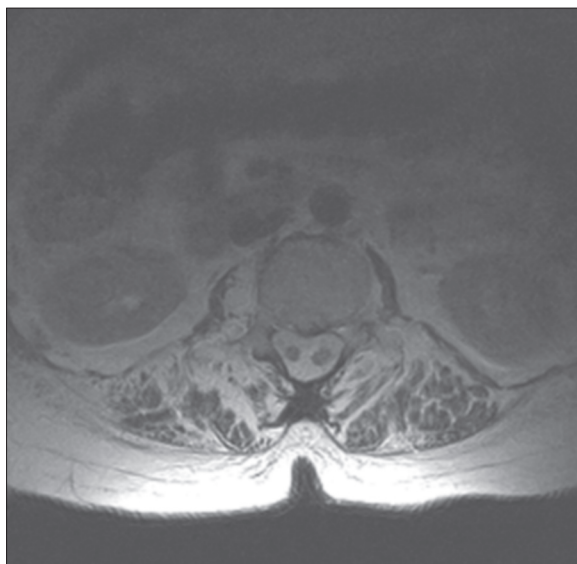


Figure 6. T2-weighted image, axial plane, level L2: a single dural sac containing both hemicords.

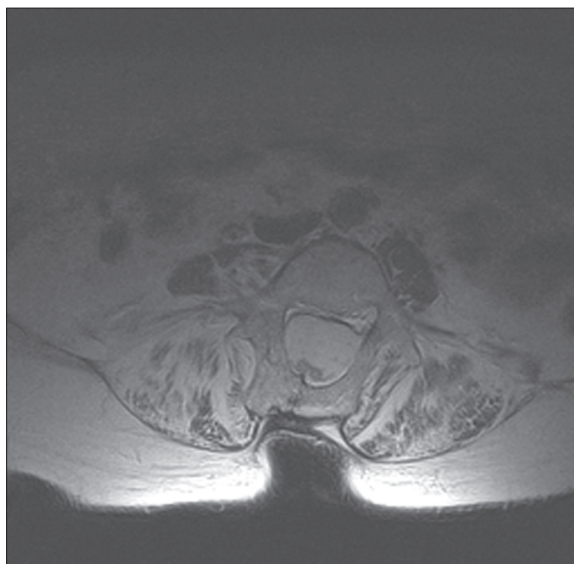


Figure 8. T2-weighted image, axial plane, level L4: a single dural sac containing both hemicords.

At the level of L2, on the lateral surface of the left hemicord, there was a sharply delineated round structure of 0.7 cm in diameter, hyperintense in T2- and PD-weighted images, and hypointense in T1-weighted sequences (Figure 4A-C). The lesion was occupying the lateral recess of the left spinal canal and could correspond to an epidermoid cyst on MRI.

T1- and T2-weighted sequences showed a hyperintense area within the Th10 body, measuring 1.3×1.2 cm, with fat-saturation in PD sequence. The area corresponded to a fatty islet, indicated for differentiation from vertebral haemangioma (Figure 4A-C).

Intervertebral discs in the examined part showed a pathological lowering of signal intensity in T2-weighted images.

Moreover, the evaluated segment revealed degenerative lesions of the vertebral bodies and intervertebral joints.

Discussion

Dysraphic lesions constitute the most numerous group of developmental abnormalities of the spinal cord and canal [5]. They are mostly diagnosed in the neonatal period, and sometimes in older children or adults [5,10]. These lesions may be divided into three groups, depending on the location of the lesion with respect to the surface of the back. There are open dysraphic lesion with a dorsal protrusion of soft tissues of the spinal canal, not covered by skin, then there are close dysraphisms with a protrusion covered by skin, and occult spinal dysraphisms, without any dorsal protrusions of soft tissues of the spinal canal [5,10].

The most important diagnostic imaging modality of dysraphisms of the spinal cord is the MRI, which allows for establishing a final diagnosis and for planning a potential surgery [4,10]. USG of the spinal canal and of the spine is the first-line treatment of open neonatal lesions and in prenatal diagnostics [1,3,4].

The most common dysraphisms is the myelomeningocele, present in approx. 1 case per every 1200–1400 live births [5]. It constitutes as much as 98.8% of all open dysraphisms of the spinal cord [10].

Diastematomyelia is a rare congenital malformation of the spinal cord, which belongs to the group of occult spinal dysraphisms [10]. It was first described in 1837 by French researcher C.P. Ollivier, who used the term 'diastematomyelia' [11]. A new classification and term ('split cord malformation, SCM) was introduced by D. Pang [13], who distinguished two types of diastematomyelia. In type I (SCM type I), two parts of the split cord (hemicords) are placed in their separate dural tubes. The spinal canal is divided in two by a septum, osseocartilaginous in most of the cases (75%) or, rarely, a fibrous one (25%). Type II (SCM type II) is characterised by the presence of one common dural tube, without any osseous septum in most of the cases, or with a fibrous septum, if any. Type II cases are asymptomatic [1,4,9–11].

Diastematomyelia is more common in women (80–90%) and tends to appear within the thoracolumbar spine (85%). It is rarely confined to the lumbar or to the thoracic spine solely. There were also cases of cervical or multilevel diastematomyelia [4,10,12].

Occult dysraphisms may be covered with a normal skin layer. However, they are frequently (i.e. in 50–75% of cases) connected with the presence of multiple skin lesions. Dysraphisms accompanied by skin lesions were first described in 1940 by B.W. Lichtenstein [9]. The most common skin marker of diastematomyelia is an abnormal hair growth (hypertrichosis) of the back, at the level of the malformation, observed in 56% of all cases of diastematomyelia [1,9]. According to Y. Izci, the rate of anomalies in the study group amounted to as much as 79% [9]. Moreover, Y. Izci presented two typical hair growth patterns in his work: 'faun tail' and 'silky down'. The 'faun tail' concerns thick, rough hair covering a wide triangular or rhombus-shaped area of the lumbosacral back, measuring mostly from a few to over ten centimetres in length. 'Silky down' is a small concentration of fine, soft hair in the midline [9]. The quoted work showed that there is a statistically significant correlation between the type of abnormal hair growth pattern and the type of diastematomyelia. The 'faun tail' pattern is connected with SCM type I, while the 'silky down' is significantly more common in SCM type II lesions [9]. In our case, this was obviously the 'faun tail' pattern (Figure 2), which speaks for Y. Izci's thesis on the relationship between this hair growth pattern and type I diastematomyelia (the presence of osseocartilaginous septum splitting the spinal canal into two parts, i.e. two hemicords placed within their separate dural tubes).

Other, frequently coexisting skin lesions include capillary angiomas (26%), dermal sinuses (22%), subdermal lipomas

(11%) or other dermal naevi and crypts [1,8,10,12,14]. Moreover, the diastematomyelia may be accompanied by spinal abnormalities such as hemivertebrae, butterfly vertebrae, fusion of vertebrae and narrowing of the intravertebral space. Very often there is also a scoliosis – even in 30–60% of cases [1,4,10,12,14]. Patients with diastematomyelia may present with different neurological and orthopaedic abnormalities, such as foot deformities (in 50% of cases), muscular atrophy, leg shortening, paraesthesias, disturbed reflex response [8,12]. There were also cases of the tethering of the spinal cord or of the terminal cone solely, syringomyelia, Klippel-Feil's syndrome, epidermoid and dermoid cysts, lipomas and dural cysts, especially the arachnoid cysts. Diastematomyelia is present in 15–20% of cases of Arnold-Chiari II syndrome [10,12].

In the presented case, the 78-year-old woman had been experiencing spine pain for over 40 years. Despite the confirmed osseous anomalies of the lumbar spine and abnormal hair growth (hypertrichosis) of the back, the correct diagnosis was established only after performing the MRI in January 2010. Taking into account the presence of the osseous-cartilaginous septum dividing the spinal canal into two parts with two hemicords in two separate dural tubes, diastematomyelia of type I (SCM type I) should be diagnosed, although above and below the septum, the hemicords fused in one cord lying in one common dural sac again. In the available literature, many authors suggest that SCM type I concerns symptomatic patients with serious, progressive neurological and/or orthopaedic abnormalities [1,4,9–11]. It is interesting that the women presented in our work did not show any significant neurological or orthopaedic abnormalities at younger age, apart from long-term back pain. She also gave birth to two children (both deliveries were spontaneous and uncomplicated; one child was healthy). Only at the L2 level, on the lateral surface of the left hemicord, there was a structure of 0.7 cm in diameter, potentially corresponding to an epidermoid cyst. Otherwise, there were no concomitant congenital abnormalities. Most probably, an important fact is here the absence of spinal cord tethering and the presence of a very low-reaching terminal cone (to L5).

Diastematomyelia diagnosed in the other, younger, son of the presented patient may speak for genetic conditioning of this malformation. Although the exact aetiology of spinal dysraphisms (of open, close and occult ones) is still unknown, authors have reported different factors influencing the future mother in her fertility or early gestation period. Approx. 50% of all cases are connected with nutritional deficiency. Other, genetic, are multifactorially conditioned [5]. Among the causes of spinal dysraphisms, there are chromosomal mutations, single-gene mutations, environmental factors and other factors, of unknown origin. Nutritional factors include i.a. consumption of cytochalasin a metabolite of the fungus *Phytophthora infestans* (found in blighted potatoes), folic acid or zinc deficiency, high consumption of nitrates (e.g. in ground water or in nitrate-preserved meat), vitamin A deficiency or hyperconsumption [5]. Moreover, mothers of children with spinal dysraphisms were often reported to reveal an abnormal carbohydrate metabolism (e.g. diabetes or hyperinsulinemia). Mothers with diabetes are more prone to deliver a child with such a pathology [15].

It is believed that one of the most important nutritional factors connected with spinal dysraphisms is the folic acid deficiency. Folic acid supplementation included in a pregnant woman's diet may decrease the risk of abnormally developing neural tube by as much as 72% [5].

Conclusions

Diastematomyelia is a rare dysraphic defect of the spinal cord. It is mostly diagnosed in the prenatal period or in children; much less often in adults. This disorder has to be

taken into account in the differential diagnosis in patients with X-rays revealing such defects of the spine as: hemivertebrae, butterfly vertebrae or vertebral fusion, especially when the patient reveals some additional skin lesions at the level of the diagnosed osseous anomalies, dorsally.

Being aware of the fact that abnormal hair growth (hypertrichosis) within the lumbosacral back accompanies the dysraphic lesions of the spinal cord, should result in an early and correct diagnosis, as well as introduction of an appropriate treatment.

References:

1. Karasahin KE, Gezginc K, Alanbay I et al: Ultrasonographic diagnosis of diastematomyelia during the 14th week of gestation. *Taiwan J Obstet Gynecol*, 2009; 48: 163-66
2. Pang D, Hoffman HJ, Rekeate HL: Split cord malformation, part II: clinical syndrome. *Neurosurgery*, 1992; 31: 481-500
3. Anderson NG, Jordan S, MacFarlane MR et al: Diastematomyelia: diagnosis by prenatal sonography. *AJR*, 1994; 163: 911-14
4. Kulkarni M, Ruparel M, Redkar R: Fetal diastematomyelia: MR imaging: a case report. *Indian J Radiol Imaging*, 2009; 19: 78-80
5. Netto JMB, Bastos AN, Figueiredo AA et al: Spinal dysraphism: a neurosurgical review for the urologist. *Rev Urol*, 2009; 11: 71-81
6. Biri AA, Turp AB, Kurdoglu M et al: Prenatal diagnosis of diastematomyelia in a 15-week-old fetus. *Fetal Diagn Ther*, 2005; 20: 258-61
7. Sonigo-Cohen P, Schmit P, Zerah M et al: Prenatal diagnosis of diastematomyelia. *Childs Nerv Syst*, 2003; 19: 555-60
8. Lewandrowski KU, Rachlin JR, Glazer PA: Diastematomyelia presenting as progressive weakness in an adult after spinal fusion for adolescent idiopathic scoliosis. *Spine J*, 2004; 4: 116-19
9. Izci Y, Gonul M, Gonul E: The diagnostic value of skin lesions in split cord malformations. *J Clin Neuroscience*, 2007; 14: 860-63
10. Rossi A, Biancheri R, Cama A et al: Imaging in spine and spinal cord malformations. *EJR*, 2004; 50: 177-200
11. Izci Y, Gurkanlar D, Gonul E: An unusual type of split cord malformation. *J Clin Neuroscience*, 2007; 14: 383-86
12. Parmar H, Patkar D, Shah J: Diastematomyelia with terminal lipomyelocystocele arising from one hemicord. *J Clin Imaging*, 2003; 27: 41-43
13. Pang D, Dias MS, Ahab-Barmada M: Split cord malformation. Part I: A unified theory of embryogenesis for double spinal cord malformations. *Neurosurgery*, 1992; 31: 451-80
14. Tomaszewska M, Siek E, Czekajska-Chehab E et al: Split cord malformation type I detected on multislice computed tomography. *Ann UMCS - Sectio D: Medicina*, 2007; 62: 346-51
15. Kitzmiller JL, Buchanan TA, Kjos S et al: Preconception care of diabetes, congenital malformations, and spontaneous abortions. *Diabetes Care*, 1996; 19: 514-41