



Contents lists available at ScienceDirect

International Journal of Surgery Case Reports

journal homepage: www.casereports.com

An unexpected finding in the resection specimen of a carcinoma of the oral cavity: A case report

D.C. Olthof^a, R.J. Bun^b, R.P. Dutrieux^c, A.P.J. Houdijk^{a,d,*}^a Department of Surgery, Medical Center Alkmaar, Postbus 501, 1800 AM Alkmaar, The Netherlands^b Department of Head and Neck surgery, Medical Center Alkmaar, Postbus 501, 1800 AM Alkmaar, The Netherlands^c Department of Pathology, Medical Center Alkmaar, Postbus 501, 1800 AM Alkmaar, The Netherlands^d Trial Center Holland Health, Alkmaar, The Netherlands

ARTICLE INFO

Article history:

Received 8 September 2015

Received in revised form 1 December 2015

Accepted 13 December 2015

Available online 17 December 2015

Keywords:

Malignancy

Carcinoma

Thyroid (gland)

Head and neck

Resection specimen

Synchronous malignancy

ABSTRACT

INTRODUCTION: The occurrence of two synchronous, primary cancers is rare. Thyroid carcinoma is incidentally found in the resection specimen after surgery for head and neck cancer in 0.3–1.9% of the patients.

PRESENTATION OF CASE: In this report, we describe the case of a 72-year-old patient in whom a primary (synchronous) papillary thyroid carcinoma was found coincidentally upon pathologic examination of lymph nodes recovered from the cervical neck lymph node dissection specimen after a ‘commando’ procedure for carcinoma of the oral cavity.

DISCUSSION AND CONCLUSION: There is no gold standard concerning treatment of the incidentally discovered thyroid gland carcinoma. The decision to perform surgery depends on the life expectancy of the patient, whether the thyroid gland demonstrates clinical or radiologic lesions, the already completed treatment for the head and neck cancer and should always be adjusted to the specific patient.

© 2015 The Authors. Published by Elsevier Ltd. on behalf of IJS Publishing Group Ltd. This is an open access article under the CC BY-NC-ND license (<http://creativecommons.org/licenses/by-nc-nd/4.0/>).

1. Introduction

Carcinoma of the oral cavity is rare and consists of 0.5% of the total amount of carcinoma's in the Netherlands with approximately 520 new patients being diagnosed per year [1,2].

The most important risk factors are tobacco and (excessive) drinking, the simultaneous consumption of which is believed to have a multiplicative effect [3–9]. A subset of head and neck squamous cell carcinomas is caused by the Human Papilloma Virus (e.g., type 16) [10,11]. Nutrition also plays a part in the development of head and neck cancers: meat and products of animal origin are associated with a higher risk of development of a tumor of the oral cavity [12] whereas a diet containing great amounts of fruits and vegetables seems to have a protective effect [13–15]. Furthermore, dental care and oral hygiene have been suggested to be related to the development of carcinoma's of the oral cavity, but the evidence is controversial [16–18]. Treatment of carcinoma of the oral cavity is dependent on the TNM stage: surgery is effective for local carcinoma's with an expectative treatment for a N0 neck (strict

follow-up is indicated). If there is a 20% or higher chance (based on tumor stage or tumor thickness) of (occult) cervical metastasis elective treatment with surgical neck dissection or radiotherapy of level I–III will be performed. Some groups advocate a Sentinel Node Procedure of the clinically N0 neck. For a clinically positive neck status (N+) with a node diameter <3 cm, a (modified) radical neck dissection of level I–V, or radiotherapy will be performed if the node diameter is <3 cm. Postoperative radiotherapy is indicated in case of a N2–N3 status or node capsule breakthrough.

The occurrence of two synchronous, primary cancers of different origin in the head and neck region is rare. Thyroid carcinoma is found incidentally in the resection specimen after surgery for head and neck cancer in 0.3–1.9% of the patients [19–22].

In this report, a 72-year-old patient is presented in whom a primary, synchronous papillary thyroid carcinoma was found coincidentally upon pathologic examination of lymph nodes recovered from the cervical neck lymph node dissection specimen after a ‘commando’ procedure for carcinoma of the oral cavity.

2. Presentation of case

A 72-year-old man was presented to the Head and Neck surgical department with a painful swelling/defect of the oral mucous membrane, located in the midline close to the mandible. The spot had increased in size over the last few weeks. He had no complaints,

* Corresponding author at: Medical Center Alkmaar, Department of Surgery, Postbus 501, 1800 AM Alkmaar, The Netherlands.

E-mail addresses: d.c.olthof@amc.nl (D.C. Olthof), r.j.bun@mca.nl (R.J. Bun), r.p.dutrieux@mca.nl (R.P. Dutrieux), a.p.j.houdijk@mca.nl (A.P.J. Houdijk).

nor weight loss and had been wearing a complete denture for 32 years. The medical history revealed hyperlipidemia and an enlarged prostate, both diagnosed in 2006. He had a smoking history of 20 pack years with an alcohol consumption of 6 units per day.

Upon oral examination at our hospital several purulent fibrous tissue-like lesions were found, caused by poor dental hygiene and a badly fitting dental prosthesis. In addition, a white, erythematous lesion (1 cm diameter) on the floor of the mouth (anterior side in the midline) was observed. Biopsies of the erythematous lesion were taken, revealing a squamous cell carcinoma. A pan endoscopy was performed, showing that the ulcer was fixated to the mandible (2.5 by 2 cm). There was no tongue involvement, the oro/hypopharynx and larynx showed healthy mucosa and no cervical lymphadenopathy was found on examination. Additional MRI scan of the head and neck showed no bone invasion of the mandible but three enlarged cervical lymph nodes were found (in level IB on both sides, level II and level III on the left side). Ultrasound guided fine needle aspiration of the lymph nodes showed on cytological examination lymphoid tissue and several limited atypical squamous cells. The lymph nodes in level II appeared to be a reactive lymph node. A chest X-ray revealed no distant metastasis.

In May 2014, a 'commando' procedure was performed for the cT₂ N₁M₀ squamous cell carcinoma (see Fig. 1), consisting of a tracheotomy, bilateral elective (supraomohyoid) neck dissection, segmental mandibular resection (on the median side of the foramen mentalis) and en-bloc resection of the primary tumor (with resection margins of 1 cm). The mandible was reconstructed with a free vascularized fibula graft, combined with a titanium reconstruction plate. Postoperative recovery was successful.

In the resection specimen, on histological examination, a radical resection was observed with free surgical margins, no perineural spread and no angioinvasion. Lymph nodes were negative for squamous cell carcinoma but three lymph nodes (level II and III on the left side of the neck) were found positive for papillary thyroid gland carcinoma (see Fig. 2). The oral carcinoma was staged as pT2N0M0. Upon this finding an MRI scan was performed, demonstrating a node in the thyroid gland that had previously been detected (on the first MRI scan) and had not changed in size (2 by 3 cm) or configuration. After being discussed in multidisciplinary tumor board meeting, it was decided to perform a total thyroidectomy. The histological examination of the thyroid lesion was a follicular variant of a papillary thyroid carcinoma (see Fig. 3). The parathyroid glands were spared. The patient had an uncomplicated recovery and left the hospital 3 days after the operation. Ablation therapy with radioactive iodide (¹³¹I) followed to eradicate any residual thyroid cells.

3. Discussion

In this case a primary, synchronous thyroid gland carcinoma was found coincidentally upon pathologic examination of lymph nodes recovered from a resection specimen after a 'commando' procedure for carcinoma of the oral cavity.

Carcinomas of the oral cavity are rare. Yearly, 520 new patients are diagnosed in the Netherlands [2].

The occurrence of two synchronous, primary cancers of different origin in the head and neck region is even more rare. A literature search on Pubmed (see Appendix 1) yielding over 1300 hits, revealed incidences of synchronous primary thyroid gland tumor discovered in the resection specimen of a patient with head and neck cancer, between 0.3 and 1.9% [19–22]. Resta et al. [21] presented eight cases in which incidental metastases of well-differentiated thyroid gland carcinoma were found in lymph nodes of patients with squamous cell carcinoma without clinical signs of thyroid disease. Seven patients had the primary diagnosis of

laryngeal cancer. In the other patient the primary carcinoma was a carcinoma of the tongue and therefore shows similarity to our case. Gilbert et al. [19] investigated 2538 neck dissections and found 28 cases (1.1%) of incidental thyroid carcinoma. Again, the majority of the patients underwent surgery for laryngeal cancer and only one of the 28 patients had a neck dissection for oral squamous cell carcinoma. Sheahan et al. [22] described 4 patients with thyroid carcinoma and 6 more patients with other incidental findings in the resection specimen of the surgically resected head and neck cancer (e.g., chronic lymphocytic leukemia, tuberculous lymphadenitis). The largest series available is that of Guzzo et al. reporting on a total of 33 cases [23], of which only 9 cases concern squamous cell carcinoma of the oral cavity.

Is there an etiological association between thyroid gland cancer and cancer of the oral cavity that might explain the co-occurrence of these tumors in our patient? A few possible explanations have been described in literature. First of all, the consumption of wine, beer and hard liquor showed positive associations with carcinoma's of both the oral cavity and the thyroid gland [24]. This might have played a role in the patient described: at the time of cancer diagnosis he drank 6 units of alcohol a day. Genetic alterations have also been reported as a possible explanation: the BRAF mutation, a molecular genetic alteration underlying thyroid gland cancer tumorigenesis and occurring in approximately 40% of papillary cancer incidences, has been found in head and neck cancer as well [25–28]. Hsu et al. [29] postulate that the aggressive use of modern diagnostic modalities might be a contributing factor to the development of synchronous primary malignancies.

In retrospect, the thyroid node was already detected on the first MRI scan and a diagnostic fine needle aspiration could have been done but would not have changed our policy. The squamous cell carcinoma of the oral cavity has the greatest impact on prognosis (5 year survival rates between 15– 80%) and should therefore be treated first. The papillary thyroid carcinoma (follicular variant, revealed by histological evaluation of the resection specimen (see Fig. 2) has a favorable prognosis with 5 year survival rates of approximately 95%. We chose to perform a thyroidectomy because of the relatively good condition and prognosis of our patient but the need for treatment is debated in literature. Some advocate surgical intervention, unless contraindicated by the poor health of the patient, while others propagate an expectative policy. Gilbert et al. [19] matched 24 patients with head and neck squamous cell carcinoma with 24 patients with squamous cell carcinoma and an incidental finding of thyroid cancer. They found no statistical significant difference in overall survival (*p*-value = 0.88), regardless whether patients received treatment that is recommended in the American Thyroid Association guidelines from 2009 (total thyroidectomy for thyroid cancer that is >1 cm, multifocal or metastatic to the cervical nodes). Although selection bias cannot be excluded in this small sample, this would suggest that surgical treatment for thyroid cancer, found incidentally in a patient treated for head and neck squamous cell carcinoma, may not be necessary. Different research groups have supported this opinion with their main argument being that a long time is required to allow the primary thyroid cancer to reach clinical significance. In the study of Guzzo et al. [23] 10 of the 33 patients did not receive any treatment on the thyroid gland and none of them developed a clinically evident cancer during follow-up (mean follow-up of 45 months). Another argument in favor of conservative treatment is the good prognosis of papillary thyroid carcinoma, although this has been disputed by Godballe et al. [30] who found that patients above the age of 60 years have a significantly worse prognosis than patients under the age of 60 (10 year survival of 22% vs. 90% in patients younger than 60). When summarizing the available evidence, a conservative treatment regarding thyroid cancer is justified when the thyroid gland does not demonstrate clinical or radiologic lesions

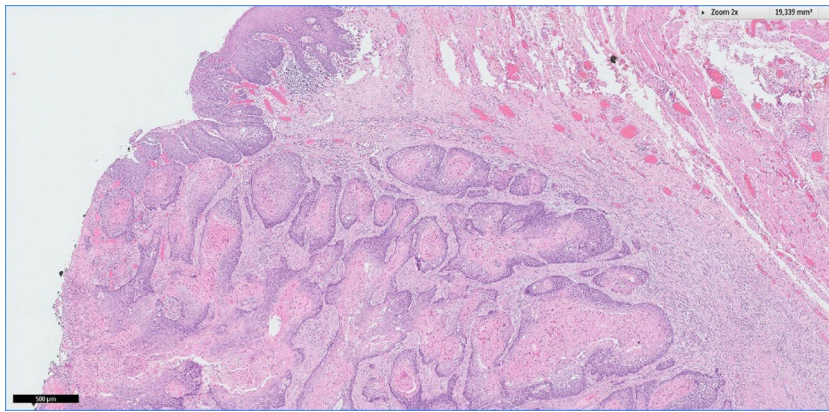


Fig. 1. Squamous cell carcinoma in the oral mucosa of the mandible. Nest of atypical keratinizing squamous cells arising from the mucosal epithelium (left side) infiltrate the deeper layers. The center of the nests show formation of horn pearls.

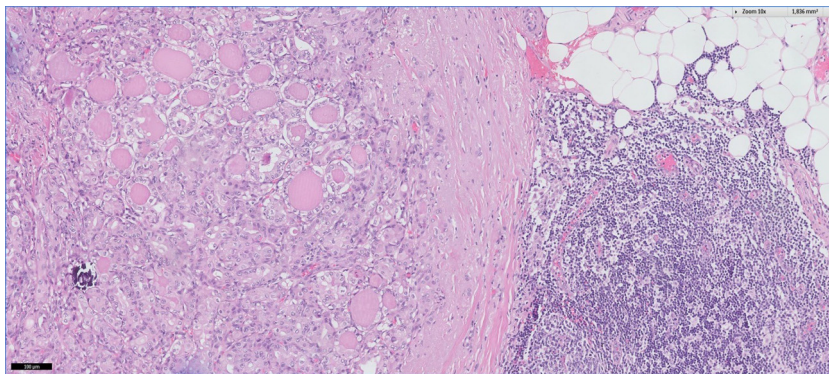


Fig. 2. Tumor localized in a lymph node from the neck dissection. The lymph node (cell rich tissue at the right side) contains a papillary/follicular tumor (left side) in which the cells have intra nuclear inclusions giving them the appearance of so called "orphan Annie eyes". This and the "psammoma body" (purple laminated dot on the left) indicate a metastasis from a papillary carcinoma of the thyroid.

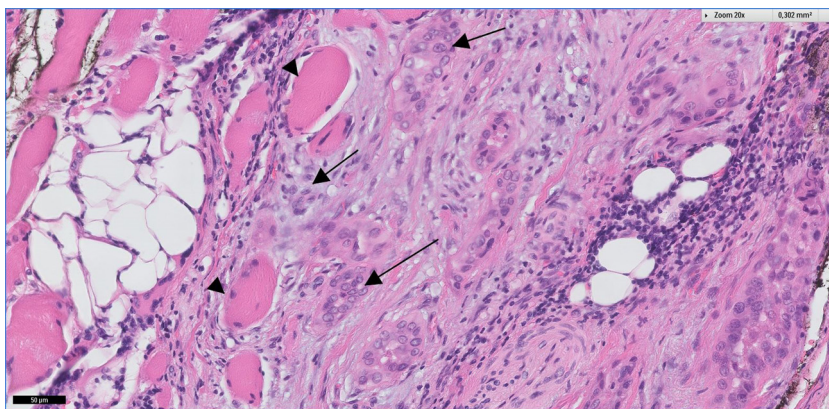


Fig. 3. Thyroidectomy with left sided follicular variant of papillary carcinoma. Tumor fields (black arrows) infiltrate the muscular tissue (arrow heads) surrounding the thyroid, indicating malignancy.

[31], in patients with papillary micro metastases that are clinically not palpable [19] or when the thyroid tissue in the lymph nodes is heterotopic instead of metastatic [32]. Also, patients (already) undergoing a hemithyroidectomy during laryngectomy for laryngeal cancer, patients undergoing radiotherapy of the neck for head and neck cancer or patients with a poor life expectancy due to the head and neck cancer might be better off with conservative treatment of the thyroid carcinoma. Another item for discussion regarding the treatment strategy is whether postoperative iodine treatment is indicated. In both the study of Guzzo et al. [23] and Sheahan et al. [22], the patients undergoing thyroidectomy did not

receive postoperative iodine treatment. Instead, the majority of the patients (23 out of 33; 69.7%) in the cohort of Guzzo et al. underwent radiotherapy of the neck, which is also effective for local control of thyroid cancer [33]. Neither of the patients in the study of Sheahan et al. received radiotherapy and the authors report no further evidence of thyroid disease recurrence after 6 years of follow-up. Physicians at the Memorial Hospital [34] only recommend total thyroidectomy to be followed by radioactive iodine treatment in tumors greater than 4 cm just like the Mayo group [35] who recommend iodine treatment only in high-risk patients (defined as an initial MACIS (distant metastasis, patient age, completeness of

resection, local invasion, and tumor size) score above 6)). In our patient the tumor size was less than 4cm but lymphatic spread already had taken place which made us decide to perform the total thyroidectomy followed by radioactive iodine treatment. The use of radioactive iodine as part of the treatment of well differentiated thyroid carcinoma is in line with the Dutch national guidelines [2] and Pitman et al. [36].

4. Conclusion

In summary, the incidental finding of a primary, synchronous thyroid gland carcinoma upon pathologic examination of lymph nodes recovered from a resection specimen after a 'commando' procedure for carcinoma of the oral cavity is rare and is therefore worth reporting. There is no gold standard concerning treatment of the incidentally discovered thyroid gland carcinoma. The decision to perform surgery depends on the life expectancy of the patient, the prognosis of the thyroid cancer (which is correlated to the age of the patient), whether the thyroid gland demonstrates clinical or radiologic lesions, and the treatment already instituted/completed for the head and neck cancer. Treatment should always be adjusted to the individual patient.

Conflict of interest

The authors have no conflict of interest to declare.

Funding

No funding has been received for the research.

Ethical approval

Not applicable.

Consent

Signed consent was obtained from the patient in question.

Author contribution

D.C. Olthof was involved in the study concept/design, review of the available literature, data* analysis/interpretation and writing of the paper.

R.J. Bun was involved in writing of the paper and critical revision of the article for important intellectual content.

R.P. Dutrieux drew the figures and revised the article critically for important intellectual content.

A.P. J Houdijk was involved in study concept/design, data* interpretation, revised the article critically for important intellectual content and takes overall responsibility for the paper.

All authors approved the version of the article to be published.

*Data = case (report).

Guarantor

Dr. A.P.J. Houdijk, MD.

Appendix A. . Pubmed search

Thyroid cancer AND squamous head and neck cancer.

Total number of hits: 1323.

Search was last updated 31 December 2014.

References

- [1] S. Siesling, J.A. van Dijck, O. Visser, J.W. Coebergh, Working group of The Netherlands Cancer Society. Trends in incidence of and mortality from cancer in the Netherlands in the period 1989–1998, *Eur. J. Cancer* 39 (17) (2003) 2521–2530.
- [2] National Dutch guidelines. Versie: 1.4, Verantwoording: Nederlandse Werkgroep Hoofd–Halstumoren (2004) Type: Landelijke richtlijn–Epidemiologie.
- [3] F. Turati, W. Garavello, I. Tramacere, V. Bagnardi, M. Rota, L. Scotti, et al., A meta-analysis of alcohol drinking and oral and pharyngeal cancers. Part 2: results by subsites, *Oral Oncol.* 46 (10) (2010) 720–726.
- [4] P. Boffetta, M. Hashibe, Alcohol and cancer, *Lancet Oncol.* 7 (2006) 149–156.
- [5] B. Secretan, K. Straif, R. Baan, Y. Grosse, F. El Ghissasi, V. Bouvard, et al., A review of human carcinogens—part E: tobacco, areca nut, alcohol, coal smoke, and salted fish, *Lancet Oncol.* 10 (11) (2009) 1033–1034.
- [6] G.J. McFarlane, T. Zheng, J.R. Marshall, Alcohol, tobacco, diet and risk of oral cancer: a pooled analysis of three case-control studies, *Eur. J. Cancer* 31 (1995) 181–187.
- [7] L. Radoí, S. Paget-Bailly, D. Cyr, A. Papadopoulos, F. Guida, A. Schmaus, S. C  n  e, et al., Tobacco smoking, alcohol drinking and risk of oral cavity cancer by subsite: results of a French population-based case-control study, the ICARE study, *Eur. J. Cancer Prev.* 22 (3) (2013) 268–276.
- [8] S. Franceschi, F. Levi, C. La Vecchia, E. Conti, L. Dal Maso, L. Barzan, et al., Comparison of the effect of smoking and alcohol drinking between oral and pharyngeal cancer, *Int. J. Cancer* 83 (1999) 1–4.
- [9] A.H. Madani, M. Dikshit, D. Bhaduri, T. Aghamolaei, S.H. Moosavy, A. Azarpaykan, Interaction of alcohol use and specific types of smoking on the development of oral cancer, *Int. J. High Risk Behav. Addict.* 11 3 (1) (2014), e12120.
- [10] A.R. Kreimer, G.M. Clifford, P. Boyle, S. Franceschi, Human papillomavirus types in head and neck squamous cell carcinomas worldwide: a systematic review, *Cancer Epidemiol. Biomarkers Prev.* 14 (2005) 467–475.
- [11] K.K. Ang, J. Harris, R. Wheeler, R. Weber, D.I. Rosenthal, P.F. Nguyen-T  n, et al., Human papillomavirus and survival of patients with oropharyngeal cancer, *N. Engl. J. Med.* 363 (2010) 24–35.
- [12] F. Bravi, C. Bosetti, M. Filomeno, F. Levi, W. Garavello, S. Galimberti, et al., Foods, nutrients and the risk of oral and pharyngeal cancer, *Br. J. Cancer* 109 (11) (2013) 2904–2910.
- [13] N.D. Freedman, Y. Park, A.F. Subar, A.R. Hollenbeck, M.F. Leitzmann, A. Schatzkin, et al., Fruit and vegetable intake and head and neck cancer risk in a large United States prospective cohort study, *Int. J. Cancer* 122 (10) (2008) 2330–2336.
- [14] D.H. Maasland, P.A. van den Brandt, B. Kremer, R.A. Goldbohm, L.J. Schouten, Consumption of vegetables and fruits and risk of subtypes of head-neck cancer in the Netherlands cohort study, *Int. J. Cancer* 136 (5) (2015) E396–E409.
- [15] N.D. Freedman, Y. Park, A.F. Subar, A.R. Hollenbeck, M.F. Leitzmann, A. Schatzkin, C.C. Abnet, Fruit and vegetable intake and head and neck cancer risk in a large United States prospective cohort study, *Int. J. Cancer* 122 (10) (2008) 2330–2336.
- [16] P.J. Allison, D. Locker, J.S. Feine, The relationship between dental status and health-related quality of life in upper aerodigestive tract cancer patients, *Oral Oncol.* 35 (2) (1999) 138–143.
- [17] B.H. Campbell, D.H. Mark, E.A. Soneson, J.E. Freije, C.J. Schultz, The role of dental prostheses in alveolar ridge squamous carcinomas, *Arch. Otolaryngol. Head Neck Surg.* 123 (10) (1997) 1112–1115.
- [18] A.M. Velly, E.L. Franco, N. Schlecht, J. Pintos, L.P. Kowalski, B.V. Oliveira, et al., Relationship between dental factors and risk of upper aerodigestive tract cancer, *Oral Oncol.* 34 (4) (1998) 284–291.
- [19] M.R. Gilbert, S. Kim, Incidental thyroid cancer found during surgery for head and neck squamous cell carcinoma, *Otolaryngol. Head Neck Surg.* 147 (4) (2012) 647–653.
- [20] A. Kr, P. Sebastian, T. Somanathan, N.A. George, K. Jayasree, Significance of incidentally detected thyroid tissue in lymph nodes of neck dissections in patients with head and neck carcinoma, *Int. J. Surg. Pathol.* 20 (6) (2012) 564–569.
- [21] L. Resta, D. Piscitelli, M.G. Fiore, V.D. Nicola, A.M. Fiorella, A. Altavilla, et al., Incidental metastases of well-differentiated thyroid carcinoma in lymph nodes of patients with squamous cell head and neck cancer: eight cases with a review of the literature, *Eur. Arch. Otorhinolaryngol.* 261 (2004) 473–478.
- [22] P. Sheahan, M. Hafidh, M. Toner, C. Timon, Unexpected findings in neck dissection for squamous cell carcinoma: incidence and implications, *Head Neck* 27 (2005) 28–35.
- [23] M. Guzzo, P. Quattrone, E. Seregini, R. Bianchi, F. Mattavelli, Thyroid carcinoma associated with squamous cell carcinoma of the head and neck: which policy? *Head Neck* 29 (2007) 33–37.
- [24] R.R. Williams, J.W. Horm, Association of cancer sites with tobacco and alcohol consumption and socioeconomic status of patients: interview study from the third national cancer survey? *J. Natl. Cancer Inst.* 58 (3) (1977) 525–547.
- [25] C.K. Jung, M.P. Little, J.H. Lubin, A.V. Brenner, S.A. Wells Jr., A.J. Sigurdson, et al., The increase in thyroid cancer incidence during the last four decades is accompanied by a high frequency of BRAF mutations and a sharp increase in RAS mutations, *J. Clin. Endocrinol. Metab.* 99 (2014) E276–E285.

- [26] L. Cheung, M. Messina, A. Gill, A. Clarkson, D. Learoyd, L. Delbridge, et al., Detection of the PAX8-PPAR gamma fusion oncogene in both follicular thyroid carcinomas and adenomas, *J. Clin. Endocrinol. Metab.* 88 (2003) 354–357.
- [27] M.N. Nikiforova, Y.E. Nikiforov, Molecular diagnostics and predictors in thyroid cancer, *Thyroid* 19 (2009) 1351–1361.
- [28] M. Xing, B.R. Haugen, M. Schlumberger, Progress in molecularbased management of differentiated thyroid cancer, *Lancet* 381 (2013) 1058–1069.
- [29] C.H. Hsu, C.L. Huang, Y.H. Hsu, U. Iqbal, P.A. Nguyen, W.S. Jian, Co-occurrence of second primary malignancy in patients with thyroid cancer, *Q. J. Med.* 107 (2014) 643–648.
- [30] C. Godballe, P. Asschenfeldt, J.A. Sorensen, et al., Papillary thyroid carcinoma: correlations between prognosis, age and clinicopathological and histomorphological findings, *The Laryngoscope* 104 (747) (1994) 747–751.
- [31] R. Vassilopoulou-Sellin, R.S. Weber, Metastatic thyroid cancer as an incidental finding during neck dissection: significance and management, *Head Neck* 14 (6) (1992) 459–463.
- [32] T. Yamamoto, Y. Tatemoto, Y. Hibi, A. Ohno, T. Osaki, Thyroid carcinomas found incidentally in the cervical lymph nodes: do they arise from heterotopic thyroid tissues? *J. Oral. Maxillofac. Surg.* 66 (2008) 2566–2576.
- [33] J. Brierley, T. Tsang, T. Panzarella, N. Bana, Prognostic factors and the effect of treatment with radioactive iodine and external beam radiation on patients with differentiated thyroid cancer seen at a single institution over 40 years, *Clin. Endocrinol.* 63 (2005) 418–427.
- [34] A.R. Shaha, J.P. Shah, T.R. Loree, Low-risk differentiated thyroid cancer: the need for selective treatment, *Ann. Surg. Oncol.* 4 (1997) 328–333.
- [35] I.D. Hay, G.B. Thompson, C.S. Grant, E.J. Bergstralh, C.E. Dvorak, C.A. Gorman, M.S. Maurer, B. Melver, B.P. Mullan, A.L. Oberg, C.C. Powell, J.A. Van Heerden, Papillary thyroid carcinoma managed at the Mayo Clinic during six decades (1940–1999): temporal trends in initial therapy and long-term outcome in 2444 consecutively treated patients, *World J. Surg.* 26 (2002) 879–885.
- [36] Pitman, K.T. Pitman, J.T. Johnson, E.N. Mayers, et al., Papillary thyroid carcinoma associated with squamous cell carcinoma of the head and neck: significance and treatment, *Am. J. Otolaryngol.* 17 (1996) 190–196.

Open Access

This article is published Open Access at [sciencedirect.com](https://www.sciencedirect.com). It is distributed under the [IJSCR Supplemental terms and conditions](#), which permits unrestricted non commercial use, distribution, and reproduction in any medium, provided the original authors and source are credited.