

Distal Triceps Rupture Repair: The Triceps Pulley-Pullover Technique



Richard A. C. Dimock, M.Eng., M.B.B.S., M.R.C.S.,
Christina Kontoghiorghe, M.B.B.S., B.Sc., M.R.C.S., Paolo Consigliere, M.D., Shadi Salamat,
Mohamed A. Imam, M.D., M.Sc.(Orth.) (Hons.), Ph.D., F.R.C.S. (Tr. & Orth.), and
A. Ali Narvani, B.Sc., M.B.B.S.(Hons.), M.Sc.(Sports Med.) (Hons.), F.R.C.S.(Tr. & Orth.),
M.F.S.E.M.(U.K.)

Abstract: Distal triceps rupture is an uncommon but debilitating injury, and surgical fixation is almost invariably warranted. A number of techniques have been described in the literature in which combinations of transosseous tunnels and bone anchors have been used. We describe a modification to existing techniques—the triceps pulley-pullover technique with all-suture anchors. This technique minimizes bone loss, while maximizing the bone-tendon contact area and creating a double-row repair to optimize strength and healing.

Distal triceps rupture is a rare injury, reportedly accounting for around 0.8% of all tendon ruptures.¹ The rupture of the triceps tendon may be partial or complete; it most commonly occurs at the osseous-tendon junction and often includes a bony avulsion (“fleck sign”). Rupture may also occur in the tendinous region, at the musculotendinous junction, or intramuscularly, but this is rare.

Conservative management may be offered to patients with low demand or those with partial tears. Surgical management should be offered to those with complete tears or a partial tear with significant weakness and high demand. Primary repair should ideally occur within 2 weeks of injury and may be arthroscopic or open; suture anchors, bone tunnel transosseous repair, suture repair, or a combination of these may be used.²

Outcomes of fixation are subjectively reported to be good. Horneff et al.³ found no difference in functional outcomes between transosseous and suture anchor repair in 56 cases but report a rerupture rate of 7%. Waterman et al.⁴ report no cases of rerupture in a series of 88 repairs using bone tunnels, suture repair, or anchors; whereas Giannicola et al.⁵ report satisfactory outcomes in 28 patients using bone tunnels or anchors, with a single case of rerupture. Mirzayan et al.⁶ compared transosseous repair with anchor repair in 184 triceps tears and found rerupture rates of 6.7% and 0%, respectively. Overall, cases of rerupture are well described in the literature and may be as high as 25% in high-demand cohorts.⁵

Yeh et al.⁷ hypothesized that an anatomic repair of the triceps footprint may improve the durability of the repair and, in cadaveric studies, found it to produce the least amount of repair-site motion after cyclical loading, compared with transosseous suture repair or anchor repair techniques.

We describe a modification of the anatomic technique used by Yeh et al.,⁷ which achieves both a strong and anatomic reattachment for repair of the avulsed triceps tendon to its footprint on the olecranon, using a double-row pulley-pullover technique, with all-suture anchors for the proximal row.

Surgical Technique

The surgical technique is explained in this Technical Note and is also detailed in [Video 1](#), “Distal Triceps

From the Rowley Bristow Unit, Ashford and St Peter's NHS Trust (R.A.C.D., C.K., P.C., S.S., and A.A.N.), Chertsey; Fortius Clinic (A.A.N.), London; Norfolk & Norwich University Hospitals (M.A.I.), Norwich, United Kingdom.

The authors report the following conflicts of interest or sources of funding: Stryker UK — Sports Medicine division provided funding to cover the submission fee for this article. Full ICMJE author disclosure forms are available for this article online, as [supplementary material](#).

Received June 25, 2018; accepted September 14, 2018.

Address correspondence to Richard Dimock, M.Eng., M.B.B.S., M.R.C.S., Rowley Bristow Unit, Ashford and St Peter's NHS Trust, Lyne, Chertsey, Surrey, KT16 0PZ, UK E-mail: richard.dimock@nhs.net

© 2018 by the Arthroscopy Association of North America. Published by Elsevier. This is an open access article under the CC BY-NC-ND license (<http://creativecommons.org/licenses/by-nc-nd/4.0/>).

2212-6287/18789

<https://doi.org/10.1016/j.eats.2018.09.006>

Table 1. Summary of Key Steps

- The patient is placed in the lateral decubitus position with the arm over the bar.
- Use a posterior approach to olecranon curving radially around the olecranon tip.
- Identify and prepare the ruptured triceps tendon.
- Prepare the triceps footprint.
- All-suture anchors (Iconix): Two 2-strand all-suture anchors are positioned in the triceps footprint to create a proximal suture anchor row; drill first, then tap in each anchor.
- Both ends of each strand are passed deep to superficial through the ruptured tendon.
- Pulley technique: Create a loop by tying a strand from each anchor over the assistant's finger.
- Pull on the other ends of the strands to snug the loop and knot down, bringing the ruptured triceps end down to the footprint—the "pulley technique."
- Tie off the free ends of the anchor strands to the 2 created knots.
- Use the remaining strands from each anchor to form a locking stitch along each edge of the triceps tendon.
- Prepare a push-lock anchor site just distal to the triceps footprint.
- Four suture limbs that form the first row are passed into the standard lateral row rotator cuff anchor, which is inserted more distally.
- Cut all sutures short; check range of movement.
- Closure is performed in layers.

Rupture Repair: The Triceps Pulley-Pullover Technique." Table 1 provides a summary of the steps, while Table 2 provides some "technical pearls" from the authors.

Preoperative Planning

A detailed history is obtained, and a thorough examination is performed during which a palpable gap at the triceps insertion and lack or lag of extension are sought. Elbow radiography may identify the fleck sign in the lateral view. Ultrasonography and/or magnetic resonance imaging may also be used to confirm the diagnosis. Surgery should ideally be performed within 2 weeks of injury.

Positioning

The patient is placed in the lateral decubitus position with the arm over a horizontal post (Fig 1). Supine positioning may also be used, according to the surgeon's preference. A tourniquet is placed on the upper

Table 2. Technical Pearls

- Ensure that strands forming the first row are passed from deep to superficial through the triceps tendon, well proximal to the ruptured end. This will help to advance and tension the triceps.
- When using the "pulley technique" to snug down the loop, bring the elbow into almost full extension to relax the triceps and closely appose the tendon to the bone.
- Similarly, when locking the strands into the distal row anchor, extending the elbow will help increase the triceps-ulna contact area. Use care in inserting the distal row anchor; predrill to avoid fracture as inserting this into cortical bone.

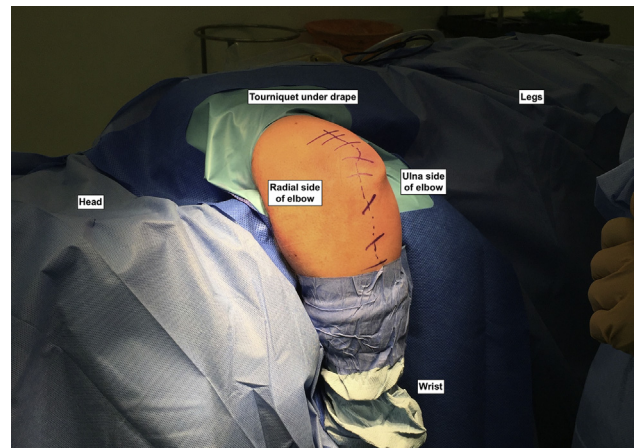


Fig 1. The patient is placed in the lateral decubitus position with the operative arm (left in this case) over a bar.

arm. Prophylactic antibiotics are given when anesthesia is induced.

Approach

Bone and tendon landmarks are drawn on the skin. After skin preparation and draping, a posterior longitudinal approach to the olecranon with a radial curve around the olecranon is initiated (Fig 2).

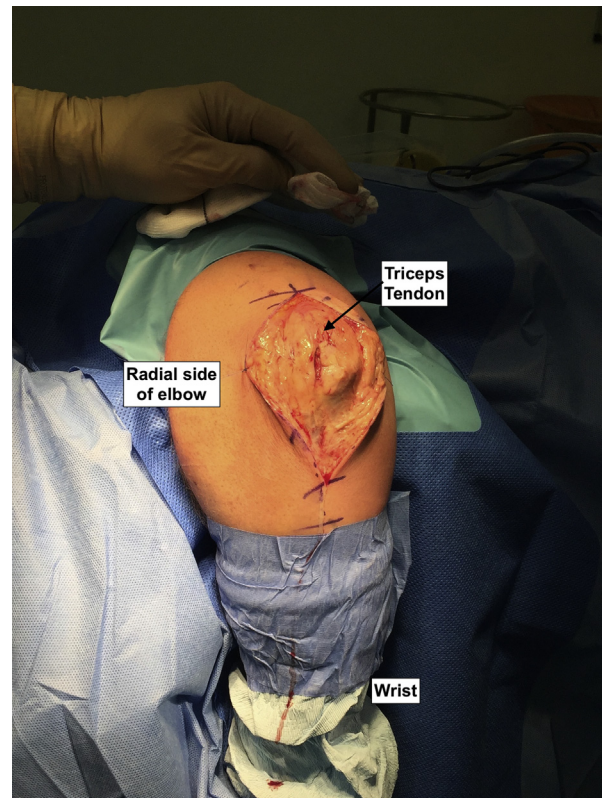


Fig 2. A standard posterior approach to the distal triceps and proximal 5 to 8 cm of ulna is used to expose the distal triceps tendon. Patient in lateral decubitus position.

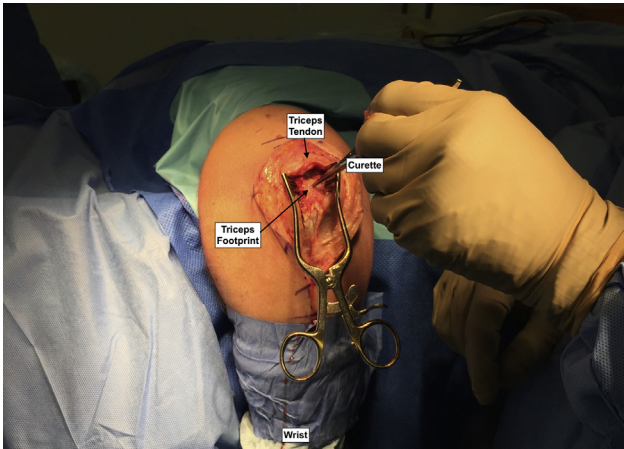


Fig 3. The triceps tendon is debrided and the footprint identified and prepared with a curette.

Preparation of Soft Tissues and Tendon Footprint

The distal end of the tendon is identified, debrided, and mobilized. Avulsed bone fragments are left in situ, and any haematoma or callus is removed. The ulna footprint of the tendon is identified and debrided to a callus-free, bleeding bone bed (Figs 3 and 4).

Insertion of “Proximal” Anchors in Footprint

Two double-strand all-suture anchors (ICONIX 3 [2.3-mm instrumentation], Stryker, Kalamazoo, MI) are inserted into the tip of the olecranon at the proximal third of the triceps footprint, approximately 15 mm from the olecranon tip and 15 mm apart. These

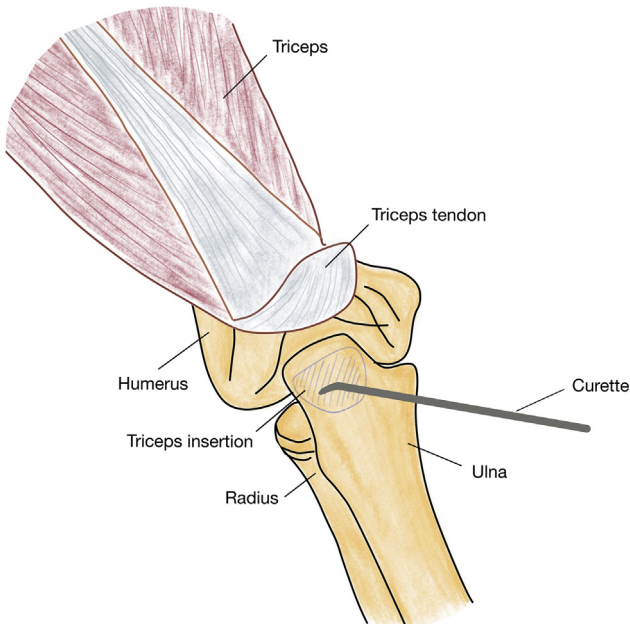


Fig 4. This sketch shows the preparation of the triceps tendon footprint. A curette is used to debride the bone to a fresh bleeding surface to optimize healing of the tendon to the bone.

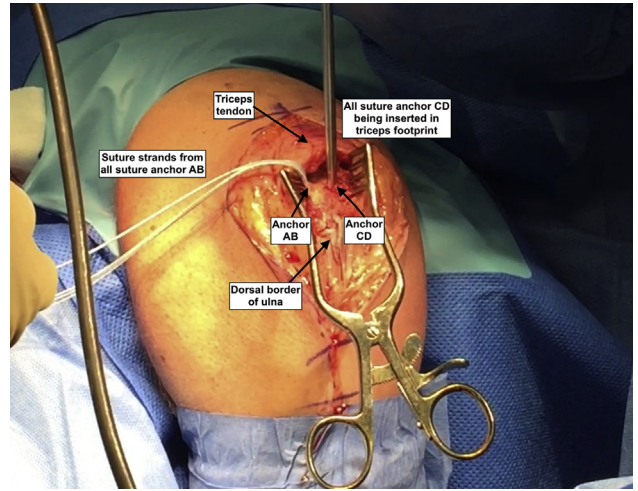


Fig 5. Two all-suture anchors are inserted into the triceps footprint. Here the anchor on the radial side (anchor AB) has already been inserted and the anchor on the ulna side (anchor CD) is now being inserted by tapping it into a predrilled 2.3-mm-diameter pilot hole. The anchors are positioned approximately 15 mm from the ulna tip and 15 mm apart.

anchors minimize the amount of bone loss caused by small drill holes. Force Fibre sutures (Stryker, San Jose, California) are used and form the proximal row of the fixation (Figs 5-7).

Pulley Technique

Starting with the radial side anchor (AB), each end of both suture anchors is passed from deep to superficial

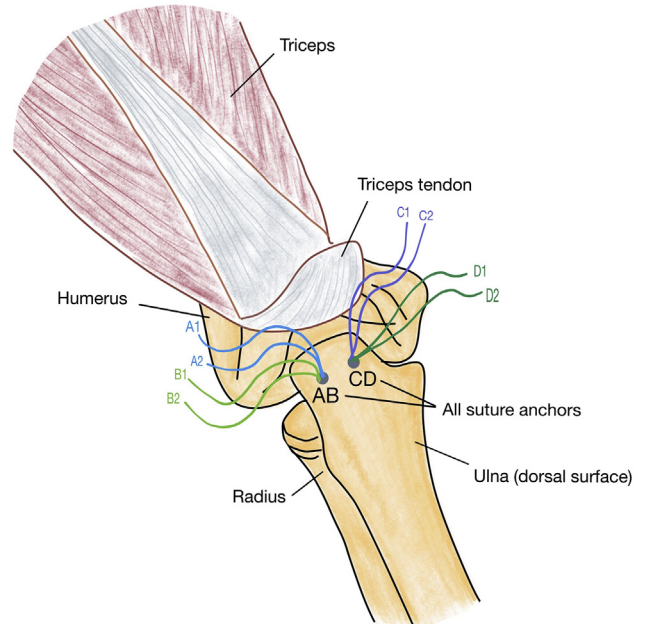


Fig 6. The 2 all-suture 2.3-mm anchors are inserted (labeled AB and CD), approximately 15 mm apart, to form the proximal row. Note that anchor AB includes sutures A and B; anchor CD includes sutures C and D.

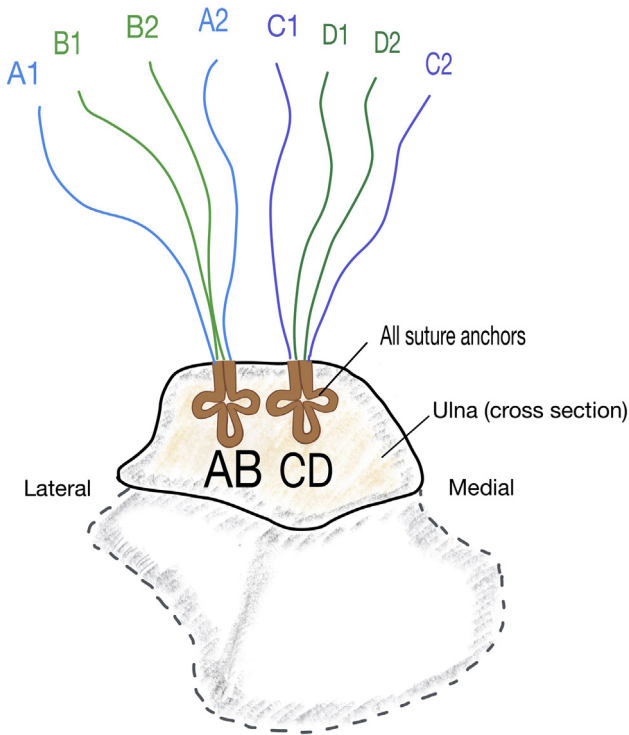


Fig 7. The all-suture anchors shown in cross-section through the proximal ulna: anchor AB on the lateral (radial) side of the footprint and anchor CD on the medial (ulna) side of the footprint. Here each anchor contains 4 strands (2 lengths of suture); however, anchors with more sutures may be used.

through the prepared end of the triceps tendon (Fig 8). This may be done with a suture passer or a loop stitch. The same is done with the strands of the ulna-sided anchor (CD). It is important to pass the sutures as proximal

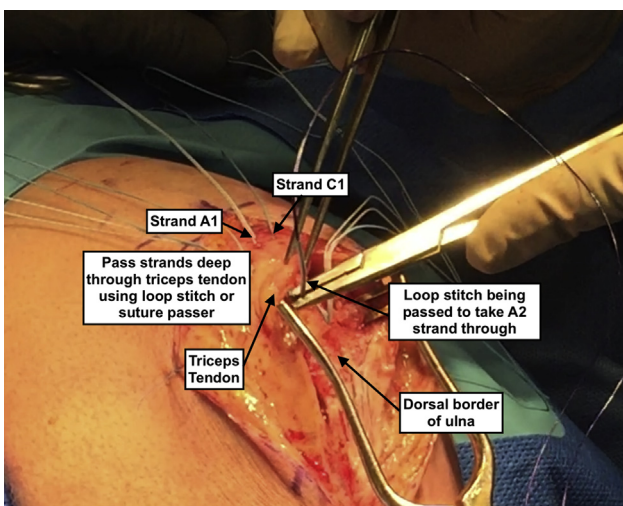


Fig 8. Forming the pulley. The A1 and C1 strands are passed from deep to superficial through the distal triceps tendon; this is repeated for the A2 and C2 strands 5 to 10 mm distal to the first pair. Here a loop-stitch is being used as a suture passer, and 6 strand anchors have been used.

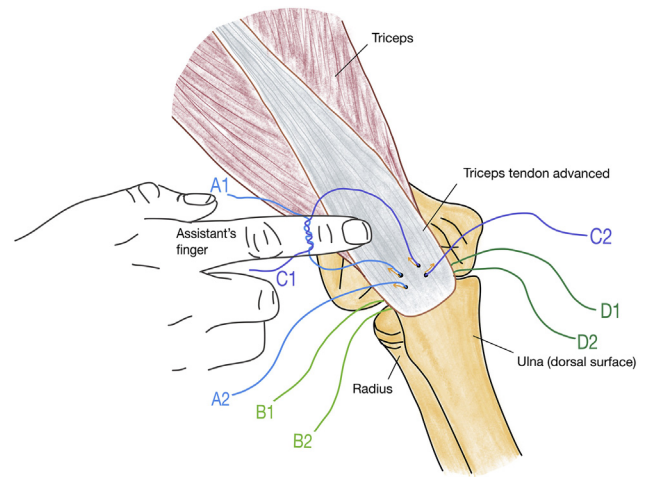


Fig 9. Forming the pulley. After the A and C strands have been passed through the triceps tendon from deep to superficial (orange arrows), strands A1 and C1 are tied over the assistant's finger to form a loop. Note B and D strands still lie under the distal triceps tendon.

as possible in the triceps tendon, so the tendon can be advanced to the original footprint. A loop is then formed by tying A1 to C1 over the assistant's finger (Fig 9). The knot is then pulled down with the triceps tendon by pulling on the ends of these strands, labeled A2 and C2 (Fig 10). This "pulley technique" brings the anterior surface of the triceps tendon firmly down onto the original triceps footprint. End A2 is then tied securely to C2, thus locking the pulley down (Fig 11).

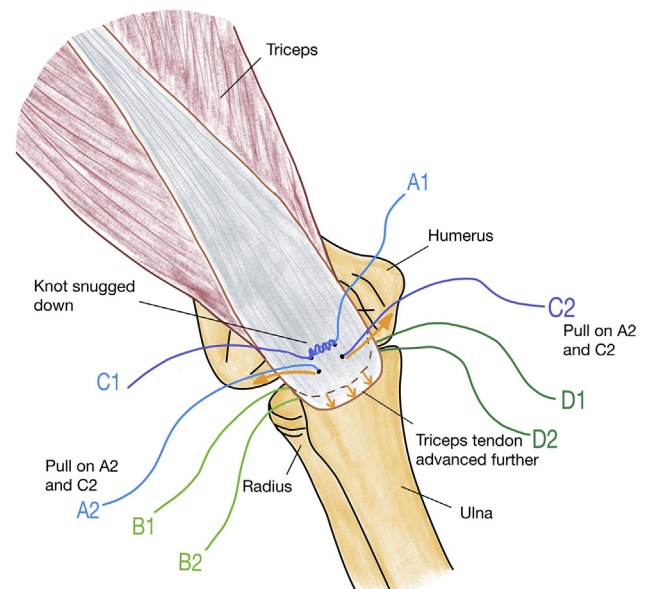


Fig 10. The pulley technique. Pulling on A2 and C2 (long orange arrows) draws the knot formed by A1 and C1, advancing and snugging the tendon down to the footprint (short orange arrows).

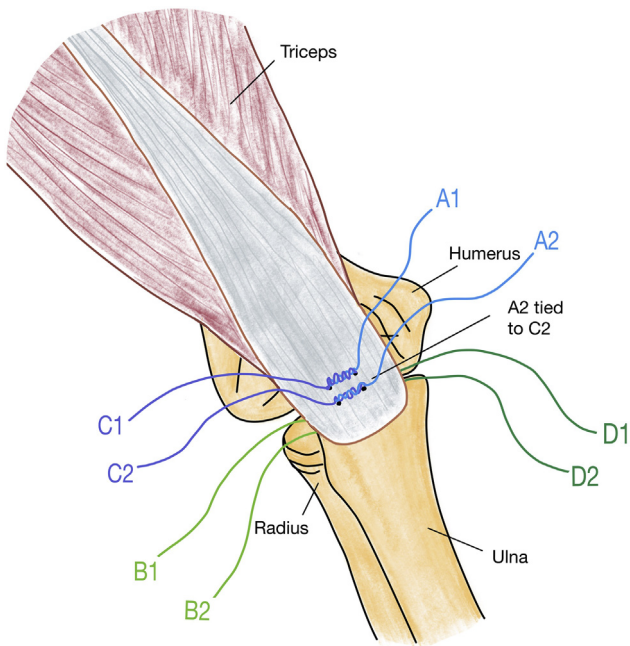


Fig 11. The pulley technique. A2 is tied to C2 over the triceps tendon, thus locking the pulley strands in place.

Augmentation of Repair

The remaining strands of anchors AB and CD are used to form locking stitches (e.g. a Krakow stitch) at the radial and ulnar borders of the distal triceps tendon, as shown in [Figure 12](#).

Pullover Technique: Advancing the Ruptured End

Once all strands have been tied and locked, the triceps repair can then be advanced further and strengthened

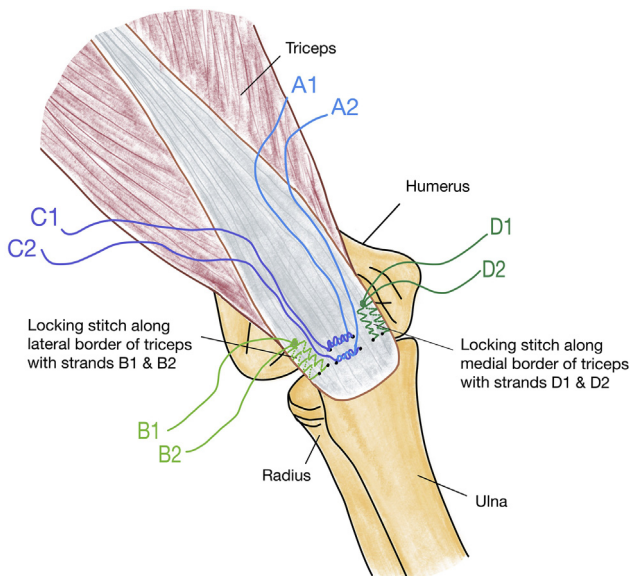


Fig 12. Augmentation. Strands B1/B2 and D1/D2 are used to form locking stitches along the medial and lateral borders of the triceps. A Krakow technique or a similar technique can be used.

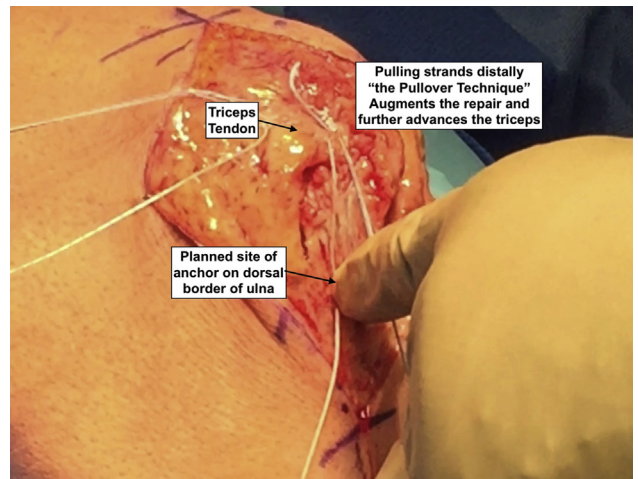


Fig 13. The pullover technique. Pulling the locked strands distally over the tendon augments and braces the repair. Here the site of the distal anchor is being planned.

with the double row. The even ends of each strand are cut short, leaving the long odd ends (A1, B1, C1, D1), which are pulled distally, further advancing the distal free end of the triceps and increasing its contact with the anatomic footprint ([Figs 13](#) and [14](#)). This is the pullover technique.

Second Row Anchor

A standard lateral row rotator cuff anchor is now inserted into the midline of the dorsum of the ulna,

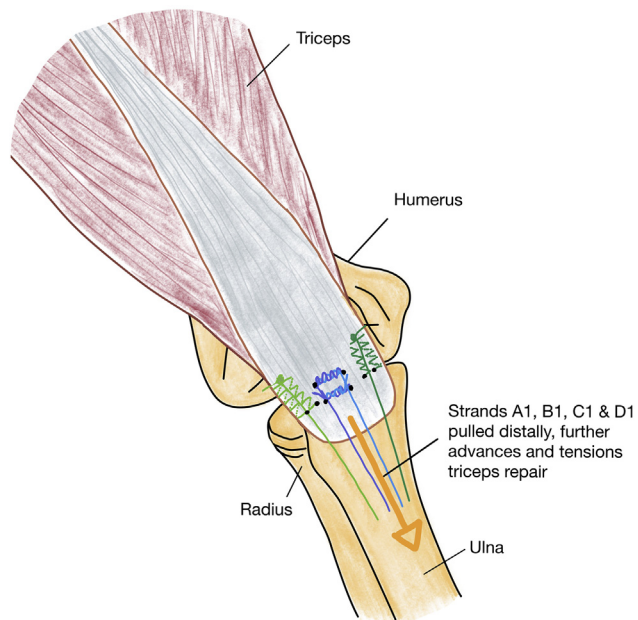


Fig 14. The pullover technique. Pulling the strands from the knots distally tensions and advances the distal triceps over the original footprint. In this example, 4 strands have been used, but more can be taken distally, depending on the capacity of the push-lock anchor chosen by the surgeon for the distal row.

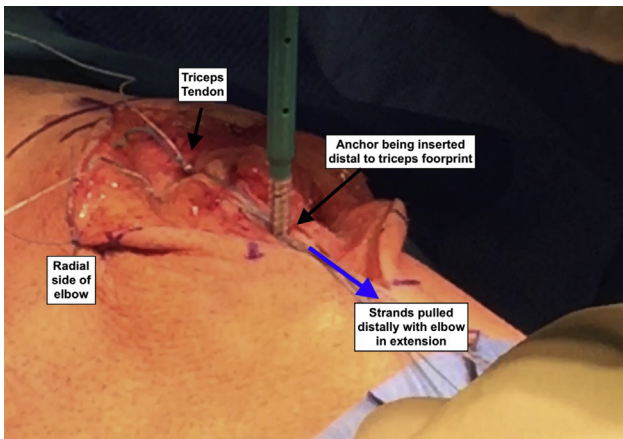


Fig 15. The pullover technique. Placement of the distal row locking anchor in the dorsal border of the ulna, distal to the triceps insertion. This must be done with the elbow in extension.

approximately 3 cm from the olecranon tip (just distal to the triceps footprint), with the 4 suture limbs from the all-suture anchors, thus forming the second row of the repair (Figs 15 and 16). All sutures are cut short, and the range of movement and fixation are checked (Fig 17).

Closure and Dressing

The paratenon is repaired with absorbable braided suture (Vicryl; Ethicon, Somerville, NJ). The wound is closed with absorbable monofilament suture (Monocryl; Ethicon) and dressed with an impermeable

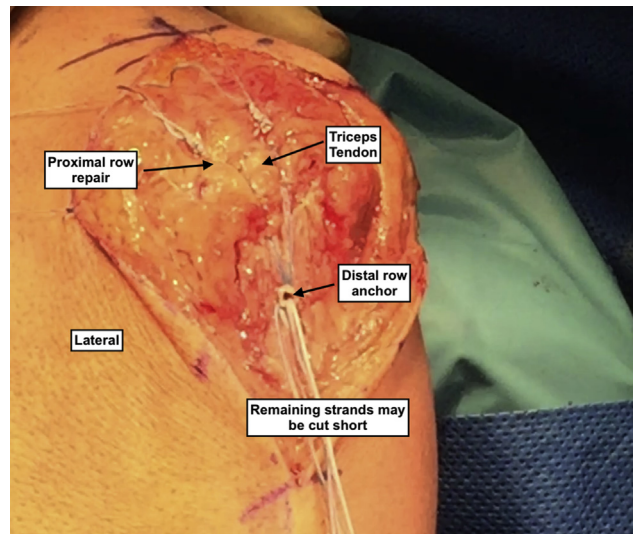


Fig 17. The distal row suture anchor in situ to complete the repair. This must be locked down with the elbow in extension. In this case 6 strands have been, advanced from the knots of the proximal row; however, 4 strands would be adequate. The remaining strands are cut short.

dressing. A back-slab is then applied with the elbow at 60° of flexion.

Rehabilitation

At 2 weeks the wound is reviewed. The patient is put into a hinged elbow brace, allowing 20° to 120° of assisted passive movement, followed by a further 2 weeks of unrestricted assisted passive movement in the brace. Active range of motion and physiotherapy begin at 4 weeks to optimize range of movement and begin strengthening exercises.

Discussion

The triceps is the principle extensor of the elbow, and complete rupture invariably requires surgical intervention to restore function. A number of surgical techniques for distal triceps rupture repair have been described in the literature (Table 3), and both open and minimally invasive techniques have been used. The primary goals of such treatment are to achieve strong and reliable reattachment of the tendon, with or without bony avulsion, to the proximal ulna to restore

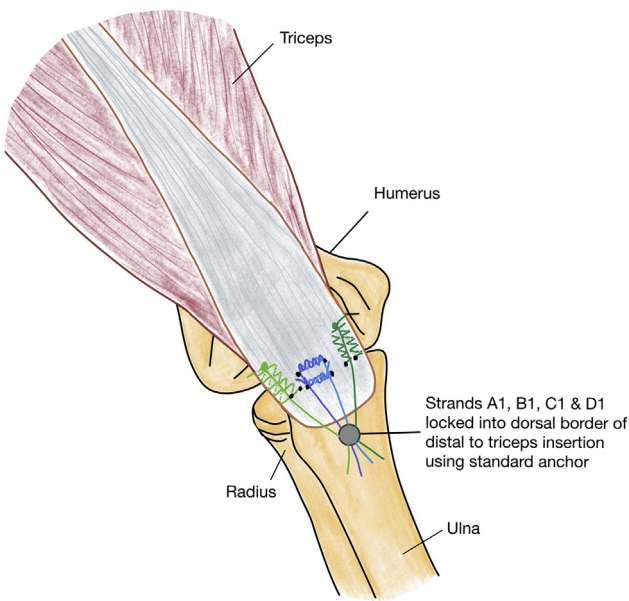


Fig 16. The pullover technique. The distal row suture anchor is placed using strands A1, B1, C1 and D1 forming the distal second row. Remaining strands are cut short.

Table 3. Described Techniques

Transosseous cruciate technique
Suture anchor technique
Combination of suture anchors and bone tunnels
Arthroscopic reattachment
Suture bridge repair
Transosseous Krakow-type whipstitch technique
K-wire and cerclage (large bony fragment)
Tendon ligament allo-/autograft augmentation

Table 4. Advantages and Disadvantages of the Technique

Advantages	Disadvantages/Risks
<ul style="list-style-type: none"> • Biological advantage: Increased “anatomic” footprint of tendon apposition to olecranon • Secure: Double-row repair • All-suture proximal row: Bone-preserving technique • Pulley technique: Allows close apposition of tendon end to triceps footprint and tensions repair 	<ul style="list-style-type: none"> • Large knots, which may cause inflammation or irritation • Anchor pullout risk in weak bone • Risk of fracture of the ulna on insertion of distal anchor

the extensor mechanism of the elbow without limitation or lag.

One technique, described by Yeh et al.,⁸ is the transosseous cruciate technique, whereby a locking stitch in the tendon (such as a Krakow suture) is passed through holes drilled in the olecranon at the center of the tendon footprint with the use of absorbable or nonabsorbable sutures, tension bands, or wire sutures. If large bony avulsion fragments are present, these are also fixed down.

As suture anchor technology has developed and improved, it has been increasingly used for triceps reattachment. Anchors are placed in the center of the triceps footprint, and their associated sutures are passed through the avulsed tendon with locking stitches, then snugged down.⁹ Other techniques described by Yeh et al.⁷ provide a more anatomic reattachment, either by combining suture anchors with transosseous tunnels or using a double-row suture anchor technique.

The aim of the technique described in this Technical Note is to achieve a strong and anatomic reattachment of the triceps to its footprint. By placing the proximal row 10 to 15 mm from the olecranon tip, the triceps is apposed proximally to the anatomic footprint. The pulley technique aids the tension of the tendon during the repair and achieves even closer approximation of the free end of the ruptured triceps to its original footprint on the ulna. The pullover technique with the double-row anchor fixation increases the contact area for bone-tendon healing and provides strength and stability. The use of all-suture anchors in the proximal row further increases the contact area and minimizes bone damage and loss as compared with use of large standard bone anchors.

This surgical technique is low risk, although there is the potential for fracture on insertion of the distal anchor row. So far, we have observed no complications of

this technique. However, as with any suture anchor technique, there is the theoretical risk of anchor pull-out, particularly in patients with mechanically incompetent bone. Furthermore, 2 relatively large knots are left on the superficial border of the triceps tendon, which may be palpable in patients with limited soft tissue coverage (Table 4).

Although this technique is described for use with complete ruptures, it could also be used for partial ruptures requiring surgical intervention. We have also created a video further outlining the technique.

We have described the triceps pulley-pullover technique, a double-row repair for distal triceps tendon ruptures, using all suture anchors for the proximal row, with a pulley technique for close apposition to the bone, followed by the pullover technique to enhance the repair. Use of this technique results in optimal bone preservation, increased surface area of contact between the tendon and the bone, and enhanced strength of the reattachment.

References

1. Anzel SH, Covey KW, Weiner AD, Lipscomb PR. Disruption of muscles and tendons: An analysis of 1,014 cases. *Surgery* 1959;45:406-414.
2. Shuttlewood K, Beazley J, Smith CD. Distal triceps injuries (including snapping triceps): A systematic review of the literature. *World J Orthop* 2017;8:507-513.
3. Horneff JG 3rd, Aleem A, Nicholson T, et al. Functional outcomes of distal triceps tendon repair comparing transosseous bone tunnels with suture anchor constructs. *J Shoulder Elbow Surg* 2017;26:2213-2219.
4. Waterman BR, Dean R, Veera SS, et al. Surgical repair of distal triceps tendon injuries: Short-term clinical outcomes and re-rupture rate. *Orthop J Sports Med* 2018;6:2325967118S00163.
5. Giannicola G, Bullitta G, Rotini R, et al. Results of primary repair of distal triceps tendon ruptures in a general population: A multicentre study. *Bone Joint J* 2018;100:610-616.
6. Mirzayan R, Acevedo DC, Sodl JF, et al. Operative management of acute triceps tendon ruptures: Review of 184 cases. *Am J Sports Med* 2018;46:1451-1458.
7. Yeh PC, Stephens KT, Solovyova O, et al. The distal triceps tendon footprint and a biomechanical analysis of 3 repair techniques. *Am J Sports Med* 2010;38:1025-1033.
8. Yeh PC, Dodds SD, Smart LR, Mazzocca AD, Sethi PM. Distal triceps rupture. *J Am Acad Orthop Surg* 2010;18:31-40.
9. Mancini F, Bernardi G, De Luna V, Tudisco C. Surgical repair of isolated triceps tendon rupture using a suture anchor technique: A case report. *Joints* 2017;4:250-252.