



Case report

Case report of Leser-Trelat sign as sequela of an atypical inflammatory process

P. Mulero-Soto ^{*,1}, J. Sanchez-Vivaldi, MD ², O. Rovira, MD ³, J. Arocho, MD ⁴,
G. Pereira-Torrellas, MD ⁵, J. Martinez-Trabal, MD, FACS ⁶, G. Bolaños-Avila, MD, FACS ⁷

Department of General Surgery at St. Luke's Medical Center, Ponce Health Sciences University, Ponce, Puerto Rico

ARTICLE INFO

Keywords:

Granuloma
Leser-Trelat
Seborrheic dermatitis
colon mass

ABSTRACT

Background: Leser-Trelat sign is a rare paraneoplastic syndrome in which one main characteristic presented is an eruption of multiple seborrheic keratoses around different areas of the body. This syndrome has been associated with multiple gastrointestinal malignancies, especially adenocarcinoma of stomach and colon.

Case report: We report a 70-year-old male who presented to the surgery clinic complaining of a persistent lower abdominal pain for the past 2 months. The pain was associated with weight loss and the gradual appearance of multiple seborrheic keratoses in his body. The patient was admitted to the hospital for further evaluation, a CT scan shows an 8.1 × 5.2 cm mass in the mid mesentery and laboratories shows anemia and positive fecal occult blood. The patient was scheduled for an exploratory laparotomy. During the surgery, a large mass was found arising from the ascending colon with invasion into the adjacent sigmoid colon. The mass was sent to pathology and shows a foreign body granuloma. In addition to the surgery, the patient undergoes an endoscopic evaluation to rule out a malignancy from the upper gastrointestinal system, no masses or lesions were found.

Conclusion: This is the first case reported, as far as our knowledge, of a foreign body granuloma in the association of Leser-Trelat sign. Foreign body granulomas are associated with multiple cellular signaling and this could be the source of the association of the Leser-Trelat sign. Further evaluation is needed to have a better understanding of the association between the Leser-Trelat sign and the formation of a foreign body granuloma.

1. Introduction

Leser-Trelat sign (LTS) is a rare paraneoplastic syndrome, in which an abrupt eruption of multiple seborrheic keratosis occurs throughout different areas of the body, most notably the chest and back [2]. LTS has been related to young otherwise healthy individuals who harvest a gastrointestinal malignancy, most commonly gastric adenocarcinoma [2]. To date, have been no standardized criteria for the diagnosis of LTS in association to malignancy [1]. A relationship with the appearance of a benign neoplasm has not been described in the literature. It is thought that LTS can be caused by paraneoplastic syndrome, where a cascade of

cytokines and growth factors are released by malignant neoplasms [2]. In this case report, we describe an adult man that presents an abrupt onset of seborrheic keratosis and a large intra-abdominal tumor, highly suspected for malignancy. Written informed consent was obtained from the patient for publication of this case report and accompanying images. A copy of the written consent is available for review by the Editor-in-Chief of this journal on request. This work had been compliances with the SCARE 2020 criteria [8].

Abbreviations: LTS, leser-trelat sign; FBG, foreign body granuloma.

* Corresponding author at: P.O Box 336810, Ponce, PR 00733-6810, Puerto Rico.

¹ PGY-2 General Surgery Resident, St. Lukes Medical Center, Ponce Health Sciences University, Ponce, Puerto Rico pmuleromd@gmail.com 787-233-3424.

² PGY-5 General Surgery Resident, St. Lukes Medical Center, Ponce Health Sciences University, Ponce, Puerto Rico. jsanchezvivaldi@gmail.com 787-241-2190.

³ PGY-3 General Surgery Resident, St. Lukes Medical Center, Ponce Health Sciences University, Ponce, Puerto Rico ojrovira3@gmail.com 787-475-2525.

⁴ PGY-2 Pediatric Resident, Medical Sciences Campus, Rio Piedras. Arochoburgos1@gmail.com 787-501-0750.

⁵ PGY-5 General Surgery Resident, St. Lukes', Ponce Health Sciences University, Ponce, Puerto Rico pereira.gab@gmail.com 787-246-6529.

⁶ Vascular Surgeon, St. Lukes Medical Center, Ponce Health Sciences University, Ponce, Puerto Rico dmartinez@caribbeanvascular.com 787-908-7645.

⁷ General Surgery, St. Lukes Medical Center, Ponce Health Sciences University, Ponce, Puerto Rico bolanosurgical@hotmail.com 787-635-3777.

<https://doi.org/10.1016/j.ijscr.2022.106833>

Received 31 October 2021; Received in revised form 8 February 2022; Accepted 10 February 2022

Available online 12 February 2022

2210-2612/Published by Elsevier Ltd on behalf of IJS Publishing Group Ltd. This is an open access article under the CC BY-NC-ND license

(<http://creativecommons.org/licenses/by-nc-nd/4.0/>).

2. Case report

A 70-year-old man was referred to our outpatient surgical center due to persistent lower abdominal pain and unintentional weight loss (12 pounds) since 2 months prior. His past medical history includes hypertension, hypothyroidism, benign prostate hyperplasia, diverticulosis, rheumatoid arthritis, and seborrheic keratosis diagnosed by his dermatologist ten years ago. His past surgical history includes a laparoscopic appendectomy (15-years ago) and knee replacement (both performed in another institution). Screening colonoscopy performed 2 years prior, reported a tortuous sigmoid colon with diverticulosis and hypertrophic folds that made the endoscope impossible to advance.

On evaluation, his abdominal pain was described as constant, dull, and of moderate intensity. It was associated with nausea, weight loss, non-bloody diarrhea, and abrupt worsening of his previously diagnosed skin lesions. Denied fever, chills, and vomiting.

On physical examination, the patient was oriented and appeared in no acute distress. He had numerous waxy, slightly elevated, dark, and regular bordered skin lesions located in the chest, back, and abdomen ([Image 1](#)). The abdominal exam had positive bowel sounds and was depressible with localized tenderness in the lower quadrants. There

were no signs of diffuse peritonitis such as guarding or rebound, there were no palpable masses or hernias and the rectal exam was unremarkable. With these clinical findings, we decided to admit the patient for further workup.

Laboratory analysis showed chronic microcytic anemia (11.5 mg/dl) and a positive fecal occult blood test. CEA and CA 19-9 were within normal limits. A CT scan of the abdomen and pelvis with PO and IV contrast was performed. It revealed a large (8.1 × 5.2 cm) mass arising from the small bowel mesentery, near the terminal ileum, with associated partial intestinal obstruction and severe inflammatory process suggestive of perforation ([Image 2](#)). A malignant neoplastic process was high in the differential diagnosis. On further imaging, there were no signs of metastatic spread.

Due to these findings, we decided to take the patient to the operating room for an exploratory laparotomy. During laparotomy, a large solid tumor was encountered. The tumor arose from the cecum, invading the adjacent small bowel mesentery and sigmoid colon. A right hemicolectomy with primary anastomosis and a left partial colectomy with end colostomy and Hartmann's pouch procedure was performed. The mass was excised en-bloc and sent to pathology. The final pathology report was consistent with a large (12.5 × 4 cm) foreign body giant cell

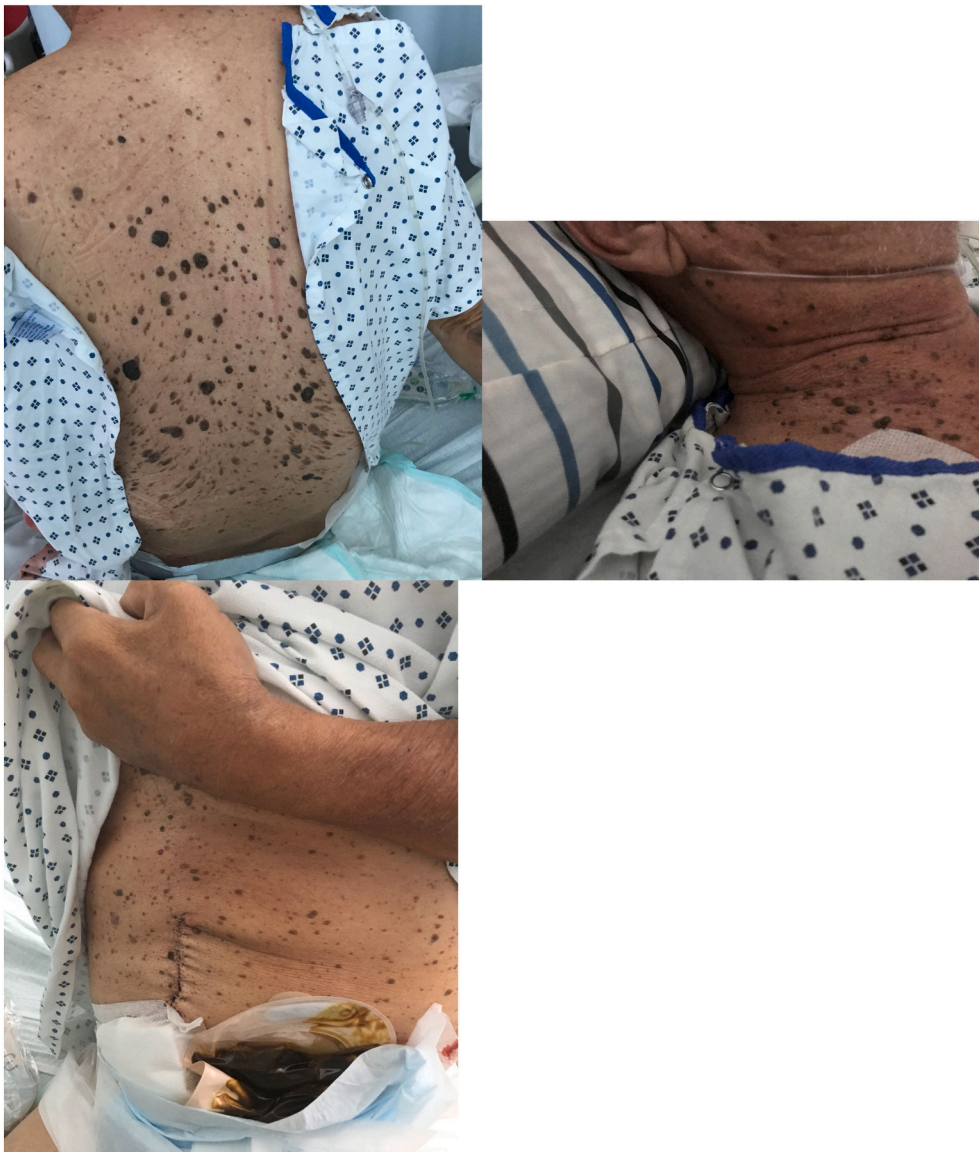


Fig. 1. (A) Back (B) Abdomen (C) Neck of the patient.

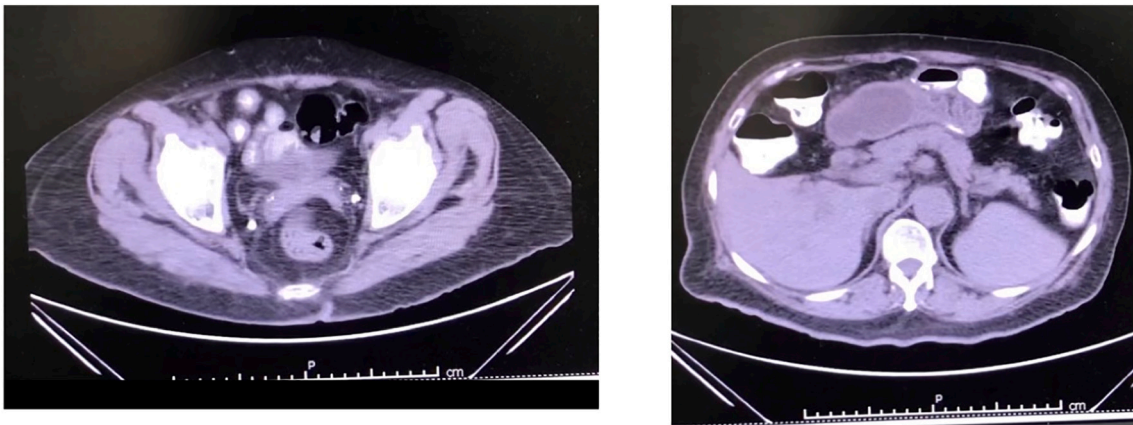


Fig. 2. CT scan showing inflammation on the small bowel.

granuloma (Image 3). No signs of malignancy were detected and 12 out of 12 lymph nodes were negative. Due to high suspicion for other gastrointestinal malignancies, esophagogastroduodenoscopy (EGD) was performed to rule out gastric cancer and was found negative. During post-operative evaluation, no changes on the skin lesions were noted.

3. Discussion

Leser-Trelat sign is a rare cutaneous manifestation that is usually related to gastrointestinal malignancies [1]. The most common association is gastric adenocarcinoma, but other gastrointestinal tract malignancies, prostate cancer, and lymphomas have also been reported [2]. Nonetheless, in a minority of cases, a malignant process is not found, thus LTS is referred to as pseudo-leser-trelat sign [3].

The pathophysiology of the LTS is not well understood, but various theories including the roles of certain growth factors (human growth

factor, EGF-alpha and EGFR) and inflammatory responses have been reported in the literature [1]. Some literature hypothesizes that tumor-derived epidermal growth factors induce epidermal proliferation and result in the rapid development of the characteristic skin lesions in LTS [4]. Furthermore, molecular genetics have shown that somatic fibroblast growth factor receptor 3 (FGFR3) and phosphatidylinositol 3- kinase catalytic subunit alpha (PIK3CA) are involved in the pathogenesis of seborrheic keratosis, but the precise mechanism is unknown [4].

Our patient, presented with an intra-abdominal neoplasm associated with an abrupt eruption of numerous cutaneous seborrheic keratosis similar to what happens in the LTS. The history and physical examination of our patient was suspicious of an underlying malignant process. Furthermore, the diagnostic workup revealed important information to suspect that this patient had a perforated tumor of the right colon. To our surprise the final pathology report was consistent with a giant cell foreign body granuloma.

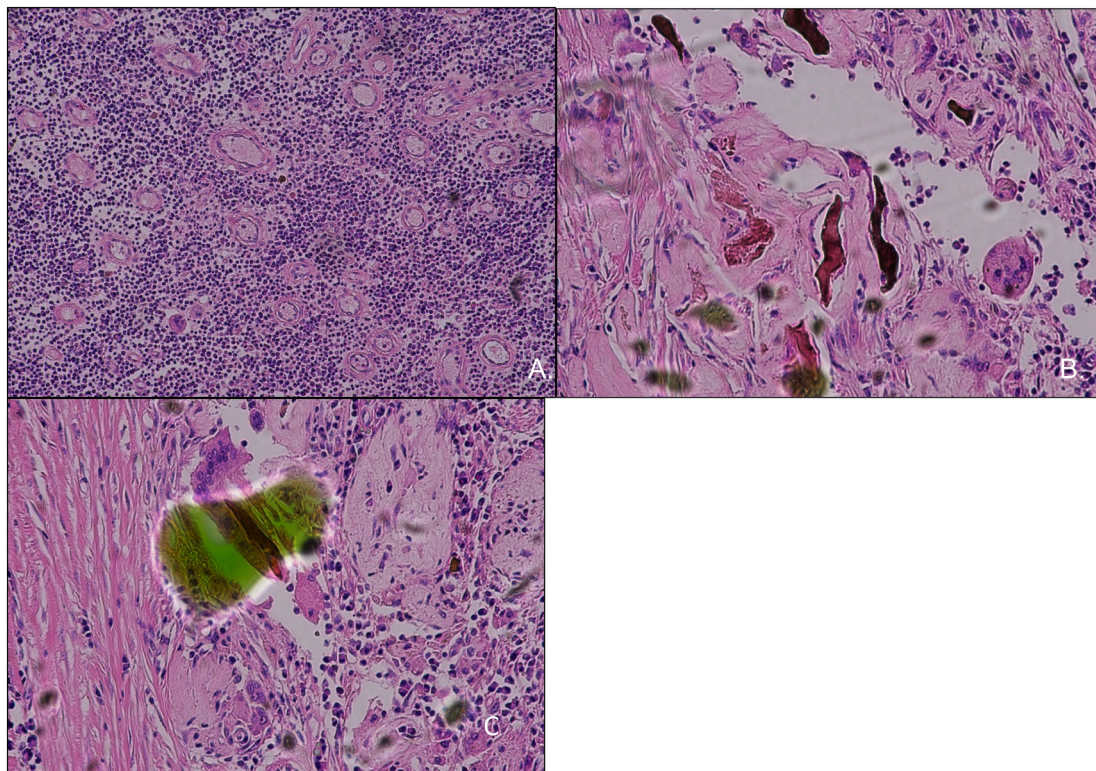


Fig. 3. A. Granulation tissue in low power. B. Giant cells and foreign body material. C. Giant cell engulfing foreign body.

Foreign substances that are introduced into the body can elicit an inflammatory process and form granulomas, these reactions can mimic malignant lesions [5]. Foreign body granulomas are usually associated with surgical material or undigested food [6]. Foreign body giant cell granulomas are formed in tissue when the size of the foreign particulate is too large to permit phagocytosis by macrophages [6,7]. Integrins 1 and 2, have been identified as a mediator for adhesion during monocyte to macrophage development and IL-4 induces the formation of the granuloma [6,7]. Our patient had an appendectomy 2 years prior to the onset of symptoms and this could have been the trigger for the formation of a foreign body granuloma (FBG).

We think that the simultaneous appearance of LTS and FBG may be secondary to the release of cytokines by the FBG that activates tumor-derived epidermal growth factors and induce epidermal proliferation, resulting in the rapid development of seborrheic keratosis. These cellular signaling pathways may be similar to the phenomenon we see in cancer patients, where the byproducts of the malignant neoplasm produce an uncontrolled proliferation of cytokines and growth factors, predisposing to the development of LTS.

4. Conclusion

This is the first case reported, as far as we know, where a giant cell foreign body granuloma presents with similar cutaneous manifestations of the Leser-Trelat sign. Foreign body granulomas are known to interact with multiple cellular signaling pathways, and this could be the source of its relationship with the Leser-Trelat sign. We think the cellular signaling pathways in FBG are similar to those ones found in malignant neoplasms of the gastrointestinal tract. This has led to the idea that FBG can provoke a cellular reaction that leads to LTS, and this is evidenced in the presentation of our case. Further molecular evaluation is needed to have a better understanding of the pathophysiologic mechanism behind the association of the Leser-Trelat sign and the formation of a foreign body granuloma.

Sources of funding

No funding received.

Ethical approval

Study is exempt from ethical approval.

Consent

Case report was approved by IRB committee.

Registration of research studies

Not applicable.

Guarantor

Patricia Mulero Soto.

CRediT authorship contribution statement

Mulero-Soto, Patricia: Data gathering, writing the paper.
 Sanchez-Vivaldi, Jorge: Data gathering, writing the paper.
 Rovira, Omar: Data gathering, writing the paper.
 Arocho, Juan: Data gathering, writing the paper.
 Pereira-Torrellas, Gabriel: Data gathering, writing the paper.
 Martinez-Trabal, Jorge: writing the paper.
 Bolaños-Avila, Guillermo: writing the paper.

Declaration of competing interest

No conflict of interest within any of the authors.

References

- [1] C.N. Bennett, G.J. Schmieder, Leser Trelat Sign, Available from:, StatPearls. StatPearls Publishing, 2020 https://pubmed.ncbi.nlm.nih.gov/29261959/?from_rm=Leser+Trelat+Sign&from_pos=1.
- [2] K. Chakradeo, K. Narsinghpura, A. Ekladios, Sign of Leser-Trélat, *BMJ Case Rep*, 2016 (2016), bcr2016215316, <https://doi.org/10.1136/bcr-2016-215316>.
- [3] Z. Husain, J.K. Ho, B.M. Hantash, Sign and pseudo-sign of Leser-Trélat: case reports and a review of the literature 12 (5) (2013) e79–e87. <https://pubmed.ncbi.nlm.nih.gov/23652964/>.
- [4] G. Safa, L. Darrieux, Leser-Trélat sign without internal malignancy, *Case Rep. Oncol*, 4 (1) (2011) 175–177, <https://doi.org/10.1159/000327363>.
- [5] P.B. Tripathi, S. Kini, A.D. Amarpurkar, Foreign body giant cell reaction mimicking recurrence of colon cancer, *Trop. Gastroenterol.* 30 (4) (2009) 219–220.
- [6] W.G. Brodbeck, J.M. Anderson, Giant cell formation and function, *Curr. Opin. Hematol.* 16 (1) (2009) 53–57, <https://doi.org/10.1097/MOH.0b013e32831ac52e>.
- [7] J.R. Rangel, Y. Chung, M. Rosenbach, A.F. Ziober, P.J. Zhang, A. Schaffer, Expression of notch signaling components in cutaneous foreign body and sarcoidal granulomas and fusing macrophages, *Am. J. Dermatopathol.* 36 (5) (2014) 409–413, <https://doi.org/10.1097/DAD.0b013e3282a730cb>.
- [8] R.A. Agha, T. Franchi, C. Sohrabi, G. Mathew, for the SCARE Group, The SCARE 2020 guideline: updating consensus Surgical CAse REport (SCARE) guidelines, *Int. J. Surg.* 84 (2020) 226–230.