

Retinoblastoma in twins: Risk assessment of genotypic variants

Vishal Raval, Meghan DeBenedictis¹, Randy Bowen, Hansell Soto, Jacquelyn Davanzo, Arun Singh

Purpose: To describe methods of risk assessment in twins with retinoblastoma (RB). **Methods:** A case series of four RB probands with a twin sibling. Family status, clinical presentation, and *RB1* germline status-based risk assessment were analyzed. **Results:** Two pairs had a positive family history (unilateral and bilateral RB in one of the parents (#1 and #2, respectively) and two pairs (#3 and #4) were sporadic. One of the familial twins (#1) had a high risk (90%) of manifesting RB in the twin. The other case (#2) with an absent *RB1* germline mutation in the twin had a 0% risk of developing RB. Among sporadic cases of twins (#3), genetic testing did not identify a germline mutation (tumor sample unavailable) in the proband which downgraded the risk of germline mutation from 15% to <1%. The twin never developed RB (5 years of age at last follow-up). Pathogenic mosaicism for germline *RB1* mutation (c.1723C>T) could be identified (tumor tissue available) in the proband (#4). Identical germline mutation (and RB tumor) was also noted in the twin. In each case, there was concordance between the assessed risk and manifestation of RB. **Conclusion:** Assessment of risk of RB in a twin presents with a unique challenge. Depending upon the genotype variant, the risk of developing RB can vary from 0% to 90%. In addition to family history, clinical manifestation in the proband, zygosity status, and *RB1* germline status are critical in formulating risk-appropriate surveillance guidelines.

Key words: Genetic testing, germline, mosaic, retinoblastoma, twins

Recommendations for the frequency and intensity of surveillance of newborn relatives of a proband with retinoblastoma (RB) are based on a calculated risk of RB tumor involvement.^[1,2] An estimated risk of developing RB can be calculated from the relationship of the infant with the proband, and the proband's tumor laterality (unilateral or bilateral),^[3,4] and the presence or absence of a germline *RB1* pathogenic variant in the proband.^[5,6] The current recommended screening guidelines published as a consensus report of the American Association of Ocular Oncologists and Pathologists allows clinicians to stratify children based on their expected risk for RB, depending on their relationship with the affected family member and refining that risk by genetic testing to optimize care.^[4] These guidelines were limited for the patient at risk, which was defined as a person with a family history of RB in a parent, sibling, or first- or second-degree relative.

Even if we consider the twin to be one of the siblings of the proband, the current guidelines do not include risk assessment in twin pregnancy, which in itself is a complex process. The assessment of risk in a twin having RB is dependent on various factors including existing parental history of RB, tumor laterality in the proband, and whether or not the proband has a heritable (germline *RB1* pathogenic variant) versus a sporadic form of RB. It is also important to realize the twin gestation (monozygotic or dizygotic).

Department of Ocular Oncology, Cole Eye Institute, Cleveland Clinic, Cleveland, Ohio, ¹Department of Genetics, Cleveland Clinic, Cleveland, Ohio, USA

Correspondence to: Dr. Arun Singh, Department of Ocular Oncology, Cole Eye Institute, Cleveland Clinic Foundation, Ohio, USA. E-mail: singha@ccf.org

Received: 01-Sep-2020

Revision: 04-Dec-2020

Accepted: 10-Dec-2020

Published: 30-Apr-2021

Access this article online

Website:

www.ijo.in

DOI:

10.4103/ijo.IJO_2811_20

Quick Response Code:



The reported number of twins is 32.6 per 1000 live births, out of which two-thirds are dizygotic twins and one-third are monozygotic twins.^[7] Considering the RB incidence of 1 in 20,000 live births in the United States,^[8,9] it can be estimated that 1 in 652 twins will be affected by RB. The current literature of RB in twins is limited to few case reports of phenotypic concordance or discordance in monozygotic or dizygotic twins.^[10-14]

We report an illustrative case series of four offsets of twins with RB. The germline status, tumor laterality, and twin zygosity (monozygotic or dizygotic) were defined for clinical risk assessment and correlated with the clinical course and *RB1* germline pathogenic variant.

Methods

A retrospective chart review of four probands with RB who had a twin sibling was analyzed. The study was approved by the institutional ethics committee and adhered to the tenets of the Declaration of Helsinki of medical research involving human subjects. All probands with RB underwent a detailed anterior segment and fundus examination under anesthesia for assessment of RB. The RB tumor was classified according to international intraocular RB classification. Probands underwent treatment according to standardized protocol depending

This is an open access journal, and articles are distributed under the terms of the Creative Commons Attribution-NonCommercial-ShareAlike 4.0 License, which allows others to remix, tweak, and build upon the work non-commercially, as long as appropriate credit is given and the new creations are licensed under the identical terms.

For reprints contact: WKHLRPMedknow_reprints@wolterskluwer.com

Cite this article as: Raval V, DeBenedictis M, Bowen R, Soto H, Davanzo J, Singh A. Retinoblastoma in twins: Risk assessment of genotypic variants. Indian J Ophthalmol 2021;69:1230-3.

upon the group staging of the tumor. Retcam® fundus photos were taken wherever it was possible. Magnetic resonance imaging (MRI) of the orbit and brain was performed (when indicated) to evaluate optic nerve extension or trilateral RB. A comprehensive birth and family history were obtained and the twin sibling of each proband also underwent an exam under anesthesia (EUA) for assessment of RB. Each family received formal genetic counseling by a state-licensed and board-certified genetic counselor during which a formal pedigree was obtained [Fig. 1] and genetic testing was discussed. After consent, genetic testing for RB in the proband was performed by a Clinical Laboratory Improvement Amendments (CLIA)-certified laboratory (Impact Genetics, Toronto, Canada).^[15] A tumor sample was provided for genetic analysis, when available. Upon review of the genetic testing results [Table 1], the genetic counselor facilitated appropriate family member testing, including that of the proband’s twin. Those family members had samples sent to the same lab for analysis and targeted familial variant analysis was performed.

Genetic testing methods

A combination of test methods listed below are employed (not all for every sample) by Impact Genetics (Toronto, Canada) to detect RB1 mutations^[15] sequence analysis of the RB1 core promoter (exons 1 through 27, including nearby flanking intronic regions). Such analysis can detect mosaic mutations at a level of 15% or greater. Reported polymorphisms are used for designing sequencing assays. Gross deletion/duplication analysis is performed using multiplex ligation-dependent probe amplification (MLPA) that simultaneously screens for small intra-exon insertions and deletions in RB1. The lab also performs a quantitative multiplex polymerase chain reaction (QM-PCR) test to measure the MYCN copy number in any tumor sample that does not have an RB1 mutation.^[16] Splice site analysis is done using a minimum of 25 nucleotides flanking each exon of RB1 to detect changes in splice sites. In silico analysis and scoring is used to determine whether a particular change is likely to cause missplicing. In the case of

an intronic variant of uncertain significance, RNA transcript analysis on a fresh blood sample is performed. Rapid detection of eleven recurrent RB1 mutations is done using allele-specific PCR (AS-PCR), which is then confirmed by sequence analysis. This highly sensitive technique can detect mutations at mosaic levels as low as 1% of mutant DNA. Aberrant methylation of the RB1 promoter leads to reduced transcription of RB1 that can initiate unilateral sporadic RB in the absence of an RB1 mutation. Methylation-specific PCR analysis is performed to detect methylation of the RB1 promoter in tumors.

Results

Family # 1 (Familial, Bilateral)

Proband (male)

A 2-month-old boy was seen in the clinic due to a family history of RB. Birth history of 37 weeks of twin gestation with a vaginal delivery was noted. Family history was significant for his mother with a history of bilateral RB for which she underwent enucleation in one eye and plaque brachytherapy in the other eye. She had not had genetic testing. Fundus examination of the proband showed a 7 × 6 × 3 mm RB in the macular area of the right eye (Group B) and 1 mm RB in the nasal quadrant of the left eye (Group A). The right eye was treated with plaque brachytherapy and with multiple sessions of transpupillary thermotherapy (TTT) and cryotherapy for control of the tumor. The left eye was initially treated with multiple sessions of cryotherapy; however, due to lack of complete response plaque brachytherapy was administered.^[17] Genetic testing was positive for a germline RB1 pathogenic variant (c.662_680del19). At last follow-up (12 years), both eyes had stable regressed tumors without evidence of trilateral RB (TRB) and secondary malignant neoplasms (SMN).

Twin (male)

Considering the positive family history, a planned fundus examination of the twin showed multiple bilateral small RB in superior and inferior quadrant, which were treated with multiple sessions of TTT and cryotherapy and remained stable at last follow-up. The targeted variant analysis was positive for the RB1 germline pathogenic variant (c.662_680del19) previously identified in the proband.

Family #2 (Familial, Unilateral)

Proband (female)

A 10-day-old baby girl was referred for an eye examination to assess for RB based on the strong family history of RB. Birth history of 37 weeks of twin gestation with cesarean section was noted. Family history was significant for her father having had unilateral RB (status post enucleation) with extended family members on the paternal side also having unilateral RB. Prenatal genetic testing was performed for the familial RB1 pathogenic variant. Results became available at 9 days of age and were positive (c.-189 G > T). EUA revealed two small RB (<0.5 mm) in the peripheral superonasal quadrant in the right eye (Group A) which were treated with multiple sessions of cryotherapy. At last follow-up (4 1/2 years) both the eyes were stable without evidence of trilateral RB.

Twin (male)

Prenatal genetic testing for the familial RB1 variant was negative, thus, reducing the necessity for continued RB surveillance.

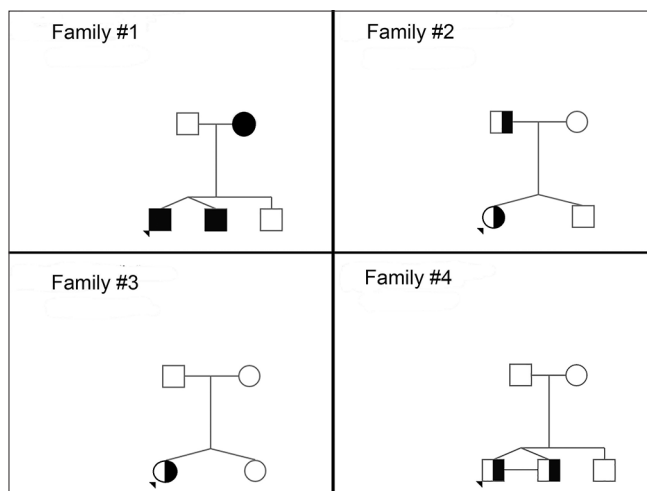


Figure 1: Pedigrees charts of four families with retinoblastoma in twins. The arrowhead (▾) shows the index case. Males are denoted as a square (□) and females denoted as circles (○). The full-shaded symbols represent bilateral retinoblastoma (■) while half-shaded ones represent unilateral retinoblastoma (◐). A horizontal line connecting the twins represents monozygosity

Table 1: Clinical status, family history, and genetic testing results in the proband and the twin

Family	Identical twins	Parent affected (Laterality)	Proband		Twin	
			Clinical Status (Laterality)	Mutation (sample)	Clinical Status (Laterality)	Mutation (sample)
#1	Yes	Mother (B/L)	Affected (B/L)	c.662_680del19 (blood)	Affected (B/L)	c.662_680del19 (blood)
#2	No	Father (U/L)	Affected (U/L)	c.-189 G > T (blood)	Unaffected	Absent
#3	No	None	Affected (U/L)	Absent	Unaffected	Not done
#4	Yes	None	Affected (U/L)	c.1723C > T (blood/tumor)	Affected (U/L)	c.1723C > T (blood)

Family # 3 (Sporadic, Unilateral)

Proband (female)

A 20-month-old girl was referred for management of RB in the right eye. Birth history of 34 weeks of twin gestation with cesarean section was noted. Family history was negative for RB. Fundus examination in the right eye showed a 15 × 13 × 10 mm nasal calcified mass with diffuse subretinal and vitreous seeding with inferior exudative retinal detachment (Group D). She received five cycles of intra-arterial chemotherapy with melphalan and topotecan along with intravitreal chemotherapy. Genetic testing did not identify a pathogenic variant in *RB1* in her blood. A tumor sample was not available for genetic analysis. At last follow-up (age 4.5 years), a calcified tumor with no evidence of new tumor or recurrence of vitreous seeding was noted.

Twin (female)

Fundus examination was normal with no evidence of RB. Since no pathogenic variant in *RB1* was detected in the proband, genetic testing was not clinically indicated.

Family # 4 (Sporadic Mosaic, Unilateral)

Proband (male)

A 1-year-old boy was referred to rule out RB in the left eye. Birth history of 38 weeks of twin gestation with a vaginal delivery was noted. Family history was negative for RB. Fundus examination showed Group E RB in the left eye for which enucleation of the eye was performed. Genetic testing identified mosaicism for a germline *RB1* variant, c.1723C > T. Twenty percent of his blood leukocytes were positive for this variant, consistent with germline mosaicism. While this result meant his older brother and parents were not at risk for having this variant, his twin brother was at risk in the event they were monozygotic twins (parents reported they were identical). At last follow-up (1 year), there was no evidence of tumor in the unaffected eye or TRB and SMN.

Twin (male)

Considering the possibility of monozygosity and the presence of germline mosaicism in the proband, fundus examination in the twin was performed within 1 month which showed a small RB (Group A) in the left eye, and hence cryotherapy was performed. The targeted variant analysis was positive for the pathogenic *RB1* variant detected in the proband. The variant was also mosaic in this patient, with approximately 5–10% of his blood leukocytes positive. At last follow-up (1 year), both the eyes were stable with no evidence of a new tumor.

Discussion

Twin zygosity is one of the main factors in determining the risk of RB recurrence in twins. It is important to differentiate

twins in terms of zygosity as monozygotic twins originate from a single fertilized egg (zygote) thereby having the same risk of hereditary disease. In dizygotic twins, two eggs are fertilized by two separate sperms and hence they share 50% of their genetic information, like any other sibling. Several postzygotic mechanisms can explain discordance even in “identical” twins.^[18] The monozygotic twins may even be discordant for the development of RB.^[19] Mosaicism, by affecting the proportion of cells with *RB1* mutation may underlie discordance.^[20-22] Various methods have been used to determine twin zygosity including blood typing and genders of newborns, Human Leukocyte Antigen (HLA) typing, chorionicity (monozygotic or dichorionic) evaluation by prenatal ultrasonography, and the examinations of the placenta after delivery;^[23] however, none of them are as accurate as genetic analysis using PCR-based technology.^[24]

In Family #1 (familial RB), both twins had a prior risk of 50% of having had inherited a pathogenic *RB1* variant from their mother.^[25]

In Family#2, the estimated risk of RB was estimated to be 50% considering the parental history of RB. However, the twin did not have germline *RB1* mutation which reduced the risk of RB to <1% (as in the general population) thereby avoiding multiple examinations under anesthesia visits and intense surveillance.^[26,27] The zygosity testing would not have provided added value in the presence of the known *RB1* germline mutation. Moreover, almost all opposite-sex twin pairs are dizygotic.^[28]

In Family#3, with sporadic unilateral RB in the proband, the risk of a germline *RB1* mutation is estimated to be 15%.^[29] Given the proband did not have a germline variant identified on genetic testing, but because tumor sample was not available for genetic analysis, her residual risk of having a germline *RB1* mutation was estimated to be less than 1% (false negative detection rate of 0.4%, $15 \times 0.4 = 0.6\%$). The zygosity testing was not done as the pregnancy was associated with two distinct placentas indicating dizygosity. Given the low risk of RB in the twin, only office exams instead of EUA was recommended. She did not develop RB until the age of 4.5 years.

In presence of tumor sample-detection of germline, *RB1* mutation can be more definite about positive or negative results as the mutation identified in the tumor sample is searched for in the blood sample. Using current technologies, the sensitivity of detecting germline mutations in the bilateral proband is as high as 96.6% (757 samples tested) and 92.5% in a unilateral proband with a positive family history of 96.2% (789 samples tested).^[15] With recent advances in the use of a liquid biopsy, the aqueous sample may be an adequate substitute for the RB tumor.^[30]

In Family#4, the estimated risk of RB in the twin was more complex considering the presence of germline mosaicism and assumed monozygosity of the twins. The zygosity testing was not done as the pregnancy was associated with a single placenta indicating monozygosity.^[28] The twin was assumed to have a 90% risk of developing RB and examined under anesthesia revealing a tumor, which was consistent with the results of the targeted variant analysis being positive for the pathogenic *RB1* variant detected in the proband. The zygosity testing would not have provided added value in the presence of the known *RB1* germline mutation.

Conclusion

Assessment of risk of RB in a twin presents with a unique challenge. Depending upon the genotype variant the risk of developing RB can vary from 0% to as high as 90%. In addition to positive family history, clinical manifestation in the proband, and accurate determination of zygosity status are critical in formulating risk-appropriate surveillance guidelines. Genetic counseling and *RB1* genetic testing should be considered in all cases.

Declaration of patient consent

The authors certify that they have obtained all appropriate patient consent forms. In the form, the patient(s) has/have given his/her/their consent for his/her/their images and other clinical information to be reported in the journal. The patients understand that their names and initials will not be published and due efforts will be made to conceal their identity, but anonymity cannot be guaranteed.

Financial support and sponsorship

This work was supported by an unrestricted departmental grant from Research to Prevent Blindness Challenge Grant, to the Cole Eye Institute, Cleveland Clinic.

Conflicts of interest

There are no conflicts of interest.

References

- Skalet AH, Gombos DS, Gallie BL, Kim JW, Shields CL, Marr BP, *et al.* Screening children at risk for retinoblastoma: Consensus report from the American Association of ophthalmic oncologists and pathologists. *Ophthalmology* 2018;125:453-8.
- Singh N, DeBenedictis MJ, Singh AD. An online application for retinoblastoma surveillance. *Ocul Oncol Pathol* 2020;6:376-80.
- Knudson AG Jr. Mutation and cancer: Statistical study of retinoblastoma. *Proc Natl Acad Sci U S A* 1971;68:820-3.
- Musarella MA, Gallie BL. A simplified scheme for genetic counseling in retinoblastoma. *J Pediatr Ophthalmol Strabismus* 1987;24:124-5.
- Gallie BL. Gene carrier detection in retinoblastoma. *Ophthalmology* 1980;87:591-5.
- Dhar SU, Chintagumpala M, Noll C, Chévez-Barrios P, Paysse EA, Plon SE. Outcomes of integrating genetics in management of patients with retinoblastoma. *Arch Ophthalmol* 2011;129:1428-34.
- Martin JA, Hamilton BE, Osterman MJ. Births in the United States, 2018. *NCHS Data Brief* 2019;1-8.
- Broadus E, Topham A, Singh AD. Incidence of retinoblastoma in the USA: 1975-2004. *Br J Ophthalmol* 2009;93:21-3.
- Kivelä T. The epidemiological challenge of the most frequent eye cancer: Retinoblastoma, an issue of birth and death. *Br J Ophthalmol* 2009;93:1129-31.
- Benedict WL. Homologous retinoblastoma in identical twins. *Trans Am Ophthalmol Soc* 1929;27:173-6.
- Kanter YC, Harris JE. Retinoblastoma occurring in one of a pair of identical twins. *Arch Ophthalmol* 1964;72:783-7.
- Brindley BI, Collins JD Jr. Bilateral retinoblastoma in identical twins: Report of a case with a review of the literature. *Arch Ophthalmol* 1961;66:37-41.
- Migdal C. Spontaneous regression of retinoblastoma in identical twins. *Br J Ophthalmol* 1982;66:691-4.
- Abraham A, Thirumalairaj K, Gaikwad N, Muthukkaruppan V, Reddy AG, Thangaraj K, *et al.* Retinoblastoma discordance in families with twins. *Indian J Ophthalmol* 2019;67:436-9.
- Available from: <https://impactgenetics.com/testing-services/retinoblastoma/info-for-rb-clinicians/>.
- Rushlow DE, Mol BM, Kennett JY, Yee S, Pajovic S, Thériault BL, *et al.* Characterisation of retinoblastomas without *RB1* mutations: Genomic, gene expression, and clinical studies. *Lancet Oncol* 2013;14:327-34.
- Echegaray JJ, Al-Zahrani YA, Singh A. Episcleral brachytherapy for retinoblastoma. *Br J Ophthalmol* 2020;104:208-13.
- Machin G. Non-identical monozygotic twins, intermediate twin types, zygosity testing, and the non-random nature of monozygotic twinning: A review. *Am J Med Genet C Semin Med Genet* 2009;151C: 110-27.
- Marcus DM, Papastergiou GI, Patel M, Pandya A, Brooks SE. Discordant retinoblastoma in monozygotic twins. *Am J Ophthalmol* 1999;128:524-6.
- DeBenedictis MJ, Singh AD. Retinoblastoma: Genetic counseling and testing. In: Kim JW, Damato B, Singh AD, editors. *V.R.J.L.B. Clinical Ophthalmic Oncology*. 3rd ed. New York: Springer Nature; 2019. Chapter 9, p. 107-17.
- Greger V, Passarge E, Horsthemke B. Somatic mosaicism in a patient with bilateral retinoblastoma. *Am J Hum Genet* 1990;46:1187-93.
- Sippel KC, Fraioli RE, Smith GD, Schalkoff ME, Sutherland J, Gallie BL, *et al.* Frequency of somatic and germ-line mosaicism in retinoblastoma: Implications for genetic counseling. *Am J Hum Genet* 1998;62:610-9.
- Scardo JA, Ellings JM, Newman RB. Prospective determination of chorionicity, amnionity, and zygosity in twin gestations. *Am J Obstet Gynecol* 1995;173:1376-80.
- Wachtel SS, Somkuti SG, Schinfeld JS. Monozygotic twins of opposite sex. *Cytogenet Cell Genet* 2000;91:293-5.
- Draper GJ, Sanders BM, Brownbill PA, Hawkins MM. Patterns of risk of hereditary retinoblastoma and applications to genetic counselling. *Br J Cancer* 1992;66:211-9.
- Richter S, Vandezande K, Chen N, Zhang K, Sutherland J, Anderson J, *et al.* Sensitive and efficient detection of *RB1* gene mutations enhances care for families with retinoblastoma. *Am J Hum Genet* 2003;72:253-69.
- Noorani HZ, Khan HN, Gallie BL, Detsky AS. Cost comparison of molecular versus conventional screening of relatives at risk for retinoblastoma. *Am J Hum Genet* 1996;59:301-7.
- Cutler TL, Murphy K, Hopper JL, Keogh LA, Dai Y, Craig JM. Why accurate knowledge of zygosity is important to twins. *Twin Res Hum Genet* 2015;18:298-305.
- Dudgeon J. Unilateral retinoblastoma--genetic implications. *Br J Ophthalmol* 1996;80:193.
- Berry JL, Xu L, Murphree AL, Krishnan S, Stachelek K, Zolfaghari E, *et al.* Potential of aqueous humor as a surrogate tumor biopsy for retinoblastoma. *JAMA Ophthalmol* 2017;135:1221-30.