



Effective treatment with Tocilizumab in a COVID-19 patient on maintenance hemodialysis: A case report

Nicole Nourie¹ · Mohamed Ammar Chamaa² · Sarah Mouawad¹ · Micheline Mia Kotait¹ · Serge Finianos¹ · Hiba Azar¹ · Dania Chelala¹

Received: 3 November 2020 / Accepted: 8 January 2021 / Published online: 27 January 2021
© Japanese Society of Nephrology 2021

Abstract

Coronavirus disease 2019 (COVID-19) is a rapidly spreading infective disease caused by the severe acute respiratory syndrome coronavirus 2 virus (SARS-CoV-2). The management of this disease remains a challenge particularly in certain subgroups of patients such in hemodialysis patients who have higher exposure rates due to the nature of their in-hospital care, and higher mortality due to their burden of comorbidities. We report a case of a 52-year-old patient with Von Hippel Lindau syndrome and end-stage renal disease on hemodialysis who contracted COVID-19 infection. Despite the patient's rapidly deteriorating clinical status he was successfully treated with Tocilizumab, after which he showed rapid improvement in his clinical, biological and radiological parameters. Although few studies were available regarding the use of Tocilizumab in the dialysis population, its use proved to be effective and well tolerated in our patient.

Keywords COVID-19 · Hemodialysis · Tocilizumab

Abbreviations

COVID-19	Coronavirus disease 2019
SARS-CoV-2	Severe acute respiratory syndrome coronavirus 2 virus
ESRD	End-stage renal disease
VHL	Von Hippel Lindau
PCR	Polymerase chain reaction
ICU	Intensive care unit
APACHE	Acute physiologic assessment and chronic health evaluation
SOFA	Sequential organ failure assessment
IL-6	Interleukin 6
IL-6R	Interleukin 6 receptor
CRS	Cytokine release syndrome
MERS	Middle East respiratory syndrome
SARS	Severe acute respiratory syndrome
NM	Not mentioned

Background

Since late December 2019, the world is witnessing a rapidly evolving healthcare emergency, manifesting as an unparalleled humanitarian and economic burden.

The novel Coronavirus disease (coronavirus disease 2019 or COVID-19) was first reported in Wuhan, a city in the Hubei province of China [1] and has since spread to 235 countries or regions resulting in an ongoing pandemic. As of early December 2020, over 61.8 million cases and 1.4 million deaths have been reported worldwide according to the World Health Organization situation reports.

It has been reported in multiple studies that old age, hypertension, diabetes, immunosuppression and cardiovascular diseases are risk factors associated with increased morbidity and mortality [2]. These comorbidities are common in patients with end-stage renal disease (ESRD) undergoing chronic hemodialysis explaining the higher mortality rate in this population ranging from 13 to 30.5% in recent studies [3, 4].

✉ Nicole Nourie
nicolenourie@yahoo.com

¹ Nephrology Department, Saint-Joseph University, Hôtel Dieu de France, Beirut, Lebanon

² Pulmonary and Critical Care Department, Saint-Joseph University, Hôtel Dieu de France, Beirut, Lebanon

Case presentation

A 51-year-old male patient presented to the emergency department for a two-day history of fever and cough (Fig. 1). The patient is known to have ESRD on maintenance hemodialysis three times weekly at our center since late 2012. He is known to have Von Hippel-Lindau (VHL) disease with many of its systemic manifestations including hemangioblastomas of the brain and spine, retinal hemangioblastoma, bilateral renal clear cell carcinoma leading to bilateral nephrectomy and adrenalectomy, and a serous cystadenoma of the pancreas. He also has a history of hypertension on multi-drug therapy including an angiotensin receptor blocker, diabetes and coronary heart disease with ischemic cardiomyopathy, he underwent percutaneous coronary intervention to the left anterior descending artery 8 months prior to this admission. His last admission four months prior to this presentation was for ascending cholangitis treated with antibiotics and endoscopic drainage.

At the emergency department, the patient was looking ill, complaining of dry cough, dyspnea and fever. A high-resolution CT of the chest revealed multiple parenchymal consolidations associated with multifocal ground-glass opacities. These findings were suggestive of a COVID-19 pneumonia in the setting of the pandemic, and the patient was admitted to our COVID-19 isolated floor unit pending PCR results.

Due to the patient's symptoms, imaging findings highly suggestive of COVID-19 disease and his rapidly deteriorating clinical status including high-grade fever and increased oxygen requirements, he was started upon admission on Azithromycin, Hydroxychloroquine and Piperacillin/tazobactam.

Our center is not equipped with negative pressure dialysis facilities; this implied the patients transfer to the dedicated COVID-19 intensive care unit to have his dialysis sessions. Upon his admission to the ICU the patient presented with an APACHE score of 16 and a SOFA score of 13. He developed on day 7 of the illness a rapidly progressive respiratory distress leading to his urgent intubation, and the patient was started on hydrocortisone 50 mg QID and norepinephrine.

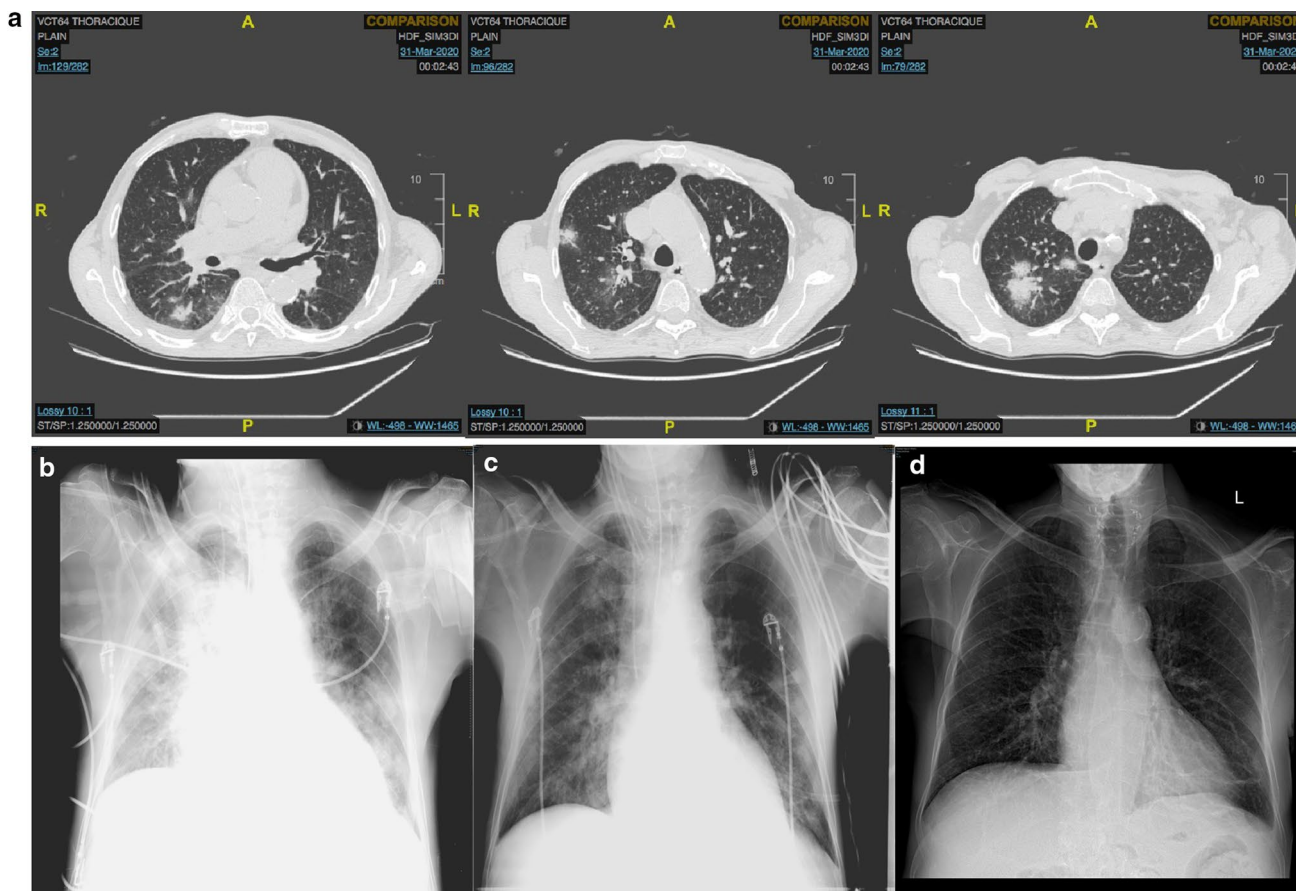


Fig. 1 Radiographic imaging of the patient. **a** Axial chest CT on admission. **b** Chest radiograph upon first intubation. **c** Chest radiograph 3 days later. **d** Chest radiograph on discharge

His clinical status deteriorated with respiratory failure and diffuse patchy infiltrate present on imaging, we decided to treat him with 400 mg of Tocilizumab despite the lack of data concerning this molecule in the hemodialysis population.

Two days later the patient presented with a prolonged QT interval (503 ms) requiring the discontinuation of Azithromycin, and Hydroxychloroquine. On day 11 of the illness, he was extubated but intubated again on day 14 secondary to increased bronchial secretions caused by superimposed bacterial pneumonia leading to septic shock with increased dosage of norepinephrine and antibiotic step up to Meropenem.

On day 27 of the illness the patient presented with a fever indicating a second bacterial pneumonia which was later known to be secondary to *Stenotrophomonas Maltophilia* found in sputum and blood cultures, treated for a total of two weeks with Levofloxacin and Ceftazidime. He was extubated on day 34 of his illness (Fig. 1).

Throughout these many complications a total of seven PCRs were performed and remained positive. On day 41 of the illness, the patient was treated with ivermectin for a total of three days. Table 1 shows the evolution of the biological parameters.

The last positive PCR was on day 48 of his illness with a negative PCR 52 days after the onset of symptoms, adding up to a total of 52 days of viral shedding. Later, after a second negative PCR the patient was transferred to our floor unit where he was rehabilitated and discharged on day 69.

Discussion and conclusions

Patients with CKD-5D are prone to infectious complications, sepsis being a major cause of mortality in hemodialysis patients after cardiovascular disease with an annual

percentage of a 100 to 300-fold higher than the general population [5].

Both the innate and adaptive immunity are impaired in patients with ESRD with in-vitro evidence of a decrease in T-cell proliferation attributed to impairment in antigen-presenting cells and toll-like receptors. Additionally, a decreased expression of Bcl2 leads to increased apoptosis of B cell lymphocytes [6] but with no consequence on IgM and IgG secretion.

Hypercytokinemia is present in patients with ESRD secondary to decreased renal elimination along with increased secretion of pro-inflammatory cytokines secondary to the continuous inflammatory state, oxidative stress, and uremic toxins [7]. Interleukin 6 (IL-6) is one of the most studied pro-inflammatory factors in uremic patients, its presence as a mediator of acute-phase response, increases the risk of malnutrition, cardiovascular disease and mortality, and it has been discussed whether anti-cytokine therapy can play a role in this population regarding reversal of cardiovascular mortality [8].

By binding to its receptor (IL-6R), IL-6 system has a role in promoting an inflammatory state via its action on activation, recruitment and differentiation of lymphocytes. The early reports from Wuhan also showed increased levels of IL-6 in critically ill patients with COVID-19 [9].

Tocilizumab, a monoclonal antibody targeting the IL-6R, previously approved for the treatment of chimeric antigen receptor T cell-induced cytokine release syndrome (CRS) and in various rheumatoid diseases such as rheumatoid arthritis, resurfaced during the beginning of the COVID-19 pandemic. The rationale behind its use is extrapolated from promising data previously reported during the previous MERS and SARS pandemics.

Tocilizumab is a well-known molecule within the nephrology community, it has been used in desensitization

Table 1 Evolution of the biological parameters

Measure	Reference range	Illness day 4	Illness day 7	Illness day 22	Illness day 56
White cell count (* 10 ⁹ /l)	4–9	5	5.1	15.8	3.9
Absolute neutrophil count (* 10 ⁹ /l)	2–7.02	3.11	3.27	14.6	2.51
Absolute lymphocyte count (* 10 ⁹ /l)	0.8–4.05	1.4	1.59	0.28	0.99
Hemoglobin (g/dl)	14–18	11.8	10.4	9	7.9
Hematocrit (%)	45–54	37	32.6	27	24.2
Platelet count (* 10 ⁹ /l)	150–400	111	80	106	171
C- reactive protein (mg/l)	< 3.5	62.2	242	28.4	66
Procalcitonin (ug/l)	< 0.1	NA	38.3	2.6	NA
Lactic acid (mmol/l)	0.7–2.1	NA	1.1	NA	NA
Triglyceride (mmol/l)	< 1.69	1.51	NA	2.89	NA
Ferritine (ng/ml)	30–400	651	2267	3337	NA
D-Dimeres (ug/ml)	< 0.5	9.66	NA	20	NA
Fibrinogene (g/l)	2–4	3.51	NA	2.33	NA

Table 2 The characteristics, clinical course and outcomes of COVID-19 patients treated with Tocilizumab

Author	Sex	Age (years)	Diabetes	Hypertension	Car- diovascular disease	Il-6 dosage (pg/ml)	Oxygen therapy	ARDS	Intubation	In hospital stay	(days) Improvement after Tocili- zumab	Viral shedding (days)
Ferrey AJ et al. [12]	M	56	No	Yes	Yes	Elevated	Yes	Yes	Yes	Ongoing at the time of publication	Critical condition at the time of publication	Still positive at the time of publication
Hammami MB et al. [13]	M	63	Yes	Yes	Yes	203.78	No	No	No	16	Yes	25
Castellano G et al. [14]	F	49	NM	NM	NM	41.07	Yes	No	No	NM	Yes	37
Castellano G et al. [14]	F	36	NM	NM	NM	NM	Yes	No	No	NM	Yes	NM
Castellano G et al. [14]	M	70	Yes	NM	Yes	NM	Yes	No	No	NM	Yes	NM
Stephen S et al. [15]	F	72	No	No	No	1959.7	Yes	Yes	Yes	42	Yes	56
Abe T et al. [16]	F	68	Yes	NM	NM	93.6	Yes	Yes	Yes	NM	Yes	36
Our patient	M	51	Yes	Yes	Yes	Not done	Yes	Yes	Yes	69	Yes	52

NM not mentioned

protocols of kidney transplant recipients and It is recently gaining a more promising role in the treatment of chronic active antibody-mediated rejection in kidney transplantation [10].

Tocilizumab had not been studied in patients with a CrCl of less than 30 ml/min and neither on patients undergoing maintenance hemodialysis, and its use in this population was limited to case reports. M. Iwamoto et al. described in 2009 its successful use in a 64-year old woman with rheumatoid arthritis on hemodialysis [11]. Early on during the COVID-19 pandemic, some case reports were published showing favorable results after the administration of Tocilizumab in COVID-19 patients on hemodialysis [12–16]. The characteristics, clinical course and outcomes of these patients are summarized in Table 2.

It is worth mentioning that the lack of serum IL-6 measurement at baseline and following Tocilizumab administration in our patient is a limitation towards concretizing its effect.

On another note, prolonged viral shedding is not exceptional in patients with ESKD, it has been described in other viral illnesses such as hepatitis C [17], and during the 2003 SARS outbreak with a persistent viral shedding for up to 8 weeks [18]. A case series of 22 patients on maintenance hemodialysis who tested positive for COVID-19, showed prolonged duration of viral shedding. In 32% of the patients, the tests remained positive 40 days after the first positive test, and 5 of those patients continued to test positive after a median of 52 days following the diagnosis [19]. Our patient showed a similar viral shedding period, therefore one might conclude that the impact of Tocilizumab on viral shedding is limited.

The use of a single dose of 400 mg of Tocilizumab was effective and well tolerated in our patient, who was afebrile 24 h later with rapid improvement of biological and radiological parameters, with no directly related adverse effects.

Its use in this subgroup of COVID-19 positive population should be further studied to better define its potential role in an overly stimulated immune system.

Acknowledgements To the patient and his family for their trust.

Author contributions NN performed the literature review and wrote the initial draft of the manuscript. AC, SM, MK and SF assisted with the data collection and case presentation. DC and HA assisted with the drafting and editing of the manuscript. DC was the treating physician for the patient. All authors read and approved the final manuscript.

Availability of data and materials All data generated or analyzed during this study are included in this published article.

Compliance with ethical standards

Competing interests The authors declare that they have no competing interests.

Consent for publication Written informed consent was obtained from the patient for publication of this Case report and any accompanying images. A copy of the written consent is available for review by the Editor of this journal.

References

- Zhu N, Zhang D, Wang W, Li X, Yang B, Song J, et al. A Novel Coronavirus from Patients with Pneumonia in China, 2019. *N Engl J Med.* 2020;382(8):727–33.
- Tian W, Jiang W, Yao J, et al. Predictors of mortality in hospitalized COVID-19 patients: a systematic review and meta-analysis. *J Med Virol.* 2020.
- Rombolà G, Brunini F. COVID-19 and dialysis: why we should be worried. *J Nephrol.* 2020;22:1–3.
- Goicoechea M, Sánchez Cámara LA, Macías N, et al. COVID-19: clinical course and outcomes of 36 hemodialysis patients in Spain. *Kidney Int.* 2020;98(1):27–34.
- Sarnak MJ, Jaber BL. Mortality caused by sepsis in patients with end-stage renal disease compared with the general population. *Kidney Int.* 2000;58(4):1758–64.
- Fernández-Fresnedo G, Ramos MA, González-Pardo MC, de Francisco AL, López-Hoyos M, Arias M. B lymphopenia in uremia is related to an accelerated in vitro apoptosis and dysregulation of Bcl-2. *Nephrol Dial Transplant Off Publ Eur Dial Transpl Assoc Eur Ren Assoc.* 2000;15(4):502–10.
- Kato S, Chmielewski M, Honda H, Pecoits-Filho R, Matsuo S, Yuzawa Y, et al. Aspects of Immune Dysfunction in End-stage Renal Disease. *Clin J Am Soc Nephrol CJASN.* 2008;3(5):1526–33.
- Stenvinkel P, Barany P, Heimbürger O, Pecoits-Filho R, Lindholm B. Mortality, malnutrition, and atherosclerosis in ESRD: what is the role of interleukin-6? *Kidney Int Suppl.* 2002;80:103–8.
- Chen N, Zhou M, Dong X, Qu J, Gong F, Han Y, et al. Epidemiological and clinical characteristics of 99 cases of 2019 novel coronavirus pneumonia in Wuhan, China: a descriptive study. *The Lancet.* 2020;395(10223):507–13.
- Lavacca A, Presta R, Gai C, Mella A, Gallo E, Camussi G, et al. Early effects of first-line treatment with anti-interleukin-6 receptor antibody tocilizumab for chronic active antibody-mediated rejection in kidney transplantation. *Clin Transplant.* 2020;34(8):e13908. <https://doi.org/10.1111/ctr.13908>.
- Iwamoto M, Honma S, Asano Y, Minota S. Effective and safe administration of tocilizumab to a patient with rheumatoid arthritis on haemodialysis. *Rheumatol Int.* 2011;31(4):559–60.
- Ferrey AJ, Choi G, Hanna RM, Chang Y, Tantisattamo E, Ivaturi K, et al. A Case of Novel Coronavirus Disease 19 in a Chronic Hemodialysis Patient Presenting with Gastroenteritis and Developing Severe Pulmonary Disease. *Am J Nephrol.* 2020;51(5):337–42.
- Hammami MB, Garibaldi B, Shah P, Liu G, Jain T, Chen P-H, et al. Clinical course of COVID-19 in a liver transplant recipient on hemodialysis and response to tocilizumab therapy: A case report. *Am J Transplant.* 2020;20(8):2254–9.
- Castellano G, Infante B, Mercuri S, et al. Treatment of COVID-19 atypical pneumonia by early Tocilizumab administration in “non-critically-ill” patients on hemodialysis. *J Nephrol.* 2020;1–4.
- Stephen S, Park Y-A, Chrysostomou A. Clinical benefits of Tocilizumab in COVID-19-related cytokine release syndrome in a patient with end-stage kidney disease on haemodialysis in Australia. *Nephrol Carlton Vic.* 2020;25(11):845–9.

16. Abe T, Izumo T, Ueda A, et al. Successful treatment of two Japanese ESRD cases with severe COVID-19 pneumonia. *CEN Case Rep.* 2020.
17. Okuda K, Hayashi H, Yokozeki K, Kobayashi S, Kashima T, Irie Y. Acute hepatitis C among renal failure patients on chronic haemodialysis. *J Gastroenterol Hepatol.* 1998;13(1):62–7.
18. Kwan BCH, Leung CB, Szeto CC, Wong VWS, Cheng YL, Yu AWY, et al. Severe acute respiratory syndrome in dialysis patients. *J Am Soc Nephrol.* 2004;15(7):1883–8.
19. Shaikh A, Zeldis E, Campbell KN, Chan L. Prolonged SARS-CoV-2 Viral RNA Shedding and IgG Antibody Response to SARS-CoV-2 in Patients on Hemodialysis. *Clin J Am Soc Nephrol.* 2020.

Publisher's Note Springer Nature remains neutral with regard to jurisdictional claims in published maps and institutional affiliations.