

Suspect the unexpected: A rare association of Autoimmune Hemolytic Anemia and Hemophagocytic Lymphohistiocytosis with Visceral Leishmaniasis: A Case Report and Review of Literature

Aman Elwadhi, MD^{1*}, Neha KC, MBBS¹, Kamal Joshi, MBBS¹, G Krishna Charan, MBBS¹

¹Department of Pediatrics, All India Institute of Medical Sciences, Rishikesh, Uttarakhand, India

Article Info

Author of correspondence:

Dr. Aman Elwadhi, MD, Department of Pediatrics;

E-mail: elwadhiaman@gmail.com;

Tel.: +919810943681;

Address:

All India Institute of Medical Sciences, Rishikesh, Uttarakhand, India – 249203.

Keywords

Autoimmune hemolytic anemia, Hemophagocytic lymphohistiocytosis, Visceral Leishmaniasis

Abstract

Visceral leishmaniasis is a common tropical infection presenting with a myriad of hematological abnormalities. We report an unusual case of an 11-year-old girl suffering from a febrile illness with hepatosplenomegaly and anemia. Laboratory findings included pancytopenia and hyperbilirubinemia. The leishmania antigen rK39 was positive and bone marrow examination revealed hemophagocytosis and amastigote forms of *Leishmania donovani*. Direct Coombs' test was positive (warm type, IgG) and LDH was elevated. Tests for other infections were negative. A diagnosis of visceral leishmaniasis with autoimmune hemolytic anemia (warm antibody type, IgG) with hemophagocytic lymphohistiocytosis was made. Patient showed response with anti-leishmanial treatment with improvement in clinical condition.

Introduction

Visceral leishmaniasis (VL) is an intracellular protozoal infection caused by *Leishmania donovani* and transmitted by infected sandfly *Phlebotomus argentipes*. India, Bangladesh, Nepal, Sudan and Brazil are home to more than 90% of cases of VL in the world.¹

Anemia is almost always present in VL and has multifactorial pathogenesis but Coombs' positive hemolytic anemia is rarely reported.² Likewise, Hemophagocytic lymphohistiocytosis (HLH) secondary to VL is very rare and overlap in the clinical characteristics of VL and HLH can be a diagnostic challenge.³ Here we present a rare case of hemolytic anaemia and HLH in a case of VL.

Case report

An 11-year-old girl resident of Nepal presented with fever and abdominal distension for 2 months. She had anorexia and weight loss with no history of rash, bleeding, jaundice, blood transfusions or contact with tuberculosis. She was developmentally appropriate and unimmunized. This thin built girl had pallor, icterus and bilateral pitting pedal edema with no palpable lymph nodes, bone pains or clubbing. There was firm, non-tender hepatomegaly of 5 cm below costal margin with span of 10 cm and firm splenomegaly of 10 cm below costal margin. There was no free fluid in the abdomen. Other organs were within normal limits.

Laboratory reports revealed hemoglobin 70 g/L, leukocyte count, platelet count $73 \times 10^9/L$, reticulocyte count 1.2% and mean corpuscular volume $69 \times 10^{15}/L$. Peripheral smear showed microcytic hypochromic red blood cells (RBC) with mild anisocytosis without abnormal cells or hemoparasites. Total bilirubin $41 \mu\text{mol}/L$ ($5.1\text{-}17 \mu\text{mol}/L$) with indirect fraction of $25.6 \mu\text{mol}/L$ ($0.2\text{-}0.8 \mu\text{mol}/L$), AST $581 \text{ U}/L$, ALT $229 \text{ U}/L$, ALP $747 \text{ U}/L$, serum albumin $20 \text{ g}/L$, international normalized ratio (INR) was 2.3, activated partial thromboplastin time (aPTT) was 45 seconds and D-dimer was positive ($>5\text{mg}/L$). Workup for her prolonged pyrexia was negative for malaria, enteric fever, tuberculosis, HIV, viral hepatitis, rickettsial illness or systemic lupus erythematosus. Bone marrow examination clinched the diagnosis as amastigote forms of *Leishmania donovani* were seen (Figure 1) along with evidence of hemophagocytosis (Figure 2). rK39 antigen was positive. Diagnosis of HLH was supported by clinical picture, bone marrow findings and the presence of hypertriglyceridemia ($4.7 \text{ mmol}/L$), hypofibrinogenemia ($0.6 \text{ g}/L$) and elevated serum ferritin ($1909 \text{ pmol}/L$). During hospital stay, her hemoglobin and platelet count started falling from $70 \text{ g}/L$ and $73 \times 10^9/L$ at admission to $47 \text{ g}/L$ and $35 \times 10^9/L$ on day 10 of admission, respectively. She was further investigated for the worsening anemia and Direct Coombs' Test (DCT) was strongly positive (4+). Further DCT profile showed presence of Immunoglobulin G. Indirect Coombs' test (ICT) at 37°C was negative. Lactate dehydrogenase (LDH) was elevated ($4199 \text{ U}/L$) and urine was positive for hemoglobin, suggesting intravascular hemolysis. Patient was started on injectable Amphotericin B alternate day therapy with supportive therapy (fluids, nutrition, antipyretics, vitamin K, and blood component support). The patient showed gradual response with improvement in general condition and appetite followed by improvement in hematological parameters (hemoglobin of $84 \text{ g}/L$, TLC of $4.5 \times 10^9/L$, platelet count of $130 \times 10^9/L$), coagulogram (INR of 1.25) and regression of organomegaly (liver 2 cm and spleen 3 cm) by day 10 of therapy. Unfortunately, the patient expired due to a suspected nosocomial intercurrent respiratory infection.

Discussion

Visceral leishmaniasis is a disseminated intracellular protozoal infection caused by the *Leishmania donovani*. It multiplies in the reticuloendothelial system (liver, spleen, lymph node and bone marrow) leading to enlargement of these organs and bone marrow dysfunction. It manifests as fever, hepatosplenomegaly, pancytopenia and hypergammaglobulinemia.⁴ In advanced illness, ascites with pedal edema (due to hypoalbuminemia), bleeding manifestations (due to thrombocytopenia and coagulopathy) and secondary infections (measles, pneumonia, tuberculosis,

dysentery, etc) are common. Anemia in VL occurs due to a combination of factors - hemolysis, hemorrhage, marrow replacement by *Leishmania* infected macrophages, splenic sequestration of red blood cells, hemodilution, shortened RBC lifespan, hemophagocytosis, marrow suppression by cytokines, reversible myelodysplasia and concomitant infections and malnutrition leading to iron, vitamin B12 and folate deficiency.^{5,6} Rarely immune hemolysis is seen which is due to immune complex deposition on the red cell surface, mostly as a result of nonspecific adsorption secondary to polyclonal hypergammaglobulinemia and in rare cases due to cold or warm antibody. In our patient, hemolysis was immune mediated by warm antibody as suggested by positive DCT at 37°C . Contributing to anemia in our patient also were hemophagocytosis and hypersplenism. We started our patient on Amphotericin B therapy which led to decrease in the DCT titres from 4+ to 2+ at the 10th day of therapy. Our patient required only one packed RBC and no platelet transfusion during hospital stay. HLH is a clinico-pathological condition characterized by uncontrolled and non-malignant proliferation of macrophages and T lymphocytes with cytokine overproduction. It is important to differentiate primary and secondary HLH as treatment of the two differs considerably. Primary HLH requires cytotoxic therapy and bone marrow transplant whereas secondary HLH requires specific therapy of the underlying disease.⁷ HLH related VL is very rare in childhood.⁸⁻¹⁰ Our patient had fever, splenomegaly, cytopenia, hypertriglyceridemia, hypofibrinogenemia, increased ferritin and hemophagocytosis on bone marrow, hence meeting the criteria for HLH. Our patient responded to amphotericin B therapy alone with improvement in fever, blood count and splenomegaly. This is the first of its kind case reporting the unique presentation of VL with AIHA and HLH. Although separate associations of AIHA with VL and HLH with VL have been reported, the combination of the three is a novel finding.

Conclusion

The present case demonstrates the unique presentation of visceral leishmaniasis with auto immune hemolytic anaemia and hemophagocytic lymphohistiocytosis. VL should be suspected in cases of febrile illness with hepatosplenomegaly presenting from endemic areas. Bone marrow aspiration is safe but less sensitive in diagnosing VL. rK39 test is a rapid diagnostic test to diagnose VL. Causes of anaemia in VL are diverse and hemolysis should be suspected in case of rapidly falling hemoglobin. HLH should always be suspected in severe infections with disseminated disease. Timely diagnosis is key and prompt institution of anti-leishmanial therapy leads to resolution of the disease in majority of patients.

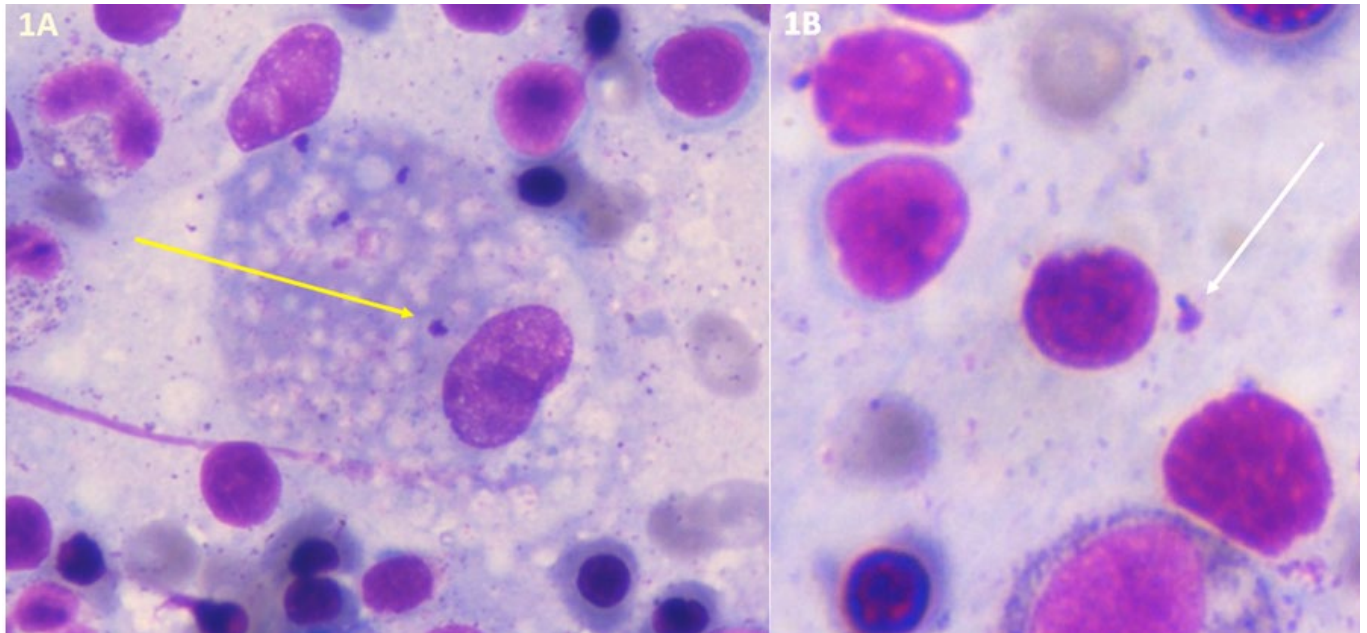


Figure 1A and 1B: Intracellular (yellow arrow) and extracellular (white arrow) amastigote forms of *Leishmania donovani* on bone marrow aspiration smear (Wright stain, 100x)

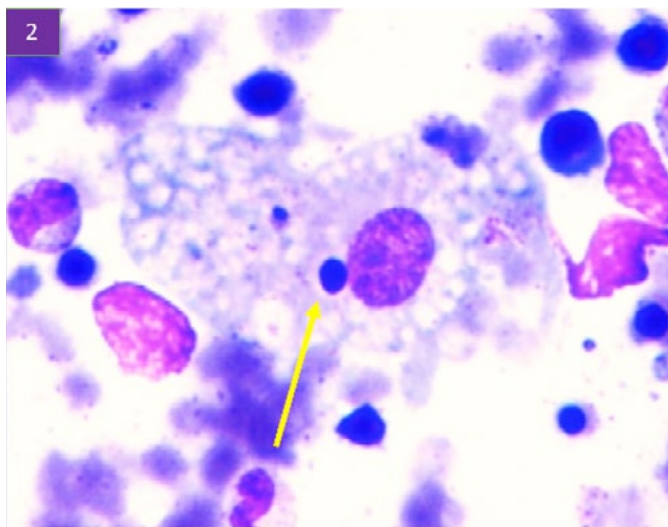


Figure 2: Hemophagocytosis on bone marrow aspirate evidenced by intracellular lymphocyte nucleus in a macrophage (yellow arrow) (Wright stain, 100x)

References

1. Desjeux P. Human leishmaniasis: Epidemiology and public health aspects. *World Health Statist Q* 1992;45:267-75
2. Erduran E, Bahadır A, Gedik Y. Kala-azar associated with Coombs positive autoimmune hemolytic anemia in the patients coming from the endemic area of this disease and successful treatment of these patients with liposomal amphotericin B. *Pediatr Hematol Oncol.* 2005;22:349-55
3. Celik U, Alabaz D, Alhan E, Bayram I, Celik T. Diagnostic dilemma in an adolescent boy: hemophagocytic syndrome in association with kala azar. *Am J Med Sci* 2007;334:139–141
4. Pearson RD, Sausa AQ. Clinical spectrum of Leishmaniasis. *Clin Infect Dis* 1996;22:1-13
5. Miescher PA, Belehu A. Leishmaniasis: hematological aspects. *Semin Hematol* 1982;19:93-99
6. Woodruff AW, Topley E, Knight R, Downie CG. The anaemia of Kala Azar. *British J Haematol* 1972;22:319-329
7. Bouguila J, Chabchoub I, Moncef Y, Mlika A, Saghrouni F, Boughamoura L, et al. Treatment of severe hemophagocytic syndrome associated with visceral leishmaniasis. *Arch Pédiatr* 2010;17:1566–1570
8. Rajagopala S, Dutta U, Chandra KSP, Bhatia P, Varma N, Kochhar R. Visceral leishmaniasis associated hemophagocytic lymphohistiocytosis-case report and systematic review. *J Infect* 2008;56:381–388.
9. TapisizA, BeletN, CiftçiE, InceE, DogruU. Hemophagocytic lymphohistiocytosis associated with visceral leishmaniasis. *J Trop Pediatr.* October 2007;53(5):359–61
10. Gagnaire MH, Galambrun C, Stephen JL. Hemophagocytic syndrome: A Misleading complication of Visceral Leishmaniasis in children-A series of 12 cases. *Pediatrics* 2000;106(4):1-6