

## Standard Article

*J Vet Intern Med* 2017;31:1067–1073

## Whole-Blood Taurine Concentrations in Cats With Intestinal Disease

A. Kathrani , A.J. Fascetti, J.A. Larsen, C. Maunder, and E.J. Hall

**Background:** Increased delivery of taurine-conjugated bile acids to the distal bowel can lead to dysbiosis resulting in colitis in mouse models of inflammatory bowel disease. A similar situation also could occur in cats with intestinal disease and might therefore result in decreased whole-body taurine concentration.

**Hypothesis/Objectives:** To determine whether whole-blood taurine concentrations are decreased at the time of diagnosis in cats with intestinal disease and to correlate concentrations with clinical and laboratory variables.

**Animals:** Twenty-one cats with chronic inflammatory enteropathy and 7 cats with intestinal neoplasia from the University of Bristol.

**Methods:** Cats that had undergone a thorough investigation consisting of a CBC, serum biochemistry, serum cobalamin and folate concentrations, transabdominal ultrasound examination and histopathology of intestinal biopsy specimens, as well as additional testing if indicated, were included. Whole-blood from these cats collected at the time of histologic diagnosis and stored in ethylenediaminetetraacetic acid was retrospectively analyzed for taurine with an automated high-performance liquid chromatography amino acid analyzer.

**Results:** Although whole-blood taurine concentrations remained within the reference range, those cats with predominantly large intestinal clinical signs had significantly lower concentrations than did cats with small intestinal and mixed bowel clinical signs ( $P = 0.033$ ) and this difference also was significant when assessed only in cats with chronic inflammatory enteropathy ( $P = 0.019$ ).

**Conclusions and Clinical Importance:** Additional studies are needed to determine whether large intestinal signs in cats with chronic inflammatory enteropathy are caused by alterations in the microbiota arising as a consequence of increased delivery of taurine-conjugated bile acids.

**Key words:** Amino acid; Enteropathy; Feline.

Taurine is an essential amino acid in cats, because they lack the metabolic pathways to synthesize it from the precursors methionine and cysteine.<sup>1</sup> In addition, cats conjugate bile acids solely with taurine and these conjugated bile acids are absorbed from the terminal ileum.<sup>1</sup> Therefore, clinically relevant ileal disease may impair the absorption of taurine-conjugated bile acids resulting in decreased whole-body taurine concentration. A significantly higher number of taurine-conjugated bile acids has been reported in the feces of mice with ileitis and colitis.<sup>2</sup> Interestingly, a diet high in saturated fat has been shown to increase the production and delivery of taurine-derived sulfur to the large intestine promoting an increase in bile-tolerant microbes such as *Bilophila wadsworthia*, which promote a Th-1-mediated immune response leading to development of colitis in IL-10 knockout mice.<sup>3</sup> Therefore, increased delivery of taurine-derived sulfur to the distal bowel might occur in cats resulting in large intestinal diarrhea

**Abbreviations:**

BCS	body condition score
FCEAI	feline chronic enteropathy activity index
GI	gastrointestinal
WSAVA	world small animal veterinary association

and a subsequent decrease in whole-body taurine concentration. Therefore, cats with intestinal disease may have decreased whole-body taurine from 2 mechanisms: as a result of decreased absorption of taurine-conjugated bile acids due to ileal disease and as a result of increased production of taurine-conjugated bile acids (e.g., due to increased cholecystokinin) which may lead to increased delivery to the colon resulting in inflammation from alterations in the microbiota. These cats might not be able to replenish their whole-body taurine concentrations especially in the presence of inappetence, anorexia, vomiting, malabsorption, or a catabolic state. Taurine deficiency can cause several metabolic abnormalities and clinical signs, which may range from an inadequate immune response to dilated cardiomyopathy.<sup>1</sup>

Determining whether cats with clinically relevant intestinal disease have concurrent low whole-body taurine concentration is important, given the potential role of taurine in nearly every body system.<sup>1,4</sup> Whole-blood taurine is the most reliable measure of whole-body status.<sup>1</sup> Therefore, the aims of our study were to determine, firstly, whether whole-blood taurine concentration at the time of diagnosis in cats with intestinal disease is decreased and, secondly, to correlate taurine status with chronicity of clinical signs; presence of inappetence, weight loss, and diarrhea; localization of gastrointestinal (GI) signs (small bowel, large bowel, or mixed bowel); body condition score (BCS); serum cobalamin

From the School of Veterinary Sciences, University of Bristol, Bristol, UK (Kathrani, Maunder, Hall); and the Department of Molecular Biosciences, School of Veterinary Medicine, University of California-Davis, Davis, CA (Fascetti, Larsen).

Corresponding author: A. Kathrani, School of Veterinary Sciences, University of Bristol, Langford House, Langford, Bristol BS40 5DU, UK; e-mail: ak16730@bristol.ac.uk.

Submitted February 24, 2017; Revised April 18, 2017; Accepted May 6, 2017.

Copyright © 2017 The Authors. *Journal of Veterinary Internal Medicine* published by Wiley Periodicals, Inc. on behalf of the American College of Veterinary Internal Medicine.

This is an open access article under the terms of the Creative Commons Attribution-NonCommercial License, which permits use, distribution and reproduction in any medium, provided the original work is properly cited and is not used for commercial purposes.

DOI: 10.1111/jvim.14773

and folate concentrations; serum albumin concentration; histologic diagnosis; feline chronic enteropathy activity index (FCEAI),<sup>5</sup> and, diet history.

## Materials and Methods

### *Retrospective Study Criteria for Case Selection*

The histopathology archive at the University of Bristol was searched for cats presented between January 2013 and December 2016 with a histologic diagnosis of chronic inflammatory enteropathy or intestinal neoplasia. All medical records then were reviewed by one of the authors (AK). Only cats with a histologic diagnosis of chronic inflammatory enteropathy that had at least a 3-week history of persistent or intermittent GI signs, and adequate and appropriate investigations to exclude other causes of chronic GI signs, and had been appropriately treated for GI parasites before histologic diagnosis were included. Cats with chronic inflammatory enteropathy that had not undergone a strict exclusion diet trial before histologic diagnosis were included. The minimum diagnostic evaluation performed on each cat included a CBC, serum biochemistry, serum cobalamin and folate concentrations, transabdominal ultrasound examination, and collection of intestinal biopsy specimens by endoscopy or exploratory laparotomy. Pancreatic testing (feline pancreatic lipase immunoreactivity and trypsin-like immunoreactivity), serum thyroxine concentrations, basal cortisol concentration, pre- and postprandial bile acid concentrations, fecal parasitology using saturated zinc sulfate flotation, fecal culture (for *Salmonella*, *Campylobacter*, and *Clostridium difficile*), polymerase chain reaction for *Tritrichomonas foetus*, and feline leukemia and feline immunodeficiency virus testing also were performed in some cats, as indicated by the history, physical examination and ultrasound examination findings.

### *Data Collection*

Medical records were reviewed for each cat and the signalment; clinical history including duration, presence of inappetence, lethargy, weight loss, vomiting, and large or small intestinal diarrhea; complete diet history; BCS; and results of diagnostic tests including laboratory, transabdominal ultrasound examination findings, endoscopic findings, and histopathology report were collected. The FCEAI was calculated for cats with chronic inflammatory enteropathy.<sup>5</sup>

Clinical signs were localized to the small bowel if weight loss, borborygmi, vomiting, large volume diarrhea, normal frequency of defecation, melena, and lack of urgency were identified. Large bowel was defined as diarrhea that was smaller in volume and characterized by increased frequency of defecation, mucus or fresh blood, straining, and increased urgency.

To determine whether the diet each cat was consuming complied with the recommendations of the World Small Animal Veterinary Association (WSAVA) Global Nutrition Committee, each manufacturer was contacted and asked to reply to the 8 questions outlined in section A of the web link.<sup>a</sup> Diets were considered to meet the recommendations outlined by the WSAVA Global Nutrition Committee if the manufacturer could satisfactorily address all of the questions.

### *Whole-Blood Taurine Analysis*

For each cat, whole-blood stored in ethylenediaminetetraacetic acid (EDTA) at  $-20^{\circ}\text{C}$  from the time of histologic diagnosis was retrieved from the DNA archive at the University of Bristol and sent to the Amino Acid Laboratory at the University of California, Davis, for taurine analysis. Whole-blood taurine

concentrations were analyzed with an automated high-performance liquid chromatography amino acid analyzer,<sup>b</sup> by a method described elsewhere.<sup>6</sup>

Although studies in humans have confirmed the stability of taurine when frozen for at least 14 months,<sup>7</sup> whole-blood from 4 blood donor cats that was stored in EDTA at  $-20^{\circ}\text{C}$  for 2 years also was retrieved from the DNA archive at the University of Bristol and sent to the Amino Acid Laboratory at the University of California, Davis, for taurine analysis to ensure that prolonged freezing did not falsely decrease concentrations below the reference range.

### *Ethical Considerations*

Stored residual blood was used in this study and the University of Bristol granted ethical approval for the study (VIN/14/017).

### *Data Analysis and Statistics*

Analyses were performed by a computer software package.<sup>c</sup> A Mann-Whitney *U*-test was used to assess for significant differences in whole-blood taurine concentration in cats with chronic inflammatory enteropathy versus those with intestinal neoplasia, cats with inappetence versus normal appetite, cats with weight stability versus those with weight loss, cats with diarrhea versus those with normal feces, cats with predominantly large intestinal clinical signs versus cats with predominantly small intestinal clinical signs, cats with clinical signs for  $>12$  months versus those with signs for  $\leq 12$  months, cats with normocobalaminemia versus those with hypocobalaminemia, cats with increased serum folate concentrations versus those with normal serum folate concentrations, cats with hypocobalaminemia and concurrent increased serum folate concentrations versus those without these biochemical findings, and cats consuming diets that met the recommendations outlined by the WSAVA Global Nutrition Committee versus diets that did not meet these recommendations.

A Spearman's rank correlation coefficient was used to assess whether there were significant correlations between whole-blood taurine and serum cobalamin, folate, or albumin concentrations, duration of clinical signs, FCEAI, BCS, and age at diagnosis. Results are reported as median and range. Significance was defined as  $P < 0.05$ .

## Results

### *Cats*

Twenty-eight cats were included in the study: 1 intact male, 15 neutered male, 1 intact female, and 11 neutered female. The age of the cats ranged from 6 months to 13 years, with a median age of 6 years. Fourteen cats were Domestic Shorthair, 3 Maine Coon, 2 Siamese, 2 Birman, 2 Domestic Longhair, and 1 each of the following breeds: Bengal, Bengal cross, Tonkinese, British Blue, and British Shorthair. Body condition score ranged from 1/9 to 6/9, with a median of 4/9.

All 4 blood donor cats were neutered males, domestic shorthaired, and 10 months of age.

### *History*

Nine cats had GI signs for  $>12$  months, whereas 19 cats had signs for  $\leq 12$  months. Duration of signs for all cats ranged between 3 weeks and 84 months (median, 8.5 months). Eighteen cats had weight loss and 10 cats

had stable body weight before diagnosis. Twelve cats were inappetent and 16 cats had normal appetite at the time of diagnosis. Sixteen cats had diarrhea and 12 cats had no history of diarrhea. The pattern of diarrhea was exclusively small intestinal ( $n = 3$ ), predominantly small intestinal ( $n = 4$ ), exclusively large intestinal ( $n = 4$ ), predominantly large intestinal ( $n = 1$ ), or mixed bowel ( $n = 4$ ). Twenty-one cats were eating a diet that met the recommendations outlined by the WSAVA Global Nutrition Committee at the time of diagnosis, whereas 7 cats were not. The reason the diets these 7 cats were eating did not meet the recommendations outlined by the WSAVA Global Nutrition Committee was because the manufacturers of these diets did not employ full-time qualified nutritionists and could not provide a complete nutrient analysis for the cat foods in question. Twenty-three cats were receiving no treatment for their intestinal disease at the time of retrospective whole-blood taurine analysis. Of the 5 cats receiving treatment, 1 was treated with metronidazole, 1 with metronidazole and omeprazole, 1 with amoxicillin-clavulanate, 1 with famotidine, and 1 with ondansetron, ranitidine, and maropitant.

### *Histologic Diagnosis*

Seven of the 28 cats were diagnosed with intestinal neoplasia: small cell intestinal lymphoma ( $n = 5$ ), large cell intestinal lymphoma ( $n = 1$ ), and adenocarcinoma of the proximal ileum ( $n = 1$ ). All biopsy specimens were collected by endoscopy, except for the cat with an adenocarcinoma, in which diagnosis was made by exploratory laparotomy. Twenty-one cats were diagnosed with chronic inflammatory enteropathy. Six had diffuse mixed bowel inflammation, with 1 each of the following: lymphoplasmacytic enteritis and colitis; mixed cell enteritis and colitis; eosinophilic enteritis and colitis; eosinophilic and neutrophilic enteritis and colitis; lymphoplasmacytic, neutrophilic, and eosinophilic enteritis; and colitis, lymphoplasmacytic enteritis, and mixed cell colitis. Twelve of the 21 cats were diagnosed with small intestinal inflammation alone: mixed cell enteritis ( $n = 4$ ), lymphoplasmacytic enteritis ( $n = 2$ ), eosinophilic enteritis ( $n = 2$ ), and 1 each of the following: lymphocytic enteritis, lymphoplasmacytic and eosinophilic enteritis, lymphoplasmacytic and neutrophilic enteritis, and eosinophilic and neutrophilic enteritis. Large intestinal inflammation alone was diagnosed in 3 of the 21 cats: 1 each of lymphoplasmacytic colitis, mixed cell colitis, and lymphoplasmacytic and neutrophilic colitis. For the cats diagnosed with chronic inflammatory enteropathy, biopsy specimens were collected by endoscopy in 18 cats and by exploratory laparotomy in 3. For these cats, the FCEAI ranged from 4 to 8, with a median of 5.

### *Serum Cobalamin, Folate, and Albumin Concentrations*

Twenty-one cats were normocobalaminemic (median, 635 ng/L; range, 259 to >1,000 ng/L; reference range,

220–500 ng/L), but 3 of the cats had received cyanocobalamin supplementation SC before analysis, and 7 cats were hypocobalaminemic (median, 111 ng/L; range, <111–207 ng/L) at the time of diagnosis. Fourteen cats had serum folate concentrations within the reference range (median, 29.4 nmol/L; range, 21.1–36.5 nmol/L; reference range 19–37 nmol/L) and 14 cats had concentrations above the reference range (median, 46.1; range, 38.1–54.4 nmol/L). Of the 14 cats with serum folate concentrations above the reference range, 4 had concurrent hypocobalaminemia, suggestive of possible dysbiosis. Twenty-four cats were normoalbuminemic (median, 2.85 g/dL; range, 2.42–3.24 g/dL; reference range, 2.4–3.5 g/dL) and 4 cats were hypoalbuminemic (median, 2.34 g/dL; range, 2.20–2.37 g/dL) at the time of diagnosis.

### *Whole-Blood Taurine Concentration*

Twenty-seven of the 28 cats had whole-blood taurine concentrations higher than the lower end of the reported reference range of 275–701 nmol/mL.<sup>8</sup> The only cat that had whole-blood taurine concentration below the reported reference range, at 267 nmol/mL, had a proximal ileal adenocarcinoma. Additional areas of intestine were not biopsied in this cat, but histologic examination of an intestinal segment proximal to the ileal mass showed clear margins with no evidence of neoplasia, but multifocal fibrosis and a focal marked increase in eosinophils within the lamina propria were observed. This cat had a 3-month history of intermittent vomiting and weight loss with good appetite and the cat was eating a diet that met the recommendations outlined by the WSAVA Global Nutrition Committee. The cat was reported to have normal feces and a BCS of 6/9. The cat had normal serum cobalamin, folate, and albumin concentrations without supplementation at the time of diagnosis (620 ng/L, 33.8 nmol/L, and 2.85 g/dL, respectively). All 4 blood donor cats had whole-blood taurine concentrations within the reference range (median, 407 nmol/mL; range, 328–490 nmol/mL).

### *Differences in Whole-Blood Taurine Concentration for Various Variables*

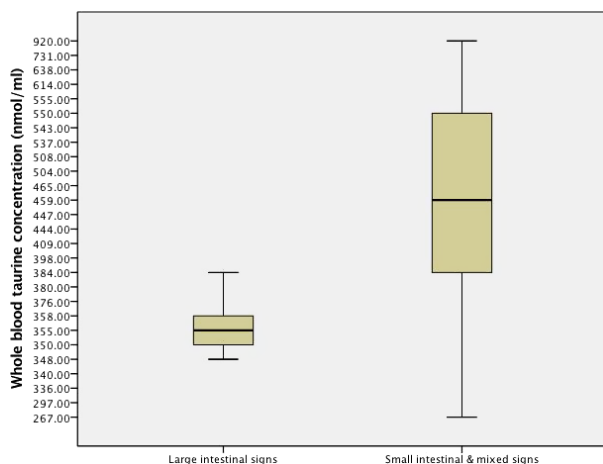
There were no significant differences ( $P > 0.3$ ) between whole-blood taurine concentrations ( $n$ , median [nmol/mL], range [nmol/mL]) in cats with chronic inflammatory enteropathy ( $n = 21$ , 398, 297–731) versus intestinal neoplasia ( $n = 7$ , 537, 267–920); with inappetence ( $n = 12$ , 429, 297–614) versus normal appetite ( $n = 16$ , 427, 267–920); with stable body weight ( $n = 10$ , 421, 297–731) versus weight loss ( $n = 18$ , 427, 267–920); with diarrhea ( $n = 16$ , 391, 297–920) versus normal feces ( $n = 12$ , 446, 267–638); with clinical signs for >12 months ( $n = 9$ , 398, 336–614) versus those with signs for ≤12 months ( $n = 19$ , 444, 267–920); cats with normocobalaminemia ( $n = 21$ , 447, 267–920) versus hypocobalaminemia ( $n = 7$ , 384, 340–550); cats with normal serum folate concentration ( $n = 14$ , 428, 267–920)

versus increased serum folate concentration ( $n = 14$ , 421, 340–614); cats with hypcobalaminemia and concurrent increased serum folate concentration ( $n = 4$ , 446, 340–550) versus those without these findings ( $n = 24$ , 427, 267–920); and cats consuming a diet that met the recommendations outlined by the WSAVA Global Nutrition Committee ( $n = 21$ , 444, 267–920) versus those that did not meet the guidelines ( $n = 7$  cats, 380, 336–638).

All cats with predominantly or exclusively large intestinal clinical signs ( $n = 5$ , 355, 348–384) had a significantly lower whole-blood taurine concentration ( $P = 0.033$ ) than cats with small intestinal and mixed bowel clinical signs ( $n = 23$ , 459, 267–920; Fig 1). Statistical significance ( $P = 0.019$ ) also was found when only cats with a diagnosis of chronic inflammatory enteropathy were evaluated, comparing those with large intestinal clinical signs ( $n = 5$ , 355, 348–384) versus those with small intestinal and mixed bowel clinical signs ( $n = 16$ , 452, 297–731). Four of the 5 cats with large intestinal signs had histologic evidence of colitis, the remaining 1 cat had biopsy samples collected by exploratory laparotomy, and therefore, biopsy of the colon was not performed to document the presence of inflammation.

### Correlation Between Whole-Blood Taurine Concentration and Various Variables

No significant correlations ( $P > 0.5$ ) were found between whole-blood taurine and serum cobalamin,



**Fig 1.** Box and whisker plot of whole-blood taurine concentration at the time of diagnosis in cats with exclusively or predominantly large intestinal clinical signs and cats with small intestinal and mixed clinical signs. Box and whisker plot of whole-blood taurine concentration at the time of diagnosis in cats with intestinal disease. Large intestinal signs—5 cats, minimum—348 nmol/mL, maximum—384 nmol/mL, median—355 nmol/mL, range—36 nmol/mL, interquartile range—22 nmol/mL. Small intestinal and mixed bowel signs—23 cats (19 small intestinal and 4 mixed bowel), minimum—267 nmol/mL, maximum—920 nmol/mL, median—459 nmol/mL, range—653 nmol/mL, interquartile range—170 nmol/mL.

serum folate, or serum albumin concentrations; duration of clinical signs; FCEAI; BCS; and age at diagnosis.

## Discussion

In our study, whole-blood taurine concentrations were measured at the time of diagnosis in 28 cats with intestinal disease. Taurine is an essential nutrient in cats, because they lack the metabolic pathways to synthesize sufficient amounts from the amino acid precursors methionine and cysteine to meet obligatory losses.<sup>1</sup> Clinically relevant ileal disease might impair the absorption and recycling of taurine-conjugated bile acids. In addition, increased production of taurine-conjugated bile acids from increased cholecystokinin release<sup>9</sup> might result in increased delivery to the colon resulting in inflammation, either from direct irritation of the mucosal lining or as a result of alterations in the microbiota. Therefore, cats with intestinal disease might be at risk for developing decreased whole-body taurine concentrations, especially if they are not able to replenish their stores by increased PO intake of a complete and balanced diet.

Taurine plays a crucial role in the immune system,<sup>10,11</sup> and therefore, a deficiency might impair the ability of the GI tract to recognize and mount an appropriate immune response. This effect may be particularly concerning in cats with chronic inflammatory enteropathy in which it is suspected that an aberrant immune system might already play a role in the pathogenesis of the disease. Therefore, documenting whether cats with intestinal disease have taurine deficiency is warranted because a deficiency might further affect the pathogenesis and treatment of the disease. To our knowledge, our study is the first to document whole-blood taurine concentrations at the time of diagnosis in cats with intestinal disease.

We found that at the time of diagnosis, all but 1 cat with intestinal disease had whole-blood taurine concentrations within the reported reference range. Therefore, whole-blood taurine was not substantially depleted in this population of cats with intestinal disease. Although 1 cat had whole-blood taurine concentration below the reference range, it was still  $>200$  nmol/mL, and therefore, clinical signs of deficiency would not be expected.<sup>1</sup> This cat had a 3-month history of intermittent vomiting and weight loss, but a normal appetite and was consuming a diet that met the recommendations outlined by the WSAVA Global Nutrition Committee. In addition, this cat had normal fecal quality, BCS of 6/9, and had serum cobalamin, folate, and albumin concentrations within reference ranges. Although the pathomechanism of decreased whole-blood taurine concentration was unknown for this cat, it was unlikely to have been caused by the type of diet nor decreased absorption and recycling as a consequence of ileal disease because the serum cobalamin concentration was within the reference range. However, although sections proximal to the mass documented fibrosis and eosinophilic infiltration, additional biopsy specimens were not taken from the

intestinal tract to determine the extent of any concurrent disease. Although the 3-month history of weight loss and intermittent vomiting might have contributed to the decreased whole-blood taurine concentration in this cat, it is likely that a second factor also was present. Bacterial overgrowth or dysbiosis in the ileum associated with changes in the local environment from the adenocarcinoma or concurrent disease might have resulted in increased cleavage of taurine-conjugated bile acids with subsequent oxidation of taurine by microbes. This would have prevented reutilization<sup>12-14</sup> and therefore could also account for the decreased taurine in this cat. However, in our study, cats with suspected dysbiosis based on low serum cobalamin and increased serum folate concentrations did not have significantly decreased whole-blood taurine concentrations. This finding may have been a result of decreased power of the study based on the small number of cats with these biochemical findings. In addition, the relative insensitivity of low serum cobalamin and increased serum folate concentrations at determining the presence of dysbiosis also may have resulted in nonsignificance. Therefore, future studies should focus on analysis of the fecal microbiota to definitively determine whether the presence of dysbiosis alters the metabolomics in such cats.

Interestingly, our study documented that cats with exclusively or predominantly large intestinal signs had significantly lower whole-blood taurine concentrations than did cats with small intestinal or mixed bowel signs, and this finding also was statistically significant when only cats with chronic inflammatory enteropathy were analyzed. However, this finding was based on a small number of cats in the large intestinal group, and whole-blood taurine concentration still overlapped between the 2 groups (Fig 1). Therefore, a larger number of cats would be needed to corroborate the preliminary findings of our study. A sample size calculation based on the results of our study indicated that 23 cats with large intestinal signs and 23 cats with small intestinal signs would be needed to detect a statistically significant difference after adjusting for multiple comparisons. Because of the pilot design of our study and suspected decreased power from the limited number of cases in the large intestinal group, the results were not corrected for multiple comparisons because of concern for type II error. Therefore, the results from our study justify completion of a larger study to corroborate these findings and warrant the performance of metabolomic studies in cats with intestinal disease.

When comparing the effects of disease location on whole-blood taurine concentration, clinical signs rather than histologic findings were used because not all cats had colonic biopsies performed. In addition, some cats were diagnosed with colitis based on histopathology, but either did not have consistent large intestinal signs or such signs represented a less relevant component of their clinical presentation.

One study documented that a diet high in saturated fat increases the production and delivery of taurine-derived sulfur to the distal bowel, promoting an increase in bile-tolerant microbes (eg *B. wadsworthia*)

that promote a Th-1-mediated immune response leading to development of colitis in IL-10 knockout mice.<sup>3</sup> Similarly, increased delivery of taurine-derived sulfur to the distal bowel might occur in cats and result in large intestinal diarrhea as a result of an alteration in the microbiota, with a subsequent decrease in whole-blood taurine concentration compared to cats with small intestinal or mixed bowel clinical signs. However, additional studies documenting a significant difference in fecal taurine concentration in cats with large and small intestinal disease would be needed to confirm this possibility. A distinct fecal bile acid profile has been observed with significantly higher concentrations of taurine-conjugated bile acids in IL-10 knockout mice with ileitis and colitis.<sup>2</sup> Similarly, feces from humans with inflammatory bowel disease contained more bile acids and taurine, and this metabolite pattern was highly correlated with a characteristic shift in the microbiota.<sup>15</sup> One study documented that the increased conjugated and sulfated bile acids in the feces of humans with Crohn's disease was attributed to the decreased capacity of the microbiome in these patients to deconjugate and desulfate bile acids, resulting in decreased production in the colon of secondary bile acids, which are normally anti-inflammatory.<sup>16</sup> Therefore, the increase in fecal taurine seen in human and animal models of inflammatory bowel disease likely results from a perturbation in microbiota, and consequently, bile acids may form the link between the dysbiosis and inflammation seen in these diseases. Similarly, taurine-conjugated bile acids might cause or exacerbate large intestinal inflammation in cats by altering the microbiota. However, additional studies (especially fecal metabolomics) as well as analysis of the microbiota are needed to determine whether cats with large intestinal disease have increased fecal taurine and whether the microbiota in these cats differs from those in cats that do not have increased fecal taurine. If taurine-conjugated bile acids play a role in large intestinal inflammation in cats, then additional studies may focus on the role of dietary fat in minimizing the production and secretion of these bile acids, because increased cholecystokinin, which may be stimulated by dietary fat, increases bile secretion in cats resulting in more luminal taurocholic acid.<sup>9</sup> Although, 1 study reported no effect of different amounts of dietary fat on fecal consistency in cats with diarrhea, this study did not specifically document the effect of different amounts of fat in those cats with predominantly or exclusively large intestinal disease.<sup>17</sup> In addition, certain fibers and peptides are able to bind to taurine-conjugated bile acids, resulting in excess loss of taurine in the feces.<sup>18,19</sup> These fibers and indigestible protein also may support the microbiota, which can cleave these bile acids resulting in increased loss of free taurine.<sup>1</sup> In cats, indigestible peptides also can increase cholecystokinin production,<sup>9</sup> which increases luminal taurocholic acid. Therefore, if further investigation confirms the role of taurine in intestinal disease in cats, additional studies to assess the impact of certain fibers and peptides on luminal taurine in cats with intestinal disease may be needed.

Surprisingly, we did not identify any significant differences in whole-blood taurine concentrations between cats with normal appetite versus those with inappetence, between those with stable body weight versus those with weight loss, or between cats consuming a diet that met the recommendations outlined by the WSAVA Global Nutrition Committee versus those consuming diets that did not meet the recommendations. Also, no correlation was found between whole-blood taurine concentrations and duration of clinical signs, and none was found with serum cobalamin, folate, or serum albumin concentrations. These findings might be because taurine depletion must occur over months to years, depending on the extent of the deficiency,<sup>1</sup> and therefore, correlating concentrations to specific clinical signs or laboratory findings might be difficult over a shorter time frame. Although the median duration of clinical signs for cats in our study was 8.5 months, this time frame might not have been long enough to cause significant changes or correlations. In addition, individual need for taurine depends on diet composition, especially the type, quantity, and digestibility of protein and fiber.<sup>1</sup> Unfortunately, because of the retrospective nature of our study, it was not possible to obtain detailed information about the diets, apart from the name and type of food being fed at the time of diagnosis when the cats were presented to the University of Bristol. However, for the majority of the cats, previous diets from at least the last few years were available from the referring veterinarians' records. However, given that the time span for inclusion into the study covered 4 years, it was not possible to accurately correlate the different macronutrient profiles with whole-blood taurine concentration.

Given studies on the effect of dietary fat on taurocholic acid production in mice and cats,<sup>3,9</sup> correlating this effect to whole-blood taurine concentrations might have been informative. Another limitation of our study involved its retrospective design, which could have made the interpretation of the clinical history and assignment of the FCEAI scores inconsistent because of the involvement of several clinicians in the cases and the fact that 2 of the variables used for assessment of the activity index (lethargy and appetite) involved a subjective scale.<sup>5</sup> In addition, although all cats with chronic inflammatory enteropathy were normobilirubinemic, did not have evidence of hepatic damage on serum biochemistry results, and had normal liver and biliary tree on abdominal imaging, pre- and postprandial bile acid concentrations to eliminate hepatic dysfunction definitively were not measured for all cats. Therefore, the presence of possible concurrent hepatic dysfunction, although considered unlikely, could not be definitively eliminated in all cats. Therefore, a prospective study to evaluate whole-blood taurine concentrations in cats with intestinal disease would allow for consistent assessment of the clinical history in all cases as well as collection of a detailed diet history for macronutrient profiling as well as pre- and postprandial bile acid concentrations to definitively eliminate hepatic dysfunction.

Five cats in our study were receiving medications at the time of retrospective taurine analysis. Three of

these cats were receiving either metronidazole or amoxicillin-clavulanate. Metronidazole use alone has less effect than do antibiotic combinations on bile acid profiles in mice,<sup>20</sup> and amoxicillin was shown not to affect fecal and plasma bile acid concentrations in humans.<sup>21</sup> However, additional studies are needed to determine whether these antibiotics have the same limited effect on blood bile acid profiles in cats with intestinal disease. Three of the cats in our study also were receiving antacid treatment (omeprazole, famotidine, and ranitidine) and 2 of the 5 cats were receiving antiemetic medications (ondansetron and maropitant). Famotidine was shown not to affect serum bile acid concentrations in healthy humans.<sup>22</sup> Although 1 study in humans showed that omeprazole significantly lowered the concentration of taurine-conjugated bile acids as a result of bacterial overgrowth,<sup>23</sup> only 1 cat in our study was receiving this medication. The results of our study still were significant when this 1 cat was removed from statistical analysis, with cats that had predominantly large intestinal clinical signs having significantly lower whole-blood taurine concentrations than cats with small intestinal and mixed bowel clinical signs ( $P = 0.040$ ), and this finding also was significant when assessed only in cats with chronic inflammatory enteropathy ( $P = 0.025$ ). However, future studies should consider the medications that the cats are receiving at the time of taurine analysis to eliminate any confounding effects from the use of these medications.

In conclusion, we documented whole-blood taurine concentrations at the time of diagnosis in cats with intestinal disease. Although our study indicated that cats with predominantly or exclusively large intestinal signs had significantly lower whole-blood taurine concentrations compared to cats with small intestinal or mixed bowel signs, the concentrations remained within the reference range. Thus, additional studies, particularly those assessing fecal taurine concentration and analysis of the microbiota, are needed in cats with large intestinal and small intestinal disease to determine the role of bile acids and taurine in the pathogenesis of chronic inflammatory enteropathy.

---

## Footnotes

<sup>a</sup> World Small Animal Veterinary Association (WSAVA) Global Nutrition Committee Guidelines: <http://www.wsava.org/sites/default/files/Recommendations%20on%20Selecting%20Pet%20Food%20s.pdf>.

<sup>b</sup> Biochrom 30, Biochrom Ltd, Holliston, MA

<sup>c</sup> IBM SPSS Statistics version 23, Armonk, NY, USA

---

## Acknowledgments

The authors thank Zengshou Yu, Michael Day, Fran Whittington, Louisa Mitchard, and Chris Whiting for technical assistance.

*Grant support:* This work was supported by the Langford Veterinary Services Clinical Research Fund, School of Veterinary Sciences, University of Bristol, UK.

*Conflict of Interest Declaration:* A. J. Fascetti is the Scientific Director of the Amino Acid Laboratory at the University of California, Davis, that provides amino acid analysis on a fee for service basis. This did not lead to any conflict of interest or influence the collection or interpretation of the results.

*Off-label Antimicrobial Declaration:* Authors declare no off-label use of antimicrobials.

## References

1. NRC. Nutrient Requirements of Dogs and Cats. Washington, DC: The National Academy Press. 2006.
2. Rau M, Stieger B, Monte MJ, et al. Alterations in enterohepatic Fgf15 signaling and changes in bile acid composition depend on localization of murine intestinal inflammation. *Inflamm Bowel Dis* 2016;22:2382–2389.
3. Devkota S, Wang Y, Musch MW, et al. Dietary-fat-induced taurocholic acid promotes pathobiont expansion and colitis in IL10<sup>-/-</sup> mice. *Nature* 2012;487:104–108.
4. Huxtable RJ. Physiological actions of taurine. *Physiol Rev* 1992;72:101–163.
5. Jergens AE, Crandell JM, Evans R, et al. A clinical index for disease activity in cats with chronic enteropathy. *J Vet Intern Med* 2010;24:1027–1033.
6. Kim SW, Morris JG, Rogers QR. Dietary soybean protein decreases plasma taurine in cats. *J Nutr* 1995;125:2831–2837.
7. Awwad HM, Geisel J, Obeid R. Determination of trimethylamine, trimethylamine *N*-oxide, and taurine in human plasma and urine by UHPLC-MS/MS technique. *J Chromatogr B Analyt Technol Biomed Life Sci* 2016;1038:12–18.
8. Heinze CR, Larsen JA, Kass PH, et al. Plasma amino acid and whole-blood taurine concentrations in cats eating commercially prepared diets. *Am J Vet Res* 2009;70:1374–1382.
9. Backus RC, Rogers QR, Rosenquist GL, et al. Diets causing taurine depletion in cats substantially elevate postprandial plasma cholecystokinin concentration. *J Nutr* 1995;125:2650–2657.
10. Schuller-Levis G, Mehta PD, Rudelli R, et al. Immunologic consequences of taurine deficiency in cats. *J Leukoc Biol* 1990;47:321–331.
11. Schuller-Levis GB, Sturman JA. Evaluation of immunity in taurine-deficient cats. *Prog Clin Biol Res* 1990;351:431–438.
12. Hickman MA, Rogers QR, Morris JG. Effect of processing on fate of dietary [<sup>14</sup>C]taurine in cats. *J Nutr* 1990;120:995–1000.
13. Hickman MA, Morris JG, Rogers QR. Intestinal taurine and the enterohepatic circulation of taurocholic acid in the cat. *Adv Exp Med Biol* 1992;315:45–54.
14. Backus RC, Rogers QR, Morris JG. Microbial degradation of taurine in fecal cultures from cats given commercial and purified diets. *J Nutr* 1994;124:2540S–2545S.
15. Jacobs JP, Goudarzi M, Singh N, et al. A disease-associated microbial and metabolomics state in relatives of pediatric inflammatory bowel disease patients. *Cell Mol Gastroenterol Hepatol* 2016;2:750–766.
16. Duboc H, Rajca S, Rainteau D, et al. Connecting dysbiosis, bile-acid dysmetabolism and gut inflammation in inflammatory bowel diseases. *Gut* 2013;62:531–539.
17. Laflamme DP, Xu H, Long GM. Effect of diets differing in fat content on chronic diarrhea in cats. *J Vet Intern Med* 2011;25:230–235.
18. Stratton-Phelps M, Backus RC, Rogers QR, et al. Dietary rice bran decreases plasma and whole-blood taurine in cats. *J Nutr* 2002;132:1745S–1747S.
19. Sugano M, Goto S, Yamada Y, et al. Cholesterol-lowering activity of various undigested fractions of soybean protein in rats. *J Nutr* 1990;120:977–985.
20. Zhang Y, Limaye PB, Renaud HJ, et al. Effect of various antibiotics on modulation of intestinal microbiota and bile acid profile in mice. *Toxicol Appl Pharmacol* 2014;277:138–145.
21. Vrieze A, Out C, Fuentes S, et al. Impact of oral vancomycin on gut microbiota, bile acid metabolism, and insulin sensitivity. *J Hepatol* 2014;60:824–831.
22. Testa R, Grasso A, Dagnino F, et al. Famotidine does not affect indocyanine green disposition and serum bile acid levels in healthy subjects. *Br J Clin Pharmacol* 1987;23:779–780.
23. Theisen J, Nehra D, Citron D, et al. Suppression of gastric acid secretion in patients with gastroesophageal reflux disease results in gastric bacterial overgrowth and deconjugation of bile acids. *J Gastrointest Surg* 2000;4:50–54.