

## Case Series

# Complications after Dynamic Hip Screw Osteosynthesis of Proximal Femoral Fractures at Army Instructional Hospital-Libreville

F. M. Bombah <sup>1</sup>, M. Diawara,<sup>2</sup> B. Y. Ekani,<sup>3</sup> T. Nana,<sup>3</sup> and A. Mikiela<sup>2</sup>

<sup>1</sup>Department of Surgery, Faculty of Medicine and Pharmaceutical Sciences, University of Douala, Cameroon

<sup>2</sup>Orthopedic and Traumatologic Surgery Department, Army Instructional Hospital, Libreville, Gabon

<sup>3</sup>Department of Surgery, Faculty of Medicine and Pharmaceutical Sciences, University of Buea, Cameroon

Correspondence should be addressed to F. M. Bombah; bombahstick@hotmail.fr

Received 25 April 2021; Accepted 25 September 2021; Published 4 October 2021

Academic Editor: George Mouzopoulos

Copyright © 2021 F. M. Bombah et al. This is an open access article distributed under the Creative Commons Attribution License, which permits unrestricted use, distribution, and reproduction in any medium, provided the original work is properly cited.

The DHS system is an effective means of open reduction and internal fixation of proximal femur fractures. Postoperative complications are little described and deserve to be studied for better preventive and curative treatment. We report the observations of five (5) patients who presented postoperative complications specific to the DHS system at army instructional Hospital-Libreville. These described complications are related to deterioration of internal fixation leading to callus, nonunion, or infection. Those found are the cut out phenomenon, avascular necrosis of the femoral head, and the fracture of the DHS system. All these complications required surgical revision without functional repercussions at the last follow-up. Complications of internal fixation by the DHS system can be avoided by rigorous asepsis, adequate indications for surgery, and rigorous surgical techniques. Good management can restore hip function.

## 1. Introduction

The DHS system is an effective means of open reduction and internal fixation of proximal femur fractures [1]. It was developed from 1980 by Richards Manufacturing and has been the subject of numerous studies [2, 3]. It has very precise indications and requires practical experience. Postoperative complications are poorly described [4] and deserve to be studied for better preventive and curative treatment. We report the observations of five (5) patients who presented postoperative complications specific to the DHS system.

## 2. Observations: (Table 1)

**2.1. Case 1.** 42-year-old patient, motorcycle driver, was a victim of a blunt trauma to the right thigh after a road traffic accident on his motorcycle. The diagnosis of subtrochanteric fracture classified 32C3 according to AO/OTA (Figure 1(a)) is made and a dynamic compressive plate osteosynthesis

performed in a clinic. The patient is referred to us 2 weeks postoperatively for posttraumatic plate removal (Figure 1(b)). The plate was deposited, and an osteosynthesis by the DHS system was performed. The evolution after six (6) postoperative months is marked by atrophic pseudarthrosis and a rupture of the plate in the 8th month (Figure 1(c)). The management consisted of a cure of nonunion, a spongy graft, and the internal fixation by a locking plate for proximal femur (Figure 1(d)). At the last follow-up (9 months), the functional [5] and radiological results (presence of callus) were very good.

**2.2. Case 2.** A 64-year-old trader was brought in an hour after trauma to the right hip in a car accident. The clinical and paraclinical examination made it possible to make the diagnosis of transcervical fracture of the femoral neck classified 31B2.3 according to AO/OTA (Figure 2(a)). The DHS was applied 5 days after the trauma under image intensifier. The course is marked by pain in the hip, pseudarthrosis of

TABLE 1: Case series.

Cases	Age	Sex	Diagnostic	AO/OTA	Disturbed healing	Complication Mechanical	Vascular	Treatment
1	42	M	Subtroch	32B2a	Subtrochanteric pseudarthrosis	DHS plate fracture	/	Plate
2	64	M	Transcervical	31B2.3	Neck pseudarthrosis	Cut out phenomenon	Cephalic avascular necrosis	PHRA
3	56	F	Pertroch.	32A2	Neck pseudarthrosis	Cut out phenomenon	Cephalic avascular necrosis	THRA
4	65	M	Pertroch.	31A1.3	Malunion	Cut out phenomenon, DHS sliding screw fracture	/	Remove of DHS system
5	46	M	Pertroch.	31A1.2	Infection	/	/	Necrosectomy, washing drainage

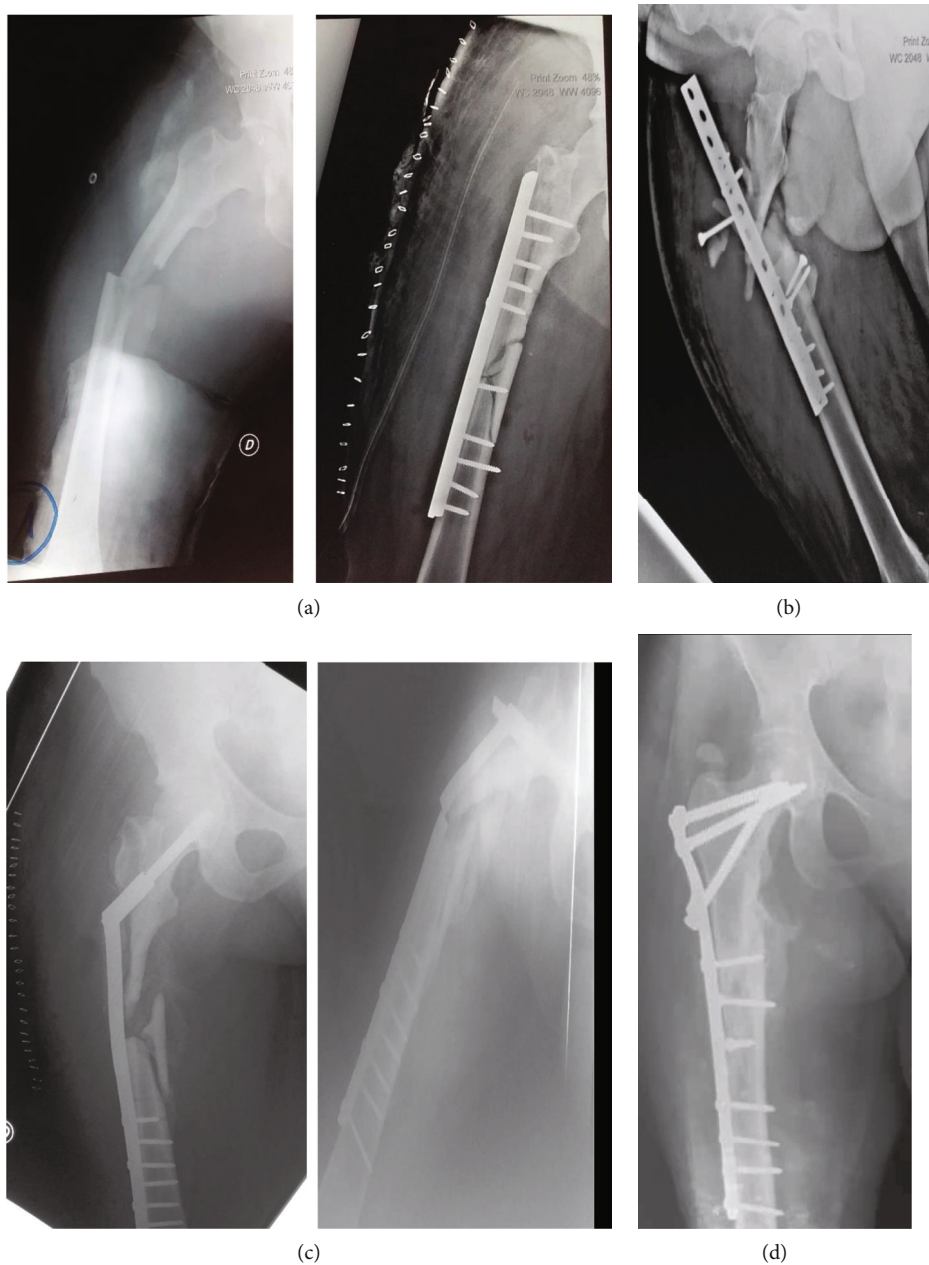

FIGURE 1: X-ray of case 1: ((a) subtrochanteric fracture; (b) missed fixation of DCP; (c) atrophic nonunion with fracture of the DHS system; (d) locked plate osteosynthesis).

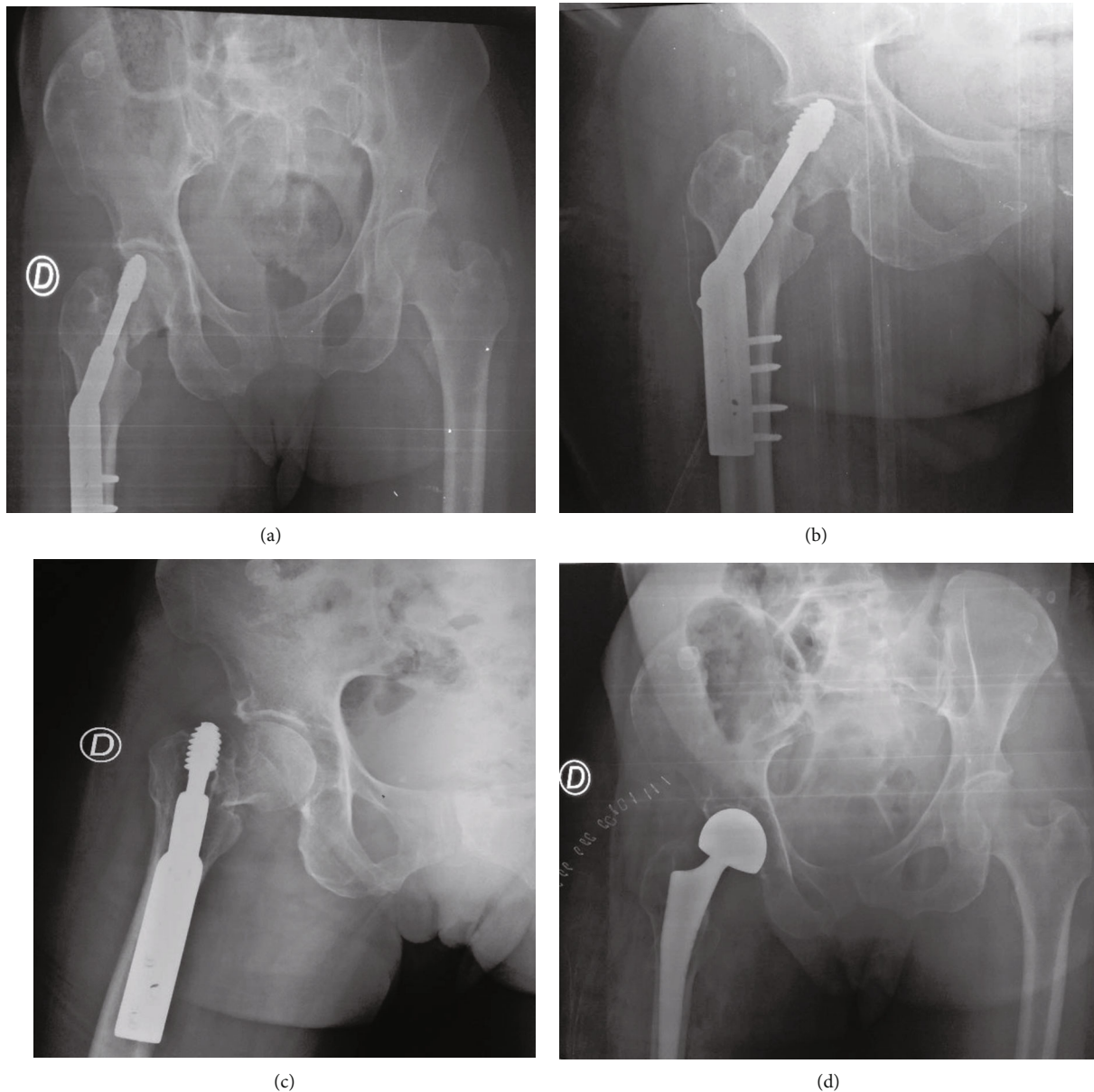


FIGURE 2: X-rays of patient 2. (a) DHS osteosynthesis of neck fracture. (b) Neck pseudarthrosis with phenomenon. (c) Cut out phenomenon with cephalic osteonecrosis. (d) Right hemiarthroplasty.

the fracture site, and necrosis of the femoral head and a gradual migration of the DHS system objectified in the 4th (Figure 2(b)) and 6th month (Figure 2(c)) postoperatively. The management consisted of a hip hemiarthroplasty (Figure 2(d)). At the last follow-up (18 months), the functional result was very good according to the PMA scale [5].

**2.3. Case 3.** A 56-year-old female farmer was received one hour from trauma to her right hip after falling from a motorcycle. The diagnosis of a basicervical fracture classified 32A2 according to AO/OTA (Figure 3(a)). A 7-hole DHS was installed. The evolution is marked by a vicious callus in the subtrochanteric region in the 4th postoperative month and pseudarthrosis of the femoral neck (Figure 3(b)). In the 6th

postoperative month, osteonecrosis of the femoral head and dynamic screw migration is observed (Figure 3(c)). The DHS was removed, and an uncemented total hip prosthesis was placed. At the last follow-up (24 months), the functional and radiological results were satisfactory according to the PMA scale [5].

**2.4. Case 4.** A 65-year-old male farmer sustained injuries when a motorbike hit him onto his right hip. At presentation, he was hemodynamically stable, and radiographs confirmed a minimally displaced pertrochanteric fracture of the right hip class 31A1.3 according to AO/OTA (Figure 4). The fracture was stabilized using DHS system after 72h. The patient had an uneventful peri-operative period and was allowed partial weight bearing. At his six

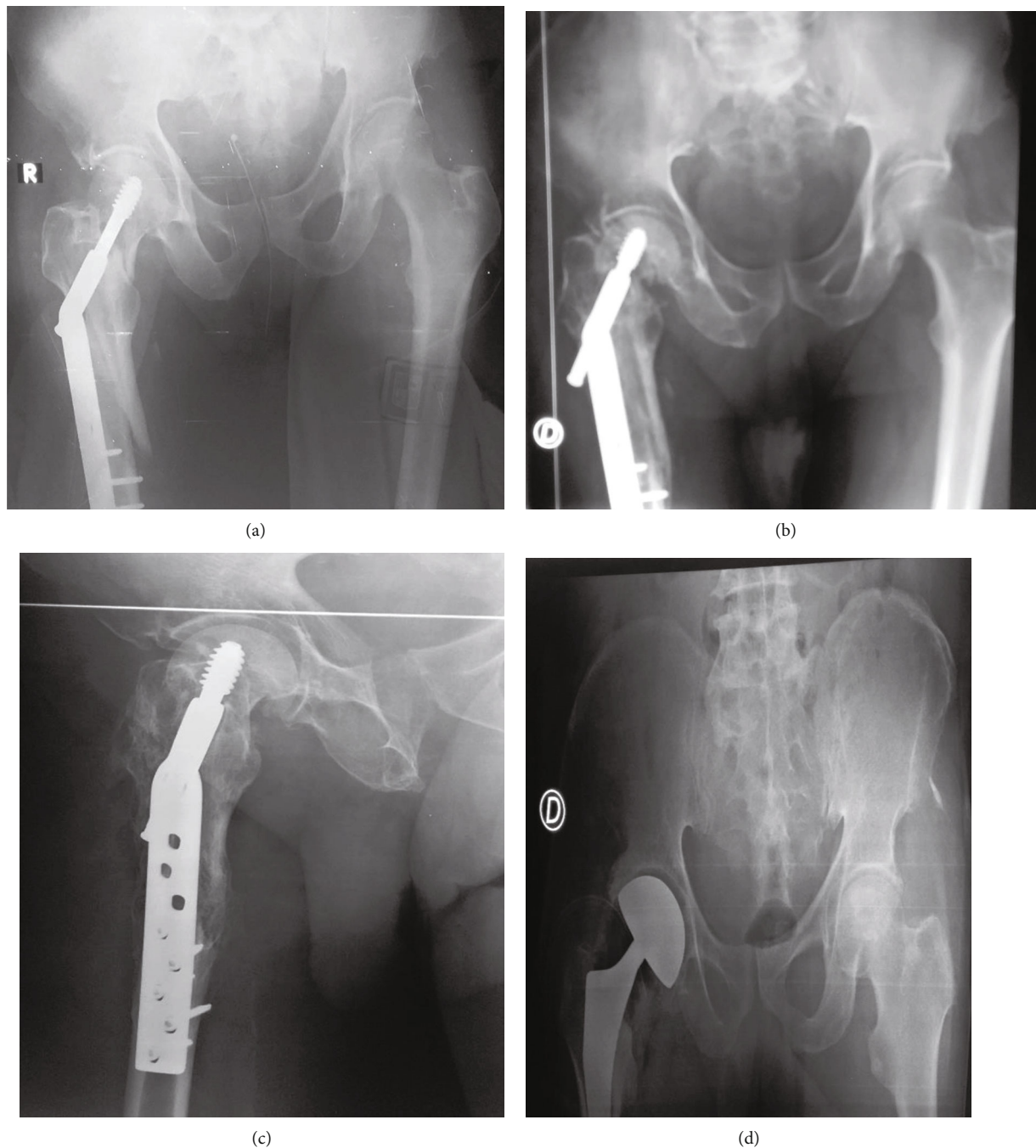


FIGURE 3: X-rays of patient 3. (a) Osteosynthesis y DHS. (b) Subtrochanteric malunion with pseudarthrosis of femur neck. (c) Cut out phenenon. (d) Hemiarthroplasty.

week outpatients' clinic appointment, radiographs showed callus and sliding screw fracture. He was therefore permitted full weight bearing after the removed of DHS system. One year after surgery, radiographs showed vicious callus with very good functional result [5]. He has returned to full-time work and is able to participate in low-impact recreational sporting activity.

2.5. *Case 5.* A 46-year-old male driver was involved in a high-speed motorbike accident in which he sustained inju-

ries onto his right hip. At presentation, he was hemodynamically stable, and radiographs confirmed a minimally displaced pertrochanteric fracture of the left hip class 31A1.2 according to AO/OTA (Figure 5). The fracture was stabilized using the DHS system (Figure 4(b)) after 3 days. The patient had an uneventful peri-operative period and was allowed partial weight bearing. At his nine month outpatients' clinic appointment, suppuration next to the operative scar is the objective, and radiographs showed callus at the proximal femoral fracture. *Staphylococcus*

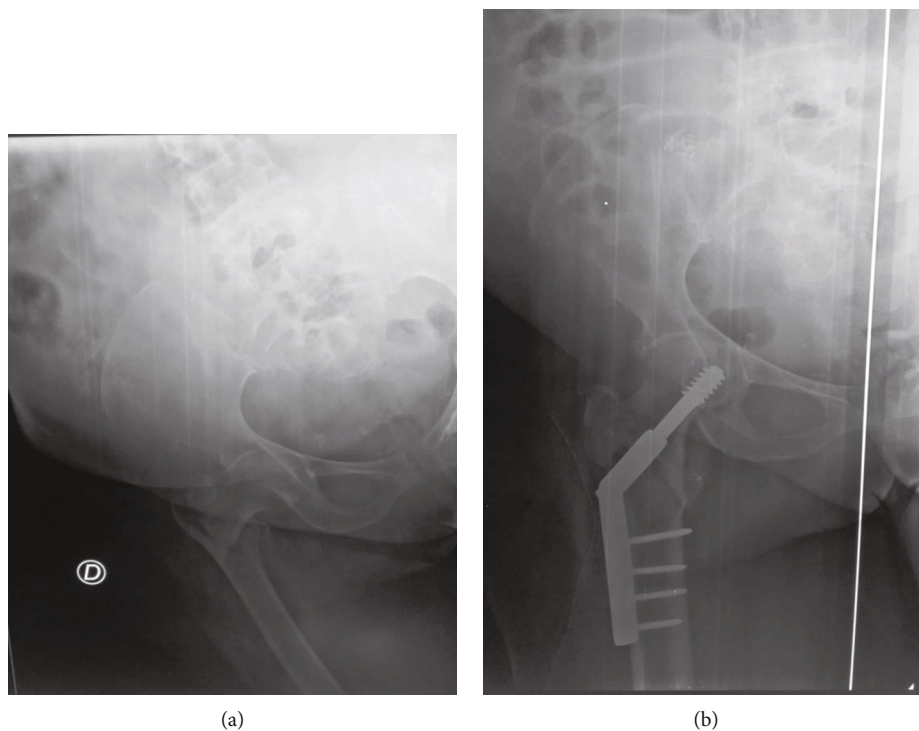


FIGURE 4: X-rays of patient 4. (a) Pertrochanteric fracture type 31A1.3 AO/OTA. (b) Osteosynthesis by DHS.

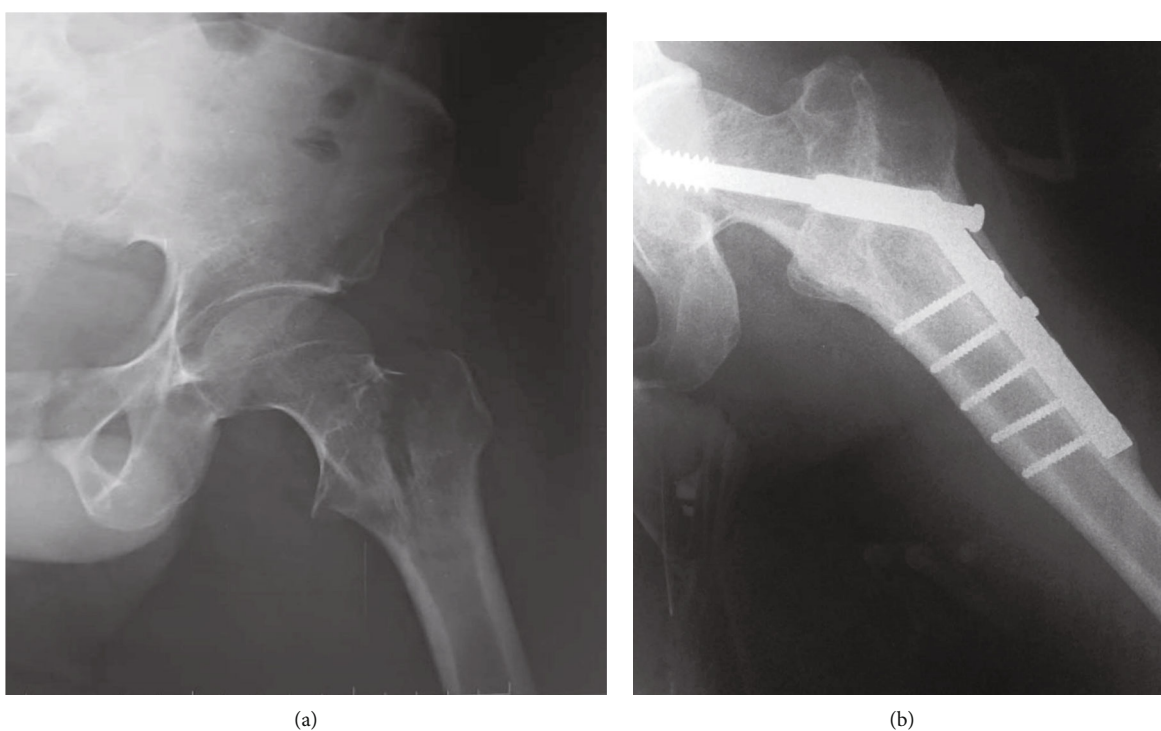


FIGURE 5: X-rays of patient 5. (a) Pertrochanteric fracture of the left hip class 31A1.2 according to AO/OTA. (b) Osteosynthesis by DHS.

aureus has been identified. The DHS system was removed followed by necrosectomy, washing, and drainage. He has returned to full-time work and is able to participate in recreational sporting activity.

### 3. Discussion

Postoperative complications of DHS are rare and not enough described [4]. The various complications described

are linked to deterioration of internal fixation leading to vicious callus, nonunion, or infection [1]. These complications are the cut out phenomenon, avascular necrosis of the femoral head, fracture of the DHS system, femoral plate fracture, and progression of coxarthrosis [4]. They represent a rate of 6% (22/367) according to Hrubina et al. [4]. We found 5 (6.5%) cases out of 77 internal fixation by DHS. We will discuss the indications, complications, and end treatments of our patients in light of the literature.

The DHS system is indicated mainly for trochanteric fractures. It is easy to set up and gives good results. However, it has limitations in cases of fracture of the lateral pillar of the upper extremity of the femur and comminution of the greater trochanter (case 3) [1].

Infection, although late, is a rare and serious complication. It can involve the vital and functional prognosis of the patient. We find 1 case of infection with *Staphylococcus aureus*. It is comparable with other relevant studies [6].

Malunion is a frequent complication of trochanteric osteosynthesis 12% for Decoulx and Lavarde [7] and lavender and 5% for Hrubina et al. [8]. It is due to an overestimation of bone quality and/or a technical error. We found 3/77 (3.9%) vicious calluses, one in the trochantero-diaphyseal region (patient 3) and 2 on the trochanteric mass in patient 4 and patient 5. These vicious calluses were tolerable and were not need a secondary realignment.

Pseudarthrosis is rare in the trochanteric mass because the vascularization is excellent [1]. On the femoral neck, there is a risk of cervical nonunion, whether or not associated with cephalic necrosis [9]. We noted 2 cases of nonunion of the cervix with avascular necrosis of the femoral head in patient 2 and patient 4. Hrubina et al. found 2 (0.5%) cases of nonunion in a series of 367 osteosynthesis by the DHS system.

Cut out phenomenon is a complication described in cases of osteoporosis in the elderly [1, 4]. It is also described in cases of targeting errors or progressive impaction of the fracture site. We find 3 cases (case 2, case 3, and case 4) in elderly patients with progressive impaction of the fracture site [10].

There are few articles about the metal breakage after the DHS osteosynthesis. For Hrubina et al. [8], there is metal breakage of K-wire, cortical screws, and sliding screw. We have seen a metal breakage of plate (case 1) and sliding screw (case 4).

#### 4. Conclusion

Postoperative complications from internal fixation by DHS are at army instructional Hospital in Libreville. They are sometimes result from the failings of surgeons. They can be avoided by rigorous asepsis, adequate surgical indications, and rigorous surgical techniques. Good management of its complications can restore hip function.

#### Conflicts of Interest

The authors declare that they have no conflicts of interest.

#### Authors' Contributions

Freddy Mertens Bombah did the conceptualization, data curation, and writing-original draft. Mohamadou Diawara did the conceptualization and writing-review and editing. Théophile Nana and Boukar Yannick Ekani did the writing-review and editing. Anicet Mikiela did the editing and supervision.

#### References

- [1] A. Morvan, J. Boddaert, J. Cohen-Bittan, H. Picard, H. Pascal-Mousselard, and F. Khiami, "Risk factors for cut-out after internal fixation of trochanteric fractures in elderly subjects," *Orthopaedics & Traumatology: Surgery & Research*, vol. 104, no. 8, pp. 1183–1187, 2018.
- [2] P. Oger, V. Katz, N. Lecorre, and P. H. Beaufile, "Fracture of the great trochanter treated by dynamic hip screw plate: measure of impaction according to fracture type," *Revue de Chirurgie Orthopédique et Réparatrice de l'appareil Moteur*, vol. 84, no. 6, pp. 539–545, 1998.
- [3] Y. H. Cha, J. I. Yoo, S. Y. Hwang et al., "Biomechanical evaluation of internal fixation of pauwels type III femoral neck fractures: a systematic review of various fixation methods," *Clinics in Orthopedic Surgery*, vol. 11, no. 1, pp. 1–14, 2019.
- [4] M. Hrubina, M. Skotak, and J. Behounek, "Complications of dynamic hip screw treatment for proximal femoral fractures," *Acta Chirurgiae Orthopaedicae et Traumatologiae Cechoslovaca*, vol. 77, no. 5, pp. 395–401, 2010.
- [5] D.'a. R. Merle, "Cotation chiffrée de la fonction de hanche," *Revue de Chirurgie Orthopédique et Réparatrice de l'appareil Moteur*, vol. 56, pp. 481–486, 1970.
- [6] M. Hrubina, M. Skotak, and J. Behounek, "DHS osteosynthesis for proximal femoral fractures: infectious complications," *Acta Chirurgiae Orthopaedicae et Traumatologiae Cechoslovaca*, vol. 80, no. 5, pp. 351–355, 2013.
- [7] P. Decoulx and G. Lavarde, "Les fractures de la région trochanterienne," in *71e congrès français de chirurgie*, Masson, Paris, 1969.
- [8] M. Hrubina, M. Skotak, O. Krumpl, and P. Mika, "Osteosynthetic material breakage in patients treated with DHS for proximal femoral fracture," *Rozhledy v Chirurgii: Mesicnik Ceskoslovenske Chirurgicke Spolecnosti*, vol. 91, pp. 146–150, 2012.
- [9] P. Simon, F. Gouin, D. Veillard et al., "Femoral neck fractures in patients over 50 years old," *Revue de Chirurgie Orthopédique et Réparatrice de l'appareil Moteur*, vol. 94, no. 6, pp. 108–132, 2008.
- [10] D. V. Prasad, S. Kumar, Y. Rabari, N. Bhatt, N. Suri, and A. Jadhav, "Comparative study between DHS and PFN in management of trochanteric an subtrochanteric femoral fractures," *International Journal of Orthopaedics*, vol. 3, pp. 106–108, 2017.