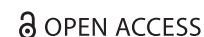

CASE REPORT



Persistent median artery in the carpal tunnel and anastomosis with superficial palmar arch

Dariush Bijannejad^a, Saeed Azandeh^a, Fatemeh Javadnia^a, Mohammad Reza Gholami^b,
Anneh Mohammad Gharravi^c and Mohsen zhaleh^d

^aDepartment of anatomy, Faculty of Medicine, Ahvaz Jundishapour University of Medical Sciences (AJUMS), Ahvaz, Iran; ^bDepartment of anatomy, Faculty of Medicine, Lorestan University of Medical Sciences, Khorram Abad, Iran; ^cSchool of Medicine, Shahroud University of Medical Sciences, Shahroud, Iran; ^dDepartment of anatomy, Faculty of Medicine, Kermanshah University of Medical Sciences, Kermanshah, Iran

ABSTRACT

Persistent median artery (PMA) in present cadaver originated from the brachial artery and anastomosed with the superficial palmar arch (SPA). As the PMA may be the cause of carpal tunnel syndrome and SPA is the main source of arterial supply, knowledge of which are important for the hand surgical interventions.

ARTICLE HISTORY

Received 11 December 2015
Accepted 13 March 2016

KEYWORDS

Persistent median artery;
superficial palmar arch;
carpal tunnel; variation

Introduction

The hand has been recognized as a site with multiple neural, vascular, tendinous and muscular anatomical variations.[1] The knowledge on the anatomical variations is important while surgical procedures such as arterial repairs, vascular graft applications are performed.

The median artery is a transitory vessel during early embryonic life and after the eighth week of gestation, is regressed by undergoing apoptosis to become as the arteria comitans nervi median. According to Rodriguez-Niedenfuhr et al. [2] the median artery in adult life can be categorized into two different patterns, antebrachial and palmar which is large, long artery and reaches the palm.

The space deep to the transverse carpal ligament is defined as the carpal tunnel. The ligament extends from the hook of the hamate and the triquetrum to the scaphoid and the trapezium. The carpal tunnel is bordered anteriorly by the flexor retinaculum and posteriorly by the carpal bones. The median nerve and tendons of muscles of the forearm that gain attachments to bones of the hand pass through the carpal tunnel: flexor pollicis longus, flexor digitorum

profundus and flexor digitorum superficialis muscles.[3] Carpal tunnel syndrome is caused by compression of the median nerve by the carpal flexor retinaculum. Increased pressure on the median nerve within the carpal tunnel results in a painful burning sensation or numbness of the first three fingers and some muscle atrophy. One of the most common causes of compression of the median nerve in the carpal tunnel is persistent median artery (PMA), which leads to compressive neuropathies.[4]

A classic superficial palmar arch (SPA) is mainly derived from the superficial branch of the ulnar artery (UA) and the superficial palmar branch of the radial artery (RA), from which the palmar digital arteries derive. SPA is the main source of arterial supply to the palm. The SPA has been classified into complete and incomplete types.[5]

Although the formation of the SPA by the RA, UA and PMA has been mentioned in the literature, the incidence in different populations is not yet known.[6]

In this study, we described the PMA in the carpal tunnel and the morphological variants of superficial palmar arch in Iranian cadaver. The present case documenting PMA and a radio-medio-ulnar type of SPA is the first of its kind reported in the recent literature

CONTACT Dr. Anneh Mohammad Gharravi ✉ annehgh@yahoo.com 📧 School of Medicine, Shahroud University of Medical Sciences, Shahroud, Iran

© 2016 The Author(s). Published by Taylor & Francis. This is an Open Access article distributed under the terms of the Creative Commons Attribution-NonCommercial License (<http://creativecommons.org/licenses/by-nc/4.0/>), which permits unrestricted non-commercial use, distribution, and reproduction in any medium, provided the original work is properly cited.

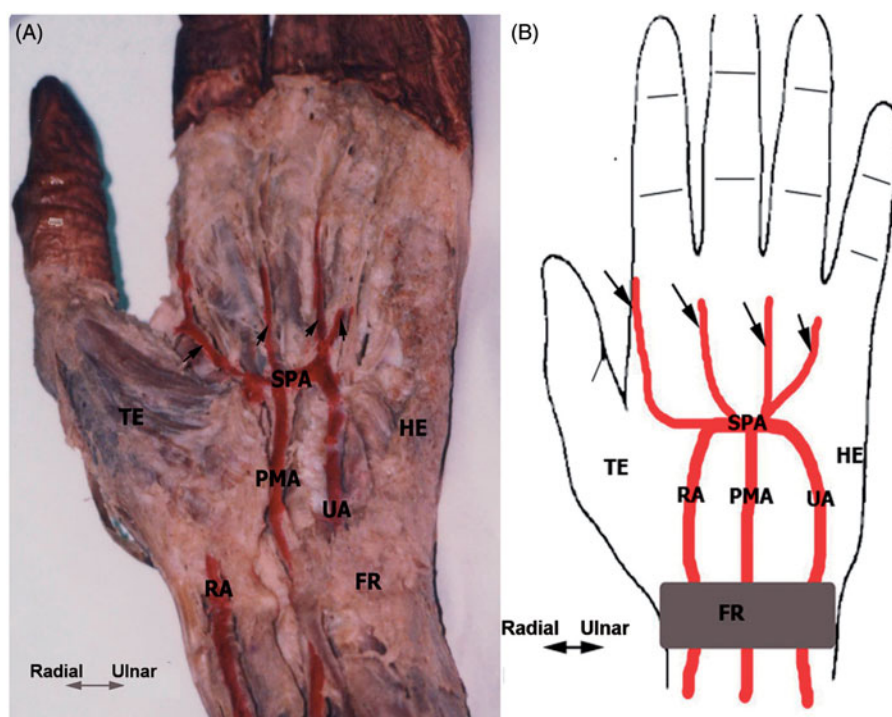


Figure 1. Ventral aspect of the distal third of the forearm and hand (after dissecting out from the cadaver and the arteries are colored red). (A) Cadaveric hand exhibiting the radio-medio-ulnar type of SPA. (B) Patterns of PMA contribution to SPA. Arrows indicate palmar digital arteries. FR, flexor retinaculum; HE, hypothenar eminence; TE, thenar eminence.

related to Iranian population. Although this type of SPA occurs very rarely, knowledge of this is important for the surgical interventions.

Case presentation

We encountered a persistent median artery in the left upper extremity of a formalin-fixed adult male cadaver during routine dissection in the Anatomy department of the Ahvaz Jundishapour University of Medical Science. The history of the individual and the cause of death was not known. During dissection, the arteries were colored with red for clear identification. In this case, the brachial artery was divided into RA and UA at the cubital fossa. Also, the PMA originated from the brachial artery (Figure 1). The PMA ran distally and passed under the flexor retinaculum. The size of the artery was as large as the radial artery. It anastomosed with the SPA. The SPA was complete and originated from three arteries: RA, UA and PMA. In addition, SPA gave four palmar digital arteries; proper palmar digital artery and three common palmar digital arteries, which pass to the medial three interdigital clefts.

Discussion

One of the most common causes of compression of the median nerve in the carpal tunnel is PMA;

therefore, knowledge on the anatomical variations of PMA is important when surgical procedures are performed on the hand.

In this study, we presented case report related to the PMA. Persistence of a median artery is not uncommon. In our study after 10 years' routine dissection, we found only one case of PMA among Iranian cadavers. The incidence of PMA is comparatively low in reported studies; 2.2–4.4%, 3.4% and 8% in Balakrishnan et al. [7], Lindley et al. [8] and Lippert and Pabst [9] studies, respectively, whereas in Henneberg and George [10] study the incidence was as high as 27.1% in Southern African cadavers.

According to Rodriguez-Niedenfuhr et al. [2] PMA in this study was palmar type which was large, long artery and reached the palm. This type of PMA was reported by similar studies.[11]

Owing to the thickness and blood supply capacity, SPA is more prominent than the other arteries of hand. In presenting the case report, PMA showed anastomosis with the SPA forming radio-medio-ulnar types of SPA, according to Schmidt [12] and corresponding to Type D of Group I of Coleman and Anson's classification.[6] Coleman and Anson [6] found the radio-medio-ulnar type of SPA in 1.2% of cases of 650 hands studied. Also, Al-Turk and Metcalf [13] found the same type of SPA in 2% of all hands. In study of Ikeda et al.

[14] and Tagil et al. [15] the radio-medio-ulnar type of SPA was absent. However, in the study of Loukas et al. [16] there were high percentages of the radio-medio-ulnar type (6.1%) of SPA in those dissected 200 hands.

In this study, four common digital arteries derived for supplying the second, third and fourth web spaces of hand similar to related studies.[17]

Taken together, this study described information related to PMA and the radio-medio-ulnar type of the SPA that would be useful in surgical intervention.

Disclosure statement

The authors declare that they have no competing interests.

References

- [1] Arey LB. Developmental anatomy: a textbook and laboratory manual of embryology. 7th ed. Philadelphia: Saunders; 1954.
- [2] Rodríguez-Niedenführ M, Sanudo J, Vazquez T, et al. Median artery revisited. *J Anat.* 1999;195:57–63.
- [3] Mitchell R, Chesney A, Seal S, et al. Anatomical variations of the carpal tunnel structures. *Can J Plast Surg.* 2009;17:e3.
- [4] Shimizu A, Ikeda M, Kobayashi Y, et al. Carpal tunnel syndrome caused by a ganglion in the carpal tunnel with an atypical type of palsy: a case report. *Hand Surg.* 2011;16:339–341.
- [5] Gray H, Williams P, Bannister L. *Gray's anatomy.* New York: Churchill Livingstone; 1995. p. 844.
- [6] Coleman S, Anson B. Arterial patterns in the hand based upon a study of 650 specimens. *Plast Reconstr Surg.* 1962;29:85–86.
- [7] Balakrishnan C, Emanuele JA, Smith FM. Asymptomatic persistent median artery in a trauma patient. *Injury.* 1997;28:697–698.
- [8] Lindley SG, Kleinert JM. Prevalence of anatomic variations encountered in elective carpal tunnel release. *J Hand Surg.* 2003;28:849–855.
- [9] Lippert H, Pabst R. *Arterial variations in man: classification and frequency.* Berlin: Springer-Verlag (Bergmann); 1985. p. 6,8,83.
- [10] Henneberg M, George B. High incidence of the median artery of the forearm in a sample of recent southern African cadavers. *J Anat.* 1992;180(Pt 1):185.
- [11] D'Costa S, Narayana K, Narayan P, et al. Occurrence and fate of palmar type of median artery. *ANZ J Surg.* 2006;76:484–487.
- [12] Schmidt H-M, Lanz U. *Surgical anatomy of the hand.* 1st ed. New York: Thieme Stuttgart; 2003. p. 29.
- [13] Al-Turk M, Metcalf W. A study of the superficial palmar arteries using the Doppler Ultrasonic Flowmeter. *J Anat.* 1984;138(Pt 1):27.
- [14] Ikeda A, Ugawa A, Kazihara Y, et al. Arterial patterns in the hand based on a three-dimensional analysis of 220 cadaver hands. *J Hand Surg.* 1988;13:501–509.
- [15] Tağil SM, Çiçekcibaşı AE, Öğün TC, et al. Variations and clinical importance of the superficial palmar arch. *SDÜ Tıp Fakül Derg.* 2007;14:11–16.
- [16] Loukas M, Holdman D, Holdman S. Anatomical variations of the superficial and deep palmar arches. *Folia Morphol.* 2005;64:78–83.
- [17] Madhyastha S, Murlimanju B, Jiji P, et al. Morphological variants of the human superficial palmar arch and their clinical implications. *J Morphol Sci.* 2011;28:261–264.