



Contents lists available at ScienceDirect

International Journal of Surgery Case Reports

journal homepage: www.casereports.com

Paracecal hernia with intestinal obstruction managed with laparoscopic surgery: A case report

Faisal Alghamdi^a, Ashwag Alharbi^{a,*}, Abdullah Alshamrani^b, Saud Alomani^a

^a Department of General Surgery, Prince Sultan Military Medical City, Riyadh, Saudi Arabia

^b Department of General Surgery, Security Forces Hospital Program, Riyadh, Saudi Arabia

ARTICLE INFO

Article history:

Received 13 October 2020

Received in revised form 25 October 2020

Accepted 25 October 2020

Available online 29 October 2020

Keywords:

Internal hernia

Paracecal hernia

Case report

Laparoscopic surgery

ABSTRACT

INTRODUCTION: Paracecal hernia is a rare cause of intestinal obstruction.

PRESENTATION OF CASE: A 75-year-old man presented with abdominal pain for 4 days, vomiting, and obstipation. Physical examination was not conclusive. Abdominal radiograph suggested small intestinal obstruction, and computed tomography confirmed an obstructed paracecal hernia. Intraoperatively, the hernial sac was seen passing through the inferior ileocecal recess. The distal bowel was collapsed. The appendix was inflamed. The hernia was reduced and appendectomy was performed. The patient recovered without complications and was discharged on the fifth postoperative day.

DISCUSSION: Internal hernia may be a cause of acute abdomen. Symptoms and signs may be nonspecific. Rapid recognition of the condition can prevent strangulation and ischemia of affected intestinal loops. Early resort to imaging examination will ensure quick diagnosis.

CONCLUSION: Paracecal hernia is a rare cause of intestinal obstruction. Awareness of the imaging features will help avoid delay in diagnosis. Laparoscopic surgery appears to be a safe and feasible treatment.

© 2020 The Author(s). Published by Elsevier Ltd on behalf of IJS Publishing Group Ltd. This is an open access article under the CC BY-NC-ND license (<http://creativecommons.org/licenses/by-nc-nd/4.0/>).

1. Introduction

Internal hernia is an unusual cause of intestinal obstruction, being responsible for only 0.5%–5.8% of all cases [1–6]. Meyer classified internal hernias into six types according to the site of herniation: paracecal sulci, cecal fossa, cecal recess, superior ileocecal recess, inferior ileocecal recess, and retrocecal recess [7]. Paracecal hernias account for 13% of all internal hernias, and are reported to be the cause of 1% of all small bowel obstructions [8]. The symptoms of internal hernias are nonspecific and so diagnosis may be delayed. Untreated intestinal obstruction may progress to strangulation, when the mortality rate is >50% [8,9]. The condition can be confidently diagnosed from computed tomography. We report a patient who presented with intestinal obstruction due to a paracecal hernia who was successfully treated by laparoscopic surgery.

This work has been reported in line with the SCARE criteria [10].

2. Presentation of case

In December 2019, a 75-year-old Saudi gentleman with history of insulin-dependent diabetes mellitus, presented to the emergency department complaining of abdominal pain for 1 week, that was dull and without radiation, had initially been in the right iliac

fossa, but had become generalized and increased gradually in intensity. There were no relieving or aggravating factors. The pain was associated with nausea, and the patient had vomited multiple times over the last 3 days, containing semi-digested food matter. He also had obstipation for the last 4 days. There was no previous history of bleeding per rectum, weight loss, fever. This patient has surgical history of left hip replacement 7 years ago due to fracture. The patient was not a smoker. There was no family history of any malignancies.

On examination, the patient was conscious, alert, and well oriented. There was no respiratory distress, pallor, or cyanosis. He appeared overweight. Vital signs were normal. Cardiovascular and respiratory system examinations were unremarkable. The abdomen was soft on palpation, but there was generalized tenderness. There was a hypertympanic note on percussion. Hernial orifices were normal.

Laboratory workup showed the following: white blood cell count, 4×10^9 /L; hemoglobin, 15 g/dL; platelet count, 220×10^9 /L; serum albumin, 32 g/L; carbohydrate antigen 19-9, 20 U/mL; carcinoembryonic antigen, 2.9 µg/L; serum alpha-fetoprotein, 8.4 kIU/L. An electrocardiogram showed normal sinus rhythm. Radiography of the chest and abdomen revealed dilated loops of bowel with multiple air–fluid levels, typical of small bowel obstruction. There was no air under the diaphragm (Fig. 1).

The patient was admitted for further workup. Computed tomography (CT) of the abdomen, axial and coronal views (Fig. 2),

* Corresponding author.

E-mail address: drashwag.al@gmail.com (A. Alharbi).

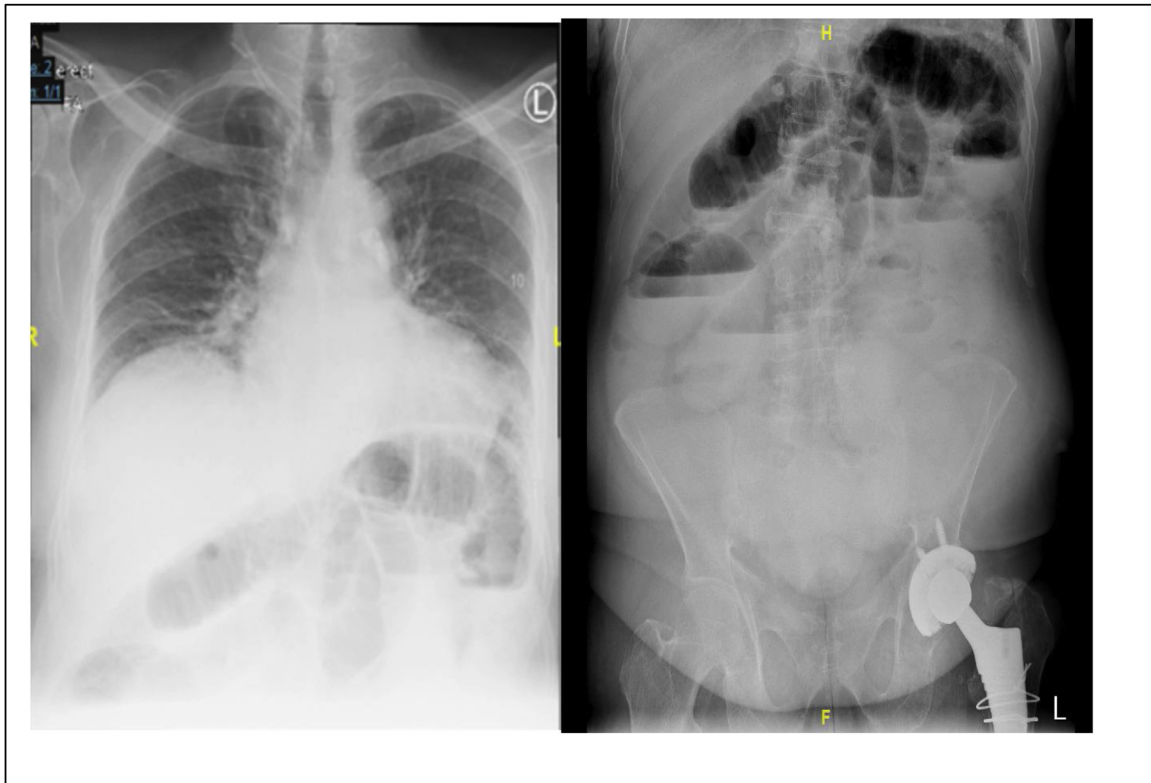

Fig. 1. Chest and abdomen radiographs reveal dilated bowel and multiple air–fluid levels; there is no air under the diaphragm.

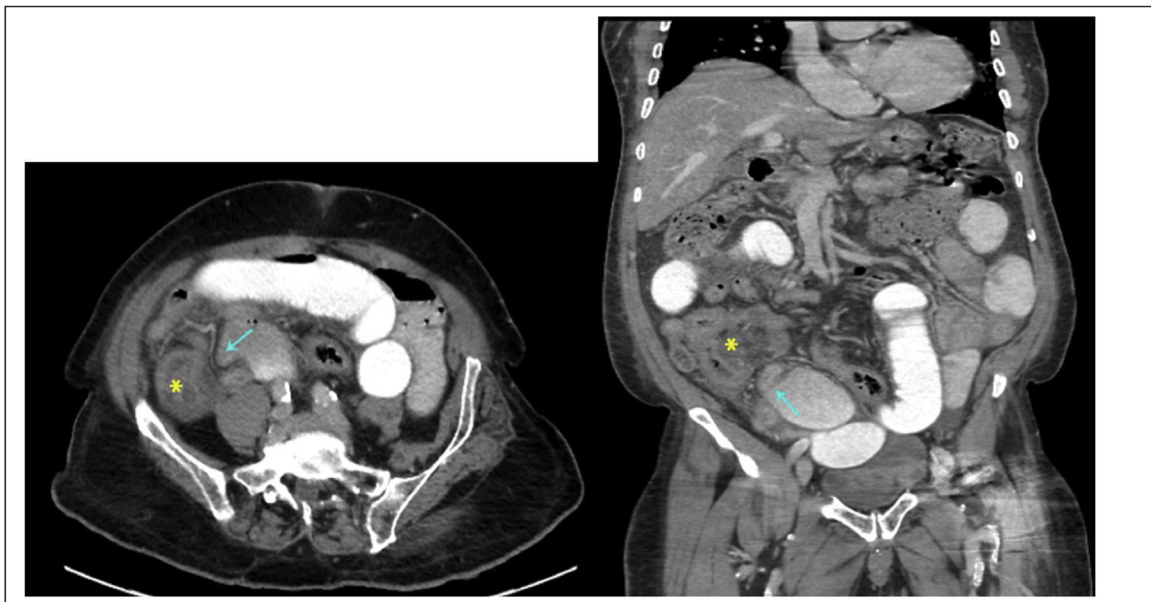


Fig. 2. CT abdomen axial views show small intestinal obstruction, with the transitional zone (arrow) at the cluster of inflamed distal ileal loops close to the cecum and ileocecal valve (asterisk); there are adjacent small loculated collections.

confirmed small intestinal obstruction, with the transitional zone at the cluster of inflamed distal ileal loops close to the cecum and ileocecal valve; there were adjacent small loculated collections, but no free air.

The patient was taken after that to the operating room for emergency laparoscopic exploration. Intraoperatively, small bowel was distended, with hernial sac containing small bowel was seen passing through the inferior ileocecal recess (Fig. 3). The distal bowel

was collapsed. The appendix was inflamed. No masses were visualized. The hernial sac was released, and the small bowel within the sac was reduced, revealing healthy, viable bowel. Laparoscopic appendectomy was performed and a drain was inserted. The post-operative course was uneventful. The drain was removed and the patient discharged after 5 days. Histopathology of the excised appendix showed luminal fibrosis with occasional foci of calcification.

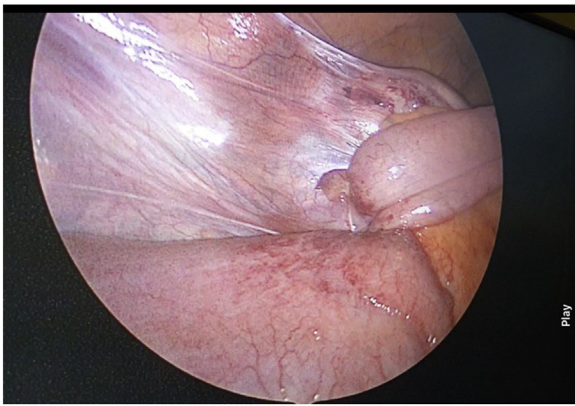

Fig. 3. Hernial sac containing small bowel entering through the inferior ileocecal recess.

3. Discussion

Internal hernia is the protrusion of abdominal viscera—usually small bowel—into a fossa, foramen, or recess in the abdominal or pelvic cavity [2]. The hernial orifice may be congenital (due to abnormalities in the process of intestinal rotation during embryonic development), or it may be acquired (following inflammation or previous surgery such as gastric bypass for bariatric treatment or liver transplantation) [5,11]. Internal hernias show no age or sex predilection [12]. They may be asymptomatic or may cause abdominal pain, vomiting, and recurrent intestinal obstruction [3,7–9]. Symptom severity is usually decided by the duration of the hernia, its reducibility, and the presence of incarceration and strangulation [3]. In paracecal hernias the pain tends to start in the right lower quadrant, and they can therefore sometimes be mistaken for appendicitis [8,13].

Imaging can reveal the diagnosis. However, because of the propensity of these hernias to spontaneously reduce, patients are best imaged when they are symptomatic [7,8]. Plain radiography and barium studies may show abnormally arranged or crowded distended small bowel loops within the hernial sac, and fluoroscopy may show apparent fixation and reversed peristalsis. CT is more informative. It can show the site, level, cause of obstruction, and the presence of ischemic changes in the involved bowel. On CT, paracecal hernias present usually as a cluster of bowel loops (usually ileal) located posteriorly and laterally to the normal cecum, occasionally extending into the right paracolic gutter [8,13–16]. A major advantage of CT is that it allows diagnosis of early or partial obstruction, closed loop obstruction, and multiple segments of obstruction. Dilated small intestine loops with a transitional zone adjacent to the cecum or an edematous small bowel located lateral to the cecum strongly suggest a diagnosis of paracecal hernia. Because of its wide availability, its speed, and multiplanar reformatting capabilities, CT has become the first-line imaging technique for intestinal obstruction due to suspected internal hernia [3,7]. For detection of small bowel obstruction, CT has sensitivity and specificity of 94%–100% and 90%–95%, respectively [15,16].

Laparoscopic surgery was previously considered to be inappropriate for small bowel obstruction because of the difficulty in establishing a working space and visualizing the site of obstruction and the consequent risk of injury to the distended bowel. However, a recent systematic review showed that morbidity is lower, hospital stay is shorter, and return of the bowel function is faster with laparoscopic surgery than with open surgery in the management of small bowel obstruction [17]; the authors concluded that laparoscopic surgery performed by an experienced surgeon is a fea-

sible alternative to laparotomy for treatment of acute small bowel obstruction.

Although internal hernias are uncommon, they must be considered in the differential diagnosis of acute abdominal pain, especially in cases of small bowel obstruction without external hernias. Even when herniation occurs through a wide orifice, as is generally the case in paracecal hernias, strangulation can occur rapidly; therefore, surgery should not be delayed [18]. A prompt imaging diagnosis can help avoid intestinal ischemia and necrosis.

4. Conclusion

Paracecal hernia is a rare cause of intestinal obstruction. Awareness of the imaging features will help in prompt diagnosis and avoidance of strangulation. Laparoscopic surgery is an excellent alternative to laparotomy, with several advantages for the patient.

Declaration of Competing Interest

The authors report no declarations of interest.

Funding

This research did not receive any specific grant from funding agencies in the public, commercial, or not-for-profit sectors.

Ethical approval

In our institute, ethical approval is exempted, depend on acquired patient consent.

Consent

Written informed consent was obtained from the guardian on behalf of the patient for publication of this case report. A copy of the written consent is available for review by the Editor-in-Chief of this journal.

Author contribution

All authors contributed to manuscript preparation, manuscript editing, manuscript review.

Registration of research studies

We don't need to register this work.

Guarantor

The Guarantor is DR Ashwag Alharbi.

Provenance and peer review

Not commissioned, externally peer-reviewed.

References

- [1] G.G. Ghahremani, Internal abdominal hernias, *Surg. Clin. North Am.* 64 (1984) 393–406, [http://dx.doi.org/10.1016/S0039-6109\(16\)43293-7](http://dx.doi.org/10.1016/S0039-6109(16)43293-7).
- [2] A. Osadchy, A. Keidar, R. Zissin, Small bowel obstruction due to a paracecal hernia: computerized tomography diagnosis, *Emerg. Radiol.* 11 (2005) 239–241, <http://dx.doi.org/10.1007/s10140-004-0397-5>.
- [3] A. Blachar, M.P. Federle, Internal hernia: an increasingly common cause of small bowel obstruction, *Semin. Ultrasound CT MR* 23 (2002) 174–183, [http://dx.doi.org/10.1016/S0887-2171\(02\)90003-X](http://dx.doi.org/10.1016/S0887-2171(02)90003-X).
- [4] H. Akyildiz, T. Artis, E. Sozuer, et al., Internal hernia: complex diagnostic and therapeutic problem, *Int. J. Surg.* 7 (2009) 334–337, <http://dx.doi.org/10.1016/j.ijsu.2009.04.013>.

- [5] L.C. Martin, E.M. Merkle, W.M. Thompson, Review of internal hernias: radiographic and clinical findings, *AJR Am. J. Roentgenol.* 186 (2006) 703–717, <http://dx.doi.org/10.2214/AJR.05.0644>.
- [6] H.P. Fan, A.D. Yang, Y.J. Chang, C.W. Juan, H.P. Wu, Clinical spectrum of internal hernia: a surgical emergency, *Surg. Today* 38 (2008) 899–904, <http://dx.doi.org/10.1007/s00595-007-3756-5>.
- [7] M.A. Meyers, Internal abdominal hernias, in: M.A. Meyers (Ed.), *Dynamic Radiology of the Abdomen*, 5th ed., Springer, New York, 2000, pp. 711–748.
- [8] G.G. Ghahremani, Abdominal and pelvic hernias, in: R.M. Gore, M.S. Levine (Eds.), *Textbook of Gastrointestinal Radiology*, 2nd ed., Saunders, Philadelphia, PA, 2000, pp. 1993–2009.
- [9] B.D. Newsom, J.S. Kukora, Congenital and acquired internal hernias: unusual causes of small bowel obstruction, *Am. J. Surg.* 152 (1986) 279–285, [http://dx.doi.org/10.1016/0002-9610\(86\)90258-8](http://dx.doi.org/10.1016/0002-9610(86)90258-8).
- [10] R.A. Agha, M.R. Borrelli, R. Farwana, K. Koshy, A. Fowler, D.P. Orgill, For the SCARE Group, The SCARE 2018 statement: updating consensus surgical Case REport (SCARE) guidelines, *Int. J. Surg.* 60 (2018) 132–136.
- [11] V. Schumpelick, B. Dreuw, K. Ophoff, A. Prescher, Appendix and cecum. Embryology, anatomy, and surgical applications, *Surg. Clin. North Am.* 80 (2000) 295–318, [http://dx.doi.org/10.1016/s0039-6109\(05\)70407-2](http://dx.doi.org/10.1016/s0039-6109(05)70407-2).
- [12] L.C. Martin, E.M. Merkle, W.M. Thompson, Review of internal hernias: radiographic and clinical findings, *AJR* 186 (2006) 703–717, <http://dx.doi.org/10.2214/AJR.05.0644>.
- [13] D. Mathieu, A. Luciani, Internal abdominal herniations, *AJR* 83 (2004) 397–404, <http://dx.doi.org/10.2214/ajr.183.2.1830397>.
- [14] S. Doishita, T. Takeshita, Y. Uchima, et al., Internal hernias in the era of multidetector CT: correlation of imaging and surgical findings, *Radiographics* 36 (2016) 88–106, <http://dx.doi.org/10.1148/rg.2016150113>.
- [15] M. Boudiaf, P. Soyer, C. Terem, J.P. Pelage, E. Maissiat, R. Rymer, CT evaluation of small bowel obstruction, *Radiographics* 21 (2001) 613–624, <http://dx.doi.org/10.1148/radiographics.21.3.g01ma03613>.
- [16] S. Pothiwala, A. Gogna, Early diagnosis of bowel obstruction and strangulation by computed tomography in emergency department, *World J. Emerg. Med.* 3 (2012) 227–231, <http://dx.doi.org/10.5847/wjem.j.issn.1920-8642.2012.03.012>.
- [17] D.B. O'Connor, D.C. Winter, The role of laparoscopy in the management of acute small-bowel obstruction: a review of over 2,000 cases, *Surg. Endosc.* 26 (2012) 12–17, <http://dx.doi.org/10.1007/s00464-011-1885-9>.
- [18] K. Inukai, E. Tsuji, S. Uehara, Paracecal hernia with intestinal ischemia treated with laparoscopic assisted surgery, *Int. J. Surg. Case Rep.* 44 (2018) 20–23, <http://dx.doi.org/10.1016/j.ijscr.2018.02.016>.

Open Access

This article is published Open Access at [sciencedirect.com](https://www.sciencedirect.com). It is distributed under the [IJSCR Supplemental terms and conditions](#), which permits unrestricted non commercial use, distribution, and reproduction in any medium, provided the original authors and source are credited.