

Comparison of Various Kinds of Probes for Lymphedematous Limbs

Hisako Hara, MD, PhD
Makoto Mihara, MD

Summary: Recently, there has been a growing interest in the use of lymphatic ultrasound in the preoperative investigation of lymphaticovenous anastomosis. The device used for the performance of lymphatic ultrasound varies among surgeons. In this case report, we compared several probes (18 MHz, 24 MHz, and 33 MHz linear probes) in 2 cases, to detect the lymphatic vessels in the lymphedematous limbs. In the upper limb lymphedema case, the lymphatic vessels were located at a depth of <5 mm. They could be better observed with the 33 MHz probe than with the 18 MHz probe. The probe with a high frequency (33 MHz) and high resolution seemed to be suitable for superficial layers <5 mm in depth. On the other hand, the probe of 33 MHz was not appropriate for the lymphedematous lower limb because the lymphatic vessels are usually located at around a depth of 1 cm. When comparing the 18 MHz and 24 MHz probes in observing the lymphatic vessels in the lower limb, the 24 MHz probe seemed more suitable because of its higher resolution. Among these options, the 33 MHz probe was suitable for lymphedematous upper limbs, and the 24 MHz probe was suitable for lymphedematous lower limbs. (*Plast Reconstr Surg Glob Open* 2021;9:e3490; doi: [10.1097/GOX.0000000000003490](https://doi.org/10.1097/GOX.0000000000003490); Published online 22 March 2021.)

Recently, the usefulness of lymphatic ultrasound in the preoperative examination of lymphaticovenous anastomosis (LVA) has been reported.¹⁻⁶ It provides essential information on lymphatic degeneration, which cannot be evaluated with lymphoscintigraphy or indocyanine green (ICG) lymphography; thus, it can diagnose the lymphatic dysfunction and suitable lymphatic vessels for LVA.^{2,3}

We previously reported the use of an ultrasound device with a common high-frequency probe (18 MHz), Eysenberg et al reported the use of a high-frequency probe (24 MHz), and Hayashi et al used an ultra-high frequency probe (70 MHz).¹⁻⁶ To our knowledge, there are no reports that discuss the suitability of probe frequency for detecting suitable lymphatics in lymphedematous limbs in the existing literature. In this case report, we compared several probes to detect the lymphatic vessels in lymphedematous limbs.

CASE 1

A 46-year-old woman underwent total mastectomy and axillary lymph node dissection, radiotherapy, and chemotherapy for right breast cancer 2 years previously. Three months postoperatively, lymphedema occurred in the right arm.

The right arm was stage 2b in International Society of Lymphology (ISL) staging. During lymphoscintigraphy, we injected ^{99m}Tc in the second web space of the hand,⁷ and dermal backflow was observed in the right forearm. During ICG lymphography, we injected ICG into multiple lymphosomes; the second and fourth web space in the hand, the flexion side of the wrist, and the distal point of the olecranon.⁸⁻¹⁰ Although we observed the lymphatic vessel from the wrist to the ulnar side soon after the injection, we could not identify any lymphatic vessels in the dorsum of the hand.

We performed lymphatic ultrasound as we previously reported,¹⁻³ and we observed dilated lymphatic vessels in the right dorsum of the hand and wrist. At the dorsum of the hand, in the ultrasonographic image of the 18 MHz linear probe of the Noblus ultrasound system (Hitachi Medical Corp., Tokyo, Japan), a blurred image of only 1 lymphatic vessel was obtained (Fig. 1A). In the image of the 33 MHz linear probe of Aplio i900 (Canon Medical

From the Department of Lymphatic and Reconstructive Surgery, JR Tokyo General Hospital, Tokyo, Japan.

Received for publication December 1, 2020; accepted January 26, 2021.

Copyright © 2021 The Authors. Published by Wolters Kluwer Health, Inc. on behalf of The American Society of Plastic Surgeons. This is an open-access article distributed under the terms of the [Creative Commons Attribution-Non Commercial-No Derivatives License 4.0 \(CCBY-NC-ND\)](https://creativecommons.org/licenses/by-nc-nd/4.0/), where it is permissible to download and share the work provided it is properly cited. The work cannot be changed in any way or used commercially without permission from the journal.

DOI: [10.1097/GOX.0000000000003490](https://doi.org/10.1097/GOX.0000000000003490)

Disclosure: The authors have no financial interest to declare in relation to the content of this article.

Related Digital Media are available in the full-text version of the article on www.PRSGlobalOpen.com.

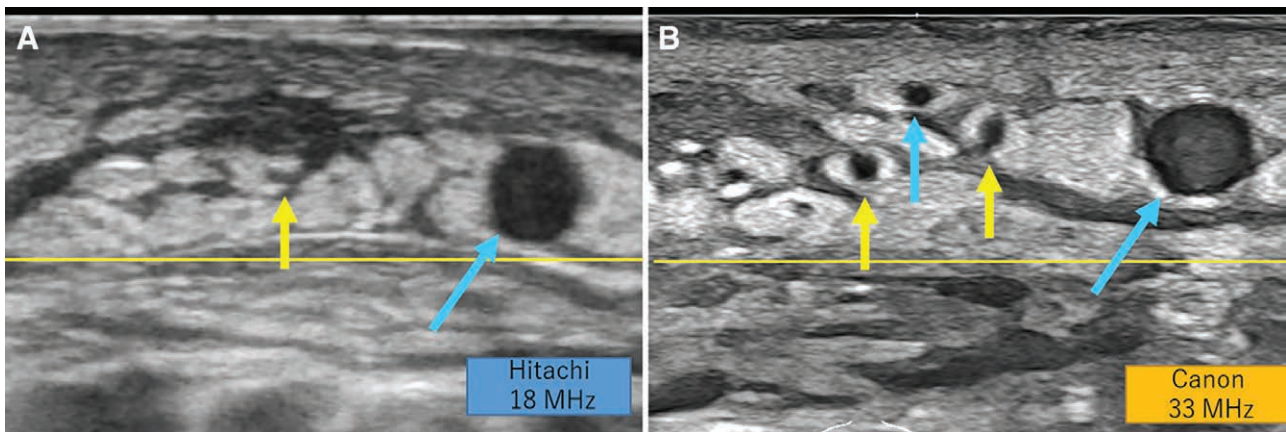


Fig. 1. Findings in the dorsum of the hand of Case 1. Yellow lines indicate a depth of 5 mm. A, In the ultrasonographic image of the 18 MHz linear probe, a blurred image of only 1 lymphatic vessel was obtained (yellow arrow). A large subcutaneous vein was also detected (blue arrow). B, In the ultrasonographic image of the 33 MHz linear probe, 2 dilated lymphatic vessels were clearly observed (yellow arrows). Both were at a depth of <5 mm. In addition, 1 large vein and 1 small vein were detected (blue arrows).

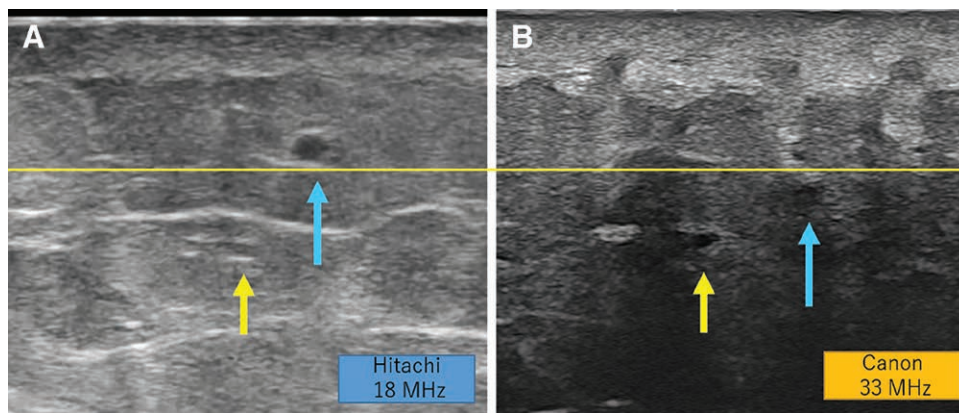


Fig. 2. Findings in the medial lower leg of Case 2. Yellow lines indicate a depth of 5 mm. A, In the ultrasonographic image of the 18 MHz linear probe, a lymphatic vessel with a gray lumen was observed (yellow arrow). It was located at a depth of 1 cm and the superficial and the deep sides of the vessel walls were seen as hypoechoic lines, which looked like an equal mark. The subcutaneous vein was also detected (blue arrow). B, In the ultrasonographic image of the 33 MHz linear probe, the lymphatic vessel appeared faint and difficult to distinguish from the surrounding tissue due to the attenuation of ultrasonic wave (yellow arrow). The subcutaneous vein was also seen briefly (blue arrow).

Systems Corp., Tokyo, Japan), 2 dilated lymphatic vessels were clearly observed (Fig. 1B). Both were at a depth of <5 mm. It took 15 minutes to perform ultrasound for the entire right arm. We performed 2 LVAs in the dorsum of the hand and wrist; intraoperative findings were consistent with ultrasonographic findings.

CASE 2

A 45-year-old woman underwent radical hysterectomy and pelvic lymph node dissection, radiotherapy, and chemotherapy for uterine cancer 7 years previously. Five months postoperatively, lymphedema occurred in the left leg.

The right and left leg were diagnosed as stage 1 and 2b, respectively, in ISL staging. During lymphoscintigraphy, we injected ^{99m}Tc into the first web space of the foot, and dermal backflow was observed in the entire left leg. During ICG lymphography, we injected ICG into multiple

lymphosomes: the first web space in the foot, lateral ankle, and lateral thigh. We observed 2 lymphatic vessels and subsequent dermal backflow points in the lateral calf and lateral thigh. On the next day, we observed dermal backflow in the entire limb.

During lymphatic ultrasound, we observed dilated lymphatic vessels in the lower leg and the thigh, around the dermal backflow point in ICG lymphography. In the medial lower leg, in the image of the 18 MHz linear probe of the Noblus ultrasound system, a lymphatic vessel with a gray lumen was observed (Fig. 2A). It was located at a depth of 1 cm, and the superficial and deep sides of the vessel walls were seen as hyperechoic lines, which looked like an equal mark. In the image of the 33 MHz linear probe of Aplio i900, the lymphatic vessel appeared faint and difficult to distinguish from the surrounding tissue due to the attenuation of the ultrasonic wave (Fig. 2B). Oppositely, in the image of the 24 MHz linear probe of

Aplio i900, the lymphatic vessel was easily distinguished from the surrounding tissue because the lumen was clearly hypoechoic. (See Video [online], which displays the ultrasonographic movie of the lymphatic vessel (yellow arrow) and the nearby subcutaneous vein. The lymphatic vessel was located beneath the superficial fascia, with a depth of approximately 1 cm. The number “1” at the left end indicates the 1-cm depth. Lymphatic vessels appeared and disappeared on ultrasound because thick and thin areas appeared alternately.)

It took 30 minutes to perform ultrasound for bilateral legs. We performed 2 LVAs in the lower leg and 1 LVA in the thigh, all of which had intraoperative findings that were consistent with ultrasonographic findings.

DISCUSSION

In this case report, we present 2 cases of lymphedema in which we compared the ultrasonographic findings of the lymphatic vessels with several probes.

In the lymphedematous upper limbs, lymphatic vessels were located at a depth of <5 mm. They could be better observed with the 33 MHz probe than with the 18 MHz probe. A probe with a high frequency (33 MHz) and high resolution seemed to be suitable for superficial layers <5 mm in depth.

On the other hand, the 33-MHz probe was not appropriate for the lymphedematous lower limb because the lymphatic vessels are usually located at around a depth of 1 cm. When comparing the 18 MHz and 24 MHz probes, the 24 MHz probe seemed more suitable. The lumen of the lymphatic vessel was clearly hypoechoic, which could be clearly distinguished from the surrounding fat tissue. Generally, higher resolution is achieved with higher frequency, though the penetration becomes smaller with higher frequency.¹¹

Hayashi and Visconti reported the use of a 18 MHz and 70 MHz probe in lymphatic ultrasound in healthy limbs. The average depth of the lymphatic vessels detected only with the ultra-high-frequency probe was 0.26 mm, which seems to be too superficial for the lower extremities. Even in the current cases, we set the frequency at 19 MHz with the 33 MHz probe because the penetration was too small at 33 MHz.

CONCLUSIONS

Currently, among the options, the 33-MHz probe was suitable for lymphedematous upper limbs and the 24 MHz probe was suitable for lymphedematous lower limbs. It would be ideal to use different probes depending on the site to be operated on and the severity of lymphedema.

In the current case report, we presented only 2 cases, and future research with a larger number of cases is necessary to determine the appropriate probe for lymphatic ultrasound.

Makoto Mihara, MD

Department of Lymphatic and Reconstructive Surgery
JR Tokyo General Hospital
2-1-3 Yoyogi
Shibuya-ku
Tokyo

E-mail: mihara.plasticsurgery@gmail.com

ACKNOWLEDGMENT

This case report is approved by the institutional ethical committee (approval no: H30-08).

REFERENCES

1. Hara H, Mihara M. Usefulness of preoperative echography for detection of lymphatic vessels for lymphaticovenous anastomosis. *SAGE Open Med Case Rep.* 2017;5:2050313X17745207.
2. Mihara M, Hara H, Kawakami Y. Ultrasonography for classifying lymphatic sclerosis types and deciding optimal sites for lymphatic-venous anastomosis in patients with lymphoedema. *J Plast Reconstr Aesthet Surg.* 2018;71:1274–1281.
3. Hara H, Mihara M. Diagnosis of lymphatic dysfunction by evaluation of lymphatic degeneration with lymphatic ultrasound. *Lymphat Res Biol.* 2021 (E-pub ahead of print).
4. Czedik-Eysenberg M, Steinbacher J, Obermayer B, et al. Exclusive use of ultrasound for locating optimal LVA sites—A descriptive data analysis. *J Surg Oncol.* 2020;121:51–56.
5. Hayashi A, Giacalone G, Yamamoto T, et al. Ultra high-frequency ultrasonographic imaging with 70 MHz scanner for visualization of the lymphatic vessels. *Plast Reconstr Surg Glob Open.* 2019;7:e2086.
6. Visconti G, Bianchi A, Hayashi A, et al. Ultra-high frequency ultrasound preoperative planning of the rerouting method for lymphaticovenular anastomosis in incisions devoid of vein. *Microsurgery.* 2020;40:717–718.
7. Maegawa J, Mikami T, Yamamoto Y, et al. Types of lymphoscintigraphy and indications for lymphaticovenous anastomosis. *Microsurgery.* 2010;30:437–442.
8. Suami H, Shin D, Chang DW. Mapping of lymphosomes in the canine forelimb: comparative anatomy between canines and humans. *Plast Reconstr Surg.* 2012;129:612–620.
9. Hara H, Mihara M. Multilymphosome injection indocyanine green lymphography can detect more lymphatic vessels than lymphoscintigraphy in lymphedematous limbs. *J Plast Reconstr Aesthet Surg.* 2020;73:1025–1030.
10. Hara H, Mihara M. Multi-area lymphaticovenous anastomosis with multi-lymphosome injection in indocyanine green lymphography: a prospective study. *Microsurgery.* 2019;39:167–173.
11. Barcaui Ede O, Carvalho AC, Lopes FP, et al. High frequency ultrasound with color Doppler in dermatology. *An Bras Dermatol.* 2016;91:262–273.