

## Groove Pancreatitis: Four Cases from a Single Center and Brief Review of the Literature

Tyler P. Black, MD<sup>1</sup>, Cynthia D. Guy, MD<sup>2</sup>, Rebekah R. White, MD<sup>3</sup>, Jorge Obando, MD<sup>4</sup>, and Rebecca A. Burbridge, MD<sup>4</sup>

<sup>1</sup>Department of Internal Medicine, Duke University Medical Center, Durham, NC

<sup>2</sup>Department of Pathology, Duke University Medical Center, Durham, NC

<sup>3</sup>Department of Surgery, Duke University Medical Center, Durham, NC

<sup>4</sup>Department of Gastroenterology, Duke University Medical Center, Durham, NC

---

### Abstract

Groove pancreatitis is a rare form of chronic pancreatitis that affects the groove anatomical area between the head of the pancreas, duodenum, and common bile duct. We provide a summary of the clinical findings of 4 groove pancreatitis cases diagnosed at a tertiary academic medical center over a 5-year period. A detailed review of the current literature surrounding this clinical entity is also provided. Although rare, groove pancreatitis should be considered in the differential diagnosis of patients presenting with pancreatic head mass lesions, as appropriate diagnosis can help avoid unnecessary surgical procedures.

---

### Introduction

Groove pancreatitis is a rare condition characterized by fibrotic inflammation affecting the anatomical area between the head of the pancreas, duodenum, and common bile duct.<sup>1</sup> This condition can often be difficult to differentiate from adenocarcinoma of the pancreatic head, but certain clinical, radiological, and histological features can be useful in making a diagnosis. The prevalence of groove pancreatitis has been difficult to establish, but has been reported as high as 24.5% in pancreaticoduodenectomy specimens from patients with chronic pancreatitis.<sup>2</sup> It often presents in middle-aged males (aged 40–50 years) with a history of alcohol consumption, recurrent or chronic pancreatitis, and pancreatic head mass lesions on imaging.<sup>3</sup> Its presentation is similar to adenocarcinoma of the pancreatic head or, more rarely, autoimmune pancreatitis, but can often be cured by conservative management.<sup>4,5</sup> We present a series of 4 cases of groove pancreatitis diagnosed at a tertiary medical center over a 5-year period, with a detailed review of the current medical literature.

### Case Report

Four cases of suspected groove pancreatitis were identified over a 5-year period. Two cases had histological confirmation of groove pancreatitis. The other 2 cases were considered to be likely diagnoses based on the clinical presentation and imaging findings. Table 1 shows a summary of the findings for each case. The average age was 56.5 years. Two patients were African American and 2 were female. All patients presented with abdominal pain and were given a diagnosis of pancreatitis based on an elevation of lipase and/or amylase. Two patients had both computed tomography (CT) and magnetic resonance imaging (MRI), while the other 2 patients had either CT or MRI. A representative CT image from patient 3 is shown in Figure 1. Patients 1 and 4 were given a diagnosis of groove pancreatitis based on their imaging findings, whereas patients 2 and 3 were diagnosed by

---

*ACG Case Rep J* 2014;1(3):154–157. doi:10.14309/crj.2014.35. Published online: April 4, 2014.

**Correspondence:** Tyler P. Black, Duke University Medical Center, 2301 Erwin Road, Durham, NC, 27710 (tylerpblack@gmail.com).

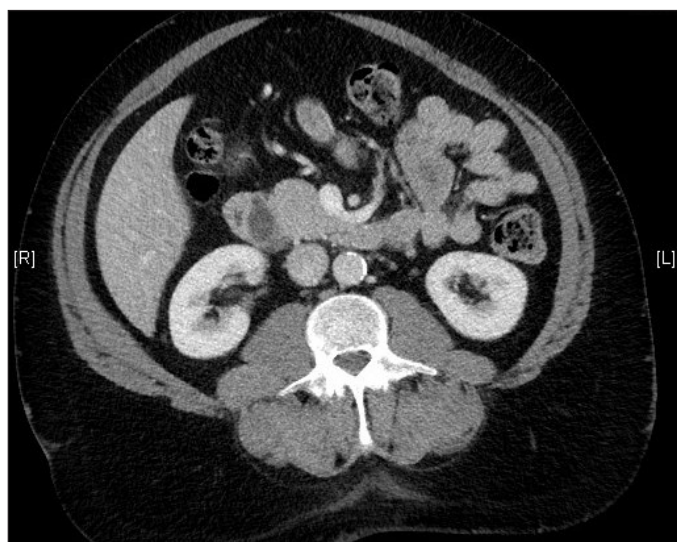
**Copyright:** © 2014 Black et al. This is an open-access article distributed under the terms of the Creative Commons Attribution License, which permits unrestricted use, distribution, and reproduction in any medium, provided the original author and source are credited.

**Table 1.** Patient Information and Diagnostics Summary

	Patient 1	Patient 2	Patient 3	Patient 4
Age, y	53	58	47	68
Race	White	Black	Black	White
Sex	Female	Male	Male	Female
Symptoms	Abdominal pain, nausea/vomiting, recurrent episodes of pancreatitis	Abdominal pain, nausea	Abdominal pain, recurrent episodes of pancreatitis	Abdominal pain, nausea
Tobacco	Yes	Yes	Yes	Yes
Alcohol	No	No	Yes	No
CT	Low-density mass in the region of the pancreatic head adjacent to the duodenum, with surrounding inflammatory changes  Thickening involving the second portion of the duodenum	None	Multiloculated cystic structure interposed between the pancreatic head and duodenum  6-mm hypoenhancing focus in the pancreatic head	Stranding around the pancreatic head and second portion of the duodenum consistent with groove pancreatitis
MRI	Pancreatic head lesion without corresponding pancreatic ductal dilatation	Pancreatic head is enlarged and inhomogenous  Significant dilation of the pancreatic duct  Complex cystic mass between the duodenum and pancreatic head	Same findings as CT	None
Pathology	Non-diagnostic	Pancreatic head and duodenum: chronic pancreatitis with features suggestive of groove pancreatitis (para-ampullary duodenal wall cyst noted)  Duodenum with Brunner's gland hyperplasia  Negative for malignancy	Pancreas negative for malignancy  Debris and reactive ductal epithelium suggestive of chronic pancreatitis	None

CT=computed tomography; MRI=magnetic resonance imaging

a combination of imaging and histological findings. Histology was obtained for patient 1, but was non-diagnostic. The pancreatic head mass seen on the imaging from patient 1 resolved on a follow-up MRI 2 months later. Histology was not obtained for patient 4. Patients 1 and 3 presented with



**Figure 1.** Abdominal CT from patient 3 showing a 6-mm hypoenhancing pancreatic head mass.

recurrent episodes of pancreatitis, which is often seen before a diagnosis of groove pancreatitis is established. All 4 patients were active or former smokers. One patient had a significant alcohol use history.

## Discussion

Groove pancreatitis was first described by Becker in 1973 in the German literature as “segmentare pancreatitis.”<sup>6</sup> In 1982, Stolte et al defined groove pancreatitis as a special form of segmental pancreatitis characterized by fibrous scars of the anatomic space between the dorsocranial part of the head of the pancreas, the duodenum, and the common bile duct.<sup>7</sup> In the early 1990s, Becker and Mischke further classified groove pancreatitis into pure and segmental forms. The pure form involves the groove area only, with preservation of the pancreatic parenchyma and main pancreatic duct. The segmental form involves both the groove and the head of the pancreas with stenosis of the pancreatic duct causing upstream dilatation.<sup>8</sup>

The prevalence of groove pancreatitis varies widely. In 3 surgical series, groove pancreatitis was diagnosed in 2.7%, 19.5%, and 24.5% of pancreaticoduodenectomy specimens taken from patients with chronic pancreatitis.<sup>7-9</sup> Groove

pancreatitis often presents in alcoholic men aged 40–50 years.<sup>7,8</sup> Presenting symptoms consist of abdominal pain, nausea, vomiting, and weight loss.<sup>7,8</sup> Laboratory evaluation often reveals an elevation in pancreatic enzymes and rarely an elevation in hepatic enzymes.<sup>10</sup> Carcinoembryonic antigen and carbohydrate antigen 19-9 can also be elevated.<sup>9</sup>

A diagnosis of groove pancreatitis is often difficult to establish. The most important distinction to make is between groove pancreatitis and adenocarcinoma of the head of the pancreas. Ultrasound will typically show a hypoechoic mass, and CT will often reveal a hypodense, poorly enhancing mass between the head of the pancreas and a thickened duodenal wall.<sup>11</sup> The most characteristic MRI finding is a sheet-like mass between the head of the pancreas and the duodenum associated with duodenal wall cystic changes and thickening.<sup>5</sup> Endoscopic retrograde cholangiopancreatography (ERCP) and endoscopic ultrasonography (EUS) are often useful in the differentiation of groove pancreatitis from pancreatic adenocarcinoma, and should be used early in evaluation even when cross-sectional imaging is not suggestive of a mass.<sup>12</sup> Table 2 lists characteristic imaging features differentiating groove pancreatitis from pancreatic adenocarcinoma.

The pathogenesis of groove pancreatitis remains unclear, and several mechanisms have been proposed. The most accepted mechanism is a disturbance of pancreatic outflow in the duct of Santorini through the minor papilla.<sup>13,14</sup> Chronic alcohol consumption is felt to contribute by increasing the viscosity of the pancreatic juice, leading to Brunner gland hyperplasia and causing occlusion or dysfunction of the minor papilla.<sup>13,14</sup> Another proposed mechanism is pancreatic heterotopia in the minor papilla causing dysfunction and occlusion of the papilla.<sup>13</sup> Other factors, such as fibrous scarring secondary to peptic ulcers, gastric and duodenal resections, or true duodenal wall cysts may also be related.<sup>5</sup>

The treatment of choice is conservative in the acute phase of groove pancreatitis and includes bowel rest, analgesia, and intravenous fluids.<sup>10</sup> Patients may have a protracted course requiring supplemental nutrition with tube feeding or total parenteral nutrition. One report demonstrated successful treatment of groove pancreatitis by endoscopic drainage of the accessory pancreatic duct via the minor papilla in patients where obstruction of the minor papilla appears to play a role in the pathogenesis.<sup>15</sup> Groove pancreatitis can be resistant to medical treatment and require surgical intervention. The surgical treatment of choice is a Whipple procedure (pancreaticoduodenectomy) or a pylorus-preserving pancreaticoduodenectomy.<sup>2</sup>

In our series of 4 patients, a combination of clinical and radiological features was used to make the diagnosis of groove

**Table 2.** Differentiation of Groove Pancreatitis and Pancreatic Adenocarcinoma Based on Imaging Features

Imaging	Groove Pancreatitis	Pancreatic Adenocarcinoma
CT	Hypoechoic mass between pancreatic head and duodenum, duodenal wall thickening, cystic changes, and stenosis, normal-to-mildly dilated common bile duct	Pancreatic head mass, with or without dilation of common bile duct and/or pancreatic duct
MRI	Sheet-like mass in groove, duodenal thickening, common bile duct stenosis	Enlarged mass mostly in pancreatic head, with widening of the space between the distal pancreatic duct and common bile duct and duodenal lumen
ERCP/EUS	Smooth tubular common bile duct stenosis	Irregular common bile duct stenosis, vascular encasement

CT=computed tomography; ERCP=endoscopic retrograde cholangiopancreatography; EUS=endoscopic ultrasonography; MRI=magnetic resonance imaging  
Adapted from Levenick et al<sup>4</sup> and Malde et al<sup>14</sup>

pancreatitis. Although other case reports show common alcohol use and a male predominance, 2 of our patients were female and only 1 patient had a history of significant alcohol use. Although rare, this condition should be considered in the differential diagnosis of pancreatic head masses with signs of duodenal wall infiltration. Alternatively, a careful and thorough evaluation to rule out adenocarcinoma should be performed before a definitive diagnosis of groove pancreatitis is established.

## Disclosures

Author contributions: All authors contributed equally to the preparation of this manuscript. RA Burbridge is the author guarantor.

Financial disclosure: None to report.

Informed consent was obtained for this case report.

Received: December 20, 2013; Accepted: March 4, 2014

## References

- Manzelli A, Petrou A, Lazzaro A, et al. Groove pancreatitis. A mini-series report and review of the literature. *JOP*. 2011;12(3):230–3.
- Balakrishnan V, Chatni S, Radhakrishnan L, et al. Groove pancreatitis: A case report and review of literature. *JOP* 2007;8(5):592–7.
- Levenick JM, Gordon SR, Sutton JE, et al. A comprehensive, case-based review of groove pancreatitis. *Pancreas*. 2009;38(6):e169–e175.
- Levenick JM, Sutton JE, Smith KD, et al. Paencreaticoduodenectomy for the treatment of groove pancreatitis. *Dig Dis Sci*. 2012;57(7):1954–8.
- Triantopoulou C, Dervenis C, Giannakou N, et al. Groove pancreatitis: A diagnostic challenge. *Eur Radiol*. 2009;19(7):1736–43.
- Becker V. Proceedings: Fundamental morphological aspects of acute and chronic pancreatitis [in German]. *Langenbecks Arch Chir*. 1973;334:317–22.
- Stolte M, Weiss W, Volkholz H, Rösch W. A special form of segmental pancreatitis: Groove pancreatitis. *Hepatogastroenterology*. 1982;29(5):198–208.

8. Becker V, Mischke U. Groove pancreatitis. *Int J Pancreatol*. 1991;10(3-4):173-82.
9. Yamaguchi K, Tanaka M. Groove pancreatitis masquerading as pancreatic carcinoma. *Am J Surg*. 1992;163(3):312-6.
10. Shudo R, Yazaki Y, Sakurai S, et al. Groove pancreatitis: Report of a case and review of the clinical and radiologic features of groove pancreatitis reported in Japan. *Int Med*. 2002;41(7):537-42.
11. Gabata T, Kadoya M, Terayama N, et al. Groove pancreatic carcinomas: Radiological and pathological findings. *Eur Radiol*. 2003;13:1679-84.
12. Newton B, Rittenbury M, Anderson M. Extrahepatic biliary obstruction associated with pancreatitis. *Ann Surgery*. 1983;197(6):645-53.
13. Chatelain, D, Vibert E, Yzet T, et al. Groove pancreatitis and pancreatic heterotopia in the minor duodenal papilla. *Pancreas*. 2005;30(4):e92-e95.
14. Malde DJ, Oliveira-Cunha M, Smith AM. Pancreatic carcinoma masquerading as groove pancreatitis: Case report and review of literature. *JOP*. 2011;12(6):598-602.
15. Isayama H, Kawabe T, Komatsu Y, et al. Successful treatment for groove pancreatitis by endoscopic drainage via the minor papilla. *Gastrointest Endosc*. 2005;61(1):175-8.

### Publish your work in ACG Case Reports Journal

ACG Case Reports Journal is a peer-reviewed, open-access publication that provides GI fellows, private practice clinicians, and other members of the health care team an opportunity to share interesting case reports with their peers and with leaders in the field. Visit <http://acgcasereports.gi.org> for submission guidelines. Submit your manuscript online at <http://mc.manuscriptcentral.com/acgcr>.