

**Case Report**

# Redo Descending Aortic Replacement via Direct Anastomosis to J Graft Open Stent Graft

Sho Kusadokoro, MD, Daijiro Hori, MD, PhD, Ryo Itagaki, MD, Koichi Adachi, MD, and Atsushi Yamaguchi, MD, PhD

A 64-year-old man with prior history of total arch replacement with frozen elephant trunk was admitted for an enlarging descending thoracic aortic aneurysm. Preoperative computed tomography revealed previously implanted J graft open stent graft, a frozen elephant trunk device approved in Japan, with enlarged dissected aortic aneurysm from distal anastomosis site to the level of the diaphragm. The patient underwent descending aortic replacement. Proximal anastomosis was directly performed at the distal end of the previously implanted J graft open stent graft. Hemostasis at the anastomosis site was uneventful and the patient was discharged from the hospital without any aneurysm-related complication.

**Keywords:** frozen elephant trunk, redo aortic repair, J graft open stent graft

## Introduction

Acute type A aortic dissection (ATAAD) is a life-threatening disease which often needs emergent surgical treatment. The primary goal is repairment of proximal aorta and closure of primary entry tear. Introduction of frozen elephant trunk (FET) simplified surgical strategy to treat distal aortic arch to descending aorta by enabling anastomosis to be performed at a more proximal site.<sup>1)</sup> FET is also useful in expanding the true lumen, thus reducing the risk of malperfusion and promoting downstream aortic remodeling.<sup>2)</sup>

Further, incidence of re-intervention is lower compared to conventional surgery.<sup>3)</sup> However, re-intervention after implantation of FET is often observed due to stent graft-induced new entry or enlargement of pseudo-lumen from the distal entry site.<sup>4)</sup>

J graft open stent graft (Japan Lifeline Inc., Tokyo, Japan) is a FET device approved in Japan in 2014 (Fig. 1). Here, we report a successful case of redo descending aortic replacement by performing proximal anastomosis directly to the distal end of previously implanted J graft open stent graft. Hemostasis at the anastomosis site was excellent and the patient was discharged from the hospital without any aneurysm-related complication.


*Department of Cardiovascular Surgery, Saitama Medical Center, Jichi Medical University, Saitama, Saitama, Japan*

Received: April 18, 2019; Accepted: May 27, 2019

Corresponding author: Daijiro Hori, MD, PhD. Department of Cardiovascular Surgery, Saitama Medical Center, Jichi Medical University, 1-847 Amanumacho, Omiya-ku, Saitama, Saitama 330-0834, Japan

Tel: +81-48-647-2111, Fax: +81-46-827-1305

E-mail: dhori07@jichi.ac.jp

 ©2019 The Editorial Committee of Annals of Vascular Diseases. This article is distributed under the terms of the Creative Commons Attribution License, which permits use, distribution, and reproduction in any medium, provided the credit of the original work, a link to the license, and indication of any change are properly given, and the original work is not used for commercial purposes. Remixed or transformed contributions must be distributed under the same license as the original.



**Fig. 1** J graft open stent graft.

## Case Report

A 64-year-old man, who underwent total arch replacement with J graft open stent graft (21 mm×60 mm) for ATAAD 2 years previously, was admitted to the hospital due to enlargement of remaining descending aorta. Computed tomography (CT) revealed aortic dissection from the distal anastomosis site to the renal artery. The diameter of the distal aortic arch was 65 mm and the descending aorta above the diaphragm was 35 mm (Fig. 2A). Adamkiewicz artery was detected at Th 10. Echocardiography showed an ejection fraction of 70% with no remarkable valvular dysfunction. He was planned for descending aortic replacement.

Cerebrospinal fluid drainage was placed 1 day before the operation. He was placed on a right lateral decubitus position. Left thoracotomy through the fourth intercostal space was performed to expose the descending aorta. However, adhesion at the previous distal anastomosis site was severe, thus complete dissection of the adhesion was not performed. The right axillary artery and right femoral artery were exposed for arterial cannulation and the right femoral vein was exposed for venous cannulation. The left ventricle vent tube was cannulated from the left atrial appendage. After initiation of cardiopulmonary bypass, body temperature was cooled down to 25°C. Under ventricular fibrillation, aortic cross clamp was performed at Th 9. Upper body circulation was stopped and the descending aortic aneurysm was opened proximally. After exposure of the previously implanted J graft open stent graft, direct cross clamp to the stent graft was performed and upper body circulation was restarted. Prosthetic graft (J Graft 24 mm, Japan Lifeline Inc., Tokyo, Japan) was anastomosed directly to the J graft open stent graft via 4-0 polypropylene running suture (Fig. 2B). Distal anastomosis was performed via open distal anastomosis just above the Adamkiewicz artery. There was no bleeding from the

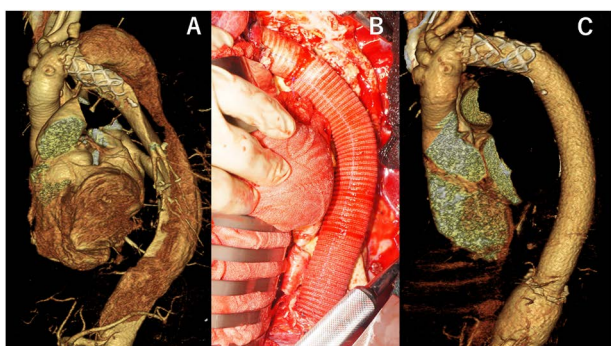
anastomosis site and clamp site.

He was extubated on postoperative day (POD) 2, but was reintubated due to pneumothorax on POD 5. The air leakage from the left chest drainage tube was continuous and he underwent thoracoscopic left lung partial resection on POD 16. Postoperative CT showed a well-repaired descending aorta without any leakage from the J graft open stent graft (Fig. 2C). He did not suffer from stroke or paraplegia after surgery. He was transmitted to another hospital for rehabilitation on POD 57, but was discharged from the hospital 2 weeks later.

## Discussion

Introduction of thoracic endovascular aortic repair (TEVAR) enabled surgeons to treat aneurysms without thoracotomy and expanded surgical indications of thoracic aneurysms to more high-risk patients. However, use of TEVAR has anatomical limitations especially with regard to landing zone. Introduction of FET prosthesis provided surgeons another option to treat patients with extended aortic disease with minimal surgical exposure. Although distal landing zone is essential, proximal landing is secured by surgical suture.

J graft open stent graft is a new device approved in Japan in 2014 and is now being used in Taiwan. It consists of polyester graft with interconnected double-layered oval-shaped nitinol stent that is conformable to the aortic curvature. The porosity of the device is 150 ml/cm<sup>2</sup>/min at 120 mmHg (Fig. 1). Mid-term outcomes of the device have been reported which were associated with good aortic remodeling.<sup>5</sup> Use of FET in acute aortic dissection results in enhanced aortic remodeling. However, existence of distal entry or stent graft-induced new entry is associated with enlargement of the pseudo-lumen and eventually to re-intervention.<sup>4</sup> FET provides sufficient proximal landing zone for secondary TEVAR, but in case of aortic dissection, distal landing zone may not be available and open surgical repair is needed. Pichlmaier et al. reported four redo aortic replacement after FET in which proximal graft was anastomosed directly to the end of stent graft together with the surrounding aortic wall.<sup>6</sup> Folkmann et al. reported nine thoracoabdominal aortic repairs after FET, in which proximal graft was anastomosed directly to the distal end of stent graft.<sup>7</sup> However, spontaneous leakage from Thoraflex (Vascutek, Inchinnan, UK) has also been reported during a second-stage repair.<sup>8</sup> The cause of leakage was undetermined, but the author concluded that missing coverage of tissue incorporation may have been associated with micropore, while clamp injury was suggested in other reports.<sup>7</sup> Despite its porosity, J graft open stent graft, which was used in our case, showed no leakage after clamp as well as from the suture line.



**Fig. 2** Preoperative computed tomography (CT) (A) and intraoperative photograph of direct anastomosis (B). Postoperative CT showed no complication at the anastomosis site (C).

## Conclusion

We report a successful case of redo descending aortic replacement by direct anastomosis to previously implanted J graft open stent graft. Direct cross-clamping and direct running suture to the J graft open stent graft was uneventful.

## Disclosure Statement

Atsushi Yamaguchi serves as a consultant to Japan Lifeline Inc. All other authors have no conflict of interest.

## Additional Note

There is no ethical problem and the patient's consent was received for this case report.

## Author Contributions

Study conception: KA, RI, SK

Data collection: KA, SK

Analysis: AY, DH

Investigation: DH, SK

Writing: DH, SK

Critical review and revision: all authors

Final approval of the article: all authors

Accountability for all aspects of the work: all authors

## References

- 1) Kato M, Kuratani T, Kaneko M, et al. The results of total arch graft implantation with open stent-graft placement for type A aortic dissection. *J Thorac Cardiovasc Surg* 2002; **124**: 531-40.
- 2) Grolitzer M, Weiss G, Meinhart J, et al. Fate of the false lumen after combined surgical and endovascular repair treating Stanford type A aortic dissections. *Ann Thorac Surg* 2010; **89**: 794-9.
- 3) Katayama A, Uchida N, Katayama K, et al. The frozen elephant trunk technique for acute type A aortic dissection: results from 15 years of experience. *Eur J Cardiothorac Surg* 2015; **47**: 355-60; discussion, 360.
- 4) Pan XD, Li B, Ma WG, et al. Endovascular repair of residual intimal tear or distal new entry after frozen elephant trunk for type A aortic dissection. *J Thorac Dis* 2017; **9**: 529-36.
- 5) Yamane Y, Uchida N, Mochizuki S, et al. Early- and mid-term aortic remodeling after the frozen elephant trunk technique for retrograde type A acute aortic dissection using the new Japanese J Graft open stent graft. *Interact Cardiovasc Thorac Surg* 2017; **25**: 720-6.
- 6) Pichlmaier MA, Teebken OE, Khaladj N, et al. Distal aortic surgery following arch replacement with a frozen elephant trunk. *Eur J Cardiothorac Surg* 2008; **34**: 600-4.
- 7) Folkmann S, Weiss G, Pizarik H, et al. Thoracoabdominal aortic aneurysm repair after frozen elephant trunk procedure. *Eur J Cardiothorac Surg* 2015; **47**: 115-9; discussion, 119.
- 8) Kreibich M, Siepe M, Beyersdorf F, et al. Spontaneous leakage of the Thoraflex™ frozen elephant trunk prosthesis. *Interact Cardiovasc Thorac Surg* 2019; **28**: 327-9.