

[ CASE REPORT ]

## Effectiveness of Plasmapheresis in a Patient with Anti-glomerular Basement Membrane Antibody Glomerulonephritis with Advanced Kidney Dysfunction

Toshiaki Usui<sup>1</sup>, Hirayasu Kai<sup>1</sup>, Kazuyuki Noguchi<sup>1</sup>, Naoki Morito<sup>1</sup>, Joichi Usui<sup>1</sup>,  
Chie Saito<sup>1</sup>, Noriko Uesugi<sup>2</sup>, Michio Nagata<sup>2</sup> and Kunihiko Yamagata<sup>1</sup>

### Abstract:

Patients with anti-glomerular basement membrane antibody glomerulonephritis (anti-GBM GN) have severe kidney dysfunction, leading to end-stage renal disease. The effect of plasmapheresis and immunosuppressive treatment in patients with severe glomerular changes is controversial. A 62-year-old man was admitted with rapidly progressive glomerulonephritis and diagnosed with anti-GBM GN. He required hemodialysis. All glomeruli in the kidney biopsy specimen had cellular crescents without fibrotic changes, suggesting reversible damage. He was treated with plasmapheresis until the anti-glomerular basement membrane antibodies disappeared. His kidney function recovered, and dialysis was able to be discontinued. Frequent plasmapheresis in patients with dialysis-dependent anti-GBM GN may improve the kidney prognosis.

**Key words:** plasmapheresis, anti-glomerular basement membrane antibody glomerulonephritis, glomerular crescents, dialysis

(Intern Med 56: 2475-2479, 2017)

(DOI: 10.2169/internalmedicine.8571-16)

### Introduction

Anti-glomerular basement membrane (anti-GBM) antibody disease, also called Goodpasture's disease, is an autoimmune-mediated disorder. Patients with anti-GBM antibody disease develop rapidly progressive glomerulonephritis (RPGN). Despite various treatments, the prognosis of anti-GBM antibody disease is poor, leading to renal failure or death (1). Once anti-GBM antibody glomerulonephritis (anti-GBM GN) patients start dialysis, they usually remain dialysis-dependent (2). Whether or not plasmapheresis in addition to immunosuppression results in a better kidney outcome in patients with advanced kidney dysfunction and extensive glomerular crescents is unclear. In particular, the effectiveness of plasmapheresis in dialysis-dependent cases is controversial. We herein report the successful treatment of a patient with anti-GBM GN who had crescents in all glomeruli on a kidney biopsy. The patient was treated with a com-

ination of dialysis, plasmapheresis and immunosuppressive treatment. Aggressive treatments, including the removal of anti-GBM antibodies by plasmapheresis with intense corticosteroid therapy, might be effective in improving the kidney prognosis of anti-GBM GN patients with no fibrotic lesions.

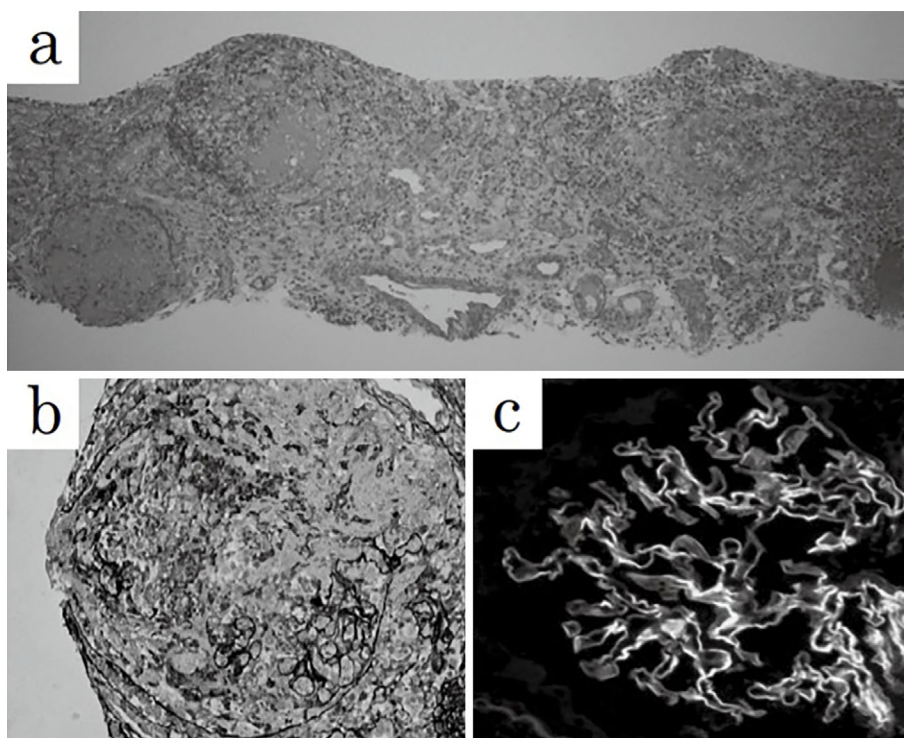
### Case Report

A 62-year-old Japanese man was admitted to our hospital with a fever and the gradual development of fatigue. He received an annual medical checkup, and he had never been told that he had kidney dysfunction. One year previously, his serum creatinine (s-Cre) had been 0.6 mg/dL, and his urinalysis findings were normal. At the present admission, his blood tests showed severe renal dysfunction [s-Cre 5.97 mg/dL, serum blood urea nitrogen (s-BUN) 50.6 mg/dL] and severe inflammation [serum C-reactive protein (s-CRP) 27.24 mg/dL]. He was positive for serum anti-GBM anti-

<sup>1</sup>Department of Nephrology, Faculty of Medicine, University of Tsukuba, Japan and <sup>2</sup>Department of Kidney and Vascular Pathology, Faculty of Medicine, University of Tsukuba, Japan

Received: November 16, 2016; Accepted: January 23, 2017; Advance Publication by J-STAGE: August 21, 2017

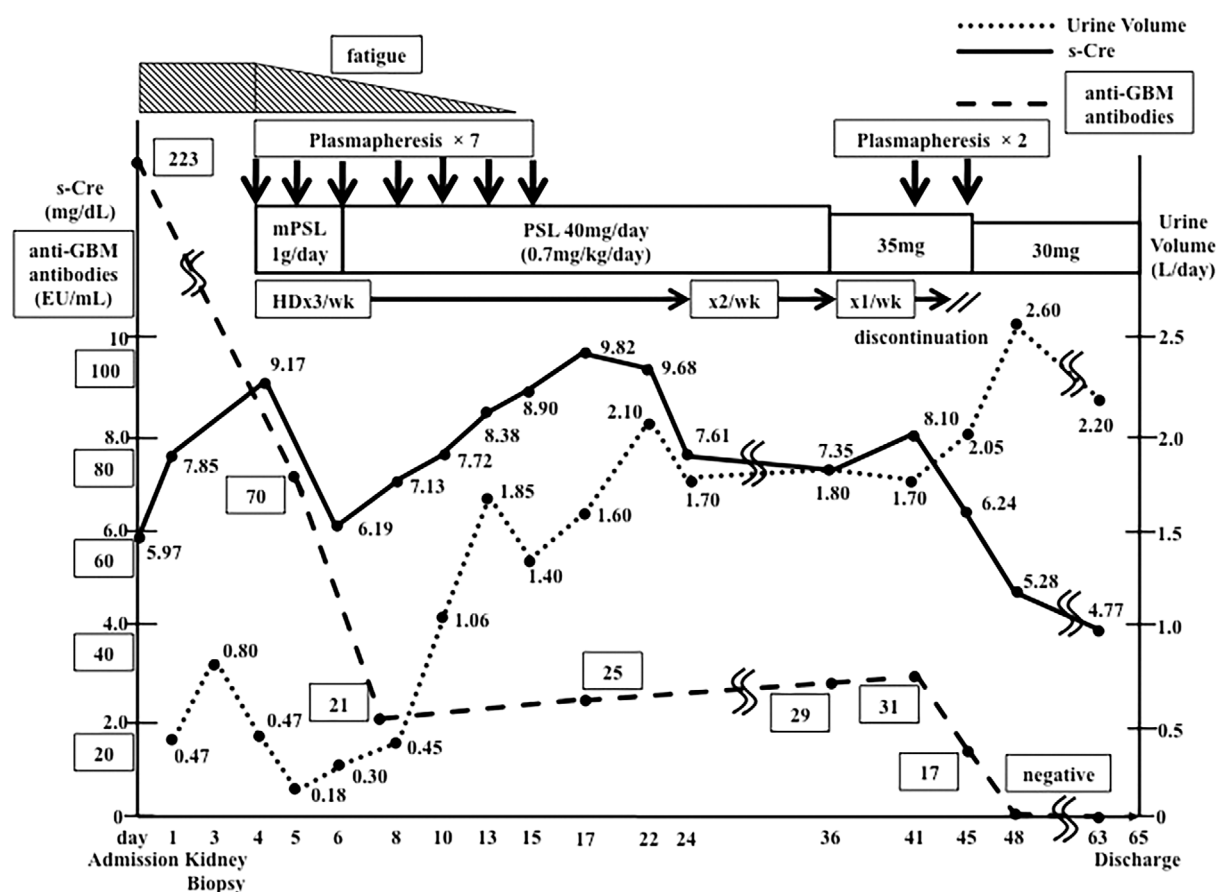
Correspondence to Dr. Kunihiko Yamagata, k-yamaga@md.tsukuba.ac.jp



**Figure 1.** Histology of the kidney biopsy specimens. (a) Periodic acid-Schiff staining, original magnification  $\times 100$ . (b) Periodic acid methenamine silver staining, original magnification  $\times 400$ . All 18 glomeruli in the kidney biopsy specimen had cellular crescents, and almost 100% of the regions of the kidney cortex interstitium had tubulitis. There were no fibrocellular or fibrotic crescents and no apparent fibrotic changes in the cortex interstitium. (c) Direct immunofluorescent IgG antibody staining, original magnification  $\times 200$ . IgG antibodies were deposited in a linear pattern along the glomerular basement membrane.

bodies (223 EU/mL) and negative for myeloperoxidase anti-neutrophil cytoplasmic antibodies (MPO-ANCA) and proteinase-3 anti-neutrophil cytoplasmic antibodies (PR3-ANCA). A urinalysis showed severe hematuria and proteinuria, urinary red blood cell casts and granular casts. His urine volume was 475 mL/day. He did not have dyspnea, and his chest plain X-ray film was normal, which indicated that he did not have typical Goodpasture's disease because of the lack of pulmonary symptoms. Findings on chest computed tomography without contrast agent were normal. Abdominal computed tomography (no contrast agent) showed mild enlargement of both kidneys. He was highly suspected of having RPGN, and a kidney biopsy was performed. All 18 glomeruli in the kidney biopsy specimen had fibrinoid necrosis, cellular crescents, rupture of the glomerular basement membrane (GBM) and Bowman's capsules, and infiltration of neutrophils. Many neutrophils and monocytes infiltrated around the glomeruli. Plasmacytes and neutrophils had infiltrated almost 100% of the regions of the kidney cortex interstitium with tubulitis; however, there were no apparent fibrotic changes in the cortex interstitium. Immunofluorescent staining showed that IgG antibodies were deposited in a linear pattern along the GBM. The pathological diagnosis was diffuse necrotizing crescentic glomerulonephritis, which is compatible with anti-GBM GN (see Fig. 1).

Plasmapheresis to remove anti-GBM antibodies from his serum was started immediately. Plasmapheresis was performed on three consecutive days, and then every other day, four times, for a total of seven times. In each plasmapheresis session, the treated volume was 1.2 plasma volume, and the replacement fluid consisted of 1,000 mL of 5% albumin plus 2,700 mL of fresh-frozen plasma (FFP). We replaced his removed plasma first with albumin and then with FFP. In addition to plasmapheresis, he was treated with intensive corticosteroids therapy, including methylprednisolone (mPSL) pulse therapy (1 g/day continuously for 3 days) and oral prednisolone, 40 mg/day, to inhibit the production of anti-GBM antibodies and reduce kidney inflammation. Oliguria worsened, and the s-Cre increased to 9.17 mg/dL. Therefore, he was started on hemodialysis therapy three times per week, simultaneously. Due to these therapies, including the seven plasmapheresis therapy sessions, his fever improved, and the levels of inflammation markers decreased. His urine volume increased, and his renal function gradually improved. After undergoing hemodialysis for 41 days, he finally discontinued it. However, the levels of anti-GBM antibodies increased, and his kidney function worsened again. Therefore, we performed two more sessions of plasmapheresis therapy. Each plasmapheresis session consisted of 0.93 plasma volume, with the replacement fluid consisting of 1,000 mL of 5% albumin plus 1,800 mL of FFP. After a to-



**Figure 2.** Clinical course of the patient. This figure shows the clinical course of the patient after admission. The time course of the clinical symptoms, urine volume, s-Cre, the titer of anti-GBM antibodies, the doses of methylprednisolone and prednisolone, and the timing of hemodialysis and plasmapheresis are shown. GBM: glomerular basement membrane, HD: hemodialysis, mPSL: methylprednisolone, PSL: prednisolone, s-Cre: serum creatinine

tal of nine plasmapheresis therapy sessions, the anti-GBM antibodies became undetectable, and his kidney function improved. He was discharged from the hospital on the 65th day (see Fig. 2).

After discharge, his kidney function continued to gradually improve. His hematuria disappeared, and his anti-GBM antibodies remained negative. The prednisolone dose was tapered to 2.5 mg/day without using immunosuppressive drugs.

However, seven months after being discharged, he developed a continuous mild fever, and his kidney function worsened. Hematuria and deformed erythrocytes and granular casts appeared again in his urine, and anti-GBM antibodies became positive. He had a relapse of anti-GBM GN with RPGN. He was immediately admitted to our hospital again, and plasmapheresis was started. His prednisolone dose was increased to 40 mg/day. After five plasmapheresis therapy sessions, the anti-GBM antibodies became negative again, and his hematuria disappeared. His s-Cre levels gradually decreased. He was started on azathioprine 50 mg/day as maintenance therapy and discharged from the hospital.

We have since continued maintenance treatments of azathioprine and prednisolone with gradual tapering. His

anti-GBM antibody levels have remained negative. He has not had another relapse to date, and he visits the outpatient clinic regularly. His s-Cre is 3.0 mg/dL. He has not developed end-stage renal disease.

## Discussion

We noted three important clinical issues with this case. First, a kidney biopsy should be performed in anti-GBM GN patients with RPGN, even if the patients have advanced kidney dysfunction and are dialysis-dependent. Second, it is important to check the quality of the glomerular crescents in the kidney biopsy specimens, even if all glomeruli have crescentic changes. The formation of cellular crescents may be reversed by immunosuppressive therapies and plasmapheresis. Third, immunosuppressive drugs along with prednisolone should be administered as maintenance therapy against anti-GBM GN to prevent relapse.

Goodpasture's disease patients with pulmonary hemorrhaging as well as anti-GBM GN should receive aggressive treatments to improve reduce their risk of mortality, regardless of the kidney prognosis (3). However, patients who are dialysis-dependent at the start of treatment and have 85-

100% glomerular crescents in an adequate biopsy sample do not recover their kidney function and generally will require long-term renal replacement therapy (4). Several studies have reported that the predictors of the kidney survival in anti-GBM GN patients were s-Cre at presentation, the need for dialysis at presentation, and the percentage of glomerular crescents (2, 4-7). Patients who required dialysis at presentation and who had 100% crescents on kidney biopsy never recovered their kidney function and were not able to discontinue dialysis (2). In another study, all patients with an initial s-Cre >5.7 mg/dL and 100% crescents on a kidney biopsy became chronically dialysis-dependent despite aggressive treatments (4). Despite intense immunosuppressive therapies, these patients did not recover their kidney function and generally went on to require long-term renal replacement therapies (4). In the kidney biopsy specimen of our patient, all glomeruli had cellular crescents, and plasma-cytes and neutrophils had infiltrated almost 100% of the regions of the kidney cortex interstitium with tubulitis; however, there were no apparent fibrotic changes in the cortex interstitium and no fibrocellular or fibrous crescents in his glomeruli. This suggested that his renal damage was reversible and that he could be weaned from hemodialysis after aggressive therapies, including plasmapheresis, to remove anti-GBM antibodies quickly.

In Japan, Kitaura and Asano reported a patient with anti-GBM GN who was able to discontinue hemodialysis after combination therapy with steroids and plasmapheresis (8). However, in that patient, the glomerular crescent rate was about 50%, and our patient might have had more severe glomerular damage. Cui et al. reported that, among anti-GBM GN patients whose initial s-Cre was >6.8 mg/mL, combination therapy with plasmapheresis and immunosuppressive therapies was more effective (hazard ratio for renal failure, 0.52; 95% confidence interval, 0.30-0.88;  $p=0.014$ ) than immunosuppressive therapy alone for the renal prognosis in a single-center cohort study (9). Flores et al. reported that, among eight anti-GBM GN patients with oliguria or anuria without lung hemorrhaging who were not treated with plasmapheresis, none recovered their renal function (10). The findings from the present case suggests that even if kidney dysfunction is advanced, aggressive therapies, including plasmapheresis, may improve the renal prognosis in cases where the renal histological damages observed on a kidney biopsy are reversible. Namely, the presence of numerous fibrous crescentic formations might be difficult to ameliorate, but fresh crescentic changes, even if the crescentic formation rate in the glomerulus is high, may be reversible with multidisciplinary treatment.

When plasmapheresis therapy for anti-GBM GN should be started remains unclear. The early diagnosis and early initiation of treatment are necessary to prevent the development of irreversible renal dysfunction. If a diagnosis of anti-GBM GN is highly suspected, beginning treatment with high-dose corticosteroids and plasmapheresis before receiving the confirmatory diagnosis seems appropriate (4). In

such situations, we are able to examine the presence of anti-GBM antibodies via enzyme-linked immunosorbent assay (ELISA) as soon as possible. Plasmapheresis can remove pathogenic antibodies from the circulation efficiently and rapidly, thereby preventing renal damage.

The American Society for Apheresis Journal of Clinical Apheresis Special Issue Writing Committee recently published guidelines for therapeutic apheresis. These guidelines suggest that plasmapheresis be performed daily or every other day, and the minimum course of plasmapheresis should be 10-20 days (11). However, there are as yet no standard protocols of plasmapheresis for the treatment of anti-GBM GN, and the efficacy of plasmapheresis for treating advanced kidney dysfunction is not yet clear. The titers of anti-GBM antibodies should be regularly monitored, as they reflects the progression of anti-GBM GN (4). In our patient, plasmapheresis was performed while periodically checking the serum anti-GBM antibody levels until the circulating antibodies were no longer detectable. We administered plasmapheresis therapy seven times; plasmapheresis was administered on three consecutive days, and then every other day, four times, to remove the anti-GBM antibodies as soon as possible. When the level of anti-GBM antibodies increased and the patient developed severe kidney dysfunction again, we administered two additional sessions of plasmapheresis. We performed plasmapheresis a total of nine times in the present patient. The American Society for Apheresis guidelines suggest that the presence or absence of antibodies should not be considered in the decision to terminate therapy; however, they also recommend that plasmapheresis therapy be continued until the resolution of the ongoing glomerular injury (11). In the present case, the level of anti-GBM antibodies increased, and he redeveloped severe kidney dysfunction. Because we judged the glomerular injury to be ongoing, we administered two additional sessions of plasmapheresis. This treatment method might have improved the patient's renal prognosis.

Immunosuppressive drugs along with prednisolone should be administered as maintenance therapy against anti-GBM GN to prevent relapse. In contrast to most other autoimmune kidney diseases, anti-GBM GN is not characterized by a frequently relapsing course (4). However, recurrence may occur, with a reported frequency of 13.9% (1). There is very little information available on maintenance therapies against anti-GBM GN. Levy et al. reported that, in patients who were on maintenance therapy of low-dose steroid for six to nine months and in some cases with a combination of azathioprine therapy, the renal survival rate did not worsen after one year (2). In our case, the patient was treated with only prednisolone for the first maintenance treatment, and he experienced a relapse of anti-GBM GN after remission was induced. After re-inducing remission, we added the immunosuppressive drug azathioprine to his regimen, and he has not relapsed since then, suggesting that immunosuppressive drugs are effective in maintenance treatment regimens against anti-GBM GN.

In conclusion, anti-GBM GN patients should undergo a kidney biopsy if they have RPGN with advanced kidney dysfunction and are dialysis-dependent. All glomeruli will have crescentic changes, but it is important to check the quality of the glomerular crescents on a histological examination of biopsy specimens. Immunosuppressive therapies and plasmapheresis may reverse the crescentic changes. If the kidney function improves, immunosuppressive drugs along with prednisolone should be administered as maintenance therapy against anti-GBM GN to prevent a relapse. Further case reports should be accumulated to determine the most effective treatments for anti-GBM GN to improve the renal prognosis.

**The authors state that they have no Conflict of Interest (COI).**

### Financial Support

This case report was supported in part by a Grant-in-Aid for Research on Advanced Chronic Kidney Disease (REACH-J), Practical Research Project for Renal Diseases from the Japan Agency for Medical Research and Development, AMED. In addition, this work was supported in part by a Grant-in-Aid for Intractable Renal Diseases Research, Research on rare and intractable diseases, Health and Labour Sciences Research Grants from the Ministry of Health, Labour and Welfare of Japan.

### References

- Hirayama K, Yamagata K, Kobayashi M, Koyama A. Anti-glomerular basement membrane antibody disease in Japan: part of the nationwide rapidly progressive glomerulonephritis survey in Japan. *Clin Exp Nephrol* **12**: 339-347, 2008.
- Levy JB, Turner AN, Rees AJ, Pusey CD. Long-term outcome of anti-glomerular basement membrane antibody disease treated with plasma exchange and immunosuppression. *Ann Intern Med* **134**: 1033-1042, 2001.
- Proskey AJ, Weatherbee L, Easterling RE, Greene JAJ, Weller JM. Goodpasture's syndrome. A report of five cases and review of the literature. *Am J Med* **48**: 162-173, 1970.
- Chapter 14: Anti-glomerular basement membrane antibody glomerulonephritis. *Kidney Int Suppl* **2**: 240-242, 2012.
- Johnson JP, Moore JJ, Austin HA 3rd, Balow JE, Antonovych TT, Wilson CB. Therapy of anti-glomerular basement membrane antibody disease: analysis of prognostic significance of clinical, pathologic and treatment factors. *Medicine (Baltimore)* **64**: 219-227, 1985.
- Cui Z, Zhao M, Xin G, Wang H. Characteristics and prognosis of Chinese patients with anti-glomerular basement membrane disease. *Nephron Clin Pract* **99**: c49-c55, 2005.
- Levy JB, Hammad T, Coulthart A, Dougan T, Pusey CD. Clinical features and outcome of patients with both ANCA and anti-GBM antibodies. *Kidney Int* **66**: 1535-1540, 2004.
- Kitaura K, Asano K. [A case of anti-GBM-antibody positive rapidly progressive glomerulonephritis who was weaned from hemodialysis after combination therapy with steroid and plasmapheresis]. *Nihon Jinzo Gakkai Shi (Jpn J Nephrol)* **47**: 887-892, 2005 (in Japanese, Abstract in English).
- Cui Z, Zhao J, Jia X, et al. Anti-glomerular basement membrane disease: outcomes of different therapeutic regimens in a large single-center Chinese cohort study. *Medicine (Baltimore)* **90**: 303-311, 2011.
- Flores JC, Taube D, Savage CO, et al. Clinical and immunological evolution of oligoanuric anti-GBM nephritis treated by haemodialysis. *Lancet (London, England)* **1**: 5-8, 1986.
- Schwartz J, Padmanabhan A, Aqui N, et al. Guidelines on the Use of Therapeutic Apheresis in Clinical Practice - Evidence-Based Approach from the Writing Committee of the American Society for Apheresis: The Seventh Special Issue. *J Clin Apher* **31**: 149-338, 2016.

The Internal Medicine is an Open Access article distributed under the Creative Commons Attribution-NonCommercial-NoDerivatives 4.0 International License. To view the details of this license, please visit (<https://creativecommons.org/licenses/by-nc-nd/4.0/>).