

A Case of Severe Biliary Anastomotic Stricture after Living Donor Liver Transplantation Successfully Treated Using the Modified Gunsight Technique with Two Balloon Catheters

1) Department of Radiology, Tokyo Saiseikai Central Hospital, Tokyo, Japan

2) Department of Radiology, Keio University School of Medicine, Tokyo, Japan

3) Department of Diagnostic Radiology, KKR-Tachikawa Hospital, Tokyo, Japan

4) Department of Pediatric Surgery, Keio University School of Medicine, Tokyo, Japan

Sayuri Iwasawa¹⁾, Masashi Tamura²⁾, Teppei Okamura³⁾, Hideyuki Torikai²⁾, Nobutake Ito¹⁾, Masanori Inoue²⁾, Yohei Yamada⁴⁾, Masahiro Jinzaki²⁾, Tatsuo Kuroda⁴⁾, Seishi Nakatsuka²⁾

Abstract

Biliary stricture is a serious postoperative complication of liver transplantation. We report the case of a 2-year-old boy with severe biliary anastomotic stricture after left lobe living donor liver transplantation. As cannulation from the occluded B3 into the jejunum was impossible using the conventional technique, a gunsight approach was utilized. By puncturing balloons dilated at the occluded site of B3 and the proximal end of the non-occlusive B2, a tract between B3 and B2 was created, and the catheter was finally successfully inserted from B3 into the jejunum through the dilated tract and B2. The gunsight approach is an option for severe biliary strictures when the conventional approach proves impossible.

Key words: liver transplantation, biliary stricture, gunsight approach

(Interventional Radiology 2021; 6: 65-68)

Introduction

Biliary stricture occurs in 5-25% of pediatric living donor liver transplants[1]. The main cause of biliary stricture is graft ischemia; in such cases, multiple branches are affected. Isolated biliary strictures, on the other hand, normally occur at an anastomotic site and tend to occur after choledochojejunostomy rather than bile duct-to-bile duct anastomosis [1]. Treatment is usually performed endoscopically or percutaneously but if the stricture is at an acute or skew angle or if occlusion is complete, canalization becomes difficult and re-anastomosis may be necessary to avoid graft loss [1]. The use of microcatheters and the rendezvous technique for penetration in difficult cases has been reported [2]. We report successful cannulation of an anastomotic stricture after liver transplantation using the gunsight approach.

Case Report

The patient was diagnosed with biliary atresia at the age of 1 month. Hepatopertoenterostomy was performed, but the patient's jaundice did not adequately resolve, and the patient underwent living-donor liver transplantation comprising a left lateral segment graft and choledochojejunostomy at 10 months of age. One year later, hepatobiliary enzyme levels were elevated in blood tests (aspartate aminotransferase, 53 IU/L; alanine aminotransferase, 42 IU/L; lactate dehydrogenase, 337 IU/L; alkaline phosphatase, 1557 IU/L; and γ -glutamyl transpeptidase, 105 IU/L) although the values of total bilirubin and direct bilirubin were normal (total bilirubin, 0.7 mg/dL; direct bilirubin, 0.1 mg/dL). As computed tomography (CT) suggested anastomotic biliary stricture, he was referred to our department for percutaneous transhepatic

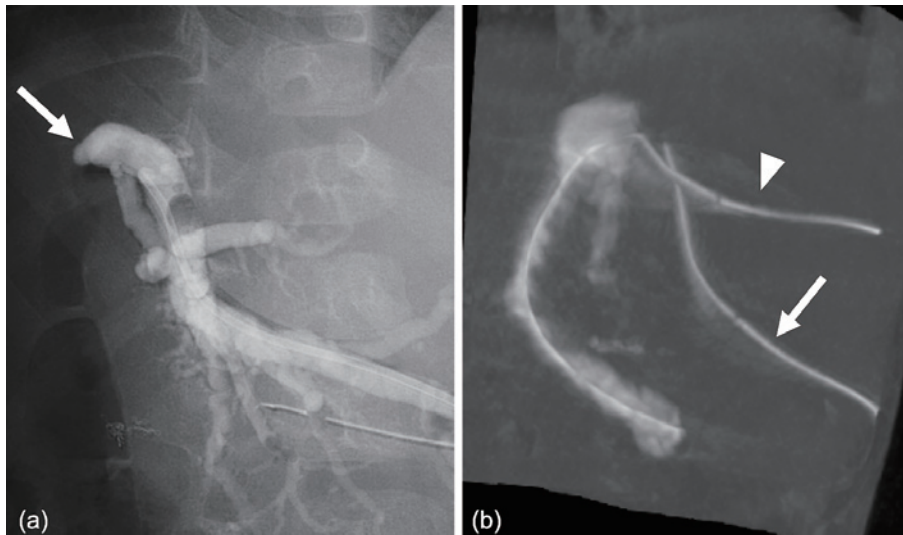


Figure 1. a) Cholangiogram shows the occluded bile duct anastomosis of B3 (arrow). b) Cone-beam CT after PTBD from B2 reveals a skew position between the catheters in B3 (arrow) and B2 (arrowhead).

biliary drainage (PTBD). The dilated left lateral anterior segmental bile duct (B3) was punctured using a 22-G Chiba needle (Hanako, Japan) under ultrasound (US) guidance, and a 4-Fr sheath dilator (Hanako, Japan) was placed. Contrast medium injection revealed that the origin of B3 was occluded (**Figure 1a**). Attempts to penetrate the occluded site with a 4-Fr hooked catheter (Medikit, Japan)/0.035-inch guidewire (Radifocus, Terumo, Japan) and a microcatheter were unsuccessful, and a 7-Fr catheter (Hanako, Japan) was temporarily placed. Liver dysfunction subsequently improved. One week later, the 2nd intervention was performed with the aim of inserting an internal-external drainage catheter. Cholangiography from the B3 catheter demonstrated faint visualization of the jejunum due to severe stricture of origin of B3. The standard antegrade approach to cross the stenosis again proved unsuccessful. Next, we performed PTBD of the non-dilated left lateral posterior segmental bile duct (B2) with a 22-G Chiba needle (Hanako, Japan) under US guidance and concluded the procedure with placement of a 7-Fr pigtail catheter (Hanako, Japan) from B2 to the jejunal limb for the preparation of the rendezvous approach [2] in the next intervention. The 3rd intervention was conducted 2 months later. A 6-Fr sheath (Medikit, Japan) was inserted into B3 and a 5-Fr sheath (Medikit, Japan) into B2. Initially, we attempted to perform a rendezvous approach, but penetration using a rendezvous technique was considered difficult because of the skew positions of B3 and B2 (**Figure 1b**, Supplementary Video) and the severity of the stricture. Therefore, we decided to use the gunsight approach [3]. Two 5.2-Fr balloon catheters (Selecon Balloon Catheter, Terumo, Japan) were placed and dilated at the end of the occluded site in B3 and at the proximal end of the non-occluded B2 (**Figure 2a**). Preoperative CT confirmed no vessels between the two balloons, and the angles of fluoroscopy were adjusted so that the two balloons appeared to

overlap on the fluoroscopic image (**Figure 2b**). From this bull's eye view, a 22-G needle (Hanako, Japan) was inserted percutaneously and transhepatically to sequentially puncture the balloons in B3 and B2. Collapse of both balloons was confirmed (**Figure 2c**); as soon as the B2 balloon had collapsed, a 0.018-inch stainless steel guidewire (Hanako, Japan) was inserted and advanced to the jejunal limb (**Figure 2d**). The tract formed between B3 and B2 was dilated using a 4-Fr sheath dilator (Hanako, Japan). A wire was then inserted from B3 along the tract to the jejunal limb. Finally, a tube was inserted from the B3 side into the jejunal limb to complete the internal-external drainage pathway (**Figure 2e**). No obvious postoperative complications were observed. Balloon dilation and tube replacement at the biliary anastomosis site were subsequently repeated, and as of the time of writing, 5 years after the procedure, the tube remained subcutaneously implanted and maintained through the anastomosis, and the patient remains under observation with no signs of graft loss.

Discussion

The gunsight approach was first reported by Haskal *et al.* for use in percutaneous portosystemic shunt formation [3]. In this technique for creating a connection between two luminal structures, fluoroscopy is rotated to identify a cross section in which the two snares overlap, and both snares are penetrated. This method has also been reported for revascularization of an occluded popliteal artery [4] and percutaneous left internal jugular vein-to-thoracic duct bypass to resolve a blocked lymphatic duct [5].

In the present case, the end of the occluded site in B3 was adjacent to B2, but severe post-transplant stricture prevented canalization using conventional methods. Alternative methods using a microcatheter set or rendezvous technique

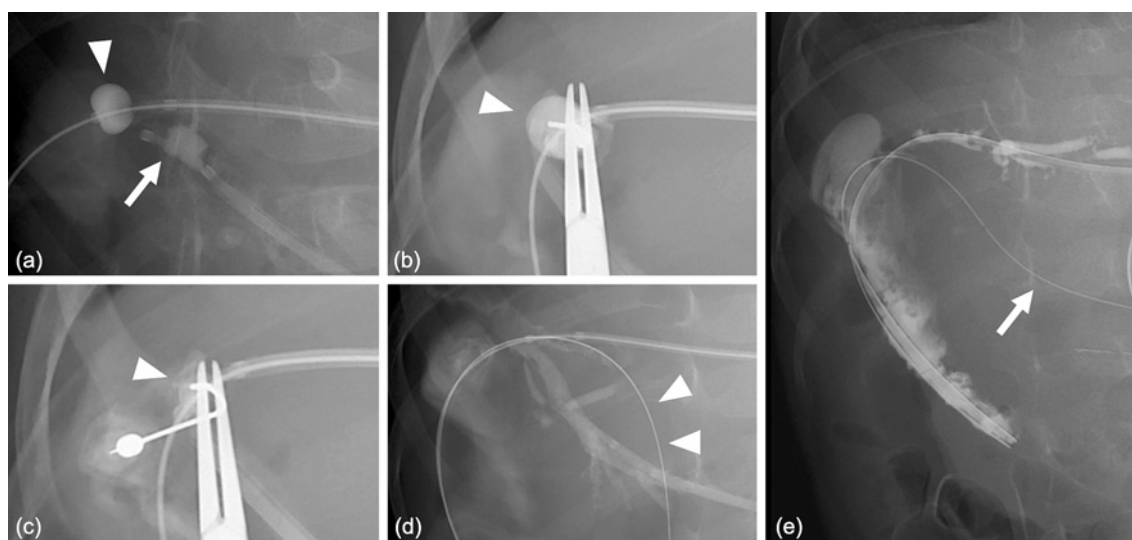


Figure 2. a) Balloon catheters are respectively dilated at the occluded site of B3 (arrow) and the proximal end of B2 (arrowhead). b-e) From the bull's eye view, balloons in B3 and B2 are sequentially punctured using a 22-G Chiba needle (b, arrowhead). Just after the rupture of the balloon in B2 (c, arrowhead), the guide wire (d, arrowhead) is inserted through the needle into the jejunum and the tract between B3 and B2 was dilated using a 5-Fr vascular sheath. Finally, the catheter (e, arrow) is successfully inserted from B3 into the jejunum through the dilated tract.

should be considered in such difficult cases [2], both of which proved unsuccessful in the present case. Direct needle puncture [6] should also be considered, but the skew relationship between B3 and B2 also made it difficult to directly puncture the lumen of B2 from a sheath placed in B3. Other recanalization techniques, such as radiofrequency puncture wires, yttrium aluminum garnet lasers, and compressing magnets, have been reported, all of which are off-label and not easy to apply [7-9]. The gunsight approach may be helpful for creating communication between two luminae that lie at acute angles to each other and have robust intervening structures.

The original method used snares, but we used balloon catheters to ensure that the bile duct lumen was dilated. Although we were unable to draw the catheter from B3 into the B2 side with a snare as in the original method, we successfully passed the catheter through from B3 to the B2 side using sheath dilation to create a passage between the two. Opening the snare in the intrahepatic duct may be difficult due to its collapse, and this revised method should be considered when using the gunsight approach for small-diameter structures.

The gunsight approach is a technique for catheter penetration by puncturing a site that is not itself a lumen, and thus entails the possibility of puncture-related complications. In this case, CT before the third intervention confirmed the absence of any intervening vascular structures such as the artery and portal vein between the end of the occluded site in B3 and B2, and no structures that should be avoided were apparent along the percutaneous transhepatic pathway to the end of the occluded site in B3. Therefore, we considered that the puncture could be conducted safely, and the proce-

cedure was performed without complications. For any puncture, investigating the safety of the puncture path on preoperative imaging is crucial.

To prevent graft loss and reoperation, proper management of the tube for the treatment of biliary stricture after living donor liver transplantation is important. Regarding the current management of the tube placed using the gunsight approach, the tube remains in place even 5 years after the procedure. The decision to maintain the tube reflects our and the family's reluctance, given the possible requirement for further invasive procedures in a 7-year-old child. As frequent and repeated balloon dilatation may be necessary to safely achieve tube-independent status [10, 11], such trials will be offered when the patient is older and does not require general anesthesia for each procedure.

Conclusions

The gunsight approach appears to be useful for crossing severe biliary strictures and should be considered when conventional approaches are unsuccessful.

Acknowledgement: None

Conflict of interest: The authors declare no conflicts of interest associated with this manuscript.

Disclaimer: Masanori Inoue is one of the Editorial Board members of *Interventional Radiology*. This author was not involved in the peer-review or decision-making process for this paper.

References

1. Kelly DA, Bucuvalas JC, Alonso EM, Karpen SJ, Allen U, Green M, et al. Long-term medical management of the pediatric patient after liver transplantation: 2013 practice guideline by the American Association for the Study of Liver Diseases and the American Society of Transplantation. *Liver Transpl* 2013; 19: 798-825.
2. Yoon HM, Kim JH, Ko GY, Song HY, Gwon DI, Sung KB. Alternative techniques for cannulation of biliary strictures resistant to the 0.035" system following living donor liver transplantation. *Korean J Radiol* 2012; 13: 189-194.
3. Haskal ZJ, Duszak R Jr, Furth EE. Transjugular intrahepatic trans-caval portosystemic shunt: the gun-sight approach. *J Vasc Interv Radiol* 1996; 7: 139-142.
4. Kahn SL, Kaufman JL. Extravascular revascularization of a chronic total occlusion using the dual bull's eye technique. *J Endovasc Ther* 2016; 23: 903-906.
5. Bundy JJ, Shin DS, Chick JFB, Monsky WL, Jones ST, List J, et al. Percutaneous extra-anatomic lymphovenous bypass creation: toward treatment of central conducting lymphatic obstructions. *Cardiovasc Interv Radiol* 2020; 43: 1392-1397.
6. Horinouchi H, Ueshima E, Sofue K, Komatsu S, Okada T, Yamaguchi M, et al. Extraluminal recanalization for postoperative biliary obstruction using transseptal needle. *Surg Case Rep* 2020; 6: 304.
7. Guimaraes M, Uflacker A, Schönholz C, Uflacker R. Successful recanalization of bile duct occlusion with a radiofrequency puncture wire technique. *J Vasc Interv Radiol* 2010; 21: 289-294.
8. Endo M, Hashimoto M, Ohuchi Y, Ogawa T, Iwamoto A, Noguchi N. Percutaneous transhepatic holmium:YAG Laser choledochojunostomy for the recanalization of obstructed surgical anastomosis. *J Vasc Interv Radiol* 2017; 28: 310-312.
9. Oya H, Sato Y, Yamanouchi E, Yamamoto S, Hara Y, Kokai H, et al. Magnetic compression anastomosis for bile duct stenosis after donor left hepatectomy: a case report. *Transplant Proc* 2012; 44: 806-809.
10. Ko GY, Sung KB, Yoon HK, Kim KR, Gwon DI, Lee SG. Percutaneous transhepatic treatment of hepaticojejunal anastomotic biliary strictures after living donor liver transplantation. *Liver Transpl* 2008; 14: 1323-1332.
11. Lin AN, Ou HY, Huang TL, Tsang LC, Chen CL, Cheng YF. Management of biliary stricture in pediatric living donor liver transplantation recipients. *Transplant Proc* 2020; 52: 1844-1848.

Interventional Radiology is an Open Access journal distributed under the Creative Commons Attribution-NonCommercial 4.0 International License. To view the details of this license, please visit (<https://creativecommons.org/licenses/by-nc/4.0/>).