

Successful leadless pacemaker deployment in a patient with challenging right heart anatomy using a double snare technique



Daniel Alyesh, MD, Ryan Cunnane, MD

From the Section of Electrophysiology, Division of Cardiovascular Medicine, University of Michigan Health System, Ann Arbor, Michigan.

Introduction

The Micra Transcatheter Pacing System (Micra TPS, Medtronic, Minneapolis, MN) has proven to be safe and effective in appropriately selected patients.¹ Its compact design and femoral-based deployment technology promote patient comfort and minimize permanently implanted hardware. The unidirectional deflectable delivery catheter design is flexible and allows for facile placement of the pacing capsule on the interventricular septum, at locations between the base of the right ventricular (RV) outflow tract and the apex, in patients with varying RV anatomy. However, little is known about how best to place a leadless pacemaker in cases where challenging anatomy, such as severe right atrial and RV dilation, make optimal deployment difficult owing to insufficient catheter reach. We present a case of successful Micra TPS deployment in a patient with severe right heart enlargement.

Case report

An 86-year-old man with a past medical history significant for rheumatic fever as a child, mitral valve repair (1998), persistent atrial fibrillation with slow ventricular response, and intermittent junctional escape with a rate in the 40s (complicated by acute kidney injury requiring transient dialysis) was referred to our institution for leadless pacemaker implantation. One month prior, he underwent an attempt at traditional transvenous device insertion at an outside institution, which ultimately failed owing to significant tricuspid valve regurgitation and an enlarged right heart (Figure 1). The case was abandoned after numerous attempts at standard

KEYWORDS Gooseneck snare; Intracardiac snare; Leadless pacemaker; Micra Transcatheter Pacing System; Micra TPS; Right heart enlargement; Rheumatic heart disease; Transvenous pacemaker (Heart Rhythm Case Reports 2019;5:399–401)

Dr Cunnane has received consulting support and honoraria from Medtronic, Boston Scientific, Phillips, and Biotronik. Dr Alyesh reports no relevant conflicts of interest. **Address reprint requests and correspondence:** Dr Ryan Cunnane, Section of Electrophysiology, Division of Cardiovascular Medicine, University of Michigan Health System, 1500 East Medical Center Dr, Ann Arbor, MI 48109. E-mail address: rcunnane@med.umich.edu.

KEY TEACHING POINTS

- Very large right heart anatomy may make it difficult to successfully deploy a leadless pacemaker using the standard delivery system.
- Gooseneck snares placed over the delivery system and through the sheath is a safe and effective method of improving the reach of the delivery system in enlarged right heart anatomy.
- Leadless pacemakers may be an effective alternative to traditional endovascular devices when anatomy is not suitable for traditional device placement.

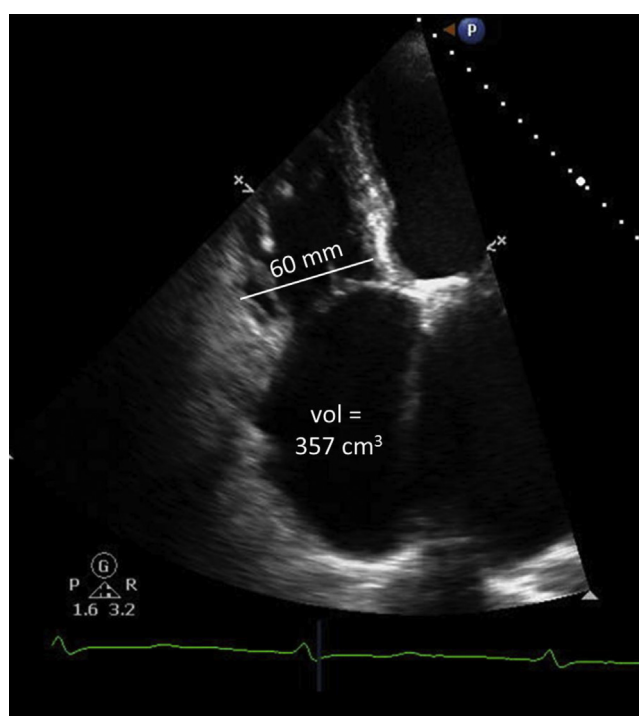


Figure 1 Apical transthoracic echocardiography imaging demonstrating right heart enlargement.




Figure 2 Mock-ups illustrating the gooseneck snare procedure: **A:** 2 gooseneck snares are deployed onto the shaft of the Micra delivery system (Medtronic, Minneapolis, MN) prior to insertion; **B:** insertion into the delivery sheath preloaded; **C:** the proximal aspect of the snares remain accessible for adjustment and traction; **D:** snares exit the introducer sheath along with the delivery catheter and pacing capsule.

lead placement resulted in unacceptable electrical parameters and poor stability despite using the longest leads available and long support sheaths and making an effort to pace the left ventricle via the coronary sinus.

The patient was brought to the electrophysiology lab at our center, prepped, and draped in the usual sterile manner for Micra TPS placement. Right femoral venous access was then obtained under ultrasound guidance and the introducer sheath was advanced to the level of the right atrium. The Micra TPS delivery catheter was deflected across the tricuspid valve and advanced into the right ventricle without difficulty. Multiple attempts at positioning the device failed to find a suitable deployment site on the interventricular septum

owing to poor stability. As contact pressure was increased at the tip of the delivery catheter, it had the tendency to slide toward the RV apex. Unfortunately, owing to insufficient reach of the delivery catheter, adequate contact with the myocardium at the apex was also a problem. Deployment was not undertaken owing to either poor contact or sensing parameters in multiple locations within the right ventricle.

In an attempt to improve the reach of the Micra TPS delivery catheter, manual traction at points along the delivery catheter was attempted using external snare equipment. Initially, a single 15 mm Amplatz Goose Neck snare (Medtronic, Minneapolis, MN) was positioned on the shaft of the delivery catheter proximal to the pacing capsule while

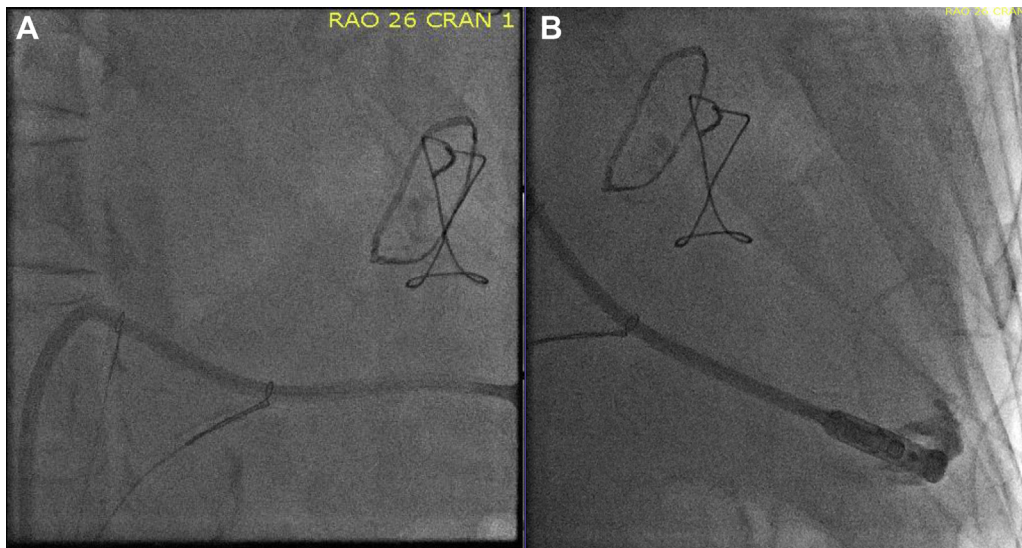

Figure 3 Fluoroscopic right anterior oblique images of the Micra delivery catheter (Medtronic, Minneapolis, MN) and snare apparatus in the heart. **A:** Traction on the snares alters the shape of the delivery catheter, allowing for a longer reach. **B:** Contrast injection demonstrating apical septal positioning of the device.

the catheter was outside of the body. This system was then inserted through the introducer sheath and manipulated into the right ventricle. Traction on the snare improved the reach of the delivery system by providing an additional point of contact beyond the superior aspect of the tricuspid valve, but adequate myocardial interaction was still not possible. The gooseneck snare was removed and right-sided venous access was then obtained. A Needle's Eye snare (Cook Medical, Bloomington, IN) was then advanced into the right atrium, but capture of the delivery catheter shaft proved difficult and, when successful, did not provide sufficient improvements in device contact with the myocardium. Eventually, 2 gooseneck snares (10 mm and 15 mm) were affixed to the shaft of the delivery catheter at approximately 5 cm and 10 cm proximal to the pacing capsule. This assembly was then inserted into the introducer sheath from the right groin and positioned in the right ventricle (Figure 2). The first snare was positioned on the delivery catheter approximately at the level of the tricuspid valve. Typically, the superior tricuspid annulus serves as a contact point for the system that allows for longitudinal force delivered at the handle to be transmitted to the tip after the approximately 90-degree turn in the right atrium. Because of the marked dilation of the tricuspid valve, the first snare effectively replaced this critical contact point. The second, more distal snare was used to help pull the shaft of the delivery catheter down toward the apex at the tip. Tension on both snares allowed for more precise positioning of the delivery catheter and for force applied at the handle to be transmitted toward the RV apex rather than superiorly into the right atrium and superior vena cava (Figure 3A). Ultimately, adequate contact with the septal myocardium was achieved with clockwise torque on the entire assembly and the device was successfully deployed at the RV apex (Figure 3B). Tug testing was performed to confirm seating of 3 times, and capture threshold, sensing, and impedance measurements were within the normal limits.

Discussion

Leadless cardiac pacing is an attractive alternative to traditional transvenous systems and represents a major leap forward in cardiac implantable electronic device technology. Safety has been well described, but questions still remain with regard to how best to manage complex anatomy and life-cycle issues such as infection, battery depletion, and long-term use in younger patients.

While there has been a report of successful implantation of leadless pacemaker technology in challenging congenital anatomy, to our knowledge this case is the first successful Micra TPS deployment in challenging right heart anatomy, where external snares provided critical added reach.² The loop snare-on-catheter shaft technique we employed is easily reproducible and could be safely and successfully replicated at other centers with readily available equipment. This case highlights some of the limitations in the current iteration of Micra TPS deployment technology and demonstrates the possible need for additional curves with extended reach for varying patient anatomies.

Conclusion

The reach of the Micra TPS delivery catheter can be improved by preloading loop snares onto the shaft of the catheter proximal to the pacing capsule. This can aid in successful deployment in the setting of challenging right heart enlargement.

References

1. Reynolds D, Duray GZ, Omar R, et al. A leadless intracardiac transcatheter pacing system. *N Engl J Med* 2016;374:533–541.
2. Ferrero P, Yeong M, D'Elia E, Duncan E, Graham Stuart A. Leadless pacemaker implantation in a patient with complex congenital heart disease and limited vascular access. *Indian Pacing Electrophysiol J* 2016;16:201–204.