


# A conundrum of West syndrome, behavioural problems and parental expressed emotions: a case report

Yogender Kumar Malik ,<sup>1</sup> Nidhi Chauhan,<sup>2</sup> Akhilesh Sharma,<sup>3</sup> Susanta Padhy<sup>4</sup>

**To cite:** Malik YK, Chauhan N, Sharma A, *et al.* A conundrum of West syndrome, behavioural problems and parental expressed emotions: a case report. *General Psychiatry* 2020;**33**:e100111. doi:10.1136/gpsych-2019-100111

Received 29 June 2019

Revised 17 May 2020

Accepted 07 July 2020

## ABSTRACT

West syndrome (WS) is the most common epileptic syndrome in infancy characterised by epileptic spasms, hypsarrhythmia and neurodevelopmental problems. Epileptic spasms remain in many ways a conundrum, and the ideal intervention, as well as how to screen patients to provide optimal care and certainly its genetic cause, remains puzzling. It is important to screen infants for early recognition and intervention to achieve the optimal outcome. We hereby discuss the approach to management of a boy aged 4½ years old with WS and behavioural problems and of parental expressed emotions.

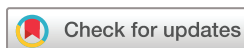## INTRODUCTION

West syndrome (WS), a form of infantile epilepsy characterised by the triad of infantile spasms, intellectual disability and hypsarrhythmia (typical electroencephalographic findings of chaotic and disorganised background activity with asynchronised, large-amplitude slow waves mixed with single focal and multifocal spikes and slow waves followed by attenuation), was first described by Dr West in 1841.<sup>1</sup> The burden of neurodisability, that is, neurological impairments, neurodevelopmental disorders (intellectual disability, autism spectrum disorders and attention deficit hyperactivity disorder (ADHD)) and learning difficulties, is high in children and adults with epilepsy, and more so in WS as it affects children at a very young age, that is, infancy.<sup>2</sup> In this paper, we discuss the approach to the management of a boy aged 4½ years old with WS and behavioural problems and of parental expressed emotions.

## CASE REPORT

A boy aged 4½ years old was brought to the outpatient services of the Department of Psychiatry with complaints of not being able to sit in one place for more than a few seconds and excessive behavioural problems. On exploration, it was found that the boy was born via preterm vaginal delivery and cried immediately after birth. There were

no intranatal/postnatal complications. He had adequate birth weight and was growing normally until approximately 5 months of age when he started to have sudden, jerky spasms of the neck and upper limbs occurring in clusters (5–6 spasms/cluster) for approximately 3–4 min, especially when waking up from sleep. A private physician started him on valproate syrup within a month of onset of these symptoms but without any response. Within 3–4 months of symptom onset, he was brought to a tertiary care hospital where he was diagnosed with WS. Investigation was conducted that includes MRI brain, metabolic work-up and spectroscopy with no abnormalities detected, and electroencephalogram (EEG) showed characteristic findings of hypsarrhythmia. He was treated with adrenocorticotrophic hormone injection (150 IU/m<sup>2</sup> for 10 weeks) and valproate syrup 35 mg/kg/day (continued for 3 years). He became spasm-free for the next 3 months after initiation of treatment and his parents also became overcautious and overprotective of him. By this time, his mother noticed that he had lost the milestones (social smile) that he earlier had achieved and also had delayed fine motor and gross motor development (eg, pincer grasp and sitting with support at 1 year). He started to speak bisyllables at 1½ years of age, played with toys and with children of his age, but had started to throw temper tantrums (screaming, shouting, trying to pull his hair, rolling down on the ground, hitting his parents and pulling their hair) if his demands were not fulfilled. His parents ultimately would give in to his demands after initial reluctance to calm him down. Around the same time, it was also observed that he did not sit in one place for more than a few seconds, and on many occasions he had gone out of the house (whenever he found the gates were open) and was not able to find his way back home. Also, he readily approached strangers, mingled with them, and took sweets



© Author(s) (or their employer(s)) 2020. Re-use permitted under CC BY-NC. No commercial re-use. See rights and permissions. Published by BMJ.

<sup>1</sup>Psychiatry, Institute of Mental Health, Pandit Bhagwat Dayal Sharma Post Graduate Institute of Medical Sciences, Rohtak, Haryana, India

<sup>2</sup>Psychiatry, Government Medical College and Hospital (GMCH), Chandigarh, Chandigarh, India

<sup>3</sup>Psychiatry, Post Graduate Institute of Medical Education and Research (PGIMER), Chandigarh, Chandigarh, India

<sup>4</sup>Psychiatry, AIIMS Bhubaneswar, Bhubaneswar, Orissa, India

## Correspondence to

Dr Yogender Kumar Malik, Psychiatry, IMH, Pt. B.D Sharma PGIMS, Rohtak, Haryana, India; yogendermalik187@gmail.com

and toys offered to him, which worried his parents. By 2½ years of age, he was walking independently, spoke a few meaningful words, scribbled and was put in play school. However, his parents received frequent complaints from his teachers that he disturbed other children, took away their pencils and erasers, did not sit in class, and cried, screamed, bit and pulled his teachers' hair when he was being disciplined. At times, his teachers would hit him in an attempt to control his behaviour but to no avail, and they finally stopped attending to him and allowed him to do whatever he wanted. Due to these complaints, the mother became very distressed and would beat him up on many occasions. His behavioural problems gradually increased both at home and school, and he would now snatch other children's food and screams if they protested, keeps on running in circles on the playground, and bangs his head and bites if he is prevented from doing so. He would be aware and conscious while indulging in these behaviours. His mother has become extremely distressed because of these and also because she found him to be lagging in all domains of growth and development compared with age-related peers and would often be critical of him. However, it was important to note that he would not indulge in such behaviours in front of a strict teacher or with children apparently stronger than him, or for 4–5 hours whenever he was reprimanded by his mother. For these behaviours, he was given risperidone tablet 0.5 mg/day for 1–2 months by the treating physician, with initial improvement but not sustained despite good compliance. Thereafter, he was given a trial of methylphenidate tablet 10 mg/day for 2 weeks and aripiprazole tablet 2.5 mg/day for 4–6 weeks without any improvement. Valproate syrup was stopped after 3 years with no seizure recurrence and he was then referred for psychiatric consultation for behavioural problems. He was admitted to the psychiatric unit for management. Ward observation revealed adequate social communication, unclear speech, no tics/abnormal movements and no hearing/visual impairment. Temperamentally (as per the Temperament Measurement Schedule),<sup>3</sup> he is an active child, readily approaches others, is less adaptable to any change, reacts instantaneously with high-intensity reactions for unfulfilled wishes and becomes irritable if demands were not met, but would persist with a task until he is faced with difficulty. In addition to being a temperamentally difficult child, inconsistent parenting led to an increase in behavioural problems. His mother was very rigid, punitive and non-tolerant to deviance and is inconsistent, comparing him with other peers and pointing out his deficits in development; the father's behaviour was opposite that of the mother. No abnormality was detected on general physical examination, and mental status examination revealed a tidy and well-groomed boy of stated age. Eye-to-eye contact was limited initially but improved as the interview progressed. He followed instructions, drew circles on a paper for 5–7 min at a stretch, and started roaming around the room after about 10 min but complied with the instructions to

sit down, did not initiate conversation, took a long time to reply to questions, and his speech was unclear. He did not show any signs of separation anxiety when his parents were asked to leave the room; however, he started to cry and scream when he was being forcefully taken out of the room, but calmed down when left alone. His intellectual function was assessed on the basis of history of social maturity (Vineland Social Maturity Scale applied) given by the parents and the Gesell Drawing Test Score. He had an IQ score of 67 (mild intellectual disability; mental age 3 years) on assessment. High negative expressed emotions, high expectations from the child and distress from the parents especially the mother were evident on the family front. Additionally, he was refused admission due to behavioural problems, which increased parental burn-out. During his ward stay, it was observed that the patient would have five to six episodes per day of temporary cessation of activity and vacant stare lasting for 1–2 s and was non-responsive, but with no other abnormal activity. These events, although seen by the mother, were not reported. Paediatric neurology consultation and video EEG confirmed ongoing seizure activity, for which valproate syrup up to 600 mg/day was prescribed. The mother was evaluated and managed for moderate depressive disorder. Parental psychoeducation for intellectual disability and associated behavioural problems, epilepsy, and for inconsistent parental handling and the role of expressed emotions was also provided. Now, the child is interacting well and attends to a task at hand for 10–12 min without getting distracted. Positive reinforcement, structured routine and realistic expectations with no comparisons, as well as parent management training, were employed, which brought about positive results to the child.

## DISCUSSION

The diagnosis of WS in the index case was not difficult given the characteristic presentation and EEG findings. Psychomotor development before convulsions is essentially normal in most cases, as was the finding in the index case.<sup>4</sup> Multiple cognitive, behavioural and emotional problems are experienced by children with epilepsy, in addition to the burden of epilepsy itself, the most common problem is impaired attention and hyperactivity.<sup>5</sup> The index case also displayed a variety of behavioural problems, which were also aggravated by the mother's negative expressed emotions and inconsistent parental handling. Behavioural problems improved following the environmental modification, employing behavioural techniques, and improving parental handling skills.

This case also highlights the fact that 'Every child presenting with hyperactivity is not necessarily a case of ADHD (attention deficit hyperactivity disorder)'. The hyperactivity in the index case was accounted for the seizure activity, manifested as absence seizures clinically but was missed by the family members. Hyperactivity improved after valproate syrup was added. Literature

supports worsening neurocognitive and behavioural dysfunction due to ongoing epilepsy and interictal discharges, a concept referred to as ‘epileptic encephalopathy’, and children presenting with such symptoms may not fit neatly into nosological diagnostic systems of ICD-10 (International Classification of Diseases-10) or DSM-5 (Diagnostic and Statistical Manual of Mental Disorders-5).<sup>6,7</sup> In addition to ongoing seizure activity causing hyperactivity, this boy was temperamentally a difficult child. Temperamental difficulties were further worsened by inconsistent parental handling and punitive mother. Although he was an active child, he did not meet the diagnostic criteria for ADHD as his hyperactivity improved on initiation of valproate and also because he was able to attend to a task for 15–20 min at a stretch with an attention span more than adequate for preschool children.

Cognitive and behavioural comorbidities in association with epilepsy are underdiagnosed and consequently undertreated. In a population-based study, 80% of school children with active epilepsy had behavioural and/or cognitive comorbidity and only a third had been diagnosed before the study was undertaken.<sup>8</sup> More importantly, it adversely affects psychosocial outcomes.

The approach to evaluating preschoolers with hyperactivity disorder should include assessment for neurodevelopmental disorders such as ADHD, autism spectrum disorder and intellectual disability with problematic hyperactivity (not appropriate to mental age), physical problems, sensory impairments, environmental issues (neglect, abuse, social isolation/deprivation), and temperament of the child. Thus, it becomes important to examine preschoolers presenting with such a plethora of symptoms in a holistic way and not be in a rush to put a diagnostic label. Rather, efforts should be made to understand the genesis of the problems in its entirety.

**Correction notice** This article has been corrected since it was published. Author bio has been updated.



*Yogender Kumar Malik completed MBBS program from Mullana Medical College, Kurukshetra University, Haryana, India in 2014, and obtained MD degree in Neuropsychiatry from PGIMER, Chandigarh, India in 2017 and also got DNB degree. He has been working at the Department of Psychiatry and Institute of Mental Health as Assistant Professor in PGIMS, Rohtak, India since 2015. His main research interests include psychopharmacology and epilepsy.*

**Acknowledgements** We acknowledge the patient and his family members for providing consent to report this case study.

**Contributors** All authors were involved in the management of the patient. YKM and NC drafted the initial manuscript. AS, SP and YKM critically evaluated the existing literature and drafted the final manuscript. All authors have equal contribution in the preparation of the manuscript.

**Funding** The authors have not declared a specific grant for this research from any funding agency in the public, commercial or not-for-profit sectors.

**Competing interests** None declared.

**Patient consent for publication** Parental/guardian consent obtained.

**Provenance and peer review** Not commissioned; externally peer reviewed.

**Open access** This is an open access article distributed in accordance with the Creative Commons Attribution Non Commercial (CC BY-NC 4.0) license, which permits others to distribute, remix, adapt, build upon this work non-commercially, and license their derivative works on different terms, provided the original work is properly cited, appropriate credit is given, any changes made indicated, and the use is non-commercial. See: <http://creativecommons.org/licenses/by-nc/4.0/>.

#### ORCID iD

Yogender Kumar Malik <http://orcid.org/0000-0003-0446-1755>

#### REFERENCES

- 1 Wilmshurst JM, Ibekwe RC, O'Callaghan FJK. Epileptic spasms - 175 years on: Trying to teach an old dog new tricks. *Seizure* 2017;44:81–6.
- 2 Koo B, Hwang PA, Logan WJ. Infantile spasms: outcome and prognostic factors of cryptogenic and symptomatic groups. *Neurology* 1993;43:2322–7.
- 3 Malhotra S, Randhawa A. A schedule for measuring temperament in children: preliminary data on development and standardization. *Indian J Clin Psychol* 1982;9:203–10.
- 4 Sari Gokten E, Duman N. West syndrome and autism: a case report. *Eur Res J* 2015;1:154–6.
- 5 Nickels KC, Zaccariello MJ, Hamiwka LD, et al. Cognitive and neurodevelopmental comorbidities in paediatric epilepsy. *Nat Rev Neurol* 2016;12:465–76.
- 6 World Health Organization. *The ICD-10 classification of mental and behavioral disorders: clinical descriptions and diagnostic guidelines*. Geneva: World Health Organization, 1992.
- 7 American Psychiatric Association. *Diagnostic and statistical manual of mental disorders*. 5th ed, 2013.
- 8 Reilly C, Atkinson P, Das KB, et al. Neurobehavioral comorbidities in children with active epilepsy: a population-based study. *Pediatrics* 2014;133:e1586–93.