

Clinical Article

Anatomical Morphometric Study of the Cervical Uncinate Process and Surrounding Structures

Sung-Ho Kim, M.D.,¹ Jae Hack Lee, M.D., Ph.D.,² Ji Hoon Kim, M.D.,³ Kwon Soo Chun, Ph.D.,⁴
Jae Won Doh, M.D., Ph.D.,⁵ Jae Chil Chang, M.D., Ph.D.³

Department of Neurosurgery,¹ Soonchunhyang University Gumi Hospital, Gumi, Korea

Department of Neurosurgery,² Hurinaeun Hospital, Seoul, Korea

Department of Neurosurgery,³ Soonchunhyang University Seoul Hospital, Seoul, Korea

Department of Pediatrics-Cardiology,⁴ Baylor College of Medicine, Houston, TX, USA

Department of Neurosurgery,⁵ Soonchunhyang University Cheonan Hospital, Cheonan, Korea

Objective : The purpose of this study is to elucidate the anatomic relationships between the uncinat process and surrounding neurovascular structures to prevent possible complications in anterior cervical surgery.

Methods : Twenty-eight formalin-fixed cervical spines were removed from adult cadavers and were studied. The authors investigated the morphometric relationships between the uncinat process, vertebral artery and adjacent nerve roots.

Results : The height of the uncinat process was 5.6-7.5 mm and the width was 5.8-8.0 mm. The angle between the posterior tip of the uncinat process and vertebral artery was 32.2-42.4°. The distance from the upper tip of the uncinat process to the vertebral body immediately above was 2.1-3.3 mm, and this distance was narrowest at the fifth cervical vertebrae. The distance from the posterior tip of the uncinat process to the nerve root was 1.3-2.0 mm. The distance from the uncinat process to the vertebral artery was measured at three different points of the uncinat process : upper-posterior tip, lateral wall and the most antero-medial point of the uncinat process, and the distances were 3.6-6.1 mm, 1.7-2.8 mm, and 4.2-5.7 mm, respectively. The distance from the uncinat process tip to the vertebral artery and the angle between the uncinat process tip and vertebral artery were significantly different between the right and left side.

Conclusion : These data provide guidelines for anterior cervical surgery, and will aid in reducing neurovascular injury during anterior cervical surgery, especially in anterior microforaminotomy.

Key Words : Anterior cervical surgery · Foraminotomy · Uncinat process, Vertebral artery · Nerve root.

INTRODUCTION

Hirsch⁶⁾ reported successful results from his discectomy without intervertebral body fusion in 1960, and various approaches have been suggested by other authors^{7-9,16)}. However, complications were also reported related to the anterior surgery from the injury of vertebral artery, nerve root and spinal cord during the operation^{7,18,19)}. Although complication from vertebral artery damage is not common, it may result in serious conditions with ischemic neurologic damage^{5,7,16,17,19)}. Flynn⁴⁾ reported 0.19% of nerve root damage in 82114 anterior cervical surgery cases.

The concern for possible complications may lead to insuffi-

cient nerve decompression being performed. In this regard, adequate anatomic knowledge of the cervical spine is essential for successful surgery without complications. Pait et al.¹⁴⁾ and Oh et al.¹²⁾ studied the spatial relationship between the uncinat process and vertebral artery in 1996, and Chang et al.²⁾ published the anatomic measurement data required for an uneventful anterior microforaminotomy. However, more studies are required in this area, especially where it lacks of in Korea.

The purpose of this study is to elucidate the anatomic relationships among neurovascular structures around the uncinat process.

• Received : May 3, 2012 • Revised : August 10, 2012 • Accepted : October 4, 2012

• Address for reprints : Jae Chil Chang, M.D., Ph.D.

Department of Neurosurgery, Soonchunhyang University Seoul Hospital, 59 Daesagwan-ro, Yongsan-gu, Seoul 140-743, Korea

Tel : +82-2-709-9268, Fax : +82-2-792-5976, E-mail : j7chang@gmail.com

• This is an Open Access article distributed under the terms of the Creative Commons Attribution Non-Commercial License (<http://creativecommons.org/licenses/by-nc/3.0>) which permits unrestricted non-commercial use, distribution, and reproduction in any medium, provided the original work is properly cited.

MATERIALS AND METHODS

Twenty-eight formalin-fixed cervical spines were removed from adult cadavers of nineteen men and nine women who ranging in age from 41 to 78 years. The anterior part of the cervical vertebral bodies and discs from C1 through C7 were exposed after removing the structures in front of them except for the longus colli muscle. Then, in the prone position, the spinal cord and nerve roots were exposed by laminectomy. The cervical vertebrae were then transected at the level of the disc spaces. Measurements made on the transverse sections were performed to understand the anatomical relationships of the various structures.

The uncinata process is a hook-shaped process on the lateral or posterior-lateral borders of the vertebral body. The height of the uncinata process is defined as the vertical distance between the upper tip of the process and the superior surface of the vertebral body (Fig. 1). The width of the uncinata process and the distances between the medial border of the uncinata process at the anterior, middle and posterior margins of the vertebral body were measured (Fig. 2). The shortest distance from the lateral



Fig. 1. Photograph of a cadaveric specimen showing the height and width of the uncinata process. 1 : height of uncinata process, 2 : width of uncinata process, UP : uncinata process.

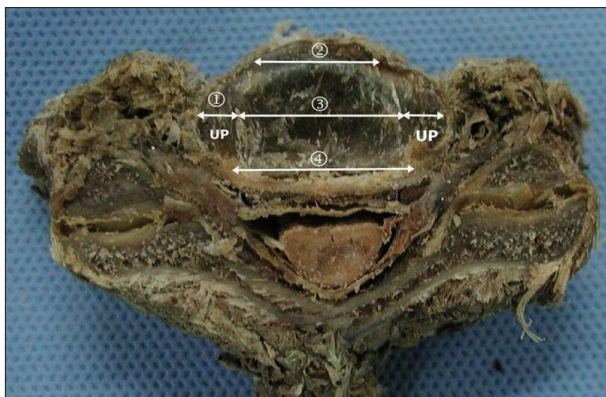


Fig. 2. Photograph of the transverse section through the disc level of the cervical spine showing the width of the uncinata process and the distance between the medial borders of the uncinata processes from each side of the vertebra. 1 : width of the uncinata process, 2 : distance between medial borders of uncinata processes at anterior margin, 3 : distance between medial borders of uncinata processes at midpoint, 4 : distance between medial borders of uncinata processes at posterior margin, UP : uncinata process.

wall of the uncinata process to the vertebral artery and the angle between the posterior tip of the uncinata process and vertebral artery were measured. The shortest distance from the posterior tip of the uncinata process to the nerve root was measured (Fig. 3). To elucidate the three-dimensional spatial relationship between the various structures of interest, the relative position between the uncinata process and vertebral artery, the shortest distance from the upper tip of the uncinata process to the vertebral artery and the shortest distance from the most antero-medial point of the uncinata process to the vertebral artery were determined (Fig. 4). The shortest distance from the upper tip of

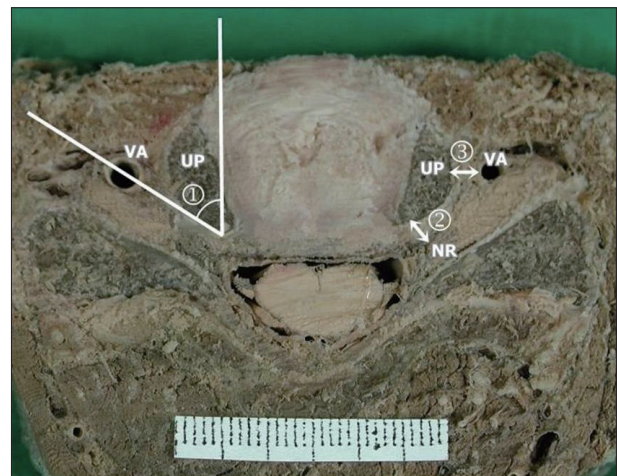


Fig. 3. Photograph of the transverse section through the disc level of the cervical spine. The relationship of the vertebral artery and nerve root to the uncinata process is shown. 1 : angle between posterior tip of uncinata process and vertebral artery, 2 : shortest distance from posterior tip of uncinata process to nerve root, 3 : shortest distance from lateral wall of uncinata process to vertebral artery, NR : nerve root, UP : uncinata process, VA : vertebral artery.

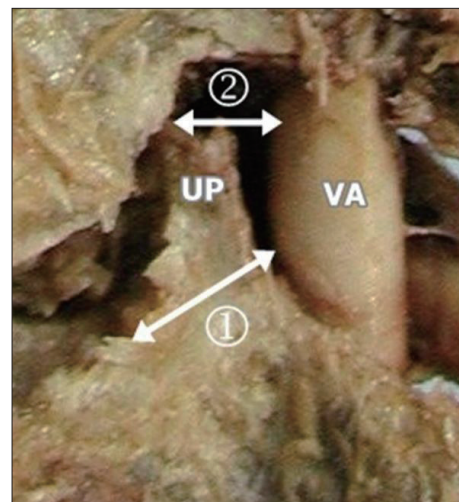


Fig. 4. Photograph of the cadaveric specimen showing the distance from the most anteromedial point of the uncinata process to the vertebral artery and the distance from the tip of uncinata process to the vertebral artery. 1 : distance from the most anteromedial point of uncinata process to vertebral artery, 2 : distance from upper tip of uncinata process to vertebral artery, UP : uncinata process, VA : vertebral artery.

the uncinat process to the vertebral body immediately above it was measured (Fig. 5).

The dimensions of each cervical vertebra then were measured with an electronic digimatic caliper (Mitutoyo, Tokyo, Japan) at a precision of 0.01 mm, and all angular measurements were recorded with a goniometer that was precise to within 1°. Averages and standard deviations were calculated, and the results for each side of uncinat process were compared to clarify the difference. The results were examined with the t-test using SPSS statistical software (version 14.0; SPSS, Chicago, IL, USA) and statistical significance was set at $p < 0.05$.

RESULTS

Height and width of uncinat process

The height of the uncinat process was 6.45 ± 1.38 (5.6-7.5) mm and the width was 6.55 ± 2.04 (5.8-8.0) mm. It was shortest (5.72 mm) and widest (7.78 mm) at C3; while, at C5, it was tallest (7.1 mm) and narrowest (5.74 mm) (Table 1).

The distance between the uncinat processes of the vertebrae

On the transverse sections, the average distances between the medial borders of the uncinat processes from each vertebrae measured at the anterior, middle and posterior margins of the

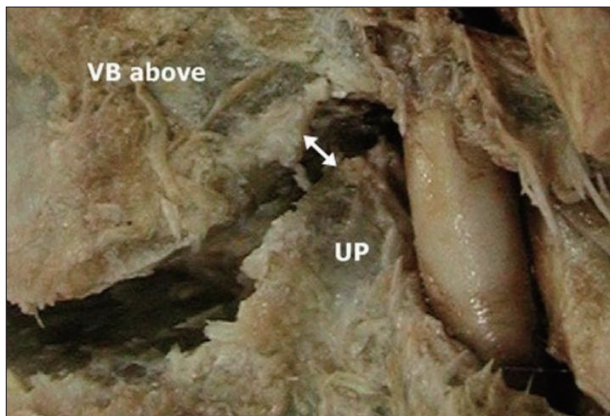


Fig. 5. Photograph of the cadaveric specimen showing Luschka joint space, corresponding to the distance from the upper tip of the uncinat process to the vertebral body immediately above it. UP : uncinat process, VB : vertebral body.

Table 1. Measurements of the uncinat process

	Distance (mm)					Average
	C3	C4	C5	C6	C7	
Height of uncinat process	5.72±1.26	6.68±1.63	7.10±1.48	6.81±1.30	5.96±1.41	6.45±1.38
Width of uncinat process	7.78±1.51	6.30±2.13	5.74±2.09	6.13±1.83	6.82±2.48	6.55±2.04
Distance between medial borders of uncinat process						
Anterior	15.70±2.32	16.81±2.97	18.07±3.15	19.47±3.36	23.21±3.93	18.65±2.91
Middle	12.00±4.08	14.58±3.92	16.13±4.11	16.74±4.81	18.64±4.81	15.62±4.29
Posterior	7.82±3.28	13.04±5.43	14.40±6.21	15.03±6.49	14.73±5.78	13.00±5.97

vertebral body were 18.65 ± 2.91 (15.7-23.2) mm, 15.62 ± 4.29 (12.0-18.6) mm, and 13.00 ± 5.97 (7.8-15.0) mm, respectively. The distance between the uncinat processes tended to be narrower towards the posterior portion of the vertebral body. In addition, the distances of three different measuring points were wider at the lower cervical vertebrae except for the distance at the posterior of the seventh cervical vertebrae (Table 1).

Relationship between the uncinat process and vertebral artery

The distance from the uncinat process to vertebral artery was measured at three different points of the uncinat process : upper tip, lateral wall, and the most antero-medial point. The distance from the upper tip of the uncinat process to the vertebral artery was 4.32 ± 0.84 (3.6-6.1) mm. The distance became shorter from C3 to C6 and widened at C7 which measured 4.5 mm on the right side and 3.8 mm on the left. The distance from the lateral wall of the uncinat process to vertebral artery was 2.04 ± 0.36 (1.7-2.8) mm. This was shortest at C4 and longest at C7. This may be because the vertebral artery passes through the transverse processes only from C6 and above. The distance at the most antero-medial point of the uncinat process was 4.94 ± 0.45 (4.2-5.7) mm. From C4 to C7, the angle between the posterior tip of the uncinat process and vertebral artery was $36.25 \pm 2.00^\circ$ ($32.2-42.4^\circ$), showing a slight variance (Table 2).

The relationship between the uncinat process and vertebral body immediately above it

The distance from the upper tip of the uncinat process to the inferior border of the vertebral body immediately above it was 2.46 ± 0.33 (2.1-3.3) mm. This was shortest at the fifth cervical vertebrae and the longest at the seventh (Table 2).

The relationship between the uncinat process (posterior tip) and nerve root

The shortest distance from the posterior tip of the uncinat process to the nerve root was 1.68 ± 0.19 (1.3-2.0) mm (Table 2).

Difference in the measurements between the right and left side uncinat process

The measurements which showed larger values for the left side than the right were as follows : the distance from the upper

Table 2. The measurements to the various structures from the uncinat process

	Distance (mm) and angle (degree)					Average
	C3	C4	C5	C6	C7	
Distance from upper tip of uncinat process to vertebral artery	5.80±1.46	4.08±1.84	3.80±1.64	3.79±1.84	4.13±1.80	4.32±0.84
Distance from lateral wall of uncinat process to vertebral artery	1.95±1.05	1.79±0.82	1.94±0.90	1.83±0.78	2.67±0.97	2.04±0.36
Distance from anteromedial point of uncinat process to vertebral artery	4.45±2.09	5.55±2.90	5.21±2.75	4.92±2.64	4.58±2.28	4.94±0.45
Distance from posterior tip of uncinat process to nerve root	1.37±0.37	1.87±0.96	1.66±0.51	1.68±0.56	1.81±0.92	1.68±0.19
Distance from upper tip of uncinat process to vertebral body above (=Luschka joint)	2.54±0.68	2.40±0.92	2.12±0.59	2.22±0.67	3.01±1.89	2.46±0.33
Angle between posterior tip of uncinat process and vertebral artery	34.72±2.84	35.54±7.47	35.71±10.20	38.77±9.46	34.96±6.66	36.25±2.00

Table 3. Right and left difference of the morphometric data

	Left (mean±SD)	Right	t-test
Distance from lateral wall of uncinat process to vertebral artery	1.9±0.9	2.0±0.9	0.202
Distance from upper tip of uncinat process to vertebral artery	4.4±2.0	3.9±1.5	0.040
Distance from anteromedial point of uncinat process to vertebral artery	5.2±2.7	4.8±2.5	0.295
Distance from posterior tip of uncinat process to nerve root	1.7±0.7	1.8±0.8	0.295
Distance from upper tip of uncinat process to vertebral body above (=Luschka joint)	2.5±1.3	2.4±0.9	0.329
Width of uncinat process	6.3±2.0	6.5±2.3	0.432
Height of uncinat process	6.2±1.3	6.9±1.7	0.001
Angle between posterior tip of uncinat process and vertebral artery	38.6±6.6	34±8.4	0.006

SD : standard deviation

tip of the uncinat process to vertebral artery, the distance from the most antero-medial point of the uncinat process to vertebral artery, the distance from the upper tip of the uncinat process to Luschka joint, and the angle between the posterior tip of the uncinat process and vertebral artery. The measurements which showed larger values for the right side than the left were as follows : the distance from the lateral wall of the uncinat process to vertebral artery, the distance from the posterior tip of the uncinat process to nerve root, and the height and width of the uncinat process. Among these results, the distance from the upper tip of the uncinat process to vertebral artery, the angle between the uncinat process and vertebral artery, and the height of the uncinat process were significantly different between the right and the left side ($p<0.05$) (Table 3).

DISCUSSION

The uncinat process, present only in the cervical vertebrae, is located on the top of the vertebral body from C3 to C7. It is a bilateral upward bony projection arising from the postero-lateral and superior surface of the vertebral body that form raised lateral borders¹⁵. In 1858, Luschka¹¹) named it as the “eminentia costaria” because it resembled an undeveloped costal bone, and in 1893, it was named “processus uncinatus” by Trolard²⁰.

Then, Payne and Spillane¹⁵) adopted the name “uncinat process” and reported that the processes were important in limiting lateral flexure. Luschka found a small space between the bottom of the upper vertebral body and the uncinat process, and reported that it was a joint space covered with synovial layer. This joint is now known as the “Luschka joint”.

If lateral dissection was more progress during discectomy through the anterior approach, the Luschka joint can be exposed and the potential of damaging the nerve root or the vertebral artery¹⁴) is likely to be increased. From the measurements of this study, the shortest distance from the upper tip of the uncinat process to vertebral body immediately above, where the Luschka joint was located, was only 2.5 mm. Pait et al.¹⁴) came up with similar measurements (0-3 mm) and also reported that the distance widened to 6 mm after moving the cervical vertebrae. It was stressed that utmost caution should be exercised when handling lesions with the cervical vertebrae being moved, in order not to damage the nerve root or vertebral artery. They also suggested that the surgery should be performed from the lateral to medial of the uncinat process, because the shortest distance from the upper tip of the uncinat process to the vertebral artery was only 0.8-1.6 mm. From the authors’ measurement, the distance was 3.6-6.1 mm, which was slightly different from the result of Pait et al.¹⁴). This may be caused by the differ-

ent measurement reference points used; the authors measured the vertebral artery distance from the medial point of the uncinat process, while the prior studies measured the distance from the lateral wall of the process.

The vertebral artery, which is separate from the subclavian artery, runs upward and rearward, and passes through the transverse foramen of the sixth cervical vertebrae¹³. The transverse foramens, along with the vertebral artery, are usually located in a more posterior position from the sixth to the third cervical vertebrae¹². In front of the transverse foramen, there is the anterior tubercle where the longus coli muscles are attached, and the inter-transverse muscles are located in-between. The uncinat process is located in the medial point. The nerve root passes through the posterior part of the cervical vertebrae. The uncinat process, which is adjacent to the vertebral artery and nerve root, is often exposed and operated on during the anterior cervical surgery. For radiculopathy from spondylosis, the recommended range of transverse decompression is, in general, 15-20 mm¹. Cooper reported that this range of decompression would be safe because the vertebral artery is located in 5 mm after removing 20 mm of vertebral body on both sides, considering that the distance between the medial borders of the transverse foramens was about 30 mm³. However, in this study, this distance showed a wide variation, from 7.8-15.0 mm and, thus, it is recommended to determine the level of decompression for each patient after measuring his/her radiologic distance rather than generally applying the level of decompression.

In case of myelopathy, decompression between both uncinat processes is sufficient; however, in case of radiculopathy, more lateral decompression is required to decompress the neural foramen. This may damage the nerve root near the uncinat process, and the risk is even higher if a large spur causes anatomic confusion. If the removal of the spur is limited in order to avoid complications during the surgery, it can lead to insufficient decompression of the neural foramen. To facilitate the surgery without complications, the authors measured the shortest distance from the posterior tip of the uncinat process to the nerve root which was 1.3-2.0 mm, showing a slight variance among measurement points. In other words, when posterior tip of the uncinat process are exposed during the neural foramen decompression for radiculopathy, it should be considered that nerve root can be located 1.3 mm apart from the process while removing spur.

Anterior approach for discectomy has been widely used because of its successful results. Recently, microforaminotomy, a minimally invasive surgery, has been developed and is increasingly being adopted⁹. It is a technique that removes a part of the uncinat process and relieves pressure upon the affected nerve root, by approaching from lateral border to medial boarder of uncinat process. This can minimize damage to the affected vertebrae's biomechanical functions, because only the lesion is removed and the discs are preserved without intervertebral body fusion or fixation. However, care should still be taken to

avoid damaging the vertebral artery and nerve root during the grinding of the uncinat process.

Lu and Ebraheim¹⁰ and Chang et al.² studied the anatomical relationship between the longus colli muscles and vertebral artery in cadavers in order to prevent damaging these structures during surgery and thus, reduce complications. Lu and Ebraheim¹⁰ measured the distance from the medial border of the longus colli muscles to the medial border of the vertebral artery. They found that the longest distance between these structures were at the sixth cervical vertebrae (11.5 mm). The distance was relatively narrower in the upper cervical vertebrae and the shortest distance was 9.0 mm at the third cervical vertebrae. According to the measurements by Chang et al.², the average distances in the 3-4, 4-5, 5-6 cervical vertebrae were 13.3-13.6 mm, and the average distance in the 6-7 cervical vertebrae was 14.7 mm. Although these two studies reported different measurement results, both agreed that the distance was narrower at the upper cervical vertebrae. These studies also suggested that extra careful operation is required at the seventh cervical vertebrae because the vertebral artery is located in front of the transverse process. However, if the longus colli muscle is removed during the surgery, it would naturally be difficult to determine the distance between the longus colli muscle and vertebral artery. Thus, the authors used the uncinat process as the reference point to determine its distance from the anatomical structures of interest during surgeries. Considering that the width of the uncinat process is 5.8-8.0 mm, the operator should be aware that the lateral wall of the uncinat process would be reached when he/she drills a hole of similar depth oriented horizontally and originating from the medial border of the uncinat process. According to Pait et al.¹⁴, the width of the uncinat process was 5.3-6.7 mm, which was slightly narrower than the authors' result. This difference is attributed to the different measurement perspectives used. The authors of the current study measured the longest width of the uncinat process from the transverse section of the specimen while Pait et al.¹⁴ measured the width of the uncinat process from the anterior view of the vertebral body. Since the distance from the lateral wall of the uncinat process to vertebral artery was only 1.7-2.8 mm, extra care is needed when the lateral wall is exposed.

Oh et al.¹² showed that the distance from the medial border of the uncinat process to the medial surface of transverse process was less than 6 mm, a little longer than the current authors' measurement (4.9 mm). Since different anatomical measurement studies on cadavers often use dissimilar measurement points in addition to the already subjective views of the researchers, this study used the uncinat process as the reference point for measuring the various distances and angles for the anatomic structures of interest in order to improve the practicality of the information for the surgery. In this study, the shortest distance from the antero-medial point of the uncinat process to the vertebral artery was 4.7-5.7 mm. Considering that the first grinding point of the uncinat process is the most antero-medial point,

drilling a 4.7 mm - deep hole through the uncinat process implies that the tip of the bit may very well reach the vertebral artery. Additionally, the lateral wall of the uncinat process is only 1.7-1.8 mm away from the vertebral artery. Understanding these anatomical relationships will help to detect the exposed points of the later wall of uncinat process and the vertebral artery. The angle between the posterior tip of the uncinat process and vertebral artery was 32.2-42.4°. It indicates that when the posterior tip of the uncinat process is exposed, the vertebral artery is located on the imaginary line along this angle, and the intersecting point between this line and 4.7-5.7 mm apart from the antero-medial point of uncinat process can be estimated as the location of vertebral artery.

Several researchers suggested various perspectives on the safety boundary. Jang et al.⁸⁾ stated that the surgical procedure could be done with a hole of 7 mm diameter at 15 mm off-center of the vertebral body. Lu and Ebraheim¹⁰⁾ stated that drilling a 5-6 mm deep hole, directed either vertically or horizontally, was safe at a point 5-6 mm medially from the lateral border of the uncinat process. Chang et al.²⁾, whose study was based on measurements using the longus colli muscle as the reference point, reported that the medial wall of the vertebral artery was located within 13-15 mm when the vertebral body is removed around at 40° with respect to the medial border of longus colli muscle. Microforaminotomy in the cervical spine is a minimally invasive technique that involves a limited surgical view. The limited surgical view can cause confusion of the anatomical relationships. Consequently, comprehensive anatomical measurements in various perspectives should be consulted for successful surgery.

CONCLUSION

From the various measurements concerning the uncinat process in relation to its neighboring structures taken at the level of the third through the seventh cervical vertebrae and using the uncinat process as a reference point, the following conclusions can be drawn. Since confusion over the anatomical structures can easily occur due to the limited surgical view associated with anterior cervical surgery, the measurement results taken from the subaxial cervical vertebrae in this study will contribute to a successful surgery.

References

1. Bartolomei J, Sonntag V : Anterior approach including cervical corpectomy in Winn HR, Youmans JR (eds) : *Youmans' Neurological Surgery*, ed 5. Philadelphia : WB Saunders, 2004, pp4431-4445
2. Chang JC, Park HK, Bae HG, Cho SJ, Choi SK, Byun PJ : Morphometric measurement of the anatomical landmark in anterior cervical microforaminotomy. *J Korean Neurosurg Soc* 39 : 340-346, 2006
3. Cooper PR : Anterior cervical vertebrectomy : tips and traps. *Neurosurgery* 49 : 1129-1132, 2001
4. Flynn TB : Neurologic complications of anterior cervical interbody fusion. *Spine (Phila Pa 1976)* 7 : 536-539, 1982
5. Hardy RW : Complication of anterior cervical surgery in Tarlov EC (ed) : *Complications of spinal surgery*. Park Ridge : American Association of Neurological Surgeons, 1991, pp85-94
6. Hirsch C : Cervical disc rupture : diagnosis and therapy. *Acta Orthopaedica* 30 : 172-186, 1961
7. Horwitz NH, Rizzoli HV : Herniated intervertebral discs and spinal stenosis in Horwitz NH, Rizzoli HV (eds) : *Postoperative complications of extracranial neurosurgery*. Baltimore : Williams & Wilkins, 1987, pp30-98
8. Jang WY, Kim KS, Lee JC, Kim CJ, Choi HY, Xuan XN, et al. : Results of microsurgical anterolateral tunnel approach for cervical disc herniation. *J Korean Neurosurg Soc* 30 : 600-604, 2001
9. Jho HD : Microsurgical anterior cervical foraminotomy for radiculopathy : a new approach to cervical disc herniation. *J Neurosurg* 84 : 155-160, 1996
10. Lu J, Ebraheim NA : The vertebral artery : surgical anatomy. *Orthopedics* 22 : 1081-1085, 1999
11. Luschka H : *Die Halbgelenke des menschlichen korpers*. Berlin : Reimer, 1858
12. Oh SH, Perin NI, Cooper PR : Quantitative three-dimensional anatomy of the subaxial cervical spine : implication for anterior spinal surgery. *Neurosurgery* 38 : 1139-1144, 1996
13. Osborne AG : *Diagnostic cerebral angiography*, ed 2. Philadelphia : Lippincott Williams & Wilkins, 1999
14. Pait TG, Killefer JA, Arnautovic KI : Surgical anatomy of the anterior cervical spine : the disc space, vertebral artery, and associated bony structures. *Neurosurgery* 39 : 769-776, 1996
15. Payne EE, Spillane JD : The cervical spine; an anatomico-pathological study of 70 specimens (using a special technique) with particular reference to the problem of cervical spondylosis. *Brain* 80 : 571-596, 1957
16. Schneider RC : Treatment of cervical spine disease in Schneider RC, Kahn EA, Crosby EC, Taren JA (eds) : *Correlative neurosurgery*, ed 3. Springfield : Charles C Thomas, 1982, pp1094-1174
17. Schweighofer F, Passler JM, Wildburger R, Hofer HP : Interbody fusion of the lower cervical spine : a dangerous surgical method? *Langenbecks Arch Chir* 377 : 295-299, 1992
18. Shintani A, Zervas NT : Consequence of ligation of the vertebral artery. *J Neurosurg* 36 : 447-450, 1972
19. Smith MD, Emery SE, Dudley A, Murray KJ, Leventhal M : Vertebral artery injury during anterior decompression of the cervical spine. A retrospective review of ten patients. *J Bone Joint Surg Br* 75 : 410-415, 1993
20. Trolard P : [Quelques articulations de la colonne vertebrale]. *Int Monatschr F Anat Physiol* 10 : 1-11, 1893