



Review article

Post-hypoxic myoclonus: Differentiating benign and malignant etiologies in diagnosis and prognosis

Brin Freund^{a,*}, Peter W. Kaplan^{b,1}^aJohns Hopkins Hospital, Department of Neurology, Baltimore, MD, USA^bJohns Hopkins Bayview Medical Center, Department of Neurology, Baltimore, MD, USA

ARTICLE INFO

Article history:

Received 31 January 2017

Received in revised form 15 March 2017

Accepted 17 March 2017

Available online 5 May 2017

Keywords:

Myoclonus status epilepticus

Lance-Adams syndrome

Post-hypoxic myoclonus

Cardiac arrest

ABSTRACT

Neurological function following cardiac arrest often determines prognosis. Objective tests, including formal neurological examination and neurophysiological testing, are performed to provide medical providers and decision-makers information to help guide care based on the extent of neurologic injury. The demonstration of post-hypoxic myoclonus on examination has been described to portend poor outcome after cardiac arrest, but recent studies have challenged this idea given that different forms of post-hypoxic myoclonus predict disparate prognoses.

The presence of myoclonus status epilepticus (MSE) usually signals a poor outcome, especially if generalized. Lance-Adams syndrome (LAS), another form of post-hypoxic myoclonus, carries a better prognosis. Differentiating subtypes of post-hypoxic myoclonus is therefore critical. This can be difficult in the acute setting with clinical examination alone due to the use of sedation to facilitate mechanical ventilation, and neurophysiological studies may be more reliable.

In this review, we describe and compare clinical and neurophysiological features of MSE and LAS. Generalized epileptiform activity and burst suppression on electroencephalography tend to be more common in MSE, and focal epileptiform activity at the vertex may define LAS. Those with multifocal MSE may have better outcomes than those with generalized MSE. We conclude that neurophysiological testing is vital acutely after cardiac arrest when post-hypoxic myoclonus is present to help determine prognostication and guide decision-making.

© 2017 International Federation of Clinical Neurophysiology. Published by Elsevier B.V. This is an open access article under the CC BY-NC-ND license (<http://creativecommons.org/licenses/by-nc-nd/4.0/>).

Contents

1. Introduction	99
2. Clinical features of PHM	99
2.1. MSE	99
2.2. LAS	100
3. Neurophysiologic features of PHM	100
3.1. MSE	100
3.2. LAS	101
4. Conclusions	102
Conflict of interest	102
References	102

* Corresponding author at: Department of Neurology, Johns Hopkins Hospital, 600 N. Wolfe St., Zayed Tower, Room 6005, Baltimore, MD 21287, USA.

E-mail addresses: bfreund3@jhmi.edu (B. Freund), pkaplan@jhmi.edu (P.W. Kaplan).

¹ Address: 4940 Eastern Avenue, Baltimore, MD 21224, USA.

1. Introduction

Prognostication in comatose patients after cardiac arrest (CA) relies heavily on the neurological examination to determine brain function, due to the fact that the extent of brain injury following CA often determines outcomes and costs for long-term care (Rossetti et al., 2016; Sandroni et al., 2015; Wijdicks et al., 2006). In particular, early post-hypoxic myoclonus (PHM) is of significant prognostic value (Elmer et al., 2016; Freund et al., 2016). PHM is defined as repetitive, generalized, focal or multifocal, motor myoclonic movements involving the face, limbs, or trunk that can occur at any time following CA, stemming from increased neuronal excitability after brain injury (Elmer et al., 2016; Freund et al., 2016; Wijdicks et al., 1994). There are different forms of PHM, previously defined by timing of onset, termed “acute” and “chronic” (Freund et al., 2016). “Acute” PHM (also referred to as myoclonus status epilepticus (MSE)) is the clinical appearance of nearly continuous myoclonic jerking for at least 30 min (Sandroni et al., 2015; Wijdicks et al., 2006). MSE was previously believed to indicate a poor prognosis (Wijdicks et al., 1994, 2006; Young et al., 1990) but this is being challenged by increasing reports of cases with a favorable outcome (Freund et al., 2016; Gupta and Caviness, 2016; Lucas et al., 2012; Malhotra and Mohinder, 2012; Seder et al., 2015; Sutter et al., 2016). Conversely, “chronic” PHM or Lance-Adams syndrome (LAS) portends a better prognosis (Malhotra and Mohinder, 2012).

Unfortunately, PHM subtypes can be difficult to differentiate in the acute setting when sedatives may mask clinical and neurophysiological characteristics (Freund et al., 2016; Gupta and Caviness, 2016). This can make diagnosis challenging, as clinical examination and neurophysiological testing are crucial in predicting future neurological function (Stevens and Sutter, 2013) and may help define PHM subtypes and their associated outcomes (Bouwes et al., 2012; Chadwick et al., 1977; Elmer et al., 2016; English et al., 2009; Freund et al., 2016; Frucht and Fahn, 2000; Gupta and Caviness, 2016; Hallett, 2000; Seder et al., 2015; van Zijl et al., 2016; Werhahn et al., 1997; Wijdicks et al., 1994; Witte et al., 1988).

In this article we will review the defining characteristics of MSE and LAS. Our goal is to elucidate clinical and neurophysiological features that can allow for better differentiation between types of PHM, to enable earlier diagnosis and the institution of the appropriate management. We will also point out gaps in our understanding to guide further study.

2. Clinical features of PHM

Prior studies have attempted to define the various forms of PHM based on a number of clinical features. Unfortunately, many authors did not clearly distinguish LAS from MSE, and only recently have studies focused more closely on differentiating the two (Elmer et al., 2016; Freund et al., 2016; Gupta and Caviness, 2016). This distinction is key, because many cases previously described as “acute” PHM were later diagnosed as being LAS once the patient awakened (Freund et al., 2016; Gupta and Caviness, 2016). Specific clinical indicators that have been studied to discriminate LAS and MSE, and to delineate subtypes of MSE include: time to onset of myoclonus after CA (Bouwes et al., 2012; Gupta and Caviness, 2016; Malhotra and Mohinder, 2012; van Zijl et al., 2016), outcomes (Bouwes et al., 2012; Elmer et al., 2016; English et al., 2009; Harper and Wilkes, 1991; Lance and Adams, 1963; Malhotra and Mohinder, 2012; Rossetti et al., 2016; Seder et al., 2015; Sutter et al., 2016; Wijdicks et al., 1994; Young et al., 1990), response to treatment (Chadwick et al., 1977; Werhahn et al., 1997; Witte et al., 1988), clinical characteristics of myoclonus (Bouwes et al., 2012; English et al., 2009; Gupta and

Caviness, 2016; Hallett et al., 1977; Hallett, 2000; van Zijl et al., 2016), and neurologic exam with particular focus on the presence of coma (English et al., 2009).

2.1. MSE

MSE has been characterized as multifocal (Bouwes et al., 2012; English et al., 2009; Gupta and Caviness, 2016; van Zijl et al., 2016) or generalized, massive jerking of the body (Hallett, 2000) and typically occurs within the first 72 h of CA (van Zijl et al., 2016). It may last for days before resolving (Gupta and Caviness, 2016). MSE is believed to originate in subcortical regions, likely from the brainstem, and can occur spontaneously, or be stimulus-sensitive (Hallett, 2000). MSE typically demonstrates bilateral synchronous myoclonus involving the sternocleidomastoid, trapezius, and facial muscles as well as of the trunk and limbs (English et al., 2009; Hallett et al., 1977). In generalized MSE, proximal musculature is often involved (Hallett et al., 1977), consistent with subcortical myoclonus (Bouwes et al., 2012), although diffuse limb involvement may also be seen (van Zijl et al., 2016). In patients with multifocal MSE, about half demonstrate proximal limb myoclonus, and 75% may have distal limb involvement (van Zijl et al., 2016). It has been reported that multifocal MSE and generalized MSE can be reliably distinguished by clinical exam (van Zijl et al., 2016), but these conclusions have not been validated and should be viewed with caution.

On examination, the patients are usually comatose. Though this is most often due to the severe neurologic insult, wakefulness is often masked by the concurrent use of sedatives for ventilator management in the acute setting after CA (English et al., 2009). Therefore, examination is optimally performed during minimal sedation.

Treatment of MSE is not well established. Given the appearance of epileptiform activity both clinically and electroencephalographically, anti-seizure drugs (ASD) are often first line, with anesthetics used if these fail (Gupta and Caviness, 2016). Clonazepam is often used, and serotonergic medications have also been tried (Hallett, 2000) though myoclonus in MSE is usually difficult to treat (Sutter et al., 2016). Previously it was believed that the anatomic localization of myoclonus could be made based on the response to treatment, but has not been consistently demonstrated (Chadwick et al., 1977; Werhahn et al., 1997; Witte et al., 1988).

The mortality in patients with MSE after CA ranges from 90 to 100% (Bouwes et al., 2012; Elmer et al., 2016; Rossetti et al., 2016; Seder et al., 2015; Sutter et al., 2016; Wijdicks et al., 1994; Young et al., 1990). The chances of a good neurologic outcome in survivors is also low (Seder et al., 2015; Sutter et al., 2016). Some authors suggest that those with multifocal PHM may have better neurologic function and survival than generalized PHM (Bouwes et al., 2012), but this has not been confirmed (van Zijl et al., 2016). Better outcomes in multifocal PHM might be attributable to differences in the extent of brain injury, given that focal or multifocal PHM has a localized cortical origin (Cassim and Houdayer, 2006; Caviness and Brown, 2004), whereas generalized PHM results from diffuse cortical injury (Cassim and Houdayer, 2006; Hallett et al., 1977). This may also explain survival differences between LAS and MSE as LAS may have a more focal localization clinically and electro-encephalographically (Elmer et al., 2016; Freund et al., 2016). Further investigation into the outcomes of the different clinical forms of MSE is warranted.

Other clinical features that portend worse outcomes in CA are seen more commonly in patients with MSE. These include longer time to professional cardiopulmonary resuscitation, less frequent bystander resuscitation, and higher rates of non-shockable cardiac rhythm on presentation (Seder et al., 2015). These clinical factors likely explain why MSE heralds a poor recovery. Further study should evaluate if these clinical indicators also help delineate

MSE from LAS, and differentiate those with MSE who have disparate outcomes.

2.2. LAS

LAS can be generalized or multifocal, and is intention and stimulus-induced (English et al., 2009; Hallett, 2000). The areas of the limb involved depend on whether or not myoclonus is from a cortical or subcortical source (Bouwes et al., 2012). It has been noted previously that LAS presents later after CA than MSE (English et al., 2009), and though it can occur months to years following CA, LAS has been seen within hours (Freund et al., 2016). Hence, time to onset cannot reliably distinguish PHM subtypes.

LAS usually occurs once patients regain consciousness (Lucas et al., 2012). This delay in the clinical diagnosis of LAS is often due to the use of sedatives that mask alertness, thereby preventing intention or action myoclonus from being clinically evident (Freund et al., 2016; Malhotra and Mohinder, 2012; Wijdicks et al., 2006). The use of sedation early after CA makes clinical examination difficult as patients appear comatose, similar to those with MSE. As patients awaken, many neurologic domains remain intact, including cognition, though they may be left with significant cerebellar dysfunction and chronic myoclonus (English et al., 2009; Harper and Wilkes, 1991; Lance and Adams, 1963; Malhotra and Mohinder, 2012).

Treatments for LAS are similar to those for MSE, including the use of the same ASDs (Frucht and Fahn, 2000) and serotonergic agents (Giménez-Roldán et al., 1988). Differentiating subtypes of myoclonus based on the response to treatment is not well established, and further study is warranted before relying on clinical response for diagnosis and management.

Historically, patients diagnosed with LAS were thought to invariably survive CA (Freund et al., 2016). However, this is likely due to survivorship bias as some patients with LAS have myoclonus soon after CA (Elmer et al., 2016; Freund et al., 2016), which may be confused with MSE and therefore lead to early withdrawal of ventilator support based on prior study that MSE consistently leads to poor outcomes after CA (Seder et al., 2015). A recent study showed that 4/8 comatose patients with early post-arrest myoclonus who demonstrated similar electroencephalography (EEG) findings survived and were subsequently diagnosed with LAS (Elmer et al., 2016). Though patients who survive may live independently, many are unable to perform activities of daily living due to neurologic dysfunction or intention myoclonus (English et al., 2009; Lance and Adams, 1963).

LAS is more commonly associated with respiratory arrest than a primary CA (Freund et al., 2016). No other clinical distinction has been found regarding particulars of the CA itself.

3. Neurophysiologic features of PHM

The use of neurophysiological studies in the evaluation of PHM has been a focus of study given the difficulty in differentiating PHM subtypes in the acute setting based on clinical examination (Cassim and Houdayer, 2006; Caviness and Brown, 2004; Elmer et al., 2016). These studies can help delineate cortical and subcortical myoclonus, and diffuse versus focal epileptiform activity, which may be useful in defining subtypes of PHM and prognosis (Brown et al., 1991; Elmer et al., 2016; Gupta and Caviness, 2016; van Zijl et al., 2016). EEG itself may facilitate the diagnosis of LAS without the use of clinical characteristics (Elmer et al., 2016).

Cortical myoclonus is represented neurophysiologically by giant somatosensory evoked potentials (SSEPs) and jerk-locking, defined by a correlation between epileptiform discharges on the EEG and clinical myoclonus using concurrent electroencephalography-electromyography (EEG-EMG) polygraphy (Bouwes et al., 2012; Cassim and Houdayer, 2006; Caviness and Brown, 2004;

Hallett, 2000; Sutter et al., 2016; Witte et al., 1988). There may be false-negatives, since the lack of jerk-locking does not exclude cortical myoclonus given that the signal might be too small to register on EEG, or it may be obscured by high signal background noise (Cassim and Houdayer, 2006). Cortical myoclonus may also be characterized on EEG by diffuse abnormalities, including epileptiform activity (Bouwes et al., 2012; Gupta and Caviness, 2016; van Zijl et al., 2016). However, others have explained these EEG findings as reflecting severe cortical injury with the subsequent disinhibition of a subcortical focus (Cassim and Houdayer, 2006; Hallett et al., 1977).

Subcortical myoclonus can be differentiated from cortical myoclonus by the absence of giant SSEPs and the lack of jerk-locking on EEG-EMG polygraphy. On EEG, generalized epileptiform activity, such as periodic discharges, may also denote subcortical myoclonus (Sutter et al., 2016; van Zijl et al., 2016). EEG-EMG polygraphy during a myoclonic jerk may also reveal muscles innervated by lower brainstem nuclei, including the trapezius and sternocleidomastoid, being activated initially before spread to facial musculature (Hallett et al., 1977).

Ultimately, EEG is the most reliable and studied tool for evaluating PHM (Gupta and Caviness, 2016). However, there is variability in EEG over time in the post-arrest period (Elmer et al., 2016) which is often not accounted for (Freund et al., 2016; Freund and Kaplan, 2016), making it difficult to interpret and apply data from studies of EEG to define myoclonus.

3.1. MSE

A previous review (Gupta and Caviness, 2016) indicated two studies that pointed to a cortical origin for myoclonus in MSE (Bouwes et al., 2012; van Zijl et al., 2016), whereas others have demonstrated a subcortical generator produced by disinhibition after diffuse cortical injury (Hallett et al., 1977; Hallett, 2000; Witte et al., 1988). Neurophysiological features noted in these patients include normal or absent SSEPs (Bouwes et al., 2012; Westhall et al., 2016; Wijdicks et al., 2006) lack of jerk-locking with EEG-EMG polygraphy (Hallett et al., 1977; Witte et al., 1988), and inconsistent correlation between clinical myoclonus and epileptiform activity on EEG without the use of EEG-EMG polygraphy (Gupta and Caviness, 2016), all of which would suggest a subcortical source. Generalized epileptiform discharges and burst-suppression have been described (Elmer et al., 2016; Hofmeijer et al., 2014; van Zijl et al., 2016; Wijdicks et al., 1994), and may portend a worse prognosis in MSE (Seder et al., 2015). EEG can show burst-suppression early on, which may then evolve into generalized periodic discharges within 2–3 days of CA (Elmer et al., 2016). Intermittent or continuous spike-wave activity is also seen in these patients and can resemble status epilepticus (Gupta and Caviness, 2016; Seder et al., 2015). Lateralized periodic discharges are not typically seen (Wijdicks et al., 1994), which is another indicator suggesting that the cortex may not be the source for myoclonus. When compared to CA survivors *without* PHM, those with MSE less commonly demonstrate generalized slowing (Wijdicks et al., 1994). Alpha coma has also been seen in some cases (Gupta and Caviness, 2016; Wijdicks et al., 1994; Young et al., 1990), although this may only be present when the EEG is performed later in the clinical course after CA (Wijdicks et al., 1994).

Given the possible differences in outcomes in patients with multifocal versus generalized MSE (Harper and Wilkes, 1991), neurophysiological testing has been investigated to help delineate these forms of MSE. Multifocal MSE is presumed to have a cortical origin based on EEG studies (Cassim and Houdayer, 2006; Caviness and Brown, 2004; van Zijl et al., 2016). However, this has not been proven using SSEP and EMG-EEG polygraphy (van Zijl et al., 2016). One study determined that generalized status epilepticus was more common in

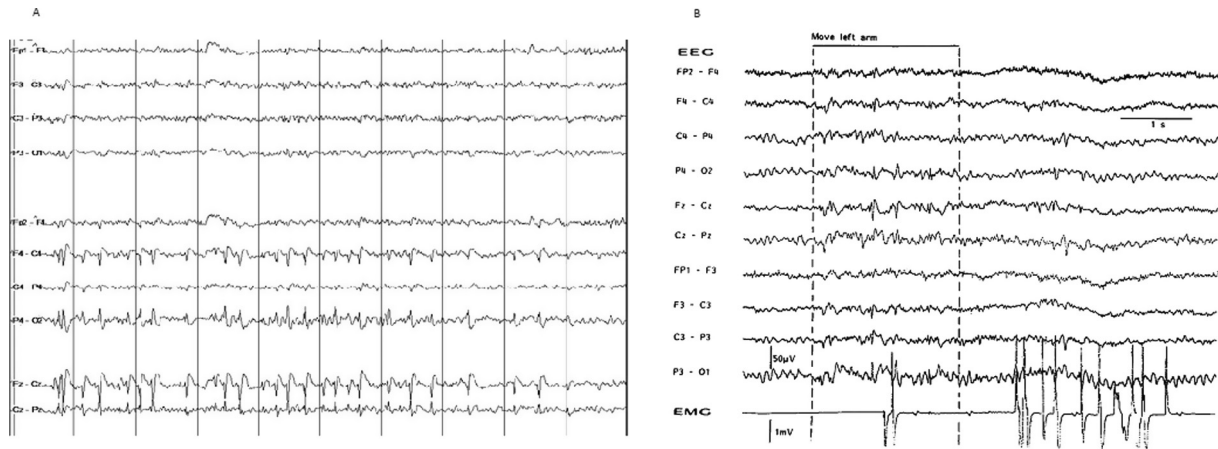


Fig. 1. A. EEG on day 0 following cardiac arrest demonstrates narrow polyspikes and spikes predominantly in the midline and parasagittal regions. Adapted with permission from Elmer et al. (2016). B. EEG demonstrates spikes maximally at the midline. Adapted with permission from Witte et al. (1988).

Table 1
Summary of clinical and EEG findings in PHM.

	MSE	LAS
<i>Clinical features</i>		
Body parts involved	Generalized or multifocal; trunk, trapezius, sternocleidomastoid, face, limbs; proximal and distal limb involved	Generalized, multifocal, or focal; limb involvement depends on cortical vs. subcortical sources
Timing of onset	Rarely after 72 h post-cardiac arrest	From hours to years following cardiac arrest
Length of duration	Days to weeks	Days to years
Response to treatment	Usually poor	Variable
Neurologic examination	Usually comatose	Comatose if sedated; awake, alert, and cognition may be relatively preserved
Mortality rate	90–100% of cases	Unclear given selection and survivorship bias, but in one retrospective study 50% of patients with similar EEG findings survived
Good neurologic outcome	Rare, may be more likely with multifocal versus generalized MSE	Common
Circumstances of cardiac arrest	Longer time to CPR, less bystander resuscitation, higher rates of non-shockable cardiac rhythm on presentation	Often primary respiratory arrest
Stimulus-sensitivity of myoclonus	Yes	Yes
Spontaneous myoclonus	Yes	Occasionally
Intention myoclonus	No	Yes
<i>Neurophysiological findings</i>		
EEG findings	Generalized epileptiform discharges and burst suppression, status epilepticus noted by intermittent or continuous spike-waves; lateralized periodic discharges and focal discharges are less common; over time burst suppression can evolve into generalized periodic discharges; diffuse slowing less common; alpha coma, particularly later after cardiac arrest	Epileptiform activity in up to 1/3 of cases often maximally or primarily at the vertex especially within hours after cardiac arrest, can have normal background activity; diffuse or focal slowing; up to 20% are normal
SSEPs	Normal or absent; giant SSEPs not consistently demonstrated; lacking thorough evaluation of multifocal PHM	Can demonstrate both giant and normal-sized SSEPs
EEG-EMG polygraphy	Typically lacks jerk-locking; a thorough evaluation of multifocal PHM is lacking	Jerk-locking has been noted in roughly 60% of cases
<i>Localization</i>		
	Subcortical, possibly cortical	Both subcortical and cortical

generalized MSE, while diffuse slowing was more likely seen in multifocal MSE (van Zijl et al., 2016). Further study in this subpopulation is needed to elucidate the source of myoclonus, the differences in EEG characteristics, and to confirm their different prognoses.

3.2. LAS

A recent review defined many of the EEG findings in LAS (Freund et al., 2016). Epileptiform activity was noted in up to 1/3 of cases, and in half of these, spike or polyspike-wave discharges were noted primarily or maximally at the vertex (Fig. 1A, B). Some

cases also demonstrated normal EEGs between myoclonic jerks. A recent retrospective study of patients within the first 6–8 h of CA reported vertex-localized spike-waves on EEG in 12% of patients, of whom 50% survived with a favorable outcome and who were subsequently diagnosed as LAS based on clinical criteria (Elmer et al., 2016). These findings localize the phenomenon to the motor cortex and explain the manifestations of intention-induced myoclonus in those with LAS (Giménez-Roldán et al., 1988). Other non-specific EEG findings in LAS include diffuse or focal slowing, although about 20% were noted to have a normal EEG (Freund et al., 2016).

Of those undergoing EEG-EMG polygraphy, about 60% demonstrated jerk-locking, denoting cortical myoclonus, which was further illustrated by SSEPs which showed a similar proportion of cortically-based myoclonus by the presence of “giant” SSEPs. However, there was a significant proportion demonstrating subcortically based myoclonus noted by the lack of jerk-locking on EEG-EMG polygraphy and normal sized SSEPs (Freund et al., 2016).

It appears that localization to the cortical or subcortical regions is not helpful in defining LAS as both areas can be involved. However, if cortical myoclonus is unique to LAS then this finding might differentiate LAS from MSE, particularly the generalized phenotype. Further study should be performed to evaluate whether the presence of subcortical or cortical myoclonus in LAS affects outcome, and to confirm if the vertex epileptiform activity can be consistently demonstrated to represent LAS.

Table 1 provides a summary of the clinical neurophysiologic features of the different forms of PHM.

4. Conclusions

In this review, we discussed the clinical and neurophysiologic characteristics of “acute” and “chronic” PHM, or MSE and LAS, in order to better define these entities, because of their markedly different prognoses. Clinical distinction between different subtypes of PHM can be difficult in the acute post-arrest period when patients are subjected to sedating medications to allow ventilator support. Though differentiating cortical and subcortical myoclonus may be helpful, better definition of the EEG features that determine the severity of brain injury and that provide reliable prognoses, is needed. Neurophysiological studies may eventually enable an understanding of the pathophysiology underlying different forms of PHM, and provide help in differentiating those patients with good versus poor outcomes.

Conflict of interest

None.

Both authors (BF and PWK) contributed to conception and design, as well as manuscript drafting and revising. Both authors have approved the final article.

References

- Bouwes, A., van Poppelen, D., Koelman, J.H., Kuiper, M., Zandstra, D.F., Weinstein, H. C., Tromp, S.C., Zandbergen, E.G.J., Tijssen, M.A.J., Horn, J., 2012. Acute posthypoxic myoclonus after cardiopulmonary resuscitation. *BMC Neurol.* 12 (1), 63.
- Brown, P., Thompson, P.D., Rothwell, J.C., Day, B.L., Marsden, C.D., 1991. A case of postanoxic encephalopathy with cortical action and brainstem reticular reflex myoclonus. *Mov. Disord.* 6 (2), 139–144.
- Cassim, F., Houdayer, E., 2006. Neurophysiology of myoclonus. *Neurophysiol. Clin.* 36 (5–6), 281–291.
- Caviness, J.N., Brown, P., 2004. Myoclonus: current concepts and recent advances. *Lancet Neurol.* 3, 598–607.
- Chadwick, D., Hallett, M., Harris, R., Jenner, P., Reynolds, E., Marsden, C., 1977. Clinical, biochemical and physiological factors distinguishing myoclonus responsive to 5-hydroxytryptophan, tryptophan plus a monoamine oxidase inhibitor, and clonazepam. *Brain* 100, 455–487.
- Elmer, J., Rittenberger, J.C., Faro, J., Molyneaux, B.J., Popescu, A., Callaway, C.W., Baldwin, M., 2016. Clinically distinct electroencephalographic phenotypes of early myoclonus after cardiac arrest. *Ann. Neurol.* 80, 175–184.
- English, W.A., Griffin, N.J., Nolan, J.P., 2009. Myoclonus after cardiac arrest: pitfalls in diagnosis and prognosis. *Anaesthesia* 64, 908–911.
- Freund, B., Kaplan, P.W., 2016. Differentiating Lance-Adams syndrome from other forms of postanoxic myoclonus. *Ann. Neurol.* 80 (6), 956.
- Freund, B., Sutter, R., Kaplan, P., 2016. Lance-Adams syndrome in the pretargeted temperature management era: a case report and systematic review. *Clin. EEG Neurosci.* <http://dx.doi.org/10.1177/1550059416643193>. Epub 2016 Apr 25.
- Frucht, S., Fahn, S., 2000. The clinical spectrum of posthypoxic myoclonus. *Mov. Disord.* 15 (Suppl 1), 2–7.
- Giménez-Roldán, S.M.D., Muradas, V., De Yébenes, J.G., 1988. Clinical, biochemical, and pharmacological observation in a patient with postasphyxial myoclonus: association to serotonin hyperactivity. *Clin. Neuropharmacol.* 11, 151–160.
- Gupta, H.V., Caviness, J.N., 2016. Post-hypoxic myoclonus: current concepts, neurophysiology, and treatment. *Tremor Other Hyperkineset. Mov.* 6, 409.
- Hallett, M., 2000. Physiology of human posthypoxic myoclonus. *Mov. Disord.* 15 (Suppl. 1), 8–13.
- Hallett, M., Chadwick, D., Adam, J., Marsden, C.D., 1977. Reticular reflex myoclonus: a physiological type of human post-hypoxic myoclonus. *J. Neurol. Neurosurg. Psychiatry* 40, 253–264.
- Harper, S., Wilkes, R., 1991. Posthypoxic myoclonus (the Lance-Adams syndrome) in the intensive care unit. *Anaesthesia* 46, 199–201.
- Hofmeijer, J., Tjepkema-Cloostermans, M.C., van Putten, M.J., 2014. Burst-suppression with identical bursts: a distinct EEG pattern with poor outcome in postanoxic coma. *Clin. Neurophysiol.* 125, 947–954.
- Lance, J.W., Adams, R.D., 1963. The syndrome of intention or action myoclonus as a sequel to hypoxic encephalopathy. *Brain* 86, 111–136.
- Lucas, J.M., Cocchi, M.N., Saliccioli, J., Stanbridge, J.A., Geocadin, R.G., Herman, S.T., Donnino, M.W., 2012. Neurologic recovery after therapeutic hypothermia in patients with post-cardiac arrest myoclonus. *Resuscitation* 83, 265–269.
- Malhotra, S., Mohinder, K., 2012. Lance-Adams syndrome: difficulties surrounding diagnosis, prognostication, and treatment after cardiac arrest. *Anesth. Essays Res.* 6, 218–222.
- Rossetti, A.O., Rabinstein, A.A., Oddo, M., 2016. Neurological prognostication of outcome in patients in coma after cardiac arrest. *Lancet Neurol.* 15, 597–609.
- Sandroni, C., Cavallaro, F., Callaway, C.W., Sanna, T., D'Arrigo, S., Kuiper, M., Della Marca, G., Nolan, J.P., 2015. Predictors of poor neurological outcome in adult comatose survivors of cardiac arrest: a systematic review and meta-analysis. Part 1: patients not treated with therapeutic hypothermia. *Resuscitation* 84, 1310–1323.
- Seder, D.B., Sunde, K., Rubertsson, S., Mooney, M., Stammet, P., Riker, R.R., Kern, K.B., Unger, B., Cronberg, T., Dziodzio, J., Nielsen, N., 2015. Neurologic outcomes and postresuscitation care of patients with myoclonus following cardiac arrest. *Crit. Care Med.* 43, 965–972.
- Stevens, R., Sutter, R., 2013. Prognosis in severe brain injury. *Crit. Care Med.* 41, 1104–1123.
- Sutter, R., Ristic, A., Rüegg, S., Fuhr, P., 2016. Myoclonus in the critically ill: diagnosis, management, and clinical impact. *Clin. Neurophysiol.* 127, 67–80.
- van Zijl, J.C., Beudel, M., vd Hoeven, H.J., Lange, F., Tijssen, M.A.J., Elting, J.W.J., 2016. Electroencephalographic findings in posthypoxic myoclonus. *J. Intensive Care Med.* 31 (4), 270–275.
- Werhahn, K., Brown, P., Thompson, P., Marsden, C., 1997. The clinical features and prognosis of chronic posthypoxic myoclonus. *Mov. Disord.* 20, 213–217.
- Westhall, E., Rossetti, A.O., van Rootselaar, A.F., Wesenberg Kjaer, T., Horn, J., Ullén, S., Friberg, H., Nielsen, N., Rosén, I., Aneman, A., Erlinge, D., Gasche, Y., Hassager, C., Hovdenes, J., Kjaergaard, J., Kuiper, M., Pellis, T., Stammet, P., Wanscher, M., Wetterslev, J., Wise, M.P., Cronberg, T., 2016. Standardized EEG interpretation accurately predicts prognosis after cardiac arrest. *Neurology* 86, 1482–1490.
- Wijdicks, E.F., Parisi, J.E., Sharbrough, F.W., 1994. Prognostic value of myoclonus status in comatose survivors of cardiac arrest. *Ann. Neurol.* 35, 239–243.
- Wijdicks, E.F.M., Hijdra, A., Young, G.B., Bassetti, C.L., Wiebe, S., 2006. Practice parameter: prediction of outcome in comatose survivors after cardiopulmonary resuscitation (an evidence-based review). *Neurology* 67, 203–210.
- Witte, O.W., Niedermeyer, E., Arendt, G., Freund, H.J., 1988. Post-hypoxic action (intention) myoclonus: a clinico-electroencephalographic study. *J. Neurol.* 235, 214–218.
- Young, G.B., Gilbert, J.J., Zochodne, D.W., 1990. The significance of myoclonic status epilepticus in postanoxic coma. *Neurology* 40, 1843–1848.