



## ORIGINAL ARTICLE

# *In vivo* assessment of the anterior scleral contour assisted by automatic profilometry and changes in conjunctival shape after miniscleral contact lens fitting



Rute Juliana Macedo-de-Araújo<sup>a,\*</sup>, Eef van der Worp<sup>b</sup>, José Manuel González-Méijome<sup>a</sup>

<sup>a</sup> *Clinical & Experimental Optometry Research Lab (CEORLab), Center of Physics, University of Minho, Braga, Portugal*

<sup>b</sup> *Eye-Contact-Lens Research & Education, Amsterdam, The Netherlands*

Received 3 August 2018; accepted 1 October 2018

Available online 2 November 2018

### KEYWORDS

Scleral shape;  
Topography;  
Profilometry;  
Fluorescein

### Abstract

**Purpose:** To compare the shape of the anterior sclera of candidates to scleral lens (ScCL) fitting with regular and irregular corneas and analyze the changes induced in the shape of the sclero-conjunctiva after ScCL wear.

**Methods:** Thirty-five eyes of 18 subjects (19 eyes with irregular corneas and 16 with regular corneas) were consecutively recruited. Three measures of sclero-conjunctival shape were taken with Eye Surface Profiler (ESP, Eaglet Eye, Houten, The Netherlands). Tangent angles and ocular sagittal heights (OC-SAG) were analyzed at different chords from 13 to 17 mm in the nasal, temporal, superior and inferior regions. The 19 eyes with irregular cornea were selected to wear ScCL and the changes in their sclero-conjunctival surface parameters were compared before and after 3 h of lens wear.

**Results:** Irregular corneas showed higher OC-SAG values than regular corneas in all the chords analyzed, with statistical significant differences in the temporal region. Regarding tangent angles, regular corneas showed lower values (flatter surface), with statistical significant differences at 8 and 8.50 mm on the nasal and 8.50 mm on the temporal region. Some changes were seen in sclero-conjunctival shape after short-term ScCL wear. There was an augment in OC-SAG after 3 h of scleral lens wear and a reduction on tangent angles, namely on the nasal region at 7.5 mm and 8.00 mm chord lengths, which is coincidental with the landing zone of ScCL.

**Conclusions:** ESP shows mild differences in scleral shape between eyes with regular and irregular corneas. ESP might be valuable in quantifying the mechanical impact of the ScCL on the anterior eye surface.

© 2018 Spanish General Council of Optometry. Published by Elsevier España, S.L.U. This is an open access article under the CC BY-NC-ND license (<http://creativecommons.org/licenses/by-nc-nd/4.0/>).

\* Corresponding author.

E-mail address: [rjfmaraújo@gmail.com](mailto:rjfmaraújo@gmail.com) (R.J. Macedo-de-Araújo).

**PALABRAS CLAVE**

Forma de la esclera;  
Topografía;  
Perfilometría;  
Fluoresceína

## Valoración *in vivo* del contorno de la esclera anterior asistida por perfilometría automática, y de los cambios en la forma conjuntival tras el uso de lentillas mini-esclerales

**Resumen**

**Objetivo:** Comparar la forma de la esclerótica anterior de los candidatos a utilizar lentes de apoyo escleral (ScCL) con córneas regulares e irregulares, y analizar los cambios inducidos en la forma de la superficie esclero-conjuntival tras el uso de dichas lentes.

**Métodos:** Se incluyeron consecutivamente treinta y cinco ojos de 18 sujetos (19 ojos con córneas irregulares y 16 con córneas regulares). Se realizaron tres mediciones de la forma esclero-conjuntival con el dispositivo Eye Surface Profiler (ESP, Eaglet Eye, Houten, The Netherlands). Se analizaron los ángulos tangenciales y las alturas sagitales oculares (OC-SAG) a diferentes cuerdas, de 13 a 17 mm en las regiones nasal, temporal, superior e inferior. Se seleccionó a los 19 ojos con córnea irregular para utilizar ScCL, comparándose los cambios de los parámetros de su superficie esclero-conjuntival antes y después del uso de lentillas durante 3 horas.

**Resultados:** Las córneas regulares reflejaron valores OC-SAG superiores a las córneas regulares en todas las cuerdas analizadas, con diferencias estadísticamente significativas en la región temporal. En cuanto a los ángulos tangenciales, las córneas regulares reflejaron unos valores inferiores (superficie más plana), con diferencias estadísticamente significativas a 8 y 8,5 mm en la región nasal, y 8,5 mm en la región temporal. También se apreciaron algunos cambios en la forma esclero-conjuntival tras el uso a corto plazo de ScCL. Se produjo un aumento de los valores OC-SAG tras 3 h de uso de lentillas esclerales, y una reducción de los ángulos tangenciales, es decir, en las distancias correspondientes a las cuerdas de la región nasal a 7,5 mm y 8 mm, lo cual es coincidente con la zona de apoyo de las ScCL.

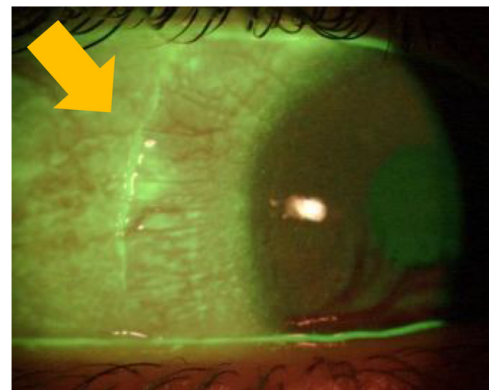
**Conclusiones:** El dispositivo ESP muestra leves diferencias en la forma escleral entre los ojos con córneas regulares e irregulares, y ha es capaz de por lo que podría resultar de utilidad para cuantificar el impacto mecánico de las lentes ScCL en la superficie anterior del ojo.

© 2018 Spanish General Council of Optometry. Publicado por Elsevier España, S.L.U. Este es un artículo Open Access bajo la licencia CC BY-NC-ND (<http://creativecommons.org/licenses/by-nc-nd/4.0/>).

**Introduction**

Contact lenses are still the preferred solution for visual correction of the irregular cornea. However, corneal rigid gas permeable, hybrid contact lenses or special soft contact lenses are frequently not suitable for highly distorted corneas. In that cases, the contact lens needs to vault the entire cornea and limbus and rest entirely in the scleral area beyond the limbus. Miniscleral and scleral lenses (ScCLs) are useful for visual rehabilitation of highly irregular corneas, and for the relief or severe dry eye symptoms in different ocular surface diseases.<sup>1,2</sup>

ScCL fitting is challenged by three main factors. First, ScCL are intended to align with the bulbar conjunctival tissue over the anterior sclera. This tissue is a thin layer of columnar epithelial cells supported by connective tissue and deep dense collagen – due to these histological characteristics, conjunctival tissue does not provide a stable support for ScCL. Instead, these lenses compress this soft tissue (Fig. 1), decreasing the vault and tightening the lens against the ocular surface over time.<sup>3,4</sup> Second, the tightening effect seals the posterior lens tear reservoir limiting the exchange of the tear film and promoting the formation of tear debris and limiting the oxygen transport to the cornea.<sup>5</sup> This might induce some degree of corneal edema, even though it is, on average, within the physiological limits (edema that occurs



**Figure 1** Conjunctival imprint after ScCL removal, indicating the landing zone area of the lens. This picture was obtained in one of the patients of the study during the initial fitting trials.

during sleep without contact lens).<sup>6</sup> Third, there was a poor understanding of the true scleral shape and until recently it was not possible to assess this relevant parameter in the clinical setting. In order to minimize the first two effects, modern ScCLs have been designed to provide a wider area of support in order to avoid localized impingement and/or compression of the sclero-conjunctiva tissue. This has been possible by the qualitative and quantitative evaluation of

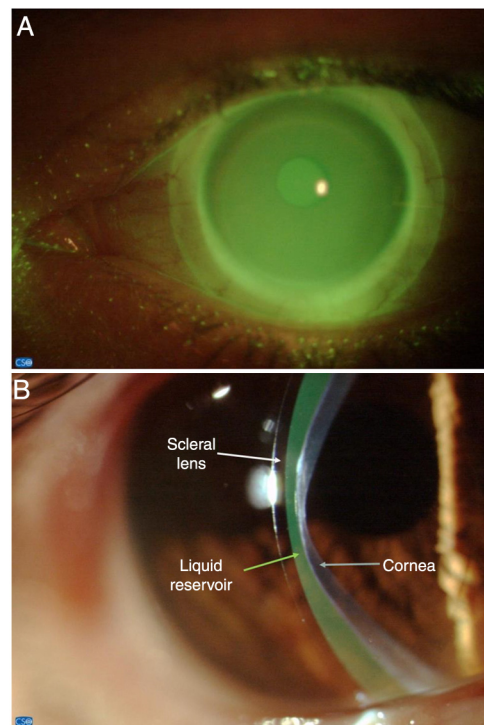
the scleral topography using image processing from anterior segment optical coherence tomography.<sup>1,7-9</sup> However, the inter-individual differences in shape and symmetry of the sclera limits the predictability of the fitting and the need to trial several lenses is frequent, increasing the chair time. Thus, a device that would be able to measure the scleral topography in the clinical setting, could potentially increase the predictability of ScCL fitting. Eye Surface Profiler (ESP) is a new device that uses optical profilometry to obtain a three dimensional reconstruction of the anterior ocular segment up to approximately 20 mm. This technology allows to measure the peri-limbal scleral topography in an automated manner<sup>10,11</sup> and could be useful in the evaluation of the areas under pressure and/or more decentered and assist in the decision to adjust ScCL parameters to seek a better distribution of the lens support over larger and wider areas using spherical or toric lens haptics designs.<sup>12</sup>

The main goals of the study were to compare scleral shape of eyes with regular and irregular corneas and to measure the changes in the topography of the sclero-conjunctiva where the miniscleral lens align with the ocular surface, in order to understand the main areas of compression of the lens.

## Material and methods

### Study design and subjects

This was a prospective study enrolling candidates to scleral lens fitting. The subjects were previously recruited to participate in a prospective clinical trial evolving ScCL fitting, have undergone the trial lens fitting process and were waiting for the final lens to be dispensed. The contact lens wearers were asked to discontinue the use of their habitual contact lenses prior to the evaluations. This study was divided into two parts. The first part of the study (Part I) aimed to compare the sclero-conjunctival shape between eyes with irregular corneal surfaces and eyes with regular corneal surfaces. Thirty-five eyes of 18 subjects (12 women) with mean age of  $35 \pm 11$  years were analyzed. Subjects were divided into two groups according to their corneal condition. Group I comprised 19 eyes with irregular corneal surfaces due to primary and secondary ectasia (2 eyes with post-LASIK ectasia, 2 eyes with keratoplasty and 15 eyes with keratoconus). The severity of keratoconus (KC) was classified with the Keratoconus Severity Score (KSS). Three eyes were classified as having grade 1, 2 eyes with grade 2, 8 eyes with grade 3 and 2 eyes with grade 5. The Group II comprised 16 regular corneas with high refractive errors (myopia  $\geq 6.00$  D and/or astigmatism  $\geq 2.00$  D). The second part of the present study (Part II) aimed to quantify the changes in sclero-conjunctival tissue after 3 h of ScCL wear. The measurements were performed only in the 19 eyes from Group I (irregular cornea group) during the scleral lens dispense visit. After Baseline (Part I) measures, these patients wore their brand new ScCL for approximately 3 h. Measurements were also performed after 3 h of ScCL wear (5 min after ScCL removal). Patients were informed about the purpose and nature of the evaluations and signed an informed consent form. The protocol of the study was reviewed and approved by the Ethics Committee of the School of Health Sciences of the University



**Figure 2** Frontal view of the miniscleral contact lens fitting (A) and relationship with the ocular surface (B).

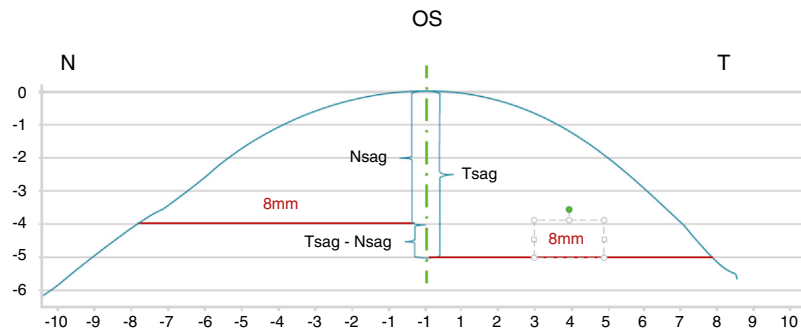
of Minho (Braga, Portugal) and followed the 1964 Helsinki declaration and its later amendments.

### Scleral Contact Lenses used and fitting protocol

The ScCLs used on the Part II of the present study were from Procornea Nederland B.V. (Eerbeek, The Netherlands). All the lenses had 16.4 mm diameter and were fitted according to manufacturers' recommendations. All subjects have already undergone a trial lens visit where the best scleral lens for each eye was selected with a trial-and-error method (Macedo-de-Araújo et al., submitted to publication). An ideal fit was achieved if there was no touch over the entire cornea and limbus, with a center corneal clearance between 100 and 200  $\mu\text{m}$  after settling and no conjunctival impingement or compression/blanching of the conjunctival vessels. Fig. 2 shows the appearance of the fitting of a ScCL. Lens fit was assessed with slit lamp examination and instillation of fluorescein (Fluo Strips, Contacare, India) directly on the lens, prior to its insertion. The measurements of Part II were done at the lens dispense visit, before that the subjects have only attended for a fitting visit more than 1 month ago.

### Measurements

The eye surface profiler (ESP) from Eaglet Eye (Houten, The Netherlands) is a new device to obtain the elevation of the anterior ocular segment using Fourier transform profilometry technique. The ESP has previously been validated.<sup>10,13</sup> It projects two grids over the anterior corneal surface stained with sodium fluorescein and creates a three dimensional



**Figure 3** Sagittal height calculation (image from Eye Surface Profiler user's manual). It is observed a flatter nasal (N) side when compared to temporal (T), which leads to a lower sagittal height on this side.

reconstruction of the anterior corneo-scleral topography up to 20mm chord. In our protocol, we stained the surface with a fixed amount of fluorescein diluted in non-preserved saline. Three repeated evaluations were performed 10s after instillation. To compensate the time lapse for processing data, a new drop of sodium fluorescein was applied after the first measurement to ensure consistent measurements. In order to achieve a greater field for analysis, the examiner held both eyelids against the orbital area without pressing the globe. Data was collected from each individual map (3 captures before and 3 captures after lens wear) and the average values at each visit were used for subsequent analysis. Different parameters were collected and analyzed:

Sagittal height of the anterior ocular surface (OC-SAG) was recorded at 14, 15 and 16mm in the horizontal meridian ( $180^\circ$ ). This measure gives the TSag (temporal sagittal height) and NSag (nasal sagittal height) and the difference between them that allows to quantify the scleral asymmetry (TSag-NSag). Fig. 3 represents a horizontal cross-section of a typical eye surface (image from ESP user's manual): as it is seen, the OC-SAG was calculated for a total chord of 16mm with the exactly half of the total chord length being attributed to NSag and TSag (8mm nasal and 8mm temporal). The respective sagittal heights are determined from the corneal apex outwards.

Tangent Angles at 6.5 mm, 7 mm, 7.5 mm, 8 mm and 8.5 mm in nasal, temporal, superior and inferior quadrants. These attributes will better describe the shape of the sclera rather than radii of curvature, because of its geometric nature. Also, tangent angles could be useful in determining the haptic zone of the lens.

## Statistical analysis

Statistical analysis has been conducted using SPSS v21.0 (IBM Inc. IL). Normality of data distribution was assessed using the Shapiro-Wilk test. Considering the nature of the data distribution, differences between quadrants were assessed using repeated measures ANOVA (normally distributed) or Friedman test (non-normally distributed). The level of statistical significance has been set at  $p < 0.05$ .

## Results

### Part I – Differences in scleral shape between eyes with regular and irregular corneal surfaces

Table 1 represents the OC-SAG at the different chord diameters analyzed (14 mm, 15 mm and 16 mm) for temporal and nasal quadrants and the difference between them for each meridian separately. As shown, the overall OC-SAG for each semi-meridian is always higher on the temporal region when compared to nasal, for all chord lengths analyzed, with statistical significant differences for all the chord diameters analyzed in both groups ( $p < 0.005$ , paired *t*-test or Wilcoxon, according to sample distribution). The OC-SAG values are increasing as the analyzed chord length is increasing in both nasal and temporal regions for both groups ( $p < 0.005$ , paired *t*-test or Wilcoxon, according to sample distribution). This suggests that there is a progressive asymmetry as we move away from limbus. The eyes with irregular corneas (Group I) showed higher values of OC-SAG than those from Group II, in all the chord lengths analyzed and in both nasal and temporal regions. Despite this, statistical significant differences between the two groups were only found on temporal region.

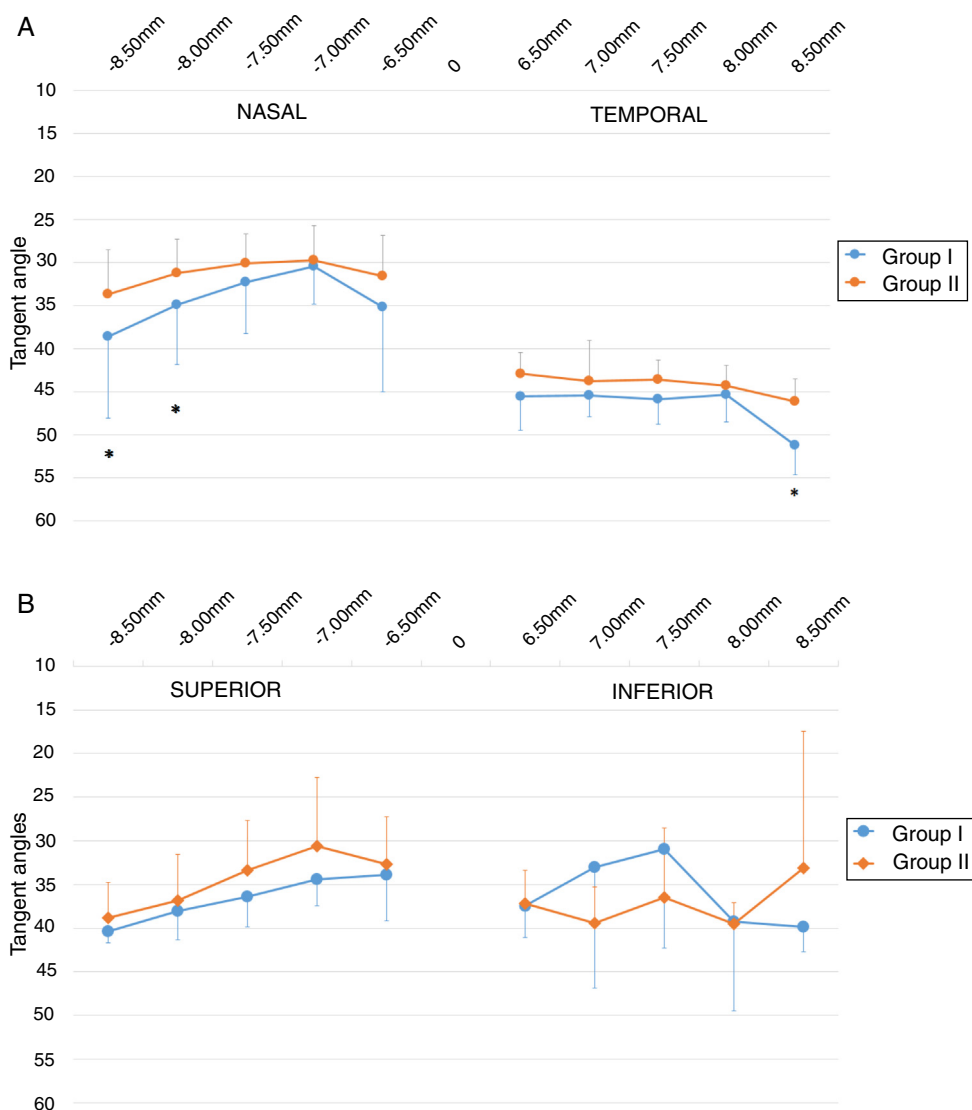
Fig. 4A represents the tangent angles at different chord lengths in nasal and temporal regions. On average, the values at temporal regions are higher than on the nasal region. The values are similar between eyes with regular and irregular corneas, with the first ones showing slightly lower values in nasal, temporal and superior regions, although without statistical significant differences between groups. The only statistical significant differences found between Group I and Group II were seen on the nasal side at 8 mm ( $31.19 \pm 3.86^\circ$  and  $34.96 \pm 6.91^\circ$ , respectively) and 8.50 mm ( $33.68 \pm 5.16^\circ$  and  $38.61 \pm 9.50^\circ$ , respectively) and for 8.50 mm on the temporal region ( $46.14 \pm 2.66^\circ$  and  $51.22 \pm 3.41^\circ$ , respectively). There is a bigger SD in eyes with KC.

Fig. 4B represents the tangent angles at different chord lengths in superior and inferior regions. Although subjects from Group II showed lower values than irregular cornea eyes (Group I) on the superior zone, there were no statistical significant differences between the two groups for all the points analyzed.

**Table 1** Differences in OC-SAG ( $\mu\text{m}$ ) between regular and irregular cornea eyes at 14, 15 and 16 mm in both temporal and nasal scleral regions.

OC-SAG ( $\mu\text{m}$ )	Regular cornea ( $n = 19$ )	Irregular cornea ( $n = 16$ )	Difference, $\mu\text{m}$ ( $p$ -value) <sup>a</sup>
TSag 14 mm	3453 $\pm$ 134	3628 $\pm$ 230	176 ( $p = 0.016$ )
NSag 14 mm	2909 $\pm$ 252	2945 $\pm$ 252	36 ( $p = 0.714$ )
TSag-NSag 14 mm	552 $\pm$ 295	683 $\pm$ 402	131 ( $p = 0.301$ )
Overall OC-SAG 14 mm	3181 $\pm$ 128	3287 $\pm$ 154	107 ( $p = 0.053$ )
TSag 15 mm	3888 $\pm$ 139	4123 $\pm$ 237	235 ( $p = 0.003$ )
NSag 15 mm	3199 $\pm$ 281	3312 $\pm$ 78	113 ( $p = 0.294$ )
TSag-NSag 15 mm	688 $\pm$ 327	810 $\pm$ 374	122 ( $p = 0.368$ )
Overall OC-SAG 15 mm	3544 $\pm$ 150	3718 $\pm$ 171	174 ( $p = 0.008$ )
TSag 16 mm	4394 $\pm$ 179	4599 $\pm$ 268	205 ( $p = 0.042$ )
NSag 16 mm	3524 $\pm$ 326	3571 $\pm$ 229	48 ( $p = 0.717$ )
TSag-NSag 16 mm	870 $\pm$ 356	1077 $\pm$ 86	207 ( $p = 0.229$ )
Overall OC-SAG 16 mm	3959 $\pm$ 192	4042 $\pm$ 127	84 ( $p = 0.253$ )

<sup>a</sup> Unpaired  $t$ -test.



**Figure 4** Differences in tangent angles between normal eyes (orange lines) and eyes with Keratoconus (KC - blue lines) on horizontal meridian (A) and vertical meridian (B).

\* Unpaired  $t$ -test.

**Table 2** Changes in sagittal height from apex at temporal and nasal sides after 3 h of lens wear.

OC-SAG ( $\mu\text{m}$ )	Baseline	After 3 h of ScCL wear	Difference ( $\mu\text{m}$ ) ( $p$ -value) <sup>a</sup>
TSag 14 mm	3608 $\pm$ 220	3694 $\pm$ 192	86 ( $p$ = 0.066)
NSag 14 mm	2911 $\pm$ 287	2922 $\pm$ 800	11 ( $p$ = 0.986)
TSag-NSag 14 mm	697 $\pm$ 401	772 $\pm$ 777	75 ( $p$ = 0.656)
TSag 15 mm	4099 $\pm$ 228	4185 $\pm$ 187	86 ( $p$ = 0.049)
NSag 15 mm	3256 $\pm$ 298	3306 $\pm$ 292	50 ( $p$ = 0.095)
TSag-NSag 15 mm	843 $\pm$ 385	859 $\pm$ 319	16 ( $p$ = 0.385)
TSag 16 mm	4547 $\pm$ 245	4599 $\pm$ 208	52 ( $p$ = 0.765)
NSag 16 mm	3497 $\pm$ 282	3600 $\pm$ 340	103 ( $p$ = 0.143)
TSag-NSag 16 mm	1092 $\pm$ 400	969 $\pm$ 350	123 ( $p$ = 0.466)

<sup>a</sup> Paired  $t$ -test.

## Part II – Differences in sclero-conjunctival tissue before and after 3 h of ScCL wear

Table 2 represents the changes on OC-SAG induced by the landing zone of a ScCL on eye (baseline and after 3 h). Both surfaces become steeper (deeper) after 3 h of ScCL wear, namely at 15 and 16 mm. There was only a statistical significant difference between measurements at 15 mm chord on the temporal region ( $p$  = 0.049).

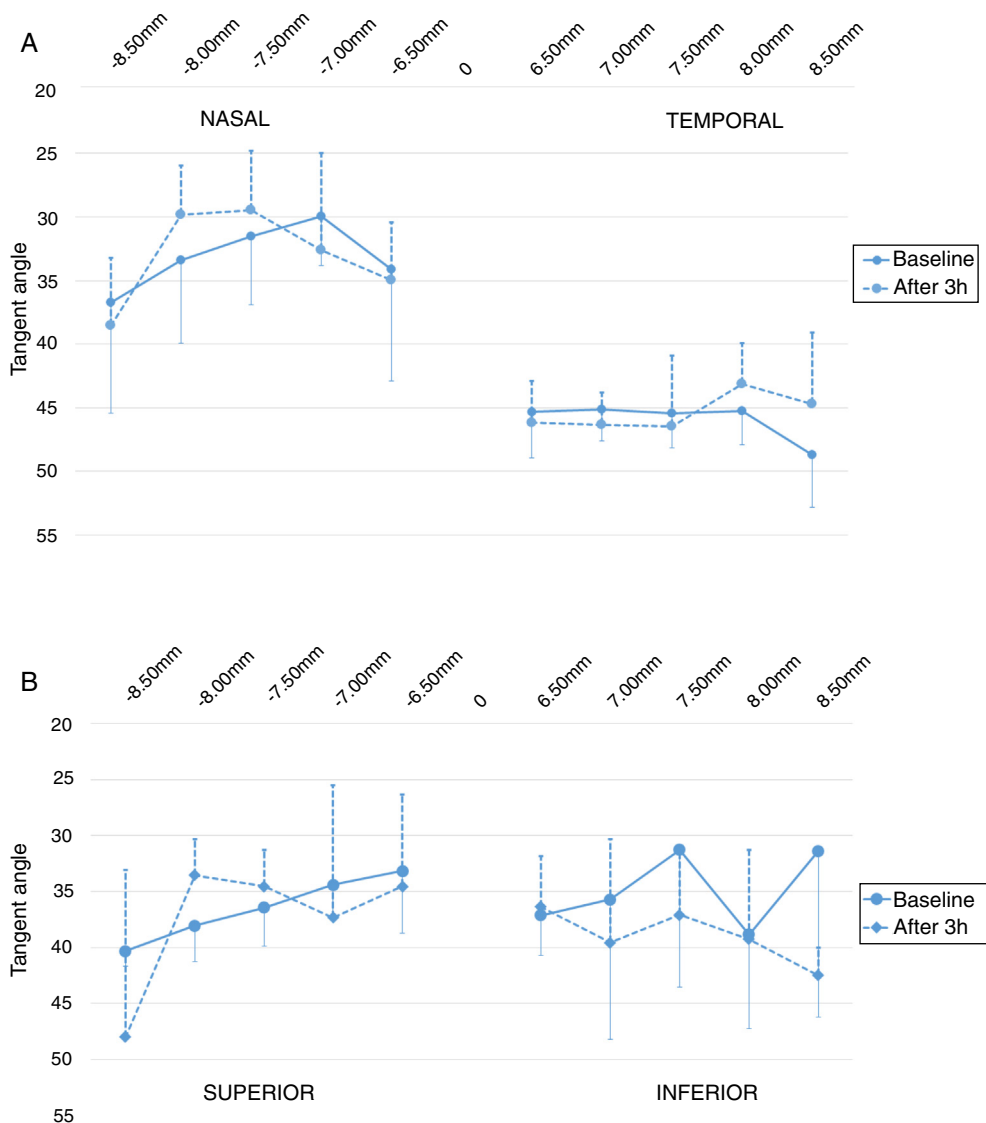
Fig. 5 shows the differences on Tangent Angles after 3 h of ScCL wear for nasal and temporal regions (Fig. 5A) and superior and inferior regions (Fig. 5B). Although there were no statistical significant differences in sclero-conjunctival shape after 3 h of scleral lens wear, there are some slight alterations namely on the nasal region. As seen, values are slightly higher between 6.50 and 7.50 mm, but after 7.50 mm became lower. On temporal side, the main differences are seen from 7.50 mm, being these values lower (meaning flatter) after 3 h of ScCL wear. In the superior zone there is not a consistent behavior. There are differences among all the chord lengths studied, and a decrease at 8.00 mm is seen, followed by a great augment.

## Discussion

In the present study a corneo-scleral topographer (ESP) was used to compare the sclero-conjunctiva shape of eyes with regular and irregular corneas and later investigate the influence of short-term scleral lens wear on sclero-conjunctiva. ESP has previously been used to measure scleral radius and limbus shape,<sup>13–15</sup> evaluation of scleral changes with accommodation<sup>16</sup> and has also been used to analyze perpendicular meridians to estimate the scleral asymmetry to relate it with scleral lens flexure on-eye.<sup>17</sup>

In the first part of the present study we aimed to detect differences in corneo-scleral profile between healthy eyes and eyes with keratoconus. It is important to establish those differences in anterior ocular surface anatomy to aid the ScCL fitting process. The emergence of recent technologies that allow to evaluate the anterior ocular surface (like scleral topographers and AS-OCT) allowed to characterize the scleral shape for different chords and its asymmetry.<sup>7,9,18,19</sup> Based on several studies with OCT, it is accepted that the

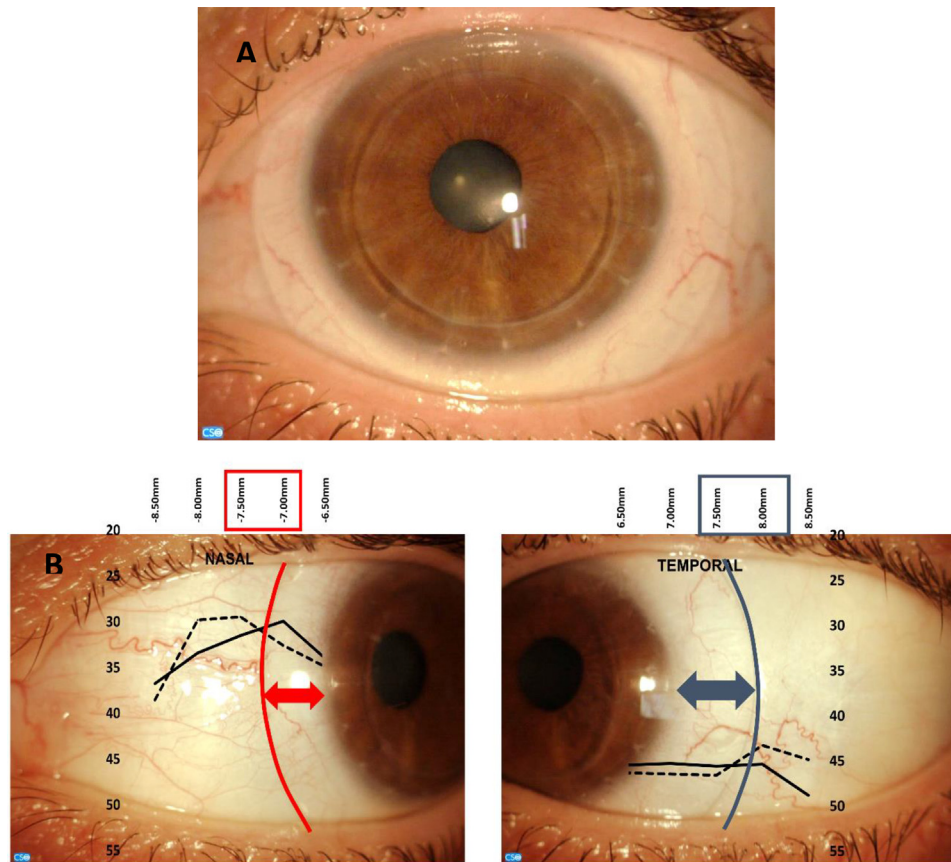
OC-SAG of the normal eye is on average about 3750  $\mu\text{m}$  with a range of 1000  $\mu\text{m}$ .<sup>20</sup> Several studies with OCT found values of horizontal OC-SAG at 15 mm of 3735  $\pm$  186  $\mu\text{m}$  (Harkness B et al., Poster American Academy Optometry, 2015), 3740  $\pm$  200  $\mu\text{m}$ <sup>8</sup> and 3740  $\pm$  160  $\mu\text{m}$ <sup>21</sup> for normal eyes, which are higher than those found in the present study for the same chord in eyes with regular cornea (3544  $\pm$  326  $\mu\text{m}$ ). Another study with ESP also found an OC-SAG value of 3755  $\pm$  207  $\mu\text{m}$  for 86 normal eyes at 15 mm.<sup>22</sup> The sample of the present study has different characteristics, as only eyes with high refractive errors were included and this could influence the mean OC-SAG. The OC-SAG of eyes with ectasias is expected to be higher than in normal eyes. Achong-Coan et al. found that eyes with keratoconus have an OC-SAG 205  $\mu\text{m}$  higher (on average) than normal eyes. (Achong-Coan et al., Poster Global Specialty Lens Symposium 2012). In the present study an average difference of 174  $\mu\text{m}$  was found between Group I and Group II ( $p$  = 0.008) for a 15 mm chord. The mean difference between groups was larger on the temporal region (235  $\mu\text{m}$ ,  $p$  = 0.03) than on the nasal region (113  $\mu\text{m}$ ,  $p$  > 0.05). Discrepancies between studies could be due to differences in the sample characteristics, as not all the eyes that are included in Group I have keratoconus, and the keratoconic eyes of the different studies might have been evaluated at different stages of severity. Recently, Piñero et al.<sup>11</sup> used a corneo-scleral topographer to compare the OC-SAG at 11, 12, 13 and 14 mm chord lengths of a large sample of normal and keratoconic eyes. For normal eyes, they found an OC-SAG of 3130  $\mu\text{m}$  for a 14 mm chord, which was similar to the value encountered in the present study for the same chord length (3181  $\mu\text{m}$ ). Similarly to the results of the present study, some differences were also found in OC-SAG between eyes with regular and irregular cornea, but only in moderate and advanced stages of keratoconus, and no statistical significant differences were found between normal eyes and eyes with less severe stages of keratoconus. Although the OC-SAG of regular cornea group at 14 mm was very similar to our study, they found a shallower OC-SAG for KC corneas (3120  $\mu\text{m}$  vs 3287  $\mu\text{m}$  in the present study). These differences could be due to different stages of keratoconus of the population analyzed, that could not be compared as the KC severity was measured with different scales in both studies. In another study from Sorbara et al.,<sup>7</sup> an OCT was used to



**Figure 5** Values of tangent angles from 6.50 to 8.50 mm in nasal and temporal regions (horizontal – A) and superior and inferior regions (vertical – B) at baseline and after 3 h of ScCL wear.

measure the OC-SAG at HVID and 15 mm chord in normal eyes and eyes with keratoconus in order to compare the differences between them. They analyzed the OC-SAG at steep and flat meridians, contrary to the present study in which the horizontal meridian (nasal and temporal regions) were analyzed. In fact, the great majority of studies conclude that there is no relationship between corneal and scleral toricity (both magnitude and orientation) especially in irregular corneas<sup>18,23,24</sup> (Posters Global Specialty Contact Lens Symposium, Kinoshita et al. 2016 and López-Alcón et al. 2018), however recent studies encountered a relationship between corneal and scleral astigmatism in subjects with healthy corneas and high corneal astigmatism.<sup>23,25</sup> Despite the methodological differences between studies, Sorbara et al. also found statistically significant differences between normal and KC eyes, and that KC eyes have a higher asymmetry in OC-SAG between steep and flat meridians (at both HVID and 15 mm) than normal eyes, similarly to the present study but in nasal and temporal regions and at 14, 15 and

16 mm chords (Table 1, Tsag-Nsag). Differences between healthy and irregular eyes were also found in tangent angles, with normal eyes having lower values, in accordance with the results of the present study. Sorbara et al.<sup>7</sup> also found differences in peripheral tangent angles between the two groups at 15 mm but not at HVID. Also, their results confirmed significant asymmetries between different quadrants of the sclera and that these asymmetries increase with the increasing chord diameter analyzed. Also, is confirmed that the nasal quadrant of the sclera is flatter. These asymmetries were already encountered by other studies with OCT and corneo-scleral topographers.<sup>1,7,18,19</sup> In conclusion, the mild differences found between regular and irregular corneas in the Part I of the study were already reported in the literature, but only in samples with normal cornea (typically with low refractive errors) and in keratoconus patients. In this study, regular cornea with high refractive errors and the irregular cornea group not only comprised with keratoconus (but also post-keratoplasties and post-lasik ectasias) were



**Figure 6** (A) Infero-temporal decentration of a ScCL. (B) Conjugation of results from Fig. 5A with figures from the nasal and temporal portion, demonstrating that the changes found on scleral tangent angles could coincide with the scleral lens haptic zone. Red (nasal) and blue (temporal) lines are overlapped with the landing zone of the lens, that is nearest the limbus on the nasal side than on the temporal side. The inferior-temporal part of the lens is visible in the bottom-right image.

analyzed, which could justify the differences found between this study and the literature.

The second part of the present study was focused on finding the possible differences in sclero-conjunctival profile after short-term ScCL wear and if the ESP device was able to detect those differences. Recent studies already showed that, although scleral lens do not mechanically touch the cornea, there is a flattening of the anterior corneal curvature following short term scleral lens wear.<sup>26–28</sup> However, as these lenses land exclusively in the sclero-conjunctival tissue, it is also relevant to assess objectively the mechanical impact of the scleral lens compression on the bulbar conjunctival as a result of lens misalignment or external sources of mechanical compression.<sup>29</sup> Although with no statistical significant differences, this pilot study found that the short-term ScCL wear (3 h) caused some changes in sclero-conjunctival tissue. Table 2 shows that after 3 h of lens wear there is an augment in OC-SAG at all the chords analyzed, meaning that these regions became steeper (deeper), namely at 15 and 16 mm. This steepening could be related to the ScCL “footprint” on the sclero-conjunctiva due to compression of the tissue. Fig. 5 also demonstrates some differences in tangent angles through different chord lengths. The differences in sclero-conjunctiva were more pronounced in the nasal region. This is coincidental with the clinical observations of stronger mechanical pressure of ScCL

in this area (since the nasal region is, on average, flatter than the other meridians).

It is already known (from OCT studies) that there is a tissue thinning/compression over all quadrants after 3 h of mini-ScCL wear.<sup>30</sup> A study from Consejo et al.<sup>31</sup> that aimed to quantify the effect of short-term (5 h) scleral lens wear on sclero-conjunctival topography (with ESP) also concluded that the anterior eye surface was significantly modified by short-term scleral lens wear – an increment in the limbal radius and a flattening in the sclero-conjunctiva was observed. These alterations in the ocular surface were previously found after short-term soft contact lens wear, though of smaller magnitude.<sup>32</sup> They also repeated the measures 3 h after lens removal and concluded that these changes did not recede to baseline values over that period. The tissue thinning found by Alonso-Carneiro et al. also did not recovered to baseline values 3 h after lens removal.<sup>30</sup> The time necessary for the sclero-conjunctiva to return to its normal shape is still unknown and should be studied in future studies to better understand the mechanical response of the scleral-conjunctival tissue during ScCL wear. A major limitation of previous studies that aimed to quantify the sclero-conjunctival changes after contact lens wear is the limited chord lengths analyzed. The present study adds an important contribution as different chord lengths are analyzed in 0.5 mm steps



(Fig. 5). In this way, it is not only possible to conclude that there is an alteration in sclero-conjunctival topography but also perceive which areas have the greatest changes during scleral lens wear. As seen on Figs. 5 and 6 regions nearest the limbus become steeper after ScCL wear and then is seen a flattening in tangent angles (between 7 and 7.5 mm nasal and 7.5 and 8 mm in temporal). The authors hypothesize that this is related with the landing zone of the lens. Due to anatomical factors, scleral lenses tend to decenter inferiorly and temporally. Because of that, the landing zone of ScCL will be closer to the limbus on the nasal region than on temporal region – that's why the flattening is seen at different chord lengths in both regions mentioned. The authors acknowledge that, contrary to what occurs when analyzing the results of Part I of the study, the evidence regarding the changes in sclero-conjunctiva after scleral lens wear could not be strong enough to draw clear conclusions, as there were no statistical significant differences between measurements and the standard deviations are quite high.

The authors recognize some other limitations in this study. Anatomical structure of the ocular surface and instrument capabilities limits the ability to take measurements at 8 or 8.50 mm in some subjects, particularly in the vertical direction, which leads to the higher values of standard deviations found. The authors ensure that at least 2 complete maps were obtained to process the data.

This is a preliminary study to further investigate the predictability role of scleral shape measurements (both OC-SAG and scleral tangent angles) to allow clinicians in the ScCL fitting process, as nowadays the most used method is trial-and-error (diagnostic lens set). When correlated to trial lens information and clinical evaluations, it is expected that the present findings will add valuable evidence to reduce the need to fit several trial lenses to achieve the best fitting, namely on unexperienced/novel fitters (Macedo-de-Araujo, submitted to publication). Although some authors have already considered this issue, further investigation needs to be done in order to investigate if ESP measurements can anticipate the areas of compression and correlate scleral anatomy parameters with the ideal lens parameters in order to improve the predictability of this increasingly popular fitting strategy. Also, it is important to know if these changes in scleral anatomy after short-term ScCL wear will maintain at the long term, as well as the time necessary for the sclero-conjunctiva to back to normal values after ScCL removal.

In conclusion, ESP shows mild differences in scleral shape between eyes with regular and irregular corneas in agreement with previous studies. The preliminary results of this study suggest that the short-term scleral lens wear alters the sclero-conjunctival topography, and that the areas where the changes are more pronounced may be related to the landing zone of the scleral lens. ESP might be valuable in quantifying the mechanical impact of the ScCL on the perilibal bulbar conjunctival.

## Disclosure

This project was supported in part by an unrestricted grant from Bausch & Lomb (Rochester, USA) and the European Fund for Regional Development (FEDER) through

the COMPETE Program and by the Portuguese Foundation for Science and Technology (FCT) in the framework of projects PTDC/SAU-BEB/098391/2008, PTDC/SAU-BEB/098392/2008 and the Strategic Project PEST-C/FIS/UI607/2011. Authors declare that they do not have any proprietary or financial interest in any of the materials mentioned in this article.

## Conflicts of interest

The authors have no conflicts of interest to declare.

## Acknowledgement

Authors want to thank Eaglet Eye (Netherlands) for the loan of the Eye Surface Profiler used in this project.

## References

1. van der Worp E, Bornman D, Ferreira DL, Faria-Ribeiro M, Garcia-Porta N, González-Mejome JM. Modern scleral contact lenses: a review. *Cont Lens Anterior Eye*. 2014;37:240–250, <http://dx.doi.org/10.1016/j.clae.2014.02.002>.
2. Schornack MM. Scleral lenses: a literature review. *Eye Cont Lens*. 2015;41:3–11, <http://dx.doi.org/10.1097/ICL.0000000000000083>.
3. Kauffman MJ, Gilmartin CA, Bennett ES, Bassi CJ. A comparison of the short-term settling of three scleral lens designs. *Optom Vis Sci*. 2014;91:1462–1466, <http://dx.doi.org/10.1097/OPX.0000000000000409>.
4. Vincent SJ, Alonso-Caneiro D, Collins MJ. The temporal dynamics of miniscleral contact lenses: central corneal clearance and centration. *Cont Lens Anterior Eye*. 2018;41:162–168, <http://dx.doi.org/10.1016/j.clae.2017.07.002>.
5. Michaud L, van der Worp E, Brazeau D, Warde R, Giasson CJ. Predicting estimates of oxygen transmissibility for scleral lenses. *Cont Lens Anterior Eye*. 2012;35:266–271, <http://dx.doi.org/10.1016/j.clae.2012.07.004>.
6. Compañ V, Oliveira C, Aguilera-Arzo M, Molla S, Peixoto-de-Matos SC, González-Mejome JM. Oxygen diffusion and edema with modern scleral rigid gas permeable contact lenses. *Investig Ophthalmol Vis Sci*. 2014;55:6421–6429, <http://dx.doi.org/10.1167/iovs.14-14038>.
7. Sorbara L, Maram J, Mueller K. Use of the Visante™ OCT to measure the sagittal depth and scleral shape of keratoconus compared to normal corneas: pilot study. *J Optom*. 2013;6:141–146, <http://dx.doi.org/10.1016/j.optom.2013.02.002>.
8. Sorbara L, Maram J, Fonn D, Woods C, Simpson T. Metrics of the normal cornea: anterior segment imaging with the Visante OCT. *Clin Exp Optom*. 2010;93:150–156, <http://dx.doi.org/10.1111/j.1444-0938.2010.00472.x>.
9. Bandlitz S, Bäumer J, Conrad U, Wolffsohn J. Scleral topography analysed by optical coherence tomography. *Cont Lens Anterior Eye*. 2017;40:242–247, <http://dx.doi.org/10.1016/j.clae.2017.04.006>.
10. Iskander DR, Wachel P, Simpson PND, Consejo A, Jesus DA. Principles of operation, accuracy and precision of an eye surface profiler. *Ophthalmic Physiol Opt*. 2016;36:266–278, <http://dx.doi.org/10.1111/opo.12292>.
11. Piñero DP, Martínez-Abad A, Soto-Negro R, et al. Differences in corneo-scleral topographic profile between healthy and keratoconus corneas. *Cont Lens Anterior Eye*. 2018.
12. Visser E, Visser R, Van Lier HJJ. Advantages of toric scleral lenses. *Optom Vis Sci*. 2006;83:233–236, <http://dx.doi.org/10.1097/01.opx.0000214297.38421.15>.

13. Jesus DA, Kedzia R, Iskander DR. Precise measurement of scleral radius using anterior eye profilometry. *Cont Lens Anterior Eye*. 2017;40:47–52, <http://dx.doi.org/10.1016/j.clae.2016.11.003>.
14. Consejo A, Iskander DR. Corneo-scleral limbus demarcation from 3D height data. *Cont Lens Anterior Eye*. 2016;39:450–457, <http://dx.doi.org/10.1016/j.clae.2016.05.001>.
15. Consejo A, Llorens-Quintana C, Radhakrishnan H, Iskander DR. Mean shape of the human limbus. *J Cataract Refract Surg*. 2017;43:667–672, <http://dx.doi.org/10.1016/j.jcrs.2017.02.027>.
16. Consejo A, Radhakrishnan H, Iskander DR. Scleral changes with accommodation. *Ophthalmic Physiol Opt*. 2017;37:263–274, <http://dx.doi.org/10.1111/opo.12377>.
17. Vincent SJ, Kowalski LP, Alonso-Caneiro D, Kricancic H, Collins MJ. The influence of centre thickness on miniscleral lens flexure. *Cont Lens Anterior Eye*. 2018, <http://dx.doi.org/10.1016/j.clae.2018.07.003>.
18. Ritzmann M, Caroline PJ, Börret R, Korszen E. An analysis of anterior scleral shape and its role in the design and fitting of scleral contact lenses. *Cont Lens Anterior Eye*. 2017;41:205–213, <http://dx.doi.org/10.1016/j.clae.2017.10.010>.
19. Denaeyer G, Sanders DR, Van Der Worp E, Jedlicka J, Michaud L, Morrison S. Qualitative assessment of scleral shape patterns using a new wide field ocular surface elevation topographer: the SSSG study. *J Cont Lens Res Sci*. 2017;1:12–22.
20. van der Worp E, Denaeyer G, Caroline PJ. Understanding anterior ocular surface shape. In: Barnett M, Johns LK, eds. *Contemp. Scleral Lenses Theory Appl*. 1st ed. Betham Ebooks; 2018:68–87, <http://dx.doi.org/10.2174/97816810856611170401>.
21. Hall LA, Young G, Wolffsohn JS, Riley C. The influence of corneoscleral topography on soft contact lens fit. *Investig Ophthalmol Vis Sci*. 2011;52:6801–6806, <http://dx.doi.org/10.1167/iops.11-7177>.
22. van der Worp E, Denaeyer G, Caroline PJ. Understanding anterior ocular surface shape. In: Barnett M, Johns LK, eds. *Contemp. Scleral Lenses Theory Appl*. Bentham Science Publishers; 2017:68–86, <http://dx.doi.org/10.2174/97816810856611170401>.
23. Macedo-de-Araújo RJ, Amorim-de-Sousa A, Queirós A, van der Worp E, González-Méijome JM. Relationship of placido corneal topography data with scleral lens fitting parameters. *Cont Lens Anterior Eye*. 2018, <http://dx.doi.org/10.1016/j.clae.2018.07.005>.
24. van der Worp E. *Corneo-scleral angles and scleral angles. A guide to scleral lens fitting*; 2015:13–14.
25. Consejo A, Rozema JJ. Scleral shape and its correlations with corneal astigmatism. *Cornea*. 2018;37:1047–1052, <http://dx.doi.org/10.1097/ICO.0000000000001565>.
26. Soeters N, Visser ES, Imhof SM, Tahzib NG. Scleral lens influence on corneal curvature and pachymetry in keratoconus patients. *Cont Lens Anterior Eye*. 2015;38:294–297, <http://dx.doi.org/10.1016/j.clae.2015.03.006>.
27. Serramito-Blanco M, Carpena-Torres C, Carballo J, Piñero D, Lipson M, Carracedo G. Anterior corneal curvature and aberration changes after scleral lens wear in keratoconus patients with and without ring segments. *Eye Cont Lens*. 2018, <http://dx.doi.org/10.1097/ICL.0000000000000534>.
28. Vincent SJ, Alonso-Caneiro D, Collins MJ. Corneal changes following short-term miniscleral contact lens wear. *Cont Lens Anterior Eye*. 2014;37:461–468, <http://dx.doi.org/10.1016/j.clae.2014.08.002>.
29. Macedo-de-Araújo RJ, van der Worp E, González-Méijome JM. On-eye breakage and recovery of mini-scleral contact lens without compromise for the ocular surface. *Cont Lens Anterior Eye*. 2018;41:311–314, <http://dx.doi.org/10.1016/j.clae.2017.12.009>.
30. Alonso-Caneiro D, Vincent SJ, Collins MJ. Morphological changes in the conjunctiva, episclera and sclera following short-term miniscleral contact lens wear in rigid lens neophytes. *Cont Lens Anterior Eye*. 2016;39:53–61, <http://dx.doi.org/10.1016/j.clae.2015.06.008>.
31. Consejo A, Behaegel J, Van Hoey M, Wolffsohn JS, Rozema JJ, Iskander DR. Anterior eye surface changes following miniscleral contact lens wear. *Cont Lens Anterior Eye*. 2018, <http://dx.doi.org/10.1016/j.clae.2018.06.005>.
32. Consejo A, Bartuzel MM, Iskander DR. Corneo-scleral limbal changes following short-term soft contact lens wear. *Cont Lens Anterior Eye*. 2017;40:293–300, <http://dx.doi.org/10.1016/j.clae.2017.04.007>.