

# Extended Boari-flap technique as a reconstruction method of total ureteric avulsion

Paweł Grzególkowski, Artur Lemiński, Marcin Słojewski

*Department of Urology and Urological Oncology, Pomeranian Medical University, Szczecin, Poland*

**Citation:** Grzególkowski P, Lemiński A, Słojewski M. Extended Boari-flap technique as a reconstruction method of total ureteric avulsion. Cent European J Urol. 2017; 70: 188-191.

## Article history

Submitted: Oct. 13, 2016

Accepted: Jan. 21, 2017

Published online: March 15, 2017

## Corresponding author

Paweł Grzególkowski  
Department of Urology  
72, Powstańców Wlkp.  
70–111 Szczecin, Poland  
phone: +48 607 445 859  
lekpawelgrzegolkowski@gmail.com

Indication has led ureteroscopy to be a worldwide technique, with the expected appearance of multiple complications. The ureteral avulsion is an uncommon severe urological complication of ureteroscopy (URS). Surgery in patients with a total ureteral loss is a demanding challenge for urologist. It requires usually immediate open or laparoscopic intervention. This case report was to present the treatment modality after ureteral avulsion. We have presented a case of 58-year-old male patient who underwent a successful repair of an upper ureteral injury. We have comprehensively described the effectiveness of an extended Boari-flap procedure for reconstruction after iatrogenic ureteral trauma. Particularly in an unexpected and casual situations, the presented extended Boari flap modification can be a great alternative for reconstructing a total ureteral loss. In conclusion we have recommend useful tips, how to counteract such unwanted events.

**Key Words:** ureteroscopy ↔ intraoperative complications ↔ ureteral calculi

## CASE PRESENTATION

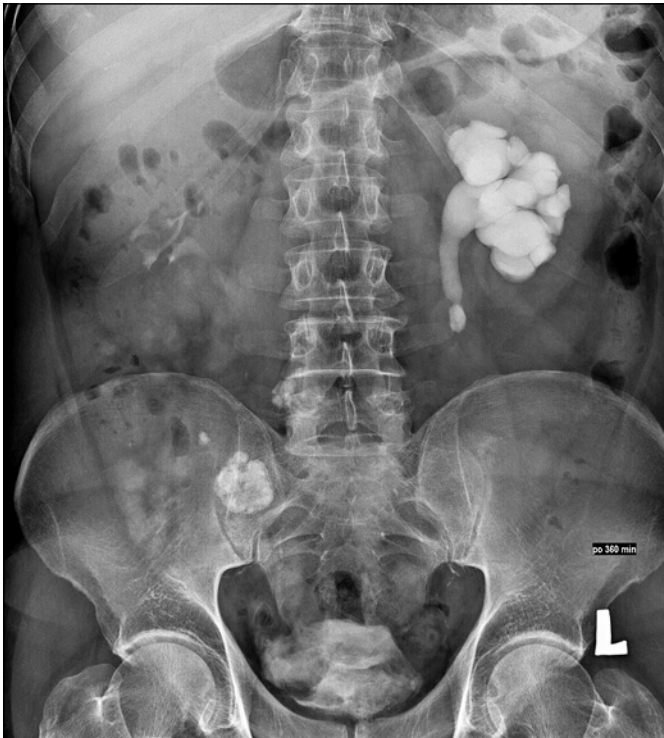
In 1980 Perez-Castro and Martinez-Pineiro introduced ureteroscopy (URS) and since that time it has evolved into a gold standard procedure for ureteral stones, and for numerous clinical conditions affecting the ureter and kidney [1]. The incidence of complications ranges from 9 to 11%, with the majority being iatrogenic. A total avulsion during URS is extremely rare and occurs in 0–0.3% cases [2].

A 58-year-old male patient was admitted for treatment of a left-sided ureteral stone in July 2015. The intravenous pyelography revealed a stone measuring 17x9 mm located in the upper left ureter (Figure 1). The ureter above the stone was dilated and hydronephrosis was present. Before admission, the patient underwent a nephrostomy drainage of his left kidney due to recurrent renal colic, which occurred after a single session of unsuccessful extracorporeal shock wave lithotripsy.

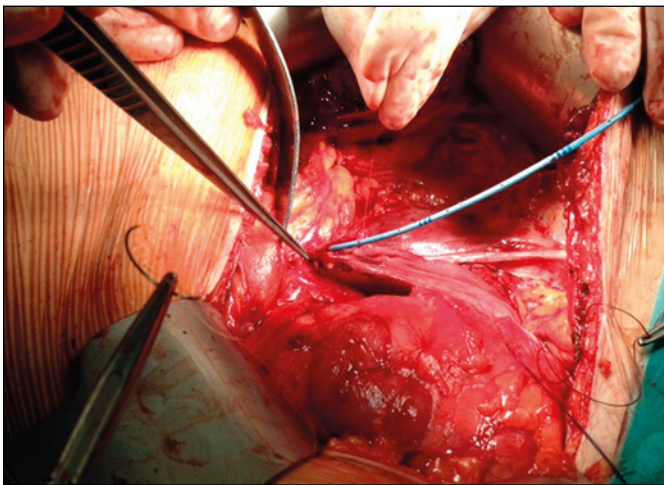
Primarily the patient was qualified for a push-up PCNL procedure. During ureteroscopy with 8F semi-rigid ureteroscope a stone was localized. Because of the stone size and its immobilization by the extensive swelling of the mucosa, the push-up attempt was unsuccessful. Intraoperatively, a decision was made to perform an in situ lithotripsy with a pneumatic device, which was successfully accomplished, with most fragments removed using an endoscopic grasper. The last fragment of the stone had migrated towards the renal pelvis and was later grasped above the level of its initial location. During the attempt of extraction, the operator realized that the ureteroscope was jammed in the upper ureter and a 'scabbard' avulsion was diagnosed after the ureteroscope was removed. An immediate repair attempt through a left side lumbotomy incision was made and the proximal end of the ureter just below the pyeloureteric junction was identified. In the first step,

a left kidney mobilization was performed to achieve the smallest gap possible. Afterwards, an extended length (22 cm) bladder flap was created to replace the missing ureteral fragment. Firstly, we filled the bladder to its maximal capacity with saline. Formation of an extended bladder flap involves the simultaneous usage of the anterior and left bladder wall. Consequently, this gave us the possibility to create an oblique 'tongue-like' bladder flap. Thereafter,

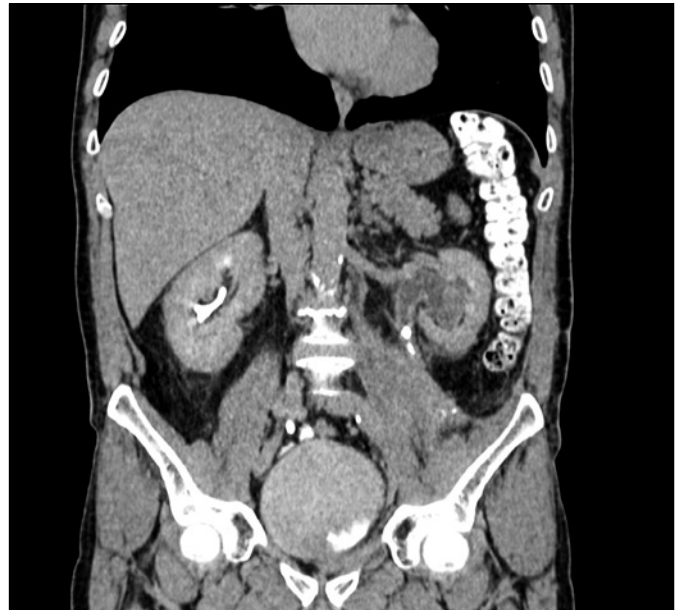a running watertight anastomosis with monofilament 4-0 suture has been accomplished over a 7F DJ stent (Figure 2). A Psoas-hitch technique was used to ensure a tension-free anastomosis and a double layer running 4-0 suture was used to tubularize the flap and to achieve a watertight reconstruction. The postoperative period was uneventful, with two days of bed rest advised. The maximum drain output was 200 ml on the 2<sup>nd</sup> day. On the 4<sup>th</sup>



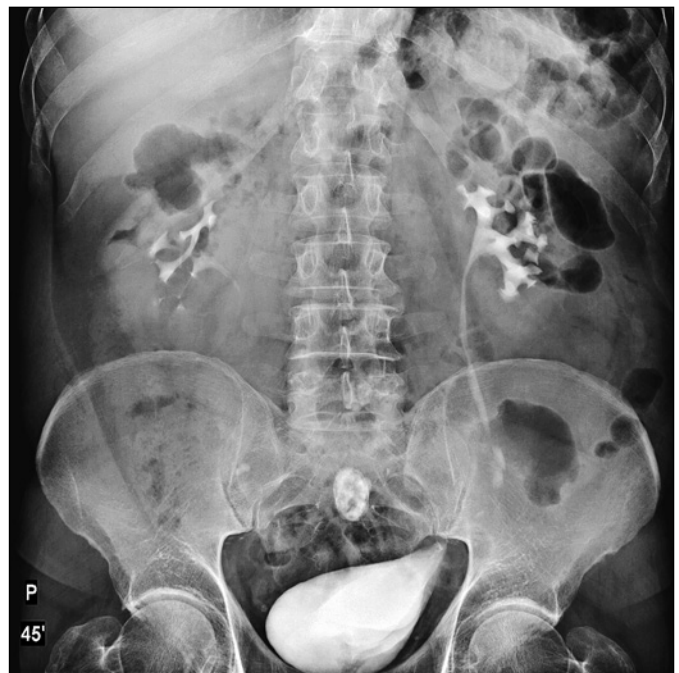**Figure 1.** An intravenous urography showing a calculus in the upper left ureter (17x9 mm).



**Figure 2.** Intraoperative view of an extended Boari flap procedure.



**Figure 3.** A postoperative CT scan (delayed phase).



**Figure 4.** A postoperative intravenous urography scan.

postoperative day, the patient was discharged home. A bladder catheter and nephrostomy tube remained in place for 11 days. The DJ catheter was kept in place for 8 weeks.

After removal of the DJ, a postoperative CT and intravenous urography was performed (Figures 3 and 4) (delayed phase). The results revealed a residual stone, causing blockade of the ureter at the level of anastomosis and a left side hydronephrosis. Subsequently the patient was again qualified for a push-up PCNL. During retrograde pyelography, an hourglass shaped stenosis at the level of anastomosis was found. Passage with the rigid ureteroscope was not possible due to the psoas-hitch causing lateral fixation of the ureteral graft. A guidewire was placed through the stenosis, and a ureteral catheter was used to successfully accomplish a push-up procedure. Finally, a tubeless PCNL was made and a DJ stent was placed using an antegrade approach. We chose to leave the ureter stented for 3 months. No complications occurred. After 3 months, the DJ stent was removed and mild hydronephrosis was observed. However, no physical discomfort or loss of renal function was indicated.

## DISCUSSION

The first cases of avulsion were reported by Hart and Hodge, after manipulation with the Dormia basket. The risk factors for avulsion include previous manipulations and larger stone burden. Furthermore, a proximal stone location, with previous ESWL treatment increases the risk of complications, which was proved by Fuganti et al. [3]. In addition, Martin et al. [4] showed that use of a rigid ureteroscope might also constitute a risk factor. In our case, the damage was likely a result of primary ureteral cause (the weakening of ureteral wall at the level of stone impaction) and improper handling of the instruments. The mechanism of injury involves the excessive stretching of the ureter that ruptures in the weakest area (degloving injury). Traditionally, ureteral avulsion has been managed surgically, with the reconstructive technique being dependent on the length and location of the injury. In distal ureteral involvement, ureteroneocystostomy is usually the treatment of choice. A mid-ureter injury may require a psoas hitch or a Boari flap procedure. Proximal trauma may be repaired well with an end-to-end anastomosis over a DJ stent, provided the distal part of the ureter remains intact. Finally, in cases

**Table 1.** Reconstruction options by site of injury

	Uteroureterostomy
Upper ureter	Transureteroureterostomy
	Ureterocalicostomy
	Uteroureterostomy
Mid ureter	Transureteroureterostomy
	Ureteral reimplantation and a Boari flap
	Ureteral reimplantation
Low ureter	Ureteral reimplantation with a psoas hitch
	Ileal interposition graft
Complete	Autotransplantation

of extensive ureteral injury with significant loss of tissue, ileal interposition or renal autotransplantation is usually required [5] (Table 1). In the presented case, a modification of the Boari flap technique was implemented and an extended length flap of bladder wall was used to replace the entire ureter and to create a watertight, tension-free anastomosis. Previous publications indicated that Boari flap and Psoas hitch techniques are used in the reconstruction of partial (mid or distal) ureteral injury. Also, a conventional Boari flap can be created to bridge up to 15 cm of ureteral defect. Furthermore, the aforementioned reconstruction attempts were conducted in conditions allowing for planning ahead. We have shown a significant value of our modification comparing to autotransplantation or ileal graft, especially in cases of intraoperative repair, not mentioning the significant limitations and disadvantages of those procedures. Our operation can be successfully performed in a single urological center and also requires no additional preparations such as bowel preparation or additional patient agreement.

In conclusion, ureteral injury prevention is the most rewarding. In our opinion, the presented extended Boari flap modification can be a great alternative for reconstructing a total ureteral loss particularly in unexpected and immediate situations. Finally, we recommend that a ureteroscope should never be forcefully manipulated. In counteracting the risks of unwanted events use a safety guidewire and a small-caliber flexible endoscope.

## CONFLICTS OF INTEREST

The authors declare no conflicts of interest.

---

**References**

---

1. D'Addessi A, Bassi P. Ureterorenoscopy: avoiding and managing the complications. *Urol Int.* 2011; 87: 251-259.
2. Unsal A, Oguz U, Tuncel A, et al. How to manage total avulsion of the ureter from both ends: our experience and literature review. *Int Urol Nephrol.* 2013; 45: 1553-1560.
3. Fuganti PE, Pires S, Branco R, Porto J. Predictive factors for intraoperative complications in semirigid ureteroscopy: analysis of 1235 ballistic ureterolithotripsies. *Urology.* 2008; 72: 770-774.
4. Martin X, Ndoye A, Konan PG, et al. Hazards of lumbar ureteroscopy: apropos of 4 cases of avulsion of the ureter. *Prog Urol.* 1998; 8: 358-362.
5. Trinchieri A, Montanari E, Salvini P, Berardinelli L, Pisani E. Renal autotransplantation for complete ureteral avulsion following lumbar disk surgery. *J Urol.* 2001; 165: 1210-1211. ■