

Malignant peripheral nerve sheath tumor presenting as orbito temporal lump: Case report and review of literature

Souvagya Panigrahi, Sudhansu S. Mishra, Sanjib Mishra¹, Srikant Das

Department of Neurosurgery, S.C.B. Medical College and Hospital, Cuttack, ¹Department of Neurosurgery, V.S.S. Medical College and Hospital, Burla, Odisha, India

ABSTRACT

Malignant peripheral nerve sheath tumor (MPNST) is a rare soft tissue sarcoma. The most common anatomical sites include the upper and lower extremities and trunk and less commonly the head and neck. To our knowledge, few patients with a cranial or facial MPNST have been reported. We report such a lesion in a 35-year-old woman who presented with left sided rapidly progressive proptosis and visual loss due to an orbital lump extending up to the temporal lobe. Cranial imaging showed a huge mass invading the orbital wall and temporal bone. The presumptive diagnosis was a malignant orbital tumor. Preoperative fine needle aspiration cytology of the orbital mass came to be neurofibroma. Near total resection of the tumor was done. Histopathology revealed MPNST which was subsequently confirmed on the basis of immunopositivity for S-100. The patient recovered uneventfully and was discharged 8 days after surgery with an advice to attend cancer institute for possible radiotherapy.

Key words: Malignant peripheral nerve sheath tumor, orbito-temporal lump, S-100

Introduction

Malignant peripheral nerve sheath tumor (MPNST) is a rare soft tissue sarcoma of the ectomesenchymal origin. It is the malignant counterpart of benign soft tissue tumors like neurofibromas and schwannomas and may follow them. It usually arises from peripheral nerves or somatic soft tissues.^[1] Common sites include deeper soft tissues, usually in the proximity of a nerve trunk. MPNSTs can develop in any anatomical region, but the sciatic nerve is affected most often.^[2] MPNSTs involving the head and face are extremely rare. Few MPNSTs involving the orbit have been reported till date. The incidence of MPNST in the general population is 0.001% however, it can increase to 5-42% in patients with neurofibromatosis type 1. MPNST arising de-novo at an unusual

site without any features of neurofibromatosis type 1 as has been noticed in our case is interesting to report.

Case Report

A 35-year-old woman presented with two month history of a swelling in her left eye which increased rapidly in size to involve the left temporal region. Within this period she developed rapidly progressive proptosis and blurring of vision leading to complete blindness. Also the patient had no pain at the time of presentation and no history of swelling at any other site of body was present.

Upon physical examination, there was a lobular firm, nontender mass of size 15 × 7 cm, extending from left orbit to the left temporal region. In addition to axial proptosis, the left eye showed restricted movement in all directions. Her palpebras exhibited prominent chemosis [Figure 1]. She was unable to perceive light in her left eye. Her cornea was intact. The round pupil was 6mm across and sluggishly reactive to light. The disc of the left optic nerve was edematous. On extensive examination there were no subcutaneous swellings, café au lait spots or Lisch nodules. Computed tomography (CT) scan showed large lobulated extra-axial mass arising from left sphenoid wing and temporal lobe apex; extending into lateral extra-coanal space of left orbit and temporal fossa destroying temporal lobe [Figure 2]. Magnetic resonance imaging (MRI) of the orbits and brain with and without contrast enhancement showed left sphenoidal

Access this article online	
Quick Response Code:	Website: www.asianjns.org
	DOI: 10.4103/1793-5482.145065

Address for correspondence:

Dr. Souvagya Panigrahi, Department of Neurosurgery, S.C.B. Medical College and Hospital, Cuttack, Odisha, India.
E-mail: souvagya.ms@gmail.com

based extra-axial marginated in-homoginously enhancing mass at the lateral side of the left optic nerve buckling the ipsilateralantero temporal lobe [Figure 3]. Other systemic observations of the patient were normal. No evidence of any distant metastasis was found on clinical or radiologic evaluation.

On this occasion, the tumor was exposed through a left lateral orbitozygomatic approach. The tumor was highly vascularised, densely adhered to the zygomatic bone and had eroded the lateral orbital wall and temporal bone of left side. Optic sheath and the duramater of temporal lobe were intact. Near total dissection of the tumor was done with microsurgical technique. The histopathological diagnosis was MPNST [Figure 4a] which was subsequently confirmed on the basis of immunopositivity for S-100. Immunohistochemically, tumoral cells were positive for S-100 [Figure 4b]. Smooth muscle actin, desmin, Leu 7 and myelin basic protein (MBP) were all negative. Postoperatively, the patient recovered rapidly. Post-operative CT scan showed minimal residual mass in the orbit [Figure 5]. At discharge, she had improved cosmeses with stable neurological status [Figure 1c]. Vision in her left eye improved to finger counting at one meter and

extra-ocular movements were normal. She was further referred to the cancer institute where she received external beam radiotherapy. On one year follow-up, the patient is doing well with no local recurrence or any distant metastasis.

Discussion

Malignant peripheral nerve sheath tumor (MPNST) is the preferred term for tumors originating from peripheral nerves or their sheaths and it has replaced the previous entities such as malignant schwannoma, malignant neurilemmoma and neurofibrosarcoma. They represent approximately 10% of all soft tissue sarcomas.^[3] They may arise spontaneously, although in 5% to 42% of cases an association with neurofibromatosis (NF) type 1 is known. MPNSTs commonly arise in adult patients ranging from 20 to 50 years of age. They originate from a major or minor peripheral nerve branch or its sheath. The common sites of origin include the extremities and trunk, usually sciatic nerve, brachial plexus and the sacral plexus. To our knowledge, few patients with a cranial or facial MPNST have been reported.^[1,4] Likewise, cranial nerves are rarely affected, although tumors of the trigeminal and acoustic nerves have been reported.^[5]

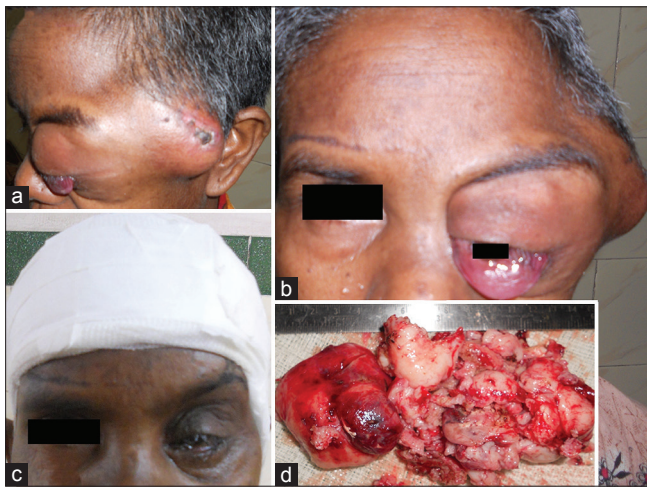

Figure 1: Pre-operative photograph (a and b) Orbito temporal lump with proptosis. Post-operative cosmesis (c) and excised tumor mass (d)

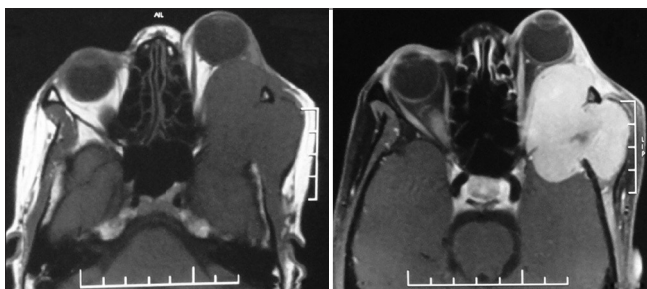


Figure 3: MRI scan of the orbit and brain with and without contrast enhancement showed left sphenoidal based extra-axial marginated in-homoginously enhancing mass at the lateral side of the left optic nerve buckling the ipsilateralantero temporal lobe

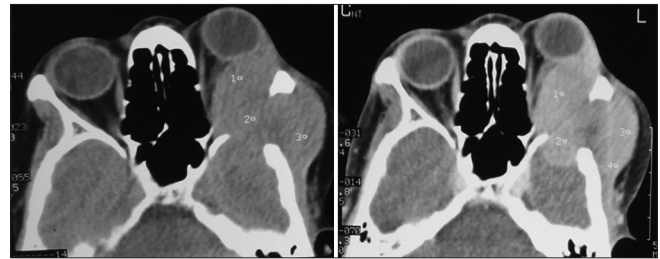


Figure 2: Pre-operative CT scan brain plain and contrast in axial view shows a large lobulated extra-axial mass arising from left sphenoid wing and temporal lobe apex; extending into lateral extra-coanal space of left orbit and temporal fossa destroying temporal lobe

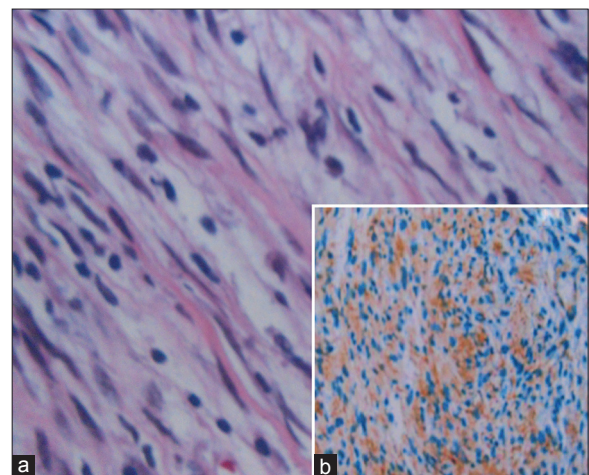


Figure 4: Histopathology picture showing fascicles of spindle cells with marked hypercellularity and high mitotic activity suggestive of MPNST (a) S-100 protein staining of the tumor tissue (b)

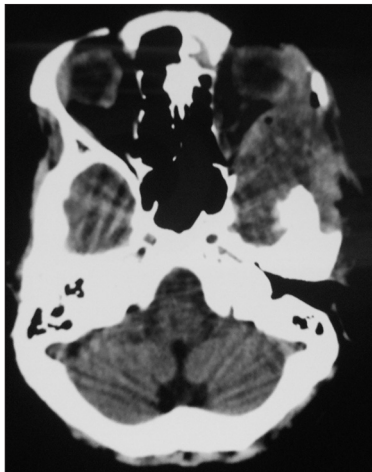


Figure 5: CT scan of brain one month following surgery showing minimal residual mass in the orbital region

Most cases are large, fleshy, often necrotic neoplasms averaging more than 5 cm in diameter.^[6] MPNSTs are fusiform to globular in shape and vary from white and firm to yellow and soft, depending on the absence or presence of necrosis. Although the tumors usually appear well circumscribed, they are not truly encapsulated. The tumor in our case was greyish white, firm, 14 cm in diameter with hemorrhage and necrosis [Figure 1d].

The histologic features of MPNSTs are those of a highly cellular, spindle-cell neoplasm resembling a soft-tissue sarcoma, but with differentiation toward elements of the nerve sheath, Schwann cell, and perineural cell.^[7] Frequent mitoses and focal necrosis are typical. Rarely are heterologous mesenchymal or epithelial elements present. As in our case, MPNSTs can include heterologous mesenchymal and epithelial elements. Such atypical components show hypercellularity, an increased nuclear-to-cytoplasmic ratio, cytological atypia, and increased mitotic activity.^[8] The histologic spectrum of MPNST is broad and the diagnosis rests on combination of some microscopic features, none of which is diagnostic by itself. S-100 protein, the most widely used antibody for nerve sheath tumor, is positive only in 50% of MPNSTs.^[9] Another diagnostic, Leu 7 immunoreactivity is reported to be positive in 30-40% of the cases.^[9] Our case showed immunopositivity with S-100 protein and was negative for other schwann cell markers. Data suggest that Leu-7 is an important marker of Schwann cell neoplasms, although it is not superior to S-100 protein. Moreover, combined immunohistochemical evaluation of potential Schwann cell markers including Leu-7, MBP, GFAP, and LN3 using commercially available antibodies offers no advantage over analysis of S-100-protein immunoreactivity alone.^[10]

Metastases occur in 39% of patients. The most common metastatic site being the lung. The most important features adversely influencing prognosis are the presence of

von Recklinghausen's disease, a tumor larger than 5 cm and extent of resection.^[11]

Radio imaging is helpful to know the exact site and extension of the tumor. Biopsy is necessary to diagnose an MPNST definitively. The differential diagnosis between benign schwannoma and neurosarcoma may be challenging: One must look for necrotic foci, the number of atypical mitoses, and an absence of differentiated cells. Tumors larger than 5 cm, histological grades II and III, an association with neurofibromatosis, and regional or distant metastases suggest an ominous prognosis.

The treatment of choice is surgery, but postoperative radio- and chemotherapy are part of adjunctive therapy.^[12] Gross total resection of the tumor is the most important therapeutic goal. When radical tumor removal is not possible, excision combined with high-dose radiation therapy seems to be the best alternative treatment.^[11] With the latest advances in molecular genetics, the target therapy for this tumor type is expected to be discovered.^[13]

Conclusion

MPNST can arise in rare locations like the orbito-temporal region. Existence neurofibromatosis may not be present. Suspicion of MPNST should be raised in rapidly growing painless tumor in and around a nerve tissue. Complete surgical removal should be the goal of treatment with definitive histological diagnosis.

References

1. D'Agostino AN, Soule EH, Miller RH. Sarcomas of the peripheral nerves and somatic soft tissue associated with multiple neurofibromatosis (von Recklinghausen's disease). *Cancer* 1963;16:1015-27.
2. Kchouk M, Rabet AM, Ghedas K, Nagi S, Douik M, Ben Romdhane K, *et al.* Extensive malignant schwannoma of the sciatic nerve. Contribution of imaging techniques [in French]. *J Radiol* 1993;74:641-4.
3. Weiss SW, Goldblum JR. Malignant tumors of the peripheral nerves. In: Strauss M, Grey L, editors. *Enzinger and Weiss's soft tissue tumors*. 4th ed. St. Louis: Mosby, Inc; 2001. p. 1209-64.
4. Aydin MD, Yildirim U, Gundogdu C, Dursun O, Uysal HH, Ozdikici M. Malignant peripheral nerve sheath tumor of the orbit: Case report and literature review. *Skull Base* 2004;14:109-13.
5. Han DH, Kim DG, Chi JG, Park SH, Jong HW, Kim YG. Malignant triton tumor of the acoustic nerve: Case report. *J Neurosurg* 1992;76:874-7.
6. Ducatman BS, Piepgras DG, Reiman HM, Ilstrup DM. Malignant peripheral nerve sheath tumors. A clinicopathologic study of 120 cases. *Cancer* 1986;57:2006-21.
7. Chitale AR, Dickersin GR. Electron microscopy in the diagnosis of malignant schwannomas. A report of six cases. *Cancer* 1983;51:1448-61.
8. Enzinger FM, Weiss SW. *Soft tissue tumors*. St. Louis, MO: CV Mosby; 1983. p. 625-54.
9. Rosai J. Soft tissues. In: Ackerman R, editor. *Surgical Pathology*. Philadelphia: Mosby; 2004. p. 2237-371.
10. Johnson MD, Glick AD, Davis BW. Immunohistochemical evaluation of Leu-7, myelin basic-protein, S-100-protein, glial-fibrillary acidic-protein, and LN3 immunoreactivity in nerve sheath tumors and sarcomas. *Arch Pathol Lab Med* 1988;112:155-60.
11. Barbara SD, Bernd WS, David GP, Herbert MR, Duane MI. Malignant peripheral nerve sheath tumors. *Cancer* 1986;57:2006-21.

12. Aguiar Vitacca S, Sarrazin D, Henry-Amar M, Henry-Amar M, Spielmann M, Genin J, *et al.* Neurosarcoma associated with von Recklinhausen disease: Apropos of 25 cases observed at the Gustave Roussy Institute from 1967 to 1990 [in French]. *Bull Cancer* 1992;79:101-12.
13. Ferner RE, Gutmann DH. International consensus statement on malignant peripheral nerve sheath tumors in neurofibromatosis. *Cancer Res* 2002;62:1573-7.

How to cite this article: Panigrahi S, Mishra SS, Mishra S, Das S. Malignant peripheral nerve sheath tumor presenting as orbito temporal lump: Case report and review of literature. *Asian J Neurosurg* 2016;11:170-1.

Source of Support: Nil, **Conflict of Interest:** None declared.