

Cutaneous Eruption due to Telaprevir

Eduardo Mastrangelo Marinho Falcão^a Beatriz Moritz Trope^a
Mariana Marteleto Godinho^a Leonardo Hoehl Carneiro^b
João Marcello de Araujo-Neto^c Cristiane Alves Villela Nogueira^c
Marcia Ramos-e-Silva^a

^aSector of Dermatology and Post-Graduation Course, ^bSector of Pathology, and ^cSector of Medical Clinics, University Hospital and School of Medicine, Federal University of Rio de Janeiro, Rio de Janeiro, Brazil

Key Words

Hepatitis C · Telaprevir · Drug eruption

Abstract

Hepatitis C virus (HCV) chronically infects 0.5–3% of the world population. A large group of patients develop cirrhosis and its complications. Since 2011, telaprevir and boceprevir are used, improving the disease evolution. One of the main side effects of these drugs is skin eruption. We report a 53-year-old patient with cirrhosis due to HCV who started the classic treatment associated with telaprevir. In the ninth week, he presented a severe rash that required the interruption of this drug. We emphasize the importance of early recognition and appropriate management of adverse skin reaction.

© 2015 The Author(s)
Published by S. Karger AG, Basel

Introduction

Hepatitis C virus (HCV) chronically infects 0.5–3% of the world population [1]. Acute infections are usually asymptomatic, and, after contact, about 80% of patients develop chronic hepatitis with a significant group developing cirrhosis and its complications [1, 2].

In recent years, new drugs have been developed, allowing an improved response to the treatment. Telaprevir and boceprevir are inhibitors of the serum protease HCV NS3/4A and are commercially available since 2011 in several countries for the treatment of chronic infections by genotype 1 HCV [3, 4], which is the most prevalent. One of the main side effects caused by these drugs is skin eruption, usually mild or moderate [5].

Case Report

A 53-year-old male patient with genotype 1 HCV cirrhosis (Child-Pugh A5), who had never undergone previous treatment for the disease, was treated with alfa-Peg-interferon in a single 180- μ g subcutaneous weekly dose associated to 1,250 mg oral ribavirin per day and 750 mg oral telaprevir 3 times daily.

After 4 weeks of treatment, a non-pruriginous erythematous macule was observed in the right inframammary region, which was treated with dexamethasone cream with improvement after 10 days.

In the ninth week, the patient presented nausea, associated to confluent pruriginous maculopapular eruption, affecting more than 50% of the body surface (fig. 1, fig. 2), showing lesions resembling a target on the trunk and limbs, enanthem and ulcers on the oral mucosa (fig. 3), as well as purpuric lesions on the legs (fig. 4). Clinical examination did not demonstrate other alterations.

A target lesion on the trunk and a purpuric lesion on the leg were submitted to biopsy, and the histopathological study evidenced lymphocytic perivascular infiltrate, with intense extravasation of red blood cells and endothelial hyperplasia, compatible with drug reaction (fig. 5, fig. 6).

Telaprevir was interrupted with maintenance of alfa-Peg-interferon and ribavirin until the end of the proposed treatment (48 weeks). Orobase triamcinolone was applied to the lesions of the oral mucosa and clobetasol cream to the cutaneous lesions with resolution of the eruption after 15 days without evidence of unbalance of the hepatic cirrhosis.

Twelve to 24 weeks after the end of the treatment, PCR-HCV remained negative and the patient did not present recurrence of the cutaneous lesions.

Discussion

Until recently, hepatitis C treatment was restricted to the use of alfa-Peg-interferon associated to ribavirin [6]. Treatment success is measured by the sustained virologic response, defined as an undetectable viral load 24 weeks after the end of the treatment [7]. This drug combination, applied for the period of 24–48 weeks, presents a sustained virologic response of around 40% in patients with genotype 1 virus [8].

Telaprevir and boceprevir began to be used commercially in several countries in association to the conventional treatment (alfa-Peg-interferon and ribavirin) for patients infected with genotype 1 HCV. They act as NS 3/4A protease inhibitors, increasing the sustained virologic response up to approximately 70%, depending on the viral and host characteristics [9].

However, these medications present several adverse effects, such as cutaneous eruption, anemia, and anal pruritus, among others [10].

Cutaneous eruptions have already been reported in the treatment with pegylated interferons and ribavirin, but the occurrence increases when inhibitors of the protease NS3/4A (telaprevir or boceprevir) are included in the therapeutic regimen [11–13]. Usually, the secondary cutaneous eruption to these medications presents as a pruriginous, erythematous macule and papule, with fine desquamation, affecting extensor surfaces of members and trunk [13]. There are reports of drug reaction with eosinophilia and systemic symptoms (DRESS), toxic epidermal necrolysis (TEN) and Stevens-Johnson syndrome (SJS) [5, 14–16].

The intensity of eruption is classified as follows: (1) mild, when the cutaneous involvement is localized, (2) moderate, when eruption is diffuse but affects less than 50% of the body surface and/or there is mucosal commitment without ulcers, and (3) severe, when

affecting over 50% of the body surface and/or presenting blisters, epidermal detachment, mucosal ulcers, target lesions or palpable purpura. [13].

In mild or moderate cases, treatment should be carried out with topic corticosteroids and antihistamines for control of the pruritus. It is necessary to discontinue telaprevir or boceprevir in severe cases, and it is important to carry out a strict clinical follow-up of the patient. When there is no improvement, interruption of the remaining drugs should be assessed (fig. 7) [17].

In patients with a rapid progression of the lesions, facial edema, vesicles or bulla, mucosal ulcers in more than one location, eosinophilia, high levels of transaminases or persistent fever, the diagnosis of DRESS or SSJ should be considered. The need for hospitalization should also be considered and the three drugs should be immediately discontinued [13, 14].

There are no specific characteristics described for eruption due to telaprevir. Other causes related or not to medication should also always be investigated for the skin lesions. Some diseases such as cryoglobulinemia, polyarteritis nodosa and erythema multiformis are commonly seen in association with hepatitis C [10]. Skin biopsy is also not specific, but it is important for the differential diagnosis with other causes of vasculitis, infectious exanthemas or autoimmune diseases [15].

New medications for the treatment of chronic hepatitis C are already available in some countries and present fewer side effects, besides providing a sustainable virologic response, superior to the treatment with protease NS3/4A inhibitors [18, 19].

Conclusion

Despite the development of new drugs, telaprevir and boceprevir continue to be alternatives for treatment of hepatitis C in many health units in Brazil. Multidisciplinary follow-up is important, enabling the recognition and early handling of side effects, especially adverse dermatological events that might put the patient's life at risk.

Statement of Ethics

The authors state that they complied with the guidelines for human studies and animal welfare regulations and that our patient gave his informed consent.

Disclosure Statement

The authors have no conflict of interest for this publication.

References

- 1 Marinho RT, Barreira DP: Hepatitis C, stigma and cure. *World J Gastroenterol* 2013;19:6703–6709.
- 2 Fattovich G, Stroffolini T, Zagni I, Donato F: Hepatocellular carcinoma in cirrhosis: incidence and risk factors. *Gastroenterology*. 2004;127(5 suppl 1):S35–S50.
- 3 Sy T, Jamal MM. Epidemiology of hepatitis C virus (HCV) infection. *Int J Med Sci* 2006;3:41–46.
- 4 FDA Antiviral Drugs Advisory Committee: Telaprevir Briefing Document. 2011. <http://www.fda.gov/downloads/AdvisoryCommittees/CommitteesMeetingMaterials/Drugs/AntiviralDrugsAdvisoryCommittee/UCM252562.pdf> (accessed April 10, 2015).

- 5 Roujeau JC, Mockenhaupt M, Tahan SR, et al: Telaprevir-related dermatitis. *JAMA Dermatol* 2013;149:152–158.
- 6 Wandeler G, Dufour JF, Bruggmann P, Rauch A: Hepatitis C: a changing epidemic. *Swiss Med Wkly* 2015;145:w14093.
- 7 Pearlman BL, Traub N: Sustained virologic response to antiviral therapy for chronic hepatitis C virus infection: a cure and so much more. *Clin Infect Dis* 2011;52:889–900.
- 8 Manns MP, McHutchison JG, Gordon SC, et al: Peginterferon alfa-2b plus ribavirin compared with interferon alfa2b plus ribavirin for initial treatment of chronic hepatitis C: a randomised trial. *Lancet* 2001;358:958–965.
- 9 Serrano BC, Manns MP. Telaprevir and boceprevir: the future is now. *Curr Hepatitis Rep* 2012;11:160–171.
- 10 Shiraishi M, Umebayashi I, Matsuda H, Sawamura K, Okada A, Karino M, Nogami Y: Postmarketing surveillance of telaprevir-based triple therapy for chronic hepatitis C in Japan. *Hepato Res* 2015, Epub ahead of print.
- 11 Cacoub P, Bourlière M, Lübke J, et al: Dermatological side effects of hepatitis C and its treatment: patient management in the era of direct-acting antivirals. *J Hepatol* 2012;56:455–463.
- 12 Mistry N, Shapero J, Crawford RI: A review of adverse cutaneous drug reactions resulting from the use of interferon and ribavirin. *Can J Gastroenterol* 2009;23:677–683.
- 13 Ktujszo E, Parcheta P, Zarębska-Michaluk D, et al: Dermatologic adverse events of protease inhibitor-based combination therapy in patients with chronic hepatitis C. *J Dermatol Case Rep* 2014;8:95–102.
- 14 Shuster M, Do D, Nambudiri V: Severe cutaneous adverse reaction to telaprevir. *Dermatol Online J* 2015;21:pii: 13030/qt2zq8z9zt.
- 15 Mousa OY, Khalaf R, Shannon RL, Egwim CI, Zela SA, Ankoma-Sey V: Chronic hepatitis C therapy in liver cirrhosis complicated by telaprevir-induced DRESS. *Case Rep Med* 2014;2014:380424.
- 16 Chen ST, Wu PA: Severe cutaneous eruptions on telaprevir. *J Hepatol* 2012;57:470–472.
- 17 Picard O, Cacoub P: Dermatological adverse effects during genotype-1 hepatitis C treatment with the protease inhibitors telaprevir and boceprevir. Patient management. *Clin Res Hepatol Gastroenterol* 2012;36:437–440.
- 18 Sadler MD, Lee SS: Revolution in hepatitis C antiviral therapy. *Br Med Bull* 2015;113:31–44.
- 19 Klibanov OM, Gale SE, Santevecchi B: Ombitasvir/ paritaprevir/ ritonavir and dasabuvir tablets for hepatitis c virus genotype 1 infection. *Ann Pharmacother* 2015;49:566–581.

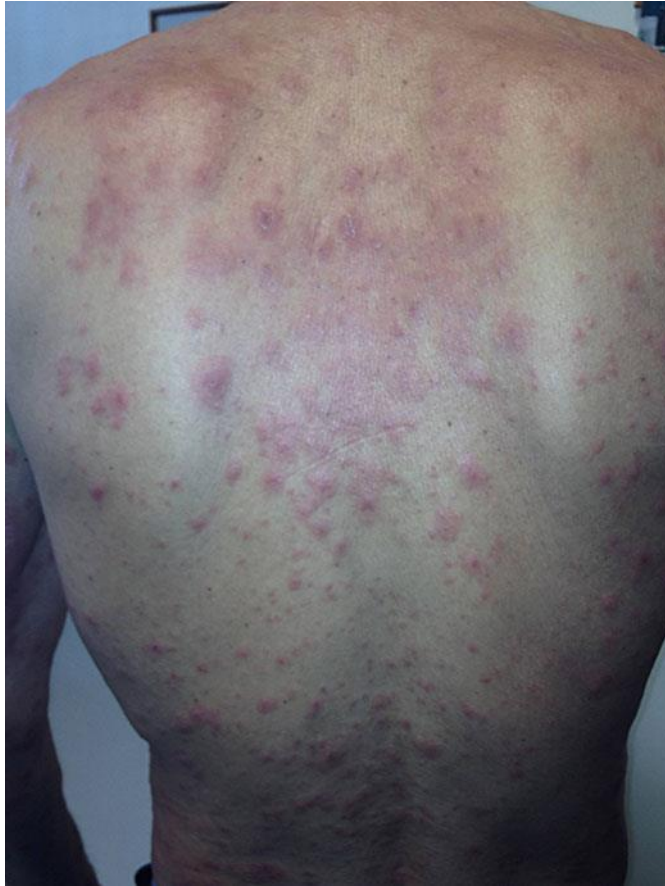

Fig. 1. Skin lesions on the back.

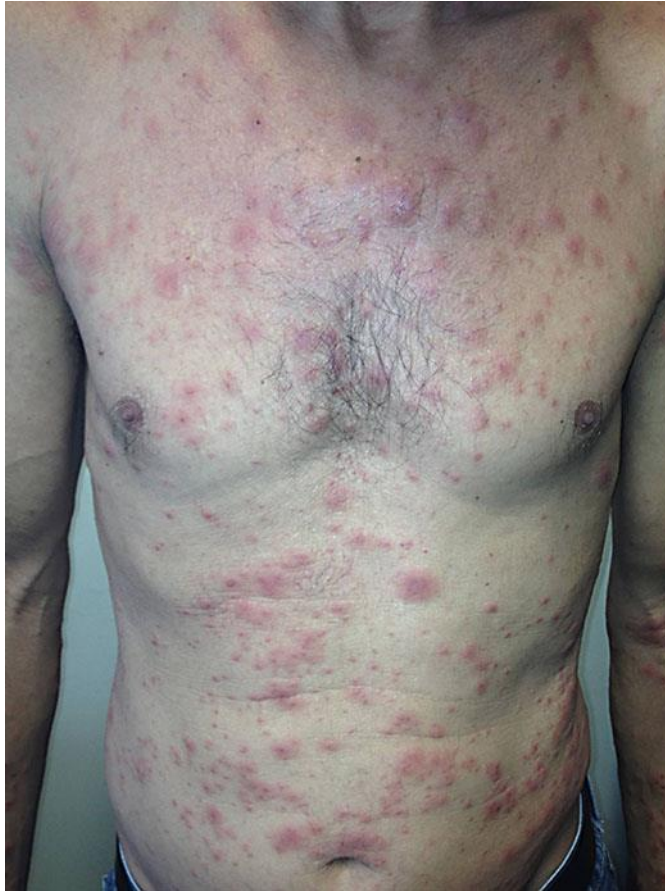

Fig. 2. Skin lesions on the chest.

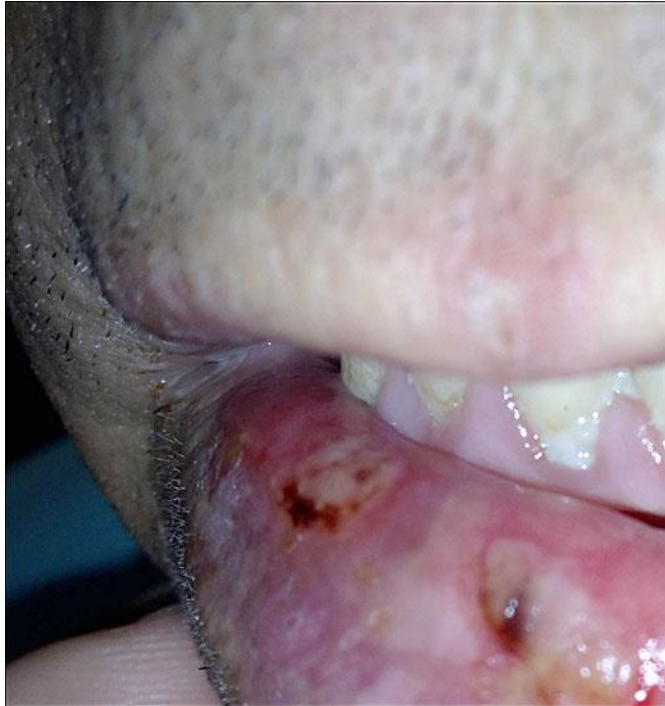

Fig. 3. Ulcers on the lower lip.

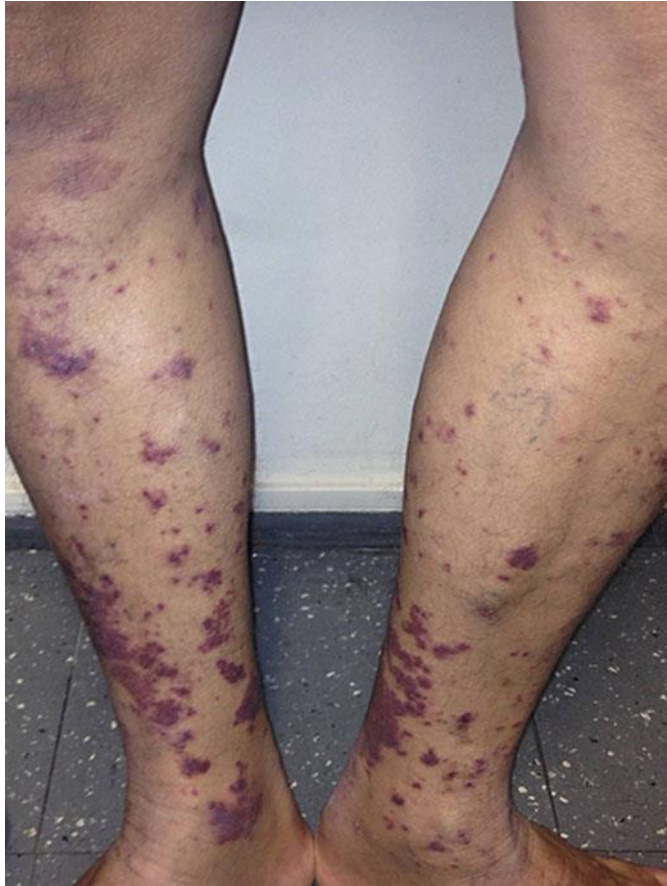

Fig. 4. Skin lesions on the legs.

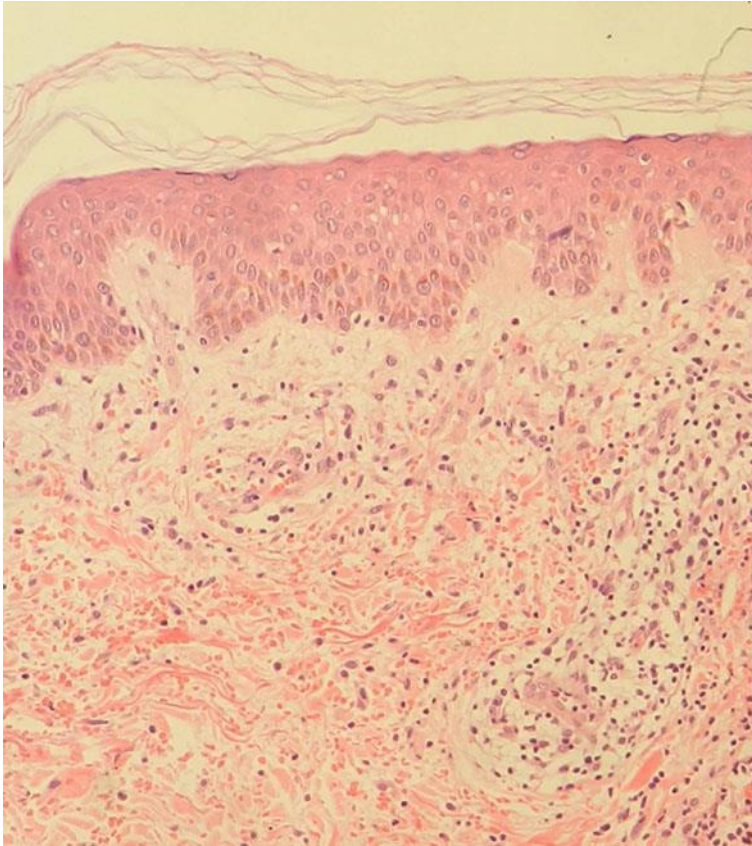

Fig. 5. Perivascular lymphocytic infiltrate, intense extravasation of red blood cells and endothelial hyperplasia, compatible with drug eruption. HE. Original magnification. $\times 100$.

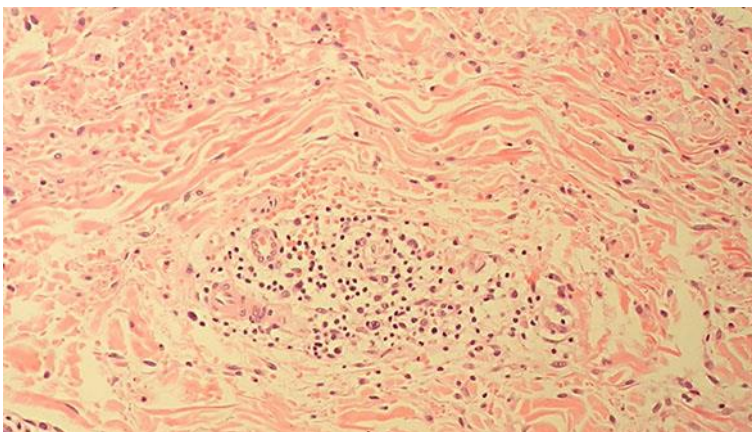


Fig. 6. Perivascular infiltrate at a higher magnification. HE. Original magnification. $\times 100$.

Classificação	Clínica	Manejo
Leve	Erupção localizada	Manter Telaprevir Corticosteroide tópico Anti-histamínico oral
Moderada	Erupção difusa (<50% da superfície corporal) Acometimento mucoso (sem úlcera)	Manter Telaprevir Corticosteroide tópico Anti-histamínico oral
Grave	Erupção difusa (>50% da superfície corporal) Úlcera mucosa Bolha/ Descolamento epidérmico Lesão em alvo Púrpura palpável	Interromper Telaprevir Corticosteroide tópico Anti-histamínico oral
SSJ/ DRESS	Progressão rápida Edema facial Bolhas Úlceras mucosas Eosinofilia Elevação das transaminases Febre persistente	Interromper as três drogas Internação hospitalar

Fig. 7. Skin adverse reaction to telaprevir: classification and management. Adapted from Cacoub et al. [11].