


## CLINICAL ARTICLE

# Are Both Preoperative Full-Spine 3Dimensional Computed Tomography Scans and X-Ray Films Necessary for Patients with Ankylosing Spondylitis Kyphosis?

Zhen Zhang, MD<sup>1,2</sup>, Chao Liu, MD<sup>3</sup>, Fanqi Hu, MD<sup>1,2</sup>, Yonggang You, MD<sup>1,2</sup>, Wenhao Hu, MD<sup>1,2</sup>, Xuesong Zhang, MD<sup>1,2</sup> 

<sup>1</sup>Medical School of Chinese PLA and <sup>2</sup>Department of Orthopedics, the Fourth Medical Centre, Chinese PLA General Hospital, Beijing and <sup>3</sup>Department of Orthopedics, The Second Affiliated Hospital Zhejiang University School of Medicine, Hangzhou, China

**Objective:** This study is aimed to investigate whether both pre-operative full-spine 3Dimensional computed tomography scan (3D CT) and X-ray film were necessary for patients with severe ankylosing spondylitis (AS) kyphosis deformity.

**Methods:** The research objects were selected from the inpatients with AS in our hospital from 2017 to 2019. A total of 42 patients were included in the study. On both the synthesized 2Dimensional (2D) lateral radiograph and X-ray film, the globe kyphosis (GK), the lumbar lordosis (LL), the thoracolumbar kyphosis (TLK) and the thoracic kyphosis (TK) were measured. And the angle seventh thoracic vertebra (T7), the angle twelfth thoracic vertebra (T12) and the angle third lumbar vertebra (L3) were also measured. Two researchers with professional medical education were randomly selected to perform the measurement method and record the measurement data. Two researchers independently completed, recorded, and evaluated the accuracy and consistency of the measurement data. This study used intraclass correlation coefficient (ICC) to analyze the synthesized 2D lateral radiograph and general X-ray film of 42 subjects by two researchers, in order to evaluate the consistency of data measurement results between the examiners. Through the comparison of the above parameters that the GK, LL, TLK, TK, angle T7, angle T12 and angle L3, the evaluation was made both pre-operative full-spine 3D CT and X-ray film were necessary for patients with severe AS kyphosis deformity.

**Results:** There was no significant difference between the GK, LL, TLK, TK, angle T7, angle T12, angle L3 on the synthesized 2D lateral radiograph and that on X-ray film ( $P = 0.240, 0.324, 0.199, 0.095, 0.421, 0.087, 0.478$ ). Agreement two researchers was excellent with ICC of the GK, LL, TLK, TK, angle T7, angle T12, angle L3 (0.977, 0.969, 0.986, 0.945, 0.947, 0.915, 0.857) on the synthesized 2D lateral radiograph. The Bland–Altman plot results that the measurement results of examiners are reliable and stable.

**Conclusion:** By estimating the degree of spinal sagittal imbalance and measuring the Cobb angle, we can see that full-length spine radiographs of the patients are unnecessary for patients with severe AS kyphosis deformity who will or have undergone preoperative spine 3D CT.

**Key words:** Ankylosing; Computerized tomography; Kyphosis; Spondylitis; X-Ray

**Address for correspondence** Chao Liu, Department of Orthopedics, The Second Affiliated Hospital Zhejiang University School of Medicine, 88 Jiefang Road, Shangcheng District, Hangzhou, 310009, Zhejiang, China. Email: [liuchaospine@163.com](mailto:liuchaospine@163.com); Xuesong Zhang, Department of Orthopedics, The Fourth Medical Center, Chinese PLA General Hospital, 51 Fucheng Road, Haidian District, Beijing, 100048, China Email: [zhangxuesong301@126.com](mailto:zhangxuesong301@126.com)  
Co-first author: Chao Liu and Fanqi Hu.

Received 8 May 2021; accepted 25 July 2022

## Introduction

Chronic back pain is common around the world and is cared for by a variety of providers, but there is usually a lack of specific and satisfactory treatment. Ankylosing spondylitis (AS) is an extreme form of inflammatory disease, which can lead to bone fusion of the spine and joints. It is a rare but recognized cause of chronic back pain. In the past decade, AS has been recognized as a subset of the more widespread and popular diagnostic entity, known as axial spondyloarthritis. Axial spondyloarthritis is similar to rheumatoid arthritis and is usually diagnosed and treated by rheumatologists; and there are special treatment methods. However, long term delays in diagnosis are common, often due to non-rheumatologists failure to recognize them.<sup>1</sup>

AS is a chronic rheumatic inflammatory disease involving sacroiliac joint, spine and spinal ligament and is an inflammatory arthritis of the axial skeleton, which mainly affects young men.<sup>2</sup> In addition, in the later stage of the disease, severe spinal deformity may occur, which usually leads to a significant decrease in quality of life and a limited field of vision, risking a loss of independence.<sup>3</sup> Late kyphosis results in impaired walking and standing ability, supine direct vision, and a decreased quality of daily life and social activities. Because ligaments can ossify at affected sites, fractures through the affected segment can cross the bone and ligaments, creating a highly unstable condition, which is similar to shear fractures. For pre-existing severe kyphosis, it may be dangerous to shift the patient to the supine position, which can open the fracture and lead to neurological complications.<sup>4-8</sup>

For patients with AS deformities, restoring the sagittal balance and chin-brow vertical angle may improve activity and quality of life.<sup>9,10</sup> Except for corrective surgery, there is no other treatment method that treats AS kyphosis deformities. Surgical intervention is the only effective and satisfactory method restoring patient's sagittal balance and horizontal gaze, and improving the patient's quality of life, including digestive function and sleep quality.<sup>11,13</sup> In 1945, Smith-Petersen *et al.* first reported the anterior opening wedge osteotomy technique.<sup>14</sup> Many other surgical techniques have been reported for treating AS kyphotic deformities, and all may achieve good clinical and radiographic outcomes as well as high patient satisfaction rates.<sup>5-15</sup> Many authors have reported good clinical and radiographic outcomes and higher patient satisfaction rate of surgical intervention.<sup>4-8</sup>

In planning for surgical treatment, full spine 3Dimensional computed tomography (3D CT) scans and X-ray were generally performed. However, with the development of 3D CT 3Dscan equipment and related software systems, synthesized 2D lateral radiographs of the full spine may be easily obtained. Whether the synthesized 2D lateral radiograph could play the same role as the general X-ray film did for patients with AS kyphosis deformity has not been determined. We hypothesized that, due to the character of stiff spine in patients with AS deformity kyphosis deformity, the

synthesized 2D lateral radiograph could play the same role as the general X-ray film did in assessing the Cobb angles for patients with AS kyphosis deformity; and the full-length spine radiographs of the patients are unnecessary for patients with severe AS kyphosis deformity who have underwent preoperative full spine 3D CT; the synthesized 2D lateral radiograph was reliable in measuring Cobb angle in patients with AS kyphosis deformity.

Hence, this present study is aimed at: (i) investigating whether both preoperative 3D CT and X-ray film are necessary for patients with severe AS kyphosis deformity; and (ii) whether the synthesized 2D lateral radiograph was reliable in measuring Cobb angle in patients with AS kyphosis deformity.

## Material and Method

### Patients

All materials were used with the consent of the inpatients with AS in our hospital from 2017 to 2019. The ethical approval was obtained from Ethics Committee Of Chinese PLA General Hospital (2021-323-01). We reviewed patients with AS kyphosis deformity who underwent surgical treatment at our institution. Inclusion criteria: (i) patients with AS kyphosis deformity; (ii) preoperative 3D CT scans of the full spine able to be performed; and (iii) full-length spine X-ray films able to be obtained; Exclusion criteria: (i) patients without other spine deformity; (ii) patients without a history of spine surgery; and (iii) patients without a history of spinal trauma. A total of 42 patients were eligible for this study.

### Radiographic Parameters

After the CT scans were performed, the full spine models were reconstructed, and then 2D lateral radiographs were synthesized by using these models. All spine models were projected to the sagittal position. On both the synthesized 2D lateral radiograph and X-ray film, globe kyphosis (GK), lumbar lordosis (LL), thoracolumbar kyphosis (TLK) and thoracic kyphosis (TK) were measured. GK was measured from the superior end plate of the fifth thoracic vertebra (T5) to the superior end plate of the first sacral vertebra (S1). LL was defined as the Cobb angle between the two lines parallel to the superior endplate of the first lumbar vertebra (L1) and the first sacral vertebra (S1). TLK was defined as the Cobb angle between the two lines parallel to the superior endplate of the eleventh thoracic vertebra (T11) and the inferior endplate of the second lumbar vertebra (L2). TK was defined as the Cobb angle between the two lines parallel to the superior endplate of T5 and the superior endplate of the fifth lumbar vertebra (L5). Lordosis was described as negative, and kyphosis was described as positive. Furthermore, the angle of the seventh thoracic vertebra (T7), the angle of the twelfth thoracic vertebra (T12) and the angle of the third lumbar vertebra (L3) were also measured on both the synthesized 2D lateral radiograph and spine X-ray film. Angle

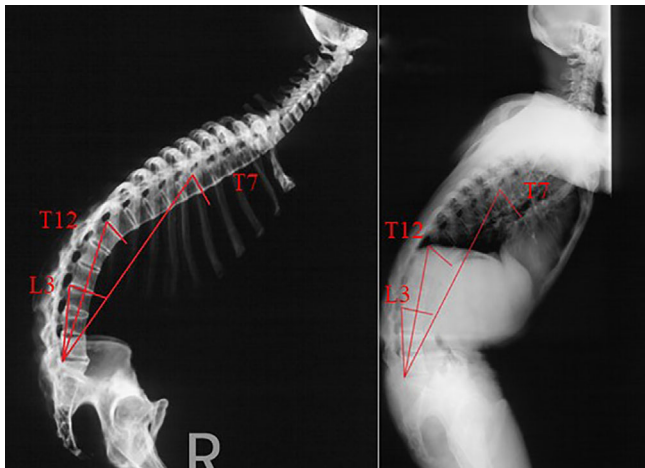
T7 was formed by the end plate of the superior T7 vertebra and the line between the superior-posterior corners of the first sacral vertebra and the T7 vertebra. Angle T12 was formed by the superior end plate of the T12 vertebra and the line between the superior-posterior corners of the first sacral vertebra and the T12 vertebra. Angle L3 was formed by the superior end plate of the L3 vertebra and the line between the superior-posterior corners of the first sacral vertebra and the L3 vertebra (Fig. 1).

### Statistical Analysis

Data analyses were performed using IBM SPSS statistics 26.0 for Windows (IBM, Armonk, NY, USA) and the exploratory graph was analyzed with MedCalc Statistical Software version 19.0.4 (MedCalc Software, Ostend, Belgium). A paired sample *t* test was performed to determine the differences between the GK, LL, TLK and TK on the synthesized 2D lateral radiograph and that on X-ray film. The paired sample *t* test was also performed to determine the differences between the angle T7, angle T12 and angle L3 on the synthesized 2D lateral radiograph and that on X-ray film. A *P* value <0.05 is significant. Measurements of the synthesized 2D lateral radiograph and X-ray film were compared using the Bland–Altman plot. The Bland–Altman plot graphically illustrates the differences in measurements. If the differences are aggregated around the mean, the consistency between raters is high.

### Results

The participants included 38 male patients and four female patients. The minimum age was 32 years, the



**Fig. 1** Angle T7: the angle was formed by T7 superior end plate and the line between superior-posterior corners of the first sacrum vertebra and T7 vertebra. Angle T12: the angle was formed by T12 superior end plate and the line between superior-posterior corners of the first sacrum vertebra and T12 vertebra. Angle L3: the angle was formed by L3 superior end plate and the line between superior-posterior corners of the first sacrum vertebra and L3 vertebra.

maximum age was 69 years, and the average age was  $42.094 \pm 7.812$  years.

### Sagittal Parameters between the Synthesized 2D Lateral Radiograph and X-Ray Film

The data analysis showed that the GK, TK, LL and TLK on the synthesized 2D lateral radiograph were  $61.350^\circ \pm 21.882^\circ$ ,  $57.250^\circ \pm 18.201^\circ$ ,  $3.598^\circ \pm 18.117^\circ$  and  $40.543^\circ \pm 13.114^\circ$ , respectively. The GK, TK, LL and TLK on the X-ray film were  $61.921^\circ \pm 22.198^\circ$ ,  $57.757^\circ \pm 17.489^\circ$ ,  $4.045^\circ \pm 18.286^\circ$  and  $41.186^\circ \pm 13.000^\circ$ , respectively. There was no significant difference between the GK, LL, TLK, and TK on the synthesized 2D lateral radiograph and that on the X-ray film. The results did not show a significant difference between the angle T7, angle T12, or angle L3 on the synthesized 2D lateral radiograph and those on the spine X-ray film. The angle T7, angle T12 and angle L3 on the synthesized 2D lateral radiograph were  $47.814^\circ \pm 11.131^\circ$ ,  $62.762^\circ \pm 10.406^\circ$  and  $84.143^\circ \pm 8.114^\circ$ , respectively. The angle T7, angle T12 and angle L3 on the X-ray film were  $48.110^\circ \pm 10.977^\circ$ ,  $62.155^\circ \pm 9.979^\circ$  and  $83.888^\circ \pm 7.740^\circ$ , respectively (Table 1).

### Repeatability of the Synthesized 2D Lateral Radiograph

The intraclass correlation coefficient (ICC) and 95% confidence intervals (CIs) of the consistency data GK, TK, LL and TLK measured by the two researchers on the synthesized 2D lateral radiograph are as follows: GK: 0.977 (95% CI, 0.959–0.988), TK: 0.969 (95% CI, 0.943–0.983), LL: 0.986 (95% CI, 0.974–0.992), and TLK: 0.945 (95% CI, 0.900–0.970). The ICC and 95% CI of the consistency between the T7 angle, T12 angle and L3 angle measured by the two researchers on the synthesized 2D lateral radiograph are as follows: T7 angle: 0.947 (95% CI, 0.903–0.971), T12 angle: 0.915 (95% CI, 0.848–0.954), and L3 angle: 0.857 (95% CI, 0.749–0.921) (Table 2). The ICC values of the two examinees were in good agreement. The repeatability was good, and the results of the two groups of data measurements were consistent.

### The Consistency of Image Parameters of the Synthesized 2D Lateral Radiograph

To graphically compare the consistency of image parameters measured by the examiners, we compared Bland–Altman plots between the two researchers. The results showed that there was a high degree of agreement between the two groups because the differences were clustered around the mean values of the two groups (Fig. 2).

### Discussion

In the present study, the results showed that agreement two researchers were excellent with ICC of the GK, LL, TLK, TK, angle T7, angle T12, angle L3 on the synthesized 2D lateral radiograph. The results also suggested that data measurement of two groups of researchers had high repeatability, and there was no significant difference between the GK, LL, TLK, TK, angle T7, angle T12, angle L3 on the synthesized 2D lateral radiograph and that on X-ray film.

**TABLE 1** The means  $\pm$  SD, T value, P Data of the GK, TK, LL, TKL, Angle T7, Angle T12, Angle L3

Group	CT	X	t	P
GK	61.350° $\pm$ 21.882°	61.921° $\pm$ 22.198°	-1.192	0.240
TK	57.250° $\pm$ 18.201°	57.757° $\pm$ 17.489°	-0.999	0.324
LL	3.598° $\pm$ 18.117°	4.045° $\pm$ 18.286°	-1.306	0.199
TLK	40.543° $\pm$ 13.114°	41.186° $\pm$ 13.000°	-1.709	0.095
Angle T7	47.814° $\pm$ 11.131°	48.110° $\pm$ 10.977°	-0.813	0.421
Angle T12	62.762° $\pm$ 10.406°	62.155° $\pm$ 9.979°	1.753	0.087
Angle L3	84.143° $\pm$ 8.114°	83.888° $\pm$ 7.740°	0.716	0.478

Note: Comparison of the sagittal parameters between the synthesized 2Dimensional (2D) lateral radiograph and X-ray film.; Abbreviations: Angle L3, the angle was formed by L3 superior end plate and the line between superior-posterior corners of the first sacrum vertebra and L3 vertebra; Angle T12, the angle was formed by T12 superior end plate and the line between superior-posterior corners of the first sacrum vertebra and T12 vertebra; Angle T7, the angle was formed by T7 superior end plate and the line between superior-posterior corners of the first sacrum vertebra and T7 vertebra; GK, globe kyphosis; LL, lumber lordosis; TK, thoracic kyphosis; TLK, thoracolumbar kyphosis.

**TABLE 2** The ICC and 95% confidence intervals (CI) of the GK, TK, LL, TKL, Angle T7, Angle T12, Angle L3

Group	ICC	95% CI
GK	0.977	0.959–0.988
TK	0.969	0.943–0.983
LL	0.986	0.974–0.992
TLK	0.945	0.900–0.970
Angle T7	0.947	0.903–0.971
Angle T12	0.915	0.848–0.954
Angle L3	0.857	0.749–0.921

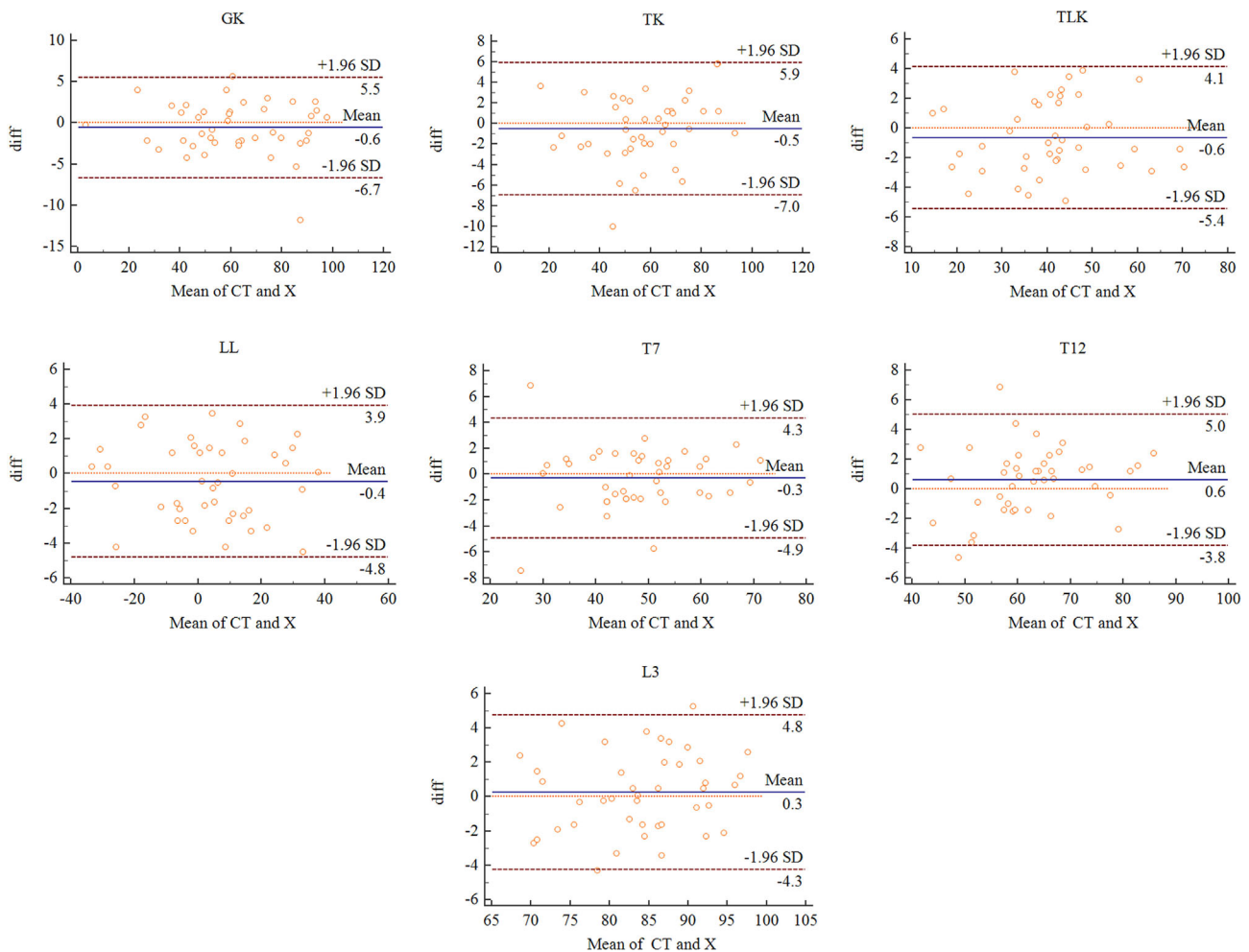
Note: Comparison of the repeatability of measurement between the synthesized 2Dimensional (2D) lateral radiograph.; Abbreviations: Angle L3, the angle was formed by L3 superior end plate and the line between superior-posterior corners of the first sacrum vertebra and L3 vertebra; Angle T12, the angle was formed by T12 superior end plate and the line between superior-posterior corners of the first sacrum vertebra and T12 vertebra; Angle T7, the angle was formed by T7 superior end plate and the line between superior-posterior corners of the first sacrum vertebra and T7 vertebra; CI, confidence intervals; GK, globe kyphosis; ICC, intraclass correlation coefficient; LL, lumber lordosis; TK, thoracic kyphosis; TLK, thoracolumbar kyphosis.

The Bland–Altman plot results also demonstrated that the two measurement methods on CT and X-ray film had good consistency and high repeatability.

### Synthesized 2D Lateral Radiograph and General X-Ray Film Have Equivalent Effects

For AS kyphosis deformities, prior to surgery, it is critical to estimate the degree of the patient's sagittal imbalance on a full-length spine X-ray. Due to the complex condition of patients with severe AS kyphosis, 3D3D CT scans of the full spine are generally performed to assess the vertebral pedicle type for safe pedicle screw placement. Three-dimensional printing techniques have become one of the latest tools in the armory of modern spine surgeons, improving precision and safety in treating patients with spinal deformities.<sup>16</sup> Three-dimensional computed tomography is indispensable for this technique. Based on 3D3D CT scans, synthesized 2D

lateral radiographs of the full spine can be easily obtained with additional software systems. Whether the synthesized 2D lateral radiograph plays the same role as the general X-ray film does for patients with AS kyphosis deformity has not yet been determined. If so, we could potentially reduce the patient's radioactive exposure and financial burden by avoidance of a general full spine X-ray. Hence, we conducted the present study. On both the synthesized 2D lateral radiograph and X-ray film, the traditional GK, LL, TLK and TK were measured. Furthermore, angle T7, angle T12 and angle L3 were also obtained. Angle T7 was formed by the end plate of the superior T7 vertebra and the line between the superior-posterior corners of the first sacrum vertebra and the T7 vertebra. Angle T12 was formed by the superior end plate of the T12 vertebra and the line between the superior-posterior corners of the first sacrum vertebra and the T12 vertebra. Angle L3 was formed by the superior end plate of the L3 vertebra and the line between the superior-posterior corners of the first sacrum vertebra and the L3 vertebra. Like the Cobb angle, the angle T7, angle T12 and angle L3 were adopted to further investigate the difference between the synthesized 2D lateral radiograph and X-ray film. The statistical results showed that there was no significant difference between GK, LL, TLK, or TK on the synthesized 2D lateral radiograph and that on X-ray film ( $P > 0.05$ ). The results also did not reveal a significant difference between the angle T7, angle T12, or angle L3 on the synthesized 2D lateral radiograph and that on the X-ray film ( $P > 0.05$ ). Because the current clinical application of X-ray film is mainly used as a physician's data measurement reference for a wide range of image data with high repeatability, this paper does not measure the ICC of X-ray film. ICC results showed that the reliability of GK, LL, TLK, TK, angle T7, angle T12, and angle L3 on the synthesized 2D lateral radiograph was high (ICC  $> 0.75$ ). The data measurement of two groups of researchers has high repeatability. The results of the Bland–Altman plot show that the two measurement methods on CT and X-ray film have good consistency and high repeatability. As the  $P$  value  $> 0.05$ , there was no statistical



**Fig. 2** The consistency of image parameters of the synthesized 2Dimensional (2D) lateral radiograph and X-ray film. Bland–Altman plot. Angle L3, the angle was formed by L3 superior end plate and the line between superior-posterior corners of the first sacrum vertebra and L3 vertebra; Angle T12, the angle was formed by T12 superior end plate and the line between superior-posterior corners of the first sacrum vertebra and T12 vertebra; Angle T7, the angle was formed by T7 superior end plate and the line between superior-posterior corners of the first sacrum vertebra and T7 vertebra; GK, globe kyphosis; LL, lumbar lordosis; TK, thoracic kyphosis; TLK, thoracolumbar kyphosis.

significance regarding CT and X-ray films. Therefore, the results demonstrated that the synthesized 2D lateral radiograph and general X-ray film have equivalent effects on estimating the degree of spinal sagittal malalignment in patients with AS kyphosis deformities.

### **Synthesized 2D Lateral Radiograph Film Is Potentially Used in Making Surgical Plan**

If the relevant parameters required for mapping out a surgical plan were measured on the synthesized 2D lateral radiograph, then full-length spine X-ray film was not necessary. Generally, preoperative full-length spine radiographs were performed with patients standing in their neutral unsupported position. Based on full-length spine X-ray film, some authors have proposed different methods for choosing the osteotomy site and calculating the correction angle to

restore spinal sagittal alignment.<sup>17,18</sup> Ondra *et al.* employed a basic trigonometric formula to calculate the desired correction angle and intraoperative osteotomy height on the preoperative full spine X-ray film.<sup>18</sup> Although this method is a clever method, it has limitations. The method does not take the chin-brow vertical angle into account when calculating the correction angle. The chin-brow vertical angle is an objective index for evaluating the patient's horizontal gaze.<sup>10</sup> The measurement of the chin-brow vertical angle is recommended in making a surgical plan. Both overcorrection and undercorrection have negative effects on patients' horizontal gazes.<sup>10</sup> In addition, pelvic compensatory rotation and lower extremity compensatory rotation are also not taken into account with this method, which would lead to underestimation of spinal sagittal imbalance and further underestimation of the correction angle needed. In 2013, Song *et al.*

also reported a method for calculating the required correction angle for spinal osteotomy.<sup>18</sup> In their method, they noted that the plumb line through the hilus pulmonis rather than C7 is the gravity axis of the trunk, and that the hilus pulmonis plumb line should pass through the midpoint of the femoral heads in normal subjects.<sup>18</sup> To eliminate the influence of lower extremity compensation, they adopted a mathematical equation proposed by Vialle *et al.* ( $PT = 0.37 \times PI - 7$ ). PI (pelvic incidence) and PT (pelvic tilt) are pelvic parameters widely accepted by spine surgeons.<sup>19</sup> In normal subjects, the angle formed by the line passing through the midpoint of the femoral heads and the midpoint of the first sacral superior endplate and the gravity axis of the trunk is equal to PT.<sup>18</sup> The postoperative gravity axis of the trunk should pass through the patient's hilus pulmonis and the femoral head midpoint. Furthermore, the required correction angle is calculated using a basic trigonometric formula as Ondra *et al.* do.<sup>18,19</sup> Although Song *et al.* takes pelvic compensatory rotation and lower extremity compensatory rotation into account when the correction angle is calculated, the chin-brow vertical angle is still ignored in patients who have fixed cervical hyperlordosis, hypolordosis or even kyphosis. For patients with fixed cervical deformities, Song *et al.*'s method could still result in over- or under-correction of the chin-brow vertical angle. Hence, this method is appropriate for patients without fixed cervical deformity, especially for those whose cervical motion retains the majority of the cervical motion range. Surgimap Spine (Nemaris Inc., New York, NY, USA) software is also available for planning osteotomy. All these methods are based on the patient's full-spine sagittal X-ray film. According to the literature, there is no method that can take both the chin-brow vertical angle and the lower extremity compensation into account when calculating the required correction angle. Therefore, a new method to calculate the correction angle by studying the X-ray film should be investigated. To estimate the degree of spine sagittal imbalance on the synthesized 2D lateral radiograph, the SVA (sagittal vertical axis) is not available because it is necessary to measure the SVA on the full spine X-ray film with patients standing in their neutral unsupported position. On the synthesized 2D lateral radiograph, the cervical 7 sacrum angle (C7SA) and the anterior pelvic plane (APP) might be suitable. To assess the patient's sagittal imbalance, the C7SA is an angle and not the distance of sagittal imbalance, and C7SA could avoid the influence of the patient's individual body size.<sup>12</sup> APP is commonly accepted as the coronal plane of the pelvis, and it is widely used by joint surgeons as an anatomical reference plane of the pelvis during the procedure of total hip replacement.<sup>20-24</sup> Referring to the APP, C7SA could be used to estimate the degree of sagittal imbalance in the patient's trunk on the synthesized 2D lateral radiograph. This method could eliminate the influences of pelvic compensatory rotation and lower extremity compensation while assessing the

degree of the patient's trunk sagittal imbalance. Hence, using the synthesized 2D lateral radiograph, Song *et al.*'s method for surgical planning is relatively suitable because their method may ignore the patient's position when they undergo a full-length spine radiograph test. According to the results of our study, pre-surgery full-length spine X-ray film should be avoided for patients with AS kyphosis deformity who will or have undergone a full spine 3D CT test, which would reduce the patient's financial burden and radioactive exposure. Moreover, as an important pelvic parameter, APP is also worthy of further study by spine surgeons. By studying APP, we may find a more rational and scientific method to develop a surgical strategy for patients with AS kyphosis deformities, especially for patients who also need total hip replacement.

### Limitations

There are some limitations in the present study. First, the present study is a small cohort radiographic study, larger cohort studies are needed. Second, the study only included patients with AS kyphosis deformities, and the AS kyphosis deformities is a kind of rigid deformity. Hence, the present study results only provide some useful information for spine surgeons and patients with AS kyphosis deformities. The conclusion of the study is not suitable for other spine deformity.

### Conclusion

Synthesized 2D lateral radiographs can play the same role as general X-ray films on estimating the degree of spinal sagittal malalignment in patients with AS kyphosis deformities. Full-length spine radiographs of the patients may be unnecessary for patients with severe AS kyphosis deformity who will or have undergone preoperative full spine 3D CT. Further studies are needed to demonstrate whether a correct surgical plan could be made according to the Synthesized 2D lateral radiographs.

### Author Contributions

Zhen Zhang, Chao Liu and Fanqi Hu are co-first author: Manuscript writing, Data analysis and interpretation. Yonggang You and Wenhao Hu: Collection and/or assembly of data. Xuesong Zhang and Chao Liu: Conception and design, supervision and financial support.

### Funding Information

The author(s) disclosed receipt of the following financial support for the research, authorship, and/or publication of this article: This work was financially supported by the National Natural Science Foundation of China (Grant No. 81972128) and Application of Clinical Features of Capital City of Science and Technology Commission China Beijing Special Subject (Z181100001718180).

## References

1. Taurog JD, Chhabra A, Colbert RA. Ankylosing spondylitis and axial spondyloarthritis. *N Engl J Med*. 2016;374:2563–74.
2. Ranganathan V, Gracey E, Brown MA, Inman RD, Haroon N. Pathogenesis of ankylosing spondylitis—recent advances and future directions. *Nat Rev Rheumatol*. 2017;13:359–67.
3. Allouch H, Shousha M, Böhm H. Surgical management of ankylosing spondylitis (Bechterew's disease). *Z Rheumatol*. 2017;76:848–59.
4. Trent G, Armstrong GW, O'Neil J. Thoracolumbar fractures in ankylosing spondylitis. High-risk injuries. *Clin Orthop Relat Res*. 1988;227:61–6.
5. Bridwell KH, Lewis SJ, Lenke LG, C. Baldus, K. Blanke *et al*. Pedicle subtraction osteotomy for the treatment of fixed sagittal imbalance. *J Bone Joint Surg Am* 2003, 85:454–463.
6. Debarge R, Demey G, Roussouly P. Radiological analysis of ankylosing spondylitis patients with severe kyphosis before and after pedicle subtraction osteotomy. *Eur Spine J*. 2010;19:65–70.
7. Kim KT, Suk KS, Cho YJ, G. Hong, B. Park, *et al*. Clinical outcome results of pedicle subtraction osteotomy in ankylosing spondylitis with kyphotic deformity. *Spine* 2002, 27:612–618.
8. Van Royen BJ, Slot GH. Closing wedge posterior osteotomy for ankylosing spondylitis. *J Bone Joint Surg*. 1995;77:117–21.
9. Scheer JK, Tang JA, Smith JS, Acosta F, Protosaltis T, Blondel B, *et al*. Cervical spine alignment, sagittal deformity, and clinical implications. *J Neurosurg Spine*. 2013;19:141–59.
10. Suk KS, Kim KT, Lee SH, Jin-Moon Kim, *et al*. Significance of chin brow vertical angle in correction of kyphotic deformity of ankylosing spondylitis patients. *Spine* 2003, 28:2001–2005.
11. Liu C, Zheng GQ, Zhang YG, Tang X, Song K, Fu J, *et al*. The radiologic clinical results and digestive function improvement in patients with ankylosing spondylitis kyphosis after pedicle subtraction osteotomy. *Spine J*. 2015;15:1988–93.
12. Hu F, Song K, Hu WH, Zhang Z, Liu C, Wang Q, *et al*. Improvement of sleep quality in patients with ankylosing spondylitis kyphosis after corrective surgery. *Spine*. 2020;45:1596–603.
13. Mangone M, Paoloni M, Procopio S, Venditto T, Zucchi B, Santilli V, *et al*. Sagittal spinal alignment in patients with ankylosing spondylitis by rasterstereographic back shape analysis: an observational retrospective study. *Eur J Phys Rehabil Med*. 2020;56:191–6.
14. Smith-Petersen MN, Larson CB, Aufranc OE. Osteotomy of the spine for correction of flexion deformity in rheumatoid arthritis. *J Bone Joint Surg*. 1945;27:1–11.
15. Liu C, Zheng G, Guo Y, Song K, Tang X, Zhang X, *et al*. Two-level osteotomy for correcting severe ankylosing spondylitis kyphosis: radiologic outcomes of different osteotomy PositionSelection strategy for different type of patients. *Spine Deform*. 2018;6:273–81.
16. Garg B, Mehta N. Current status of 3D printing in spine surgery. *J Clin Orthop Trauma*. 2018;9:2018–225.
17. Ondra SL, Marzouk S, Koski T, Fernando E. Silva, S. Salehi *et al*. Mathematical calculation of pedicle subtraction osteotomy size to allow precision correction of fixed sagittal deformity. *Spine* 2006, 31:973–979.
18. Song K, Zheng GQ, Zhang YG, Xuesong Zhang, K. Mao, Yan Wang *et al*. A new method for calculating the exact angle required for spinal osteotomy. *Spine* 2013, 38: 616–620.
19. Vialle R, Levassor N, Rillardon L, A. Templier, W. Skalli, P. Guigui, *et al*. Radiographic analysis of the sagittal alignment and balance of the spine in asymptomatic subjects. *J Bone Joint Surg Am* 2005, 87: 260–267.
20. Lewinnek GE, Lewis JL, Tarr R, C. Compere, J. R. Zimmerman, *et al*. Dislocations after total hip-replacement arthroplasties. *J Bone Joint Surg Am* 1978, 60:217–220.
21. Nishno H, Nakamura S, Arai N, T. Matsushita, *et al*. Accuracy and precision of version angle measurements of the acetabular component after total hip arthroplasty. *J Arthroplasty* 2013, 28:1644–1647.
22. Nomura T, Naito M, Nakamura Y, Ida T, Kuroda D, Kobayashi T, *et al*. An analysis of the best method for evaluating anteversion of the acetabular component after total hip replacement on plain radiographs. *Bone Joint J*. 2014;96:587–603.
23. Paterno SA, Lachiewicz PF, Kelley SS. The influence of patient-related factors and the position of the acetabular component on the rate of dislocation after total hip replacement. *J Bone Joint Surg Am*. 1997;79:1202–10.
24. Robinson M, Bornstein L, Mennear B, Bostrom M, Nestor B, Padgett D, *et al*. Effect of restoration of combined offset on stability of large head THA. *Hip Int*. 2012;22:248–53.