



Since January 2020 Elsevier has created a COVID-19 resource centre with free information in English and Mandarin on the novel coronavirus COVID-19. The COVID-19 resource centre is hosted on Elsevier Connect, the company's public news and information website.

Elsevier hereby grants permission to make all its COVID-19-related research that is available on the COVID-19 resource centre - including this research content - immediately available in PubMed Central and other publicly funded repositories, such as the WHO COVID database with rights for unrestricted research re-use and analyses in any form or by any means with acknowledgement of the original source. These permissions are granted for free by Elsevier for as long as the COVID-19 resource centre remains active.



## BRIEF COMMUNICATION

# Risks of paxlovid in a heart transplant recipient

Kristin Stawiariski, MD, Robin Avery, MD, Sara Strout, PharmD, and  
Priya Umaphathi, MD

*From the Division of Cardiology, Department of Internal Medicine at the Johns Hopkins School of Medicine, Baltimore MD.*

**KEYWORDS:**

COVID-19;  
heart transplant;  
immunosuppression  
interaction;  
drug interaction;  
monoclonal antibody  
therapy

The burden of morbidity and mortality from SARS-CoV-2 infection is especially significant in heart transplant patients who are at higher risk for poor outcomes owing to immunosuppression, blunted response to vaccination, and multiple comorbid conditions. Over the last 3 years the therapeutic landscape for COVID-19 has evolved and our drug armamentaria continues to expand. With these advancements comes a time of great hope to mitigate significant illness from SARS – CoV – 2 infection. However, as with many emerging frontiers, the administration of novel therapeutics to a complex patient population remains challenging. We present a patient case encountered at our institution that highlights the need for increased awareness of nuances while managing COVID-19 infection in a heart transplant recipient.

J Heart Lung Transplant 000;000:1–3

© 2022 International Society for Heart and Lung Transplantation. All rights reserved.

With these advancements comes a time of great hope to mitigate significant illness from SARS – CoV – 2 infection. However, as with many emerging frontiers, the administration of novel therapeutics to a complex patient population remains challenging. We present a patient case encountered at our institution that highlights the need for increased awareness of potential toxicities. The burden of morbidity and mortality from SARS-CoV-2 infection is especially significant in heart transplant patients<sup>1</sup> who are at higher risk for poor outcomes owing to immunosuppression, blunted response to vaccination, and multiple comorbid conditions. Over the last 3 years the therapeutic landscape for COVID-19 has evolved and our drug armamentaria continues to expand.<sup>2</sup> With these advancements comes a time of great hope to mitigate significant illness from SARS – CoV – 2 infection. However, as with many emerging frontiers, the administration of novel therapeutics to a complex patient population remains challenging. We present a patient case encountered at our institution that

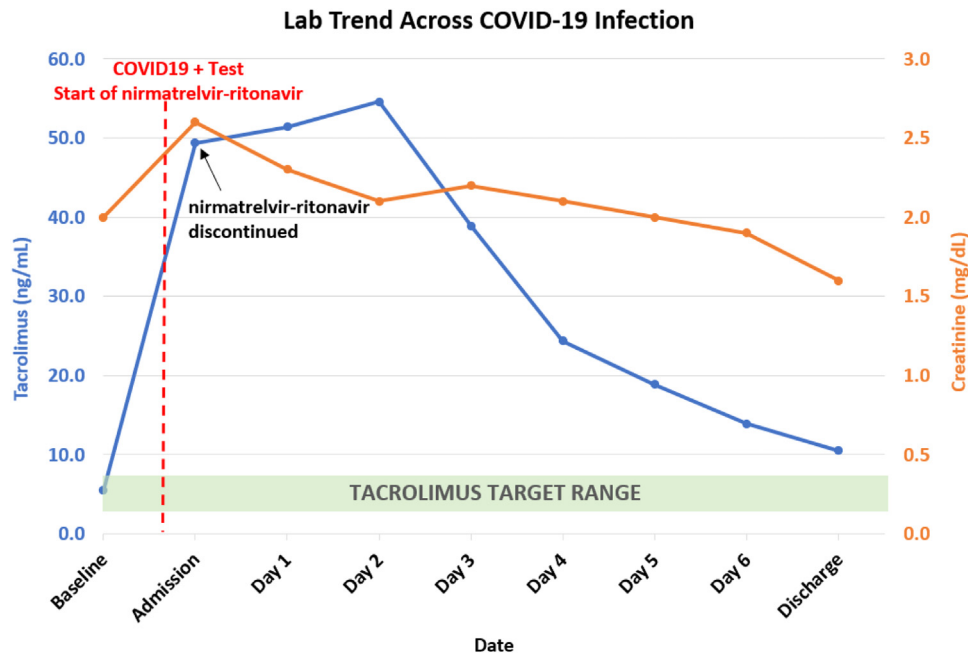
highlights the need for increased awareness of nuances while managing COVID-19 infection in a heart transplant recipient.

## Case

Recently, a 76-year-old heart transplant recipient at our center contracted mild COVID-19 infection, confirmed by PCR testing, with symptoms of sore throat and fatigue. He received his heart transplant in 2014 and was maintained on mycophenolate mofetil (500mg daily) and tacrolimus (1mg twice daily) with therapeutic range of 4 to 6 ng/mL. His 2-dose COVID-19 vaccination series, plus 2 booster doses, were completed 2 months prior to infection. All vaccine doses were the BNT162b2 mRNA vaccine. He was prescribed nirmatrelvir/ritonavir (Paxlovid) 300mg/100 mg twice daily under the emergency use authorization by another physician with no adjustment to his tacrolimus dose. He notified the transplant office 2 days later, at which time he was instructed to discontinue nirmatrelvir-ritonavir immediately, and to present to the Emergency Department. As anticipated, his tacrolimus level returned supratherapeutic at 49 ng/mL from 5.5 ng/mL the month

Reprint requests: Priya Umaphathi, MD, Johns Hopkins Hospital, 601 N Wolfe Street, Baltimore, MD 21287.

E-mail address: [mumapat1@jhmi.edu](mailto:mumapat1@jhmi.edu)



**Figure 1** Trends of tacrolimus and creatinine levels from prior to COVID-19 infection until discharge. The patient's individual tacrolimus target trough level is 4 to 6 ng/mL.

prior (Figure 1). He also had acute kidney injury with creatinine of 2.6 mg/dL, from baseline 1.8-2.0 mg/dL. Nirmatrelvir/ritonavir was not restarted, and he received monoclonal antibody therapy with 175mg of bebtelovimab. He had symptom resolution without the need for additional COVID specific therapies such as steroids or remdesivir. Tacrolimus was held. His additional home medications included aspirin, lisinopril, atorvastatin, icosapent ethyl, omeprazole, famotidine, semaglutide, and insulin. The tacrolimus level peaked at 54.6 ng/mL and then gradually decreased to an acceptable range (10.5 ng/mL) with subsequent resolution of acute kidney injury over his 7-day hospitalization.

Nirmatrelvir is a SARS-CoV-2 main ( $M^{pro}$  or 3CL) protease inhibitor given in combination with ritonavir, which acts as a pharmacokinetic booster to increase nirmatrelvir concentrations. Preliminary outcomes of the EPIC-HR study reported an 89% reduction in the relative risk of hospitalization for unvaccinated patients treated with nirmatrelvir/ritonavir compared with placebo.<sup>3</sup> However, ritonavir is a potent inhibitor and inducer of several cytochrome P450 enzymes, resulting in the potential for a wide range of drug interactions. Transplant recipients are particularly vulnerable due to the potent interaction with calcineurin inhibitors (CNI) and mTOR inhibitors (mTORi) due to inhibition of CYP3A and p-glycoprotein by ritonavir.<sup>4</sup> When used in combination with ritonavir, tacrolimus dosing requirements are reduced as much as 99%, and patients often maintain therapeutic levels with low doses of tacrolimus a few times a week or less when used concurrently.<sup>3</sup> Similar interactions with cyclosporine, everolimus, and sirolimus are expected.<sup>3</sup> If used concurrently, holding CNI and mTORi doses should be considered while receiving nirmatrelvir/ritonavir and for 2 to 3 days after completing therapy unless therapeutic drug monitoring is available to guide

dosing.<sup>3</sup> Ritonavir is an irreversible CYP3A inhibitor, so return to normal drug metabolism is dependent on production of new CYP3A enzymes, with pharmacokinetic modeling suggesting return to ~80% function in 48-72 hours but that some effect may persist for at least a week.<sup>3</sup> The effect of these interactions is difficult to manage without close therapeutic drug monitoring, which may be challenging in the outpatient setting while quarantining. There have been recommendations made regarding dose adjustment of calcineurin inhibitors (CNI) to be used in conjunction with nirmatrelvir/ritonavir, however, no definitive guidelines exist.<sup>3,4</sup> Additionally, transplant recipients are commonly receiving medications for various comorbidities that may also need to be held or adjusted during nirmatrelvir/ritonavir therapy. One such example is atorvastatin which our patient was taking at the time of nirmatrelvir/ritonavir therapy that may have potentiated the adverse effects. Close, co-management of COVID-19 in heart transplant patients with primary care providers, pharmacists, and transplant teams is imperative.

Given the availability of other highly effective therapies such as monoclonal antibodies, these are vastly preferred for patients on immunosuppressive regimens who have issues with profound drug/drug interactions.<sup>5</sup> It may be prudent to approach the use of nirmatrelvir/ritonavir if it is the only option available, and even then, to proceed with extreme caution and very close monitoring.

## Conclusion

The advent of novel, COVID-19 antiviral therapy is a welcome tool against severe disease in high-risk patients with increasing nation-wide use of the FDA Emergency Use Authorization (EUA) for 2 oral antivirals -Nirmatrelvir/Ritonavir and Molnupiravir for treatment of

COVID-19. Transplant recipients are among the group eligible for this therapy and we present a case that highlights some cautions to be considered when treating these patients. Given the concerns for potent drug-drug interaction between the oral antivirals and CNI's, the American Society for Transplantation recommends that providers consider other therapies available for early disease that are shown to reduce progression to severe disease such as monoclonal antibodies or early treatment with intravenous remdesivir.<sup>5</sup> Recommendations are suggested related to mitigating the drug-drug interaction with CNI's but may prove cumbersome/infeasible in real-world clinical situations. Nirmatrelvir/ritonavir is undoubtedly very useful in mitigating the severity of COVID-19 for patients who have risk factors. However, in the transplant population it is reasonable to consider as first line other highly effective therapies such as monoclonal antibodies (notably bebtelovimab at the time of this writing) that may obviate the need for antivirals and the drug-drug interactions that arise.

## Disclosure statement

The authors have no conflicts of interest to disclose.

## References

1. Bottio T, Bagozzi L, Fiocco A, et al. COVID-19 in heart transplant recipients: a multicenter analysis of the Northern Italian Outbreak. *JACC Heart Fail* 2021;9:52-61.
2. Cochran W, Shah P, Barker L, et al. COVID-19 clinical outcomes in solid organ transplant recipients during the Omicron surge. *Transplantation* 2022;106:e346-7.
3. Fishbane S, Hirsch JS, Nair V. Special considerations for paxlovid treatment among transplant recipients with SARS-CoV-2 infection. *Am J Kidney Dis* 2022;79:480-2.
4. Salerno DM, Jennings DL, Lange NW, et al. Early clinical experience with nirmatrelvir/ritonavir for the treatment of COVID-19 in solid organ transplant recipients. *Am J Transplant* 2022;22:2083-8.
5. Kumar D, Humar A, Ison MG, et al. AST statement on oral antiviral therapy for COVID. Available at: <https://www.myast.org/sites/default/files/AST%20Statement%20on%20Oral%20Antiviral%20Therapy%20for%20COVID%20Jan%204%20%28%29.pdf>. Accessed April 19, 2022.