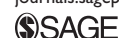

# Dexmedetomidine as an Adjunct to Treat Anticholinergic Toxidrome in Children

Global Pediatric Health  
Volume 4: 1–5  
© The Author(s) 2017  
Reprints and permissions:  
sagepub.com/journalsPermissions.nav  
DOI: 10.1177/2333794X17704764  
journals.sagepub.com/home/gph



Krista Cowan, BS<sup>1</sup>, Rebecca A. Landman, DPh<sup>1</sup>, and Arun Saini, MD<sup>1</sup>

Received March 14, 2017. Accepted for publication March 21, 2017.

## Introduction

Anticholinergic drug exposure is very common and responsible for 15% to 20% of hospital admissions and up to 40% of intensive care admissions related to acute poisonings.<sup>1,2</sup> A well-described anticholinergic toxidrome frequently occurs after exposure to various drugs with anticholinergic properties including antihistamines, atropine, tricyclic antidepressants, jimsonweed, atypical antipsychotics, and scopolamine.<sup>1</sup> These drugs can antagonize both peripheral and central muscarinic receptors to produce anticholinergic toxidrome. Central nervous system manifestations are usually presenting symptoms and include severe agitation, hallucinations, and acute psychosis. Peripheral manifestations often include flushing, dry mouth, dry skin, mydriasis, urinary retention, fever, tachycardia, and hypertension. In severe cases, death can occur due to dysrhythmias.

Supportive care is the mainstay of management of anticholinergic toxidrome including hydration, temperature control, and removal of the offending agent.<sup>3</sup> Patients with delirium and agitation are at risk of self-harm and potential harm to medical staff. These patients frequently require medical therapy with benzodiazepines or benzodiazepines and physostigmine to control delirium and agitation.<sup>3</sup> Benzodiazepines work to control agitation by enhancing the effects of  $\gamma$ -aminobutyric acid (GABA) at the GABA-A receptors, while physostigmine crosses the blood-brain barrier and reverses the toxidrome by reversibly inhibiting acetylcholinesterase.<sup>4</sup> Benzodiazepines have been shown to control agitation in less than 25% of patients and proved ineffective in reversing delirium in these patients.<sup>5</sup> Additionally, benzodiazepines require frequent dosing and can cause significant respiratory depression, resulting in higher rates of intubations in these patients.<sup>5</sup> Physostigmine is an antidote available to treat anticholinergic toxidrome. Physostigmine use is limited for multiple reasons including the need for frequent dosing, unavailability in many centers, lack of familiarity with its use among providers, and certain undesirable side effects including seizure, dysrhythmia,

and bowel or urogenital obstructions.<sup>3,6</sup> These limitations of benzodiazepines and physostigmine have encouraged physicians to use adjunct therapies to control manifestations of anticholinergic toxidrome.<sup>7-9</sup> In this article, we present 2 novel cases of dexmedetomidine use to treat anticholinergic toxidrome, a toddler who is so far the youngest reported case to the best of our knowledge and an adolescent girl who had a relative contraindication to physostigmine use.

## Case I

A 3-year-old, 13.6-kg boy was presented to a local emergency department (ED) with agitation and hallucinations after unintentional ingestion of 10 to 20 tablets (25 mg each) of diphenhydramine. On initial assessment, he was delirious and experiencing visual hallucination. He had heart rate (HR) of 166 beats per minute, respiration rate (RR) of 30 breaths per minute, and blood pressure (BP) of 119/71 mm Hg. Initial laboratory evaluation showed normal routine serum chemistry and negative urine drug screen for amphetamines, barbiturates, methadone, opiates, phencyclidine, benzodiazepines, cocaine, cannabinoids, and ecstasy. Electrocardiogram (EKG) showed normal QRS interval and QT interval.

On arrival to the pediatric ED, the patient's vitals were BP of 142/92 mm Hg, HR of 158 beats per minute, and RR of 26 breaths per minute. He appeared agitated and was grabbing and scratching at himself. Additional pertinent physical exam findings include pupils dilated to 7 mm and a dry oral mucosa. He received a 1-mg dose of intravenous midazolam to control agitation with a minimal clinical response. Subsequently, he received

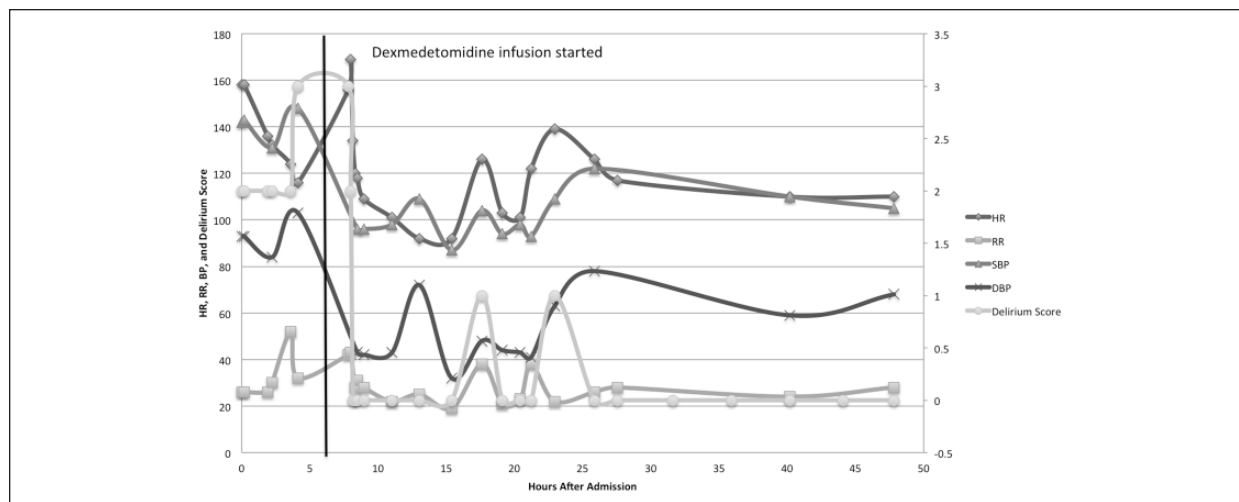
<sup>1</sup>Le Bonheur Children's Hospital, University of Tennessee Health Science Center, Memphis, TN, USA

### Corresponding Author:

Arun Saini, Pediatric Critical Care Medicine, Department of Pediatrics, 50 N Dunlap Street, Suite 370R, Memphis, TN 38103, USA.

Email: asaini1@uthsc.edu





**Figure 1.** Case 1: Trend of vital signs and delirium score.

two 1.5-mg doses of lorazepam in an attempt to control agitation and minimize agitation. The patient remained agitated and continuing to pull off his monitor leads, intravenous (IV) line, and clothes. He was then transferred to the pediatric intensive care unit (PICU) for a possibility of a midazolam IV drip initiation.

On arrival in the PICU, the patient required an intranasal dose of midazolam 6 mg, to help control agitation, while placing a new IV catheter. He developed more notable features of anticholinergic toxidrome (severe agitation, fever, tachycardia, tachypnea, hypertension, and dilated pupils). Physostigmine was considered but was not given due to limited experience of the providing physician and inpatient pharmacist, a need for frequent dosing, and unavailability of onsite toxicologists to guide the therapy. He was started on dexmedetomidine infusion at the rate of 0.5  $\mu\text{g}/\text{kg}/\text{h}$ . The patient had a dramatic response to dexmedetomidine infusion with control of agitation in 30 minutes. After approximately 10 hours of dexmedetomidine infusion, he had no agitation, normal neurological exam, and normal vital signs (Figure 1). The dexmedetomidine drip was discontinued, and he was transferred out to lower acuity care.

## Case 2

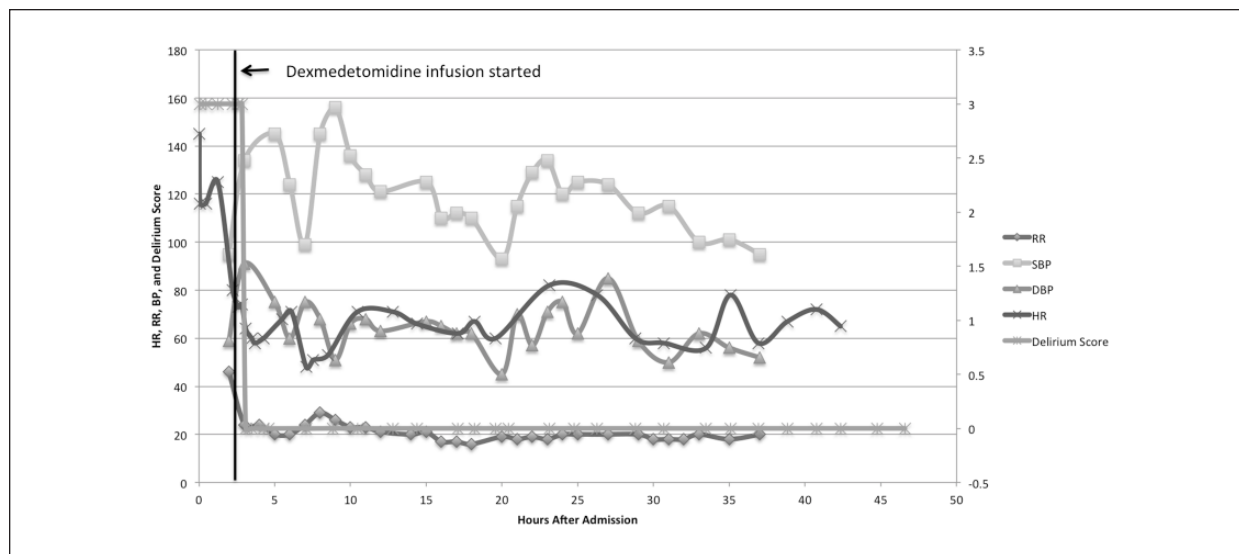
A 15-year-old, 45.1-kg teenager was brought to the ED for altered mental status after an intentional unwitnessed ingestion of dicyclomine. The patient's mother found the patient having hallucinations and an empty bottle of dicyclomine (approximately 20-30 tablets). There were also empty bottles of ranitidine and ciprofloxacin. Also, her urine drug test was found positive for cannabinoids.

In the ED, she was severely agitated and hallucinating. She was given a 2-mg intramuscular dose of lorazepam after she pulled out her IV line. Her initial vital signs were a temperature of 36.7°C, HR of 64 to 74 beats per minute, and RR of 26 to 29 breaths per minute. However, she remained very anxious, hallucinating, and angry. She had inappropriate speech and behavior. She was placed in soft restraints due to potential self-harm or harm to others. Additional pertinent findings on the physical exam included mydriasis (pupil size 6 mm), abrasions over knees due to thrashing on a gurney, a flight of ideas, and incomprehensible speech. She was given an additional 2-mg dose of intravenous lorazepam. She was then transferred to the PICU for ongoing care.

In the PICU, she had an EKG, which showed the corrected QT interval of 420 milliseconds. Physostigmine was considered but was not given due to the high normal corrected QT interval in a setting of multidrug ingestion, which could have increased her risk for developing bradycardia or asystole following physostigmine treatment. She was started on dexmedetomidine infusion at 0.5  $\mu\text{g}/\text{kg}/\text{h}$ , instead of physostigmine to control delirium. She responded well to dexmedetomidine with a resolution of agitation and hallucinations within 30 minutes. She did not develop severe bradycardia or hypotension while on the dexmedetomidine infusion (Figure 2). She was weaned off the infusion after 6 hours when her altered mental status resolved and normalization of EKG. She was transferred to a psychiatric facility for inpatient psychiatric care.

## Discussion

Our cases demonstrated that dexmedetomidine is an effective adjunctive treatment for anticholinergic



**Figure 2.** Case 2: Trend of vital signs and delirium score.

toxidrome. In addition to the 2 cases presented in this article, dexmedetomidine has been used successfully to treat 7 other pediatric anticholinergic overdoses cases<sup>7-9</sup> (Table 1). Case 1 was the youngest patient to date who received dexmedetomidine to treat anticholinergic toxidrome. Dexmedetomidine successfully controlled both central and peripheral manifestations of anticholinergic toxidrome. Using dexmedetomidine instead of continuous infusion of benzodiazepines allowed treating physicians to avoid respiratory depression and potential intubation as a complication. While in Case 2 dexmedetomidine was used due to relative contraindication to physostigmine use including high normal QT interval and multidrug ingestion with unknown cardiac toxicity profile.

Physostigmine is an effective antidote to treat anticholinergic toxidrome especially in a clinical severity score of 2 or 3.<sup>1,6</sup> However, there is extreme variability in its use among centers across the world related to its availability, local experience, and practice pattern. A review of the Toxicology Investigators Consortium Registry showed that benzodiazepines were prescribed most frequently in 28.7% patients and only 12.4% patients were prescribed physostigmine by toxicologists to control anticholinergic toxidrome.<sup>3</sup> They also found a differential use of physostigmine based on possible causative agents. Physostigmine was used more frequently when the causative agent exerted primarily anticholinergic toxicity as opposed to those agent(s), which exhibit more “mixed” effects. There was a lower rate of intubation but a significantly higher rate of rhabdomyolysis in those receiving physostigmine. There is also

significant variability in its dosing regimen ranging from rapid bolus to slow titration. The possibility of excessive cholinesterase inhibition including excessive secretions, bronchospasm, bradyarrhythmias, and seizures are a limitation to its use. Another primary concern is the substantial increase in the risk of seizures and cardiac dysrhythmias with tricyclic antidepressant overdose.<sup>10</sup> The above-described concerns coupled with unfamiliarity with its use among emergency and critical care physicians make physostigmine use sparse in anticholinergic toxidrome.

Dexmedetomidine is a selective  $\alpha_2$ -adrenergic agonist with sedative, anxiolytic, and analgesic properties.<sup>11</sup> Its sedative and anxiolytic activities are produced by its effects in the locus ceruleus leading to decreased sympathetic outflow with a resultant increased action of the inhibitory GABA neurons. Its analgesic effects are mediated as a result of the release of substance P from the dorsal horn of the spinal cord. Although first approved by the Food and Drug Administration for short-term sedation in mechanically ventilated patients in 1999, dexmedetomidine has increasingly been used for multiple indications.<sup>12</sup> The excellent pharmacological profile with minimal respiratory depression makes dexmedetomidine a reasonable alternative to other sedatives for agitation and delirium associated with anticholinergic toxidrome. Dexmedetomidine’s commonly reported side effects of hypotension and bradycardia offer a significant advantage in controlling peripheral manifestations of tachycardia and hypertension.<sup>13</sup> In contrast to physostigmine, dexmedetomidine may be used safely even in the presence of prolonged QTc.

**Table 1.** Reported Dexmedetomidine Use in Pediatric Anticholinergic Toxicity Cases.

Case	Age, Sex	Ingested Agent	Additional Medication	Dexmedetomidine Dosing	Outcomes
Walker et al <sup>9</sup>	13 years, female	Diphenhydramine	Lorazepam	1 µg/kg/h loading dose with 0.5 µg/kg/h infusion for 25 hours, then 0.5 µg/kg/h for 8 hours	Control of agitation from RASS score of 4+ to RASS score of 3-. Improved tachycardia. No reported adverse events.
Tobias <sup>8</sup>	16 years, female	Dextromethorphan	Lorazepam	1 µg/kg/h for 12 hours, then 0.5 µg/kg/h for 4 hours	Improved mental status. No reported adverse events.
	14 years, female	Dextromethorphan		1 µg/kg/min over 10 minutes ×2 then 1.5 µg/kg/min for 8 hours and 1 µg/kg/min for 4 hours	Resolution of delirium. No reported adverse events.
	16 years, male	Methamphetamine		1 µg/kg/min over 10 minutes ×1 then 1 µg/kg/min for 8 hours	Resolution of delirium, tachycardia, and tachypnea. No reported adverse events.
Gee et al <sup>7</sup>	13 years, male	Diphenhydramine; Cotinine	Lorazepam	0.5 µg/kg/h infusion reduced to 0.3 µg/kg/h for 24 hours	Heart rate (HR) in 60s, which improved with dose reduction. QT normalization. Resolution of delirium.
	15 years, female	Divalproex sodium; Quetiapine; Buspirone	Haloperidol; Lorazepam	0.3 µg/kg/h infusion reduced by 0.1 µg/kg/h over 19 hours with final dose of 0.1 µg/kg/h	HR in 80s. BP in 86-95/40 which improved to 110s/60s with dose reduction. QT normalization. Improved mental status.
	17 years, male	Diphenhydramine	Lorazepam	1 µg/kg/h infusion reduced to 0.5 µg/kg/h for 24 hours	Transient bradycardia (HR 62-95), which improved with dose reduction. Improved mental status.
This study	3 years, male	Diphenhydramine	Midazolam; Lorazepam	0.5 µg/kg/h for 10 hours	Control of agitation and peripheral symptoms. No adverse events.
	15 years, female	Dicyclomine	Lorazepam	0.5 µg/kg/h for 4 hours then reduced to 0.2 µg/kg/h for 4 hours	QT normalization. Effective control of agitation. No adverse events.

Dexmedetomidine may also diminish the associated fever and flushing by its effect on thermoregulation both centrally and peripherally. Although dexmedetomidine requires continuous monitoring of hemodynamics, its wide availability, minimal effect on respiratory function, ease of titration, and predictable hemodynamic effects support its use as an adjunct therapy for treatment of anticholinergic toxidrome in pediatric patients.

## Conclusions

Dexmedetomidine can successfully treat anticholinergic toxidrome and can be a useful adjunct agent, especially in patients at risk of respiratory depression or cardiac toxicity. A larger prospective comparative study is needed to establish its usefulness.

## Author Contributions

KC: Contributed to literature review; drafted the manuscript; gave final approval; agrees to be accountable for all aspects of work ensuring integrity and accuracy.

RAL: Contributed to literature review; critically revised the manuscript; gave final approval; agrees to be accountable for all aspects of work ensuring integrity and accuracy.

AS: Contributed to conception; contributed to literature review; critically revised the manuscript; gave final approval; agrees to be accountable for all aspects of work ensuring integrity and accuracy.

## Declaration of Conflicting Interests

The author(s) declared no potential conflicts of interest with respect to the research, authorship, and/or publication of this article.

## Funding

The author(s) received no financial support for the research, authorship, and/or publication of this article.

## References

1. Dawson AH, Buckley NA. Pharmacological management of anticholinergic delirium—theory, evidence and practice. *Br J Clin Pharmacol*. 2016;81:516-524.
2. Mowry JB, Spyker DA, Brooks DE, Zimmerman A, Schauben JL. 2015 Annual Report of the American Association of Poison Control Centers' National Poison Data System (NPDS): 33rd Annual Report. *Clin Toxicol (Phila)*. 2016;54:924-1109.
3. Watkins JW, Schwarz ES, Arroyo-Plasencia AM, Mullins ME, Toxicology Investigators Consortium Investigators. The use of physostigmine by toxicologists in anticholinergic toxicity. *J Med Toxicol*. 2015;11:179-184.
4. Hamouda AK, Kimm T, Cohen JB. Physostigmine and galanthamine bind in the presence of agonist at the canonical and noncanonical subunit interfaces of a nicotinic acetylcholine receptor. *J Neurosci*. 2013;33:485-494.
5. Burns MJ, Linden CH, Graudins A, Brown RM, Fletcher KE. A comparison of physostigmine and benzodiazepines for the treatment of anticholinergic poisoning. *Ann Emerg Med*. 2000;35:374-381.
6. Moore PW, Rasimas JJ, Donovan JW. Physostigmine is the antidote for anticholinergic syndrome. *J Med Toxicol*. 2015;11:159-160.
7. Gee SW, Lin A, Tobias JD. Dexmedetomidine infusion to control agitation due to anticholinergic toxidromes in adolescents, a case series. *J Pediatr Pharmacol Ther*. 2015;20:329-334.
8. Tobias JD. Dexmedetomidine to control agitation and delirium from toxic ingestions in adolescents. *J Pediatr Pharmacol Ther*. 2010;15:43-48.
9. Walker A, Delle Donne A, Douglas E, Spicer K, Plum T. Novel use of dexmedetomidine for the treatment of anticholinergic toxidrome. *J Med Toxicol*. 2014;10:406-410.
10. Pentel P, Peterson CD. Asystole complicating physostigmine treatment of tricyclic antidepressant overdose. *Ann Emerg Med*. 1980;9:588-590.
11. Keating GM. Dexmedetomidine: a review of its use for sedation in the intensive care setting. *Drugs*. 2015;75:1119-1130.
12. Barends CR, Absalom A, van Minnen B, Vissink A, Visser A. Dexmedetomidine versus midazolam in procedural sedation. A systematic review of efficacy and safety. *PLoS One*. 2017;12:e0169525.
13. Gong M, Man Y, Fu Q. Incidence of bradycardia in pediatric patients receiving dexmedetomidine anesthesia: a meta-analysis. *Int J Clin Pharm*. 2017;39:139-147.