



## Case Report

## Disseminated coccidioidomycosis: Monitoring of serologic markers for treatment response



Dunja Wilmes<sup>a,\*</sup>, Daniela Schui<sup>b</sup>, Jürgen Held<sup>c</sup>, Sina Ackermann<sup>a</sup>, Udo Geipel<sup>d</sup>, Kai Emrich<sup>e</sup>, Ernst-Joachim Winkelmann<sup>f</sup>, Volker Rickerts<sup>a</sup>

<sup>a</sup> Robert Koch Institut, FG 16, Seestrasse 10, Berlin, 13353, Germany

<sup>b</sup> Bioscientia Institut für Medizinische Diagnostik GmbH, Konrad-Adenauer-Str. 17, 55218, Ingelheim, Germany

<sup>c</sup> Mikrobiologisches Institut - Klinische Mikrobiologie, Immunologie und Hygiene, Universitätsklinikum Erlangen und Friedrich-Alexander-Universität (FAU) Erlangen-Nürnberg, Wasserturmstrasse 3/5, 91054, Erlangen, Germany

<sup>d</sup> Bioscientia MVZ Saarbrücken GmbH, Winterberg 1, 66119, Saarbrücken, Germany

<sup>e</sup> Institut für Pathologie Saarbrücken-Rastpfuhl, Rheinstraße 2, 66113, Saarbrücken, Germany

<sup>f</sup> Facharzt für Innere Medizin und Pneumologie, Friedrich-Ebert-Straße 40, 66763, Dillingen/Saar, Germany

## ARTICLE INFO

## Keywords:

Coccidioidomycosis  
Endemic mycosis  
travel Related diseases  
Osteomyelitis  
Coccidioides qPCR

## ABSTRACT

We describe a patient with a disseminated coccidioidomycosis. Biomarkers in serum during itraconazole therapy showed a rapid clearing of *Coccidioides* DNA as detected by PCR. *Coccidioides* antibody detection by lateral flow assay became negative after one year and decreased from 1:64 to 1:8 in the complement fixation test after two years. The (1 → 3)-β-D-glucan levels normalised after two years without increase after cessation of antifungal therapy. Biomarkers in serum may guide treatment decisions in disseminated coccidioidomycosis.

## 1. Introduction

Coccidioidomycosis is a systemic fungal disease, caused by the thermally dimorphic fungus *Coccidioides* (*C.*). The two species, *C. immitis* and *C. posadasii* are found in the semi-arid, desert regions of America, including northern Mexico and different regions of South America. *C. immitis* is found in central and southern California, but also in Washington State [1], whereas infections by *C. posadasii* have been reported in parts of Latin America [2] and the United States from central and southern Arizona to western Texas and southern New Mexico [3].

The disease is acquired by inhalation of aerosolized arthroconidia, formed by the saprophytic mycelial form of the fungus. It is estimated that only a minority of infected people become symptomatic at a point to consult physicians. Among symptomatic patients, 90% experience a self-limited respiratory illness with less than one percent progressing to a disseminated disease [4]. Risk factors for dissemination include African and Filipino ancestry and cell-mediated immunological defects [5].

Besides central nervous system (CNS) and skin, skeleton is frequently involved in disseminated disease and can essentially affect

every bone or joint. Lesions are generally chronic and progressive and may lead to loss of function [6]. In one study conducted in an endemic region, more than half of the patients who underwent surgical biopsy or resection of osseous coccidioidomycosis had a previously documented history of coccidioidomycosis, in mean 4.2 years prior to the surgery [6]. In non-endemic regions these osteolytic lesions of coccidioidomycosis are often suspected to be malignant tumours [6].

*Coccidioides* antibody detection is a helpful tool to establish a presumptive diagnosis, but biopsy is necessary to exclude an underlying neoplastic disorder and to confirm the diagnosis by culturing of the fungus or histopathologic demonstration of tissue forms [6].

Current treatment guidelines recommend the use of azole therapy, unless the patients have extensive or limb-threatening skeletal or vertebral disease causing imminent cord compromise in which case amphotericin B is initially recommended eventually in association with surgical intervention [4]. The optimal length of treatment remains unknown, but most patients are treated for periods of 3 years to lifelong [4]. Biomarkers in serum may help to rationalize treatment decisions including treatment duration, but studies documenting different biomarkers during antifungal therapy in serum are scarce. Therefore, monitoring is not recommended in the current coccidioidomycosis

\* Corresponding author.

E-mail addresses: [WilmesD@rki.de](mailto:WilmesD@rki.de) (D. Wilmes), [Daniela.Schui@bioscientia.de](mailto:Daniela.Schui@bioscientia.de) (D. Schui), [juergen.held@uk-erlangen.de](mailto:juergen.held@uk-erlangen.de) (J. Held), [AckermannS@rki.de](mailto:AckermannS@rki.de) (S. Ackermann), [Udo.Geipel@bioscientia.de](mailto:Udo.Geipel@bioscientia.de) (U. Geipel), [K.Emrich@pathologie-saarbruecken.de](mailto:K.Emrich@pathologie-saarbruecken.de) (K. Emrich), [Info@Lungenarzt-Saarland.de](mailto:Info@Lungenarzt-Saarland.de) (E.-J. Winkelmann), [RickertsV@rki.de](mailto:RickertsV@rki.de) (V. Rickerts).

<https://doi.org/10.1016/j.mmcr.2020.05.007>

Received 14 May 2020; Received in revised form 20 May 2020; Accepted 25 May 2020

Available online 30 May 2020

2211-7539/© 2020 The Authors. Published by Elsevier B.V. on behalf of International Society for Human and Animal Mycology. This is an open access article under the CC BY-NC-ND license (<http://creativecommons.org/licenses/by-nc-nd/4.0/>).

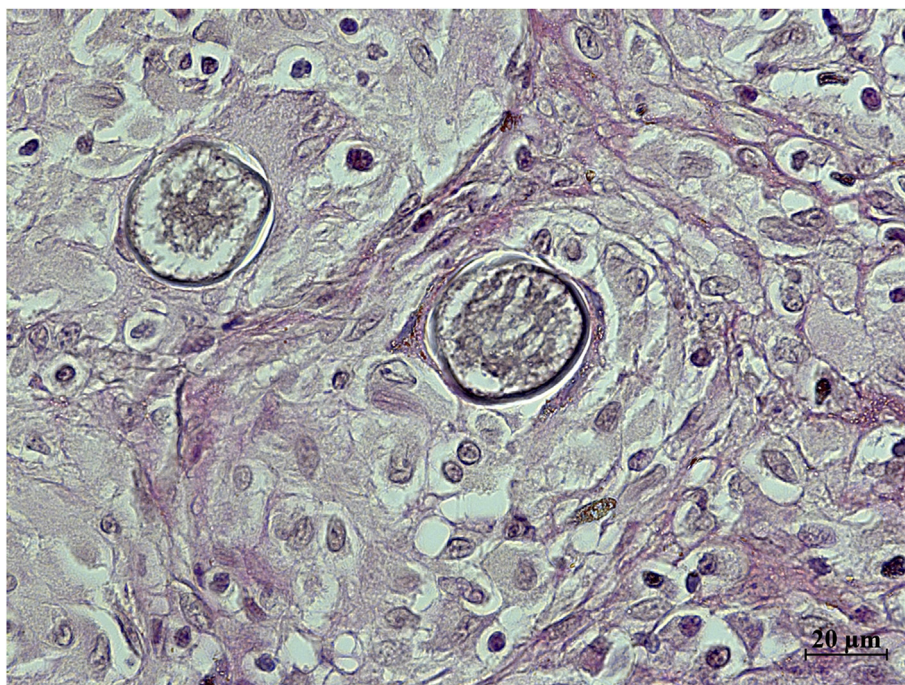


Fig. 1. Tissue biopsy of tumour showing characteristic (~20  $\mu\text{m}$ ) spherules consistent with coccidioidomycosis (Grocott's methenamine silver stain).

guidelines, even if anti-*Coccidioides* antibody titres measured by complement fixation (CF) are often used to evaluate treatment response [4,7].

In this case description we report the detection of *Coccidioides* antibodies, the (1  $\rightarrow$  3)- $\beta$ -D-Glucan (BDG) and *Coccidioides* DNA by a specific *Coccidioides* qPCR in sera of a patient with disseminated coccidioidomycosis in order to illustrate their potential use in monitoring of treatment response.

## 2. Case presentation

In December 2015, on day 0, a 74-year-old Caucasian male underwent a surgical biopsy of an ulcerative tumour on his ankle. Histopathology demonstrated spherules (Fig. 1) proving *Coccidioides* osteomyelitis. On day 7, the culture on Sabouraud dextrose agar showed growth of a mould at 30 °C and at 37 °C. Colonies were greyish and developed after one week an aerial mycelium. Microscopic examination showed fine hyphae falling apart in barrel shaped arthroconidia and diagnosis of *Coccidioides posadasii* was confirmed by sequencing of the partial ITS2 region (primers ITS4 and ITS5) [8]. Sequencing of partial 28S rDNA (primer 10F and 12R) [9] from the formalin fixed paraffin-embedded biopsy (FFPE) extracted DNA showed also identification of *Coccidioides*.

The patients' medical history included chronic arterial hypertension. Four years prior to the surgical sampling pneumonia was diagnosed (Fig. 2) several weeks after a camping trip to Texas. Despite a workup including bronchoalveolar lavage, no etiologic pathogen was identified. No serologic tests for *Coccidioides* were requested. The patient's symptoms improved under symptomatic treatment.

On day 0, the physical examination and chest radiograph were normal. Antibodies against *Coccidioides* were detected by a lateral flow assay (LFA) and CF test with a titre of 1:64.

In the absence of symptoms or signs indicating CNS disease, anti-fungal therapy was started using oral itraconazole (200 mg three times per day for three days followed by 200 mg twice a day) on day 15 until day 908. During this time the patient had to be treated by intravenous analgesia for severe hip osteoarthritis, which needed a total hip prosthesis on day 487 and subsequently on day 630 a revision surgery.

We performed a retrospective analysis of the biopsy sample, as well as of the sera (n = 15) sent for follow-up and stored at 20 °C.

### 2.1. *Coccidioides* qPCR

For serum DNA extraction, the Maxwell Blood 16 LEV DNA Kit (Promega GmbH, Mannheim, Germany) was used as described by the manufacturer. One extraction negative control, consisting of DNA free water per three samples was processed in parallel to document the absence of contamination during DNA extraction. For FFPE tissue DNA extraction, the protocol as described by Rickerts et al was used [10]. Each of these DNAs was studied by three different qPCRs. To document successful DNA extraction a qPCR detecting the human 18S rRNA gene [11] was used. An internal amplification control DNA (IAC qPCR) was used to identify PCR inhibition. *Coccidioides* DNA was amplified using an inhouse Taqman qPCR assay. Primers and probe were modified from a previously published report targeting the internal transcribed spacer region two (ITS2) of the rRNA gene complex of *Coccidioides* [12]. The primer sequences were Cocci ITS-2 fw 5'-ACCCTTCAAGCACGGCTT-3' and Cocci ITS-2 rev 5'-TACACTCAGACACCAGGAATC-3', and the probe was Cocci ITS-2 5'-6-FAM-AACGTCCTCCGCTTGT-MGB-3'. Analytical specificity of the in house assay was confirmed (100%) by testing fungal DNAs (1000 pg/reaction) (*Aspergillus fumigatus*, *Candida albicans*, *Exophiala dermatitidis*, *Histoplasma capsulatum*, *Talaromyces marneffe*, *Blastomyces dermatitidis*, *Uncinocarpus reesii*, *Paracoccidioides brasiliensis*, *Emergomycetes africanus*, *Emergomycetes europaeus*, *Emmonsia parva* and *Cryptococcus neoformans*) and human DNA. Analytical sensitivity was estimated at 0.001 pg/reaction using genomic DNA of a *Coccidioides* isolate.

All qPCRs were performed on the Bio-Rad CFX Maestro cyclor. Samples were tested in single tubes in the human DNA detecting qPCR and in the IAC qPCR for 40 cycles and in duplicates in the *Coccidioides* qPCR for 45 cycles. If inhibition ( $\Delta\text{C}_q$  of  $\geq 2$  cycles) was detected and fungal qPCRs remained negative, DNA extracted from serum samples was diluted by a factor of 10.

The initial FFPE sample tested positive for *Coccidioides* DNA although there was a detectable inhibition. The first serum showed evidence of inhibition and was therefore retested by the specific

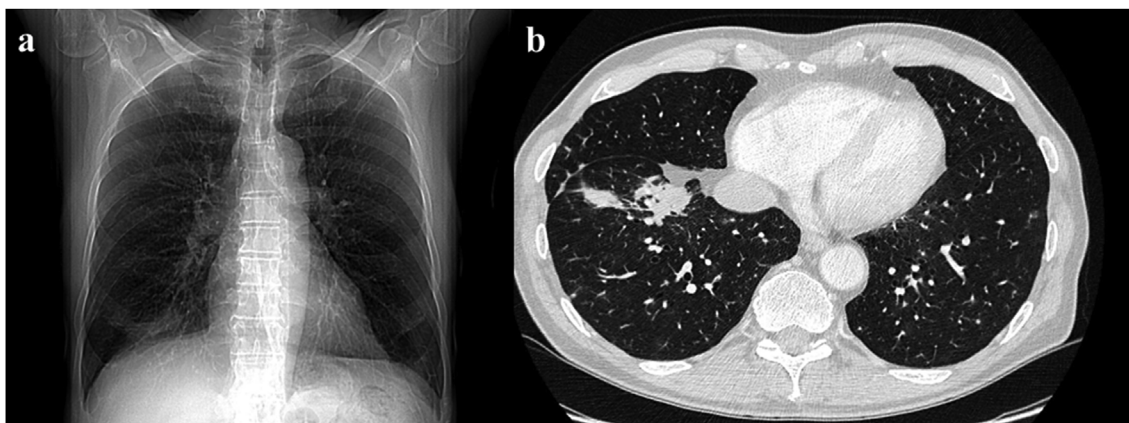


Fig. 2. Posterior-anterior chest radiograph (a) and axial section of a CT scan (b) four years prior to diagnosis of disseminated coccidioidomycosis demonstrating consolidation in the lower right lobe.

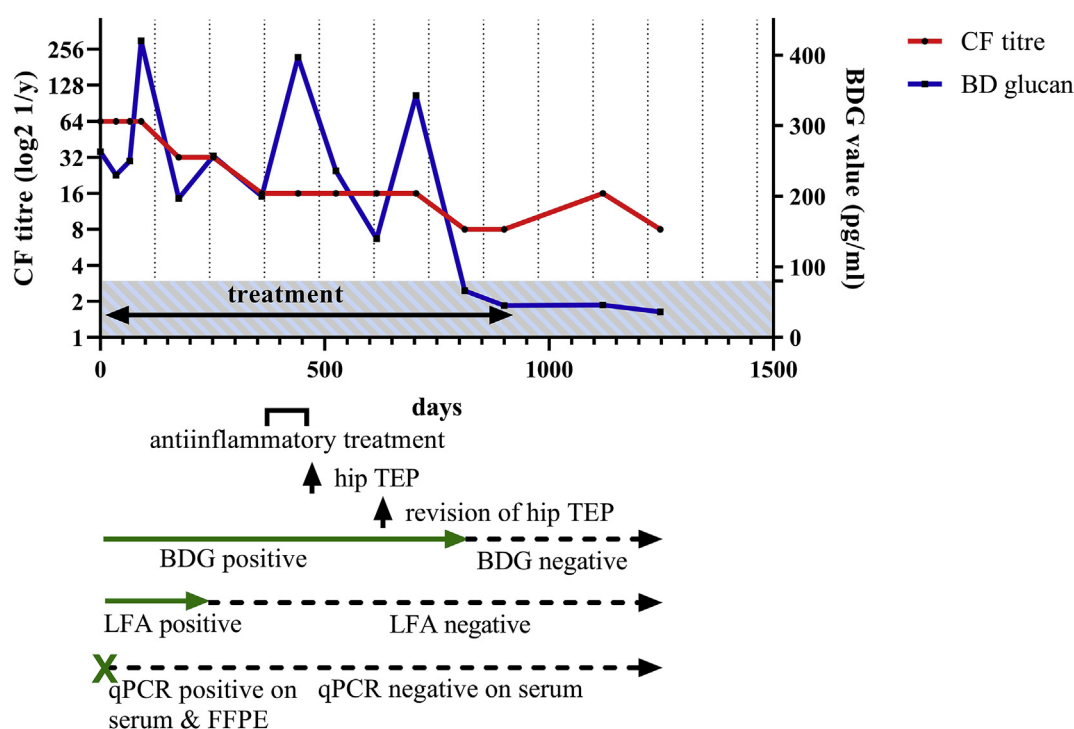


Fig. 3. Serologic markers and qPCR results on patient samples (sera: n = 15; FFPE: n = 1) before, during (day 15- day 908) and after antifungal therapy. Complement fixation titre (CF, red line) and (1 → 3)-β-D-Glucan assay (BDG, blue line) over time after starting therapy are displayed. Under the diagram are resumed the results of the tests: the specific *Coccidioides* qPCR (qPCR), the lateral flow assay (LFA) and the BDG (negative under 80 pg/ml, blue striped area). FFPE = formalin fixed paraffin-embedded tissue. (For interpretation of the references to colour in this figure legend, the reader is referred to the Web version of this article.)

*Coccidioides* qPCR at a 1:10 dilution. This diluted sample was tested positive for *Coccidioides* DNA. All following serum samples, which were taken after starting the therapy, remained negative in this specific qPCR (Fig. 3 and supplement 1).

2.2. Antibody and antigen detection

Anti-*Coccidioides* IgG and IgM antibodies were detected by a CF test (*Histoplasma* Yeast CF antigen, dilute, IMMY, USA) and a LFA (sōna *Coccidioides* Ab LFA, IMMY, USA). Sera were tested retrospectively in a single test run by semi-quantitative CF to study evolution during the treatment avoiding interrun variation. LFA was done qualitatively as described by the manufacturer and read visually by two laboratory workers.

While the LFA became negative on sera after one year of treatment, the CF titres decreased continuously to 1:8 after a little bit more than

two years of treatment (Fig. 3 and Appendix A).

Sera were also tested retrospectively for fungal antigens by a quantitative BDG test (Fungitell assay, Associates of Cape, Cod, USA) and became negative (< 80 pg/ml) after two years of treatment, however peaking several times during this time (Fig. 3 and Appendix A).

3. Discussion

Optimal treatment duration in patients with disseminated coccidioidomycosis is unknown. Most patients with bone or joint involvement are treated for three years to lifelong depending on the severity of disease and the immunocompetence of the host [4]. Biomarkers may offer insights into treatment response and personalize decisions on treatment duration. Semi-quantitative CF tests are widely used to monitor disease evolution. A recent study, including 434

coccidioidomycosis patients, described the titre trends under therapy [7]. The authors set the cut-off value for complicated infections (disseminated infections and CNS involvement) at  $\geq 1:32$ . Titre reduction rates for disseminated disease were  $\geq 4$  month per dilution, but about a third of these patients were serologic nonimprovers (who failed to decrease of at least one dilution step a year), as our patient, without evidence to affect clinical outcomes.

The place of antibody detection by LFA in the monitoring of disseminated coccidioidomycosis has not been studied so far. In our patient the LFA remained positive during the first year, as long as CF titres were  $\geq 1:32$ .

BDG, as a component of the cell wall of many fungal pathogens is independent of the immunological status of the patient and has subsequently a potential advantage in the diagnosis in immunosuppressed patients who may have undetectable specific antibody titres and in patients with hyperacute coccidioidomycosis. But data concerning sensitivity of this assay in coccidioidomycosis is limited.

One study of 12 patients showed serum BDG assay positivity ( $\geq 80$  pg/ml) in  $> 90\%$  of disseminated disease [13]. However, in another study by Thompson et al., serum BDG was detectable  $> 31$  pg/ml in 83% and elevated in only 10% of patients with disseminated and meningeal cases ( $n = 44$ ) [14]. The explanation of the authors was a possible compartmentalization of BDG in the central nervous system in CNS coccidioidomycosis [14]. So far, there is only scarce data on the value of BDG as follow-up marker in coccidioidomycosis. Thompson et al. found that BDG values correlated poorly with serum coccidioidal CF antibody titres an observation that is now confirmed by us [14]. In our patient, BDG was initially positive and decreased unsteadily below 80 pg/ml after 2 years. The decline of this measurement was marked by several peaks which weren't accompanied by an increase of the CF titres. Two of these peaks coincided with the patient's orthopaedic treatment by intravenous analgesia and a prosthetic hip replacement which needed surgical revision. It is known, that the administration of certain drugs (e.g. intravenous immunoglobulins or albumin) or surgical procedures (e.g. abdominal surgery) can cause false-positive BDG results [15]. Another reason for this could be the more or less panfungal nature of BDG leading to elevated levels not only in coccidioidomycosis but also in other invasive fungal diseases [15]. However, no other fungal infection was diagnosed in our patient.

We performed additionally a specific *Coccidioides* qPCR on an FFPE tissue sample from the resected tumour [12]. Even if spherules are specific for coccidioidomycosis, they are not found in around 19% of skeleton biopsies [6] and if they are found may be difficult to distinguish from rhinosporidiosis and adiasporomycosis [16,17].

The examination by *Coccidioides* qPCR of all sera, showed a positive result only in the first sample. One prior publication showed that *Coccidioides* DNA could be amplified through another *C. immitis* specific qPCR in 6 out of 64 sera and cerebrospinal fluid (CSF) that were provided for antibody detection tests. Of these PCR positive tested sera and CSF, four were antibody negative but developed subsequently positive titres [18]. However PCR positivity was transient and disappeared as antibodies appeared [18]. In our patient antibodies and *Coccidioides* DNA were detectable at the same time but DNA cleared rapidly with the start of itraconazole therapy.

In conclusion, detection of *Coccidioides* DNA from serum suggests the potential of qPCR as a non-invasive diagnostic tool for the diagnosis of disseminated infections in untreated patients. The application on pathology blocks may improve diagnosis in the absence of characteristic spherules. Subsequent failure to detect DNA from serum may serve as an indicator of early treatment response, but suggests low diagnostic

yield in treated patients. The CF antibody and the BDG test significantly decrease after 2–3 years. During that time, peaks of BDG may be observed without obvious worsening of disease.

#### Declaration of competing interestCOI

There are none.

#### Acknowledgements

This research did not receive any specific grant from funding agencies in the public, commercial, or not-for-profit sectors.

#### Appendix A. Supplementary data

Supplementary data related to this article can be found at <https://doi.org/10.1016/j.mmcr.2020.05.007>.

#### References

- [1] A.P. Litvintseva, N. Marsden-Haug, S. Hurst, H. Hill, L. Gade, E.M. Driebe, et al., Valley fever: finding new places for an old disease: *Coccidioides immitis* found in Washington State soil associated with recent human infection, *Clin. Infect. Dis.* 60 (1) (2015) e1–3.
- [2] R. Laniado-Laborín, E.G. Arathoon, C. Canteros, R. Muñiz-Salazar, A. Rendon, Coccidioidomycosis in Latin America, *Med. Mycol.* 57 (Supplement\_1) (2019) S46–S55.
- [3] J. Brown, K. Benedict, B.J. Park, G.R. Thompson 3rd, Coccidioidomycosis: epidemiology, *Clin. Epidemiol.* 5 (2013) 185–197.
- [4] J.N. Galgiani, N.M. Ampel, J.E. Blair, A. Catanzaro, F. Geertsma, S.E. Hoover, et al., 2016 infectious diseases society of America (IDSA) clinical practice guideline for the treatment of coccidioidomycosis, *Clin. Infect. Dis.* 63 (6) (2016) e112–e146.
- [5] L.M. Gabe, J. Malo, K.S. Knox, Diagnosis and management of coccidioidomycosis, *Clin. Chest Med.* 38 (3) (2017) 417–433.
- [6] R.W. Ricciotti, T.A. Shekkel, J.E. Blair, T.V. Colby, R.E. Sobonya, B.T. Larsen, Surgical pathology of skeletal coccidioidomycosis: a clinical and histopathologic analysis of 25 cases, *Am. J. Surg. Pathol.* 38 (12) (2014) 1672–1680.
- [7] I.H. McHardy, B.N. Dinh, S. Waldman, E. Stewart, D. Bays, D. Pappagianis, et al., Coccidioidomycosis complement fixation titer trends in the age of antifungals, *J. Clin. Microbiol.* 12 (2018) 56.
- [8] T. White, T. Burns, S. Lee, J. Taylor, Analysis of Phylogenetic Relationships by Amplification and Direct Sequencing of Ribosomal RNA Genes, in: M.A. Innis, D.H. Gelfand, J.J. Sninsky, T.J. White (Eds.), *A Guide to Methods and Applications*, Academic Press, New York, 1990, pp. 315–322 PCR Protocols.
- [9] P.D. Khot, D.L. Ko, D.N. Fredricks, Sequencing and analysis of fungal rRNA operons for development of broad-range fungal PCR assays, *Appl. Environ. Microbiol.* 75 (6) (2009) 1559–1565.
- [10] V. Rickerts, P.D. Khot, D.L. Ko, D.N. Fredricks, Enhanced fungal DNA-extraction from formalin-fixed, paraffin-embedded tissue specimens by application of thermal energy, *Med. Mycol.* 50 (6) (2012) 667–672.
- [11] P.D. Khot, D.L. Ko, R.C. Hackman, D.N. Fredricks, Development and optimization of quantitative PCR for the diagnosis of invasive aspergillosis with bronchoalveolar lavage fluid, *BMC Infect. Dis.* 8 (2008) 73.
- [12] M.J. Binnicker, S.P. Buckwalter, J.J. Eisberner, R.A. Stewart, A.E. McCullough, S.L. Wohlfiel, et al., Detection of *Coccidioides* species in clinical specimens by real-time PCR, *J. Clin. Microbiol.* 45 (1) (2007) 173–178.
- [13] T.T. Zangeneh, J. Malo, C. Luraschi-Monjagatta, C.A. Hage, L.J. Wheat, C. Strawter, et al., Positive (1-3) B-d-glucan and cross reactivity of fungal assays in coccidioidomycosis, *Med. Mycol.* 53 (2) (2015) 171–173.
- [14] G.R. Thompson 3rd, D.J. Bays, S.M. Johnson, S.H. Cohen, D. Pappagianis, M.A. Finkelman, Serum (1- > 3)-beta-D-glucan measurement in coccidioidomycosis, *J. Clin. Microbiol.* 50 (9) (2012) 3060–3062.
- [15] L. Ostrosky-Zeichner, B.D. Alexander, D.H. Kett, J. Vazquez, P.G. Pappas, F. Saeki, et al., Multicenter clinical evaluation of the (1- > 3) beta-D-glucan assay as an aid to diagnosis of fungal infections in humans, *Clin. Infect. Dis.* 41 (5) (2005) 654–659.
- [16] S. Bhargava, M. Grover, V. Maheshwari, Rhinosporidiosis: intraoperative cytological diagnosis in an unsuspected lesion, *Case Rep. Pathol.* 2012 (2012) 101832.
- [17] D.M. England, L. Hochholzer, Adiasporomycosis: an unusual fungal infection of the lung. Report of 11 cases, *Am. J. Surg. Pathol.* 17 (9) (1993) 876–886.
- [18] S.M. Johnson, K.A. Simmons, D. Pappagianis, Amplification of coccidioidal DNA in clinical specimens by PCR, *J. Clin. Microbiol.* 42 (5) (2004) 1982–1985.