

Acute Painful Reversible Steroid Myopathy with IV Methylprednisolone

Sir

A 20-year-old boy presented with a history of excessive sleepiness for the last one year. Two months earlier he started developing unsteadiness and a tendency to fall to the left along with horizontal diplopia, worse on looking to the left side. Two weeks prior to admission, he developed slurring of speech and inability to walk without support. There were no systemic symptoms. Magnetic resonance imaging (MRI) brain showed symmetrical flair hyperintensities in the mammillary bodies, periaqueductal grey matter, caudate nucleus, mid-brain, and bilateral thalamocapsular region. CSF study was normal. Paraneoplastic workup was negative. Erythrocyte sedimentation rate (ESR), C-reactive protein (CRP), and routine blood investigations were normal. He was treated as a possible case of Wernicke's encephalopathy with high dose thiamine injections, however he continued to worsen and was admitted in our department. On examination, he had severe dysarthria, skew deviation (left eye hypertropia), bilateral ptosis, bilateral pyramidal signs and left ataxic hemiparesis. A repeat MRI brain with contrast showed patchy confluent involvement with patchy and nodular enhancement affecting the upper brainstem, hypothalamus/thalamus basal ganglia, and internal capsules. A differential diagnosis of primary CNS lymphoma, parenchymal neuro-Behcet's disease, neuro-sweet syndrome, paraneoplastic encephalitis, or other CNS inflammatory disease was considered. The pathergy test was clinically positive (2 mm papule at 48 h) and a skin biopsy was taken from the site. Human leukocyte

antigen (HLA)-B5 (51, 52) test was negative, however, a provisional diagnosis of parenchymal neuro-Behcets disease was made.

He was started on 750 mg of IV methylprednisolone per day for 5 days. By day 2, his neurological signs disappeared. On day 3 after starting steroids, he started complaining of severe body pain and muscle tenderness. On day 4, a whole body fluorodeoxyglucose positron emission tomography-computed tomography (FDG-PET CT) was normal. He continued to worsen and developed grade 0/5 Medical Research Council (MRC) power in the proximal upper and lower limbs with normal distal power by day 6. Deep tendon reflexes and cranial nerve examination were normal. On day 6, creatinine phosphokinase (CPK) levels were 60 u/L. Serum electrolytes and calcium, phosphorus, magnesium, and 25 OH vitamin D levels were normal. Nerve conduction velocity (NCV) and repetitive nerve stimulation (RNS) study were normal and electromyography (EMG) showed scattered proximal muscle denervation (positive sharp waves and fibrillations), with small myopathic potentials and increased recruitment. A whole body short tauinversion recovery (STIR) MRI muscle imaging was performed to look for any underlying myositis and was normal [Figure 1]. As he was not receiving any other medications, the possibility of acute steroid myopathy was considered. He continued to complain of severe myalgia and had severe proximal muscle tenderness. However, by day 7, his muscle power started improving and by day 9, power had improved to

Table 1: Differences between acute and chronic steroid myopathies and Critical illness myopathy

	Acute steroid myopathy	Chronic steroid myopathy	Critical illness myopathy
Onset	1-15 days of steroid therapy	Weeks to years	3 days to weeks after admission
Setting	Stable patients	Ambulant patients	Critically ill patients (sepsis and multi-organ failure)
Clinical presentation	Proximal musculature	Proximal musculature	Generalised, often sparing cranial nerves. Respiratory weakness and inability to wean from ventilator are common.
Myalgia	+/-	Absent	Absent
Rhabdomyolysis	May occur	No	Seen with the necrotizing variant
Recovery	Can occur within days	Takes weeks to months	Takes weeks to months
Nerve conduction studies	Normal	Normal	CMAPs, SNAPs can be abnormal with a concurrent critical illness polyneuropathy
EMG	Normal	Myopathic potentials	May show denervation and myopathic potentials
Muscle biopsy	Normal	Type II fiber atrophy. Increased fiber type variation.	Shows selective loss of myosin and loss of type 2 > type 1 fibers
	Rarely can show a necrotizing myopathy with a vacuolar appearance	No evidence of inflammation, necrosis or regeneration.	May show features of denervation and reinnervation with small muscle fibers, fiber-type grouping, and grouped fiber group. Nerve biopsy can show sensori-motor axonal degeneration

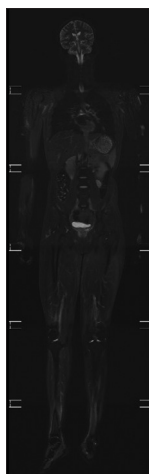


Figure 1: Whole body coronal STIR MRI images showing normal muscle intensities

grade 4+/5 MRC. He was administered vitamin injections and paracetamol for pain. A Naranjo adverse drug reaction causality assessment score was 6 suggesting a probable association with steroids.

Acute steroid myopathy (ASM) is probably underdiagnosed and less than 50 patients with ASM have been reported. It is reportedly seen more often with fluorinated steroids (triamcinolone, betamethasone, and dexamethasone) than non fluorinated steroids. ASM is often well-recognized in patients with underlying respiratory illness [asthma or Chronic obstructive pulmonary disease (COPD)] or cancer. It can occur idiosyncratically with the first dose, although it usually occurs within 1–3 days, usually within 15 days of onset of steroid therapy. The cumulative steroid dosage could also play a role and doses >1 mg/kg/day of prednisone are more likely to produce an ASM.^[1] The route of administration (PO, IV, IM, inhaled, epidural) is probably unimportant and ASM can occur with any mode of steroid administration. The typical presentation includes a rapidly evolving proximal limb muscle weakness with or without myalgia. ASM can progress to distal limb with bulbar or respiratory muscle involvement requiring mechanical ventilation. Generalized muscle atrophy and rhabdomyolysis can occur.^[2] Patients with COPD or asthma can develop an isolated respiratory muscle weakness without limb weakness. Additional neck flexor weakness has been noted in cancer patients who receive dexamethasone.^[1] Most patients improve within days to months after steroid cessation if the condition is recognized early and steroids are discontinued. Some cases are left with residual deficits or their condition worsens as the underlying cancer progresses.^[3]

In most cases, steroid myopathy is recognized retrospectively after days to months of therapy or by the time a chronic steroid myopathy has set in and hence patients are left with residual weakness. CPK levels, muscle biopsies, nerve conduction studies, and repetitive nerve stimulation studies

are normal. Electromyographic (EMG) studies are often normal but may show myopathic potentials. All types of steroids can induce type II b (fast-twitch) fiber atrophy in a chronic steroid myopathy.^[4] Muscle biopsies in ASM are less likely to be performed, but may disclose a necrotizing myopathy with a vacuolar appearance, although it is more likely to be normal.^[5] ASM can occur with fluorinated or non fluorinated steroid preparations such as methylprednisolone. In most cases, it is probably an idiosyncratic reaction that occurs within 2 weeks of steroid therapy and affects proximal muscles more than the distal muscles initially. Severe myalgia with normal tendon reflexes, serum CPK levels, normal nerve conduction, and EMG studies should prompt the consideration of an iatrogenic disorder. Whole body muscle short TI inversion recovery (STIR) imaging contributes another layer of diagnostic certainty.

Neurologists will encounter this type of acute flaccid paralysis in the context of steroid therapy for neuro-inflammatory conditions or general medical illnesses. The differential diagnosis in this situation include neuromuscular diseases such as Guillain-barre syndrome (GBS), critical illness myo-neuropathy, hypo or hyperkalemic paralysis, myasthenia gravis, inflammatory myopathy, hypophosphatemia, hypermagnesemia, or weakness secondary to the underlying illness. After ruling out these conditions, ASM should be included in the differential diagnosis. Critical illness myopathy usually occurs in ventilated patients, is not associated with severe myalgia and takes weeks to months to recover [Table 1]. We had previously published a mnemonic for acute generalized weakness in the ICU, which included steroid induced weakness. This report emphasizes the entity of an acute steroid myopathy. In our patient, early recognition of the condition and the use of a non fluorinated rather than a fluorinated steroid led to a full and early recovery^[6] This is also the first report of a whole body STIR MRI imaging in acute steroid myopathy.

Financial support and sponsorship

Nil.

Conflicts of interest

There are no conflicts of interest.

Boby Varkey Maramattom, Hanna Angel Meleth

Department of Neurology, Division of Neurocritical Care, Aster Med City, Kothad, Kochi, Kerala, India

Address for correspondence: Dr. Boby Varkey Maramattom, Department of Neurology, Division of Neurocritical Care, Aster Med City, Kothad, Kochi - 682 023, Kerala, India. E-mail: bobvarkey@gmail.com

REFERENCES

1. Batchelor TT, Taylor LP, Thaler HT, Posner JB, DeAngelis LM. Steroid myopathy in cancer patients. *Neurology* 1997;48:1234-8.
2. Dekhuijzen PN, Decramer M. Steroid-induced myopathy and its significance to respiratory disease: A known disease rediscovered. *Eur Respir J* 1992;5:997-1003.

3. Haran M, Schattner A, Kozak N, Mate A, Berrebi A, Shvidel L. Acute steroid myopathy: A highly overlooked entity. QJM 2018;111:307-11.
4. van Balkom RH, van der Heijden HF, van Herwaarden CL, Dekhuijzen PN. Corticosteroid-induced myopathy of the respiratory muscles. Neth J Med 1994;45:114-22.
5. George KK, Pourmand R. Toxic myopathies. Neurol Clin 1997;15:711-30.
6. Perrot S, Le Jeunne C. [Steroid-induced myopathy]. Presse Med 2012;41:422-6.

Submitted: 21-Mar-2020 **Revised:** 06-Apr-2020 **Accepted:** 25-Apr-2020

Published: 28-Apr-2021

This is an open access journal, and articles are distributed under the terms of the Creative Commons Attribution-NonCommercial-ShareAlike 4.0 License, which allows others to remix, tweak, and build upon the work non-commercially, as long as appropriate credit is given and the new creations are licensed under the identical terms.

DOI: 10.4103/aian.AIAN_200_20