

Identification of presumed pathogenic *KRT3* and *KRT12* gene mutations associated with Meesmann corneal dystrophy

Judy L. Chen, Benjamin R. Lin, Katherine M. Gee, Jessica A. Gee, Duk-Won D. Chung, Ricardo F. Frausto, Sophie X. Deng, Anthony J. Aldave

Stein Eye Institute, David Geffen School of Medicine at UCLA, Los Angeles, CA

Purpose: To report potentially pathogenic mutations in the keratin 3 (*KRT3*) and keratin 12 (*KRT12*) genes in two individuals with clinically diagnosed Meesmann corneal dystrophy (MECD).

Methods: Slit-lamp examination was performed on the probands and available family members to identify characteristic features of MECD. After informed consent was obtained, saliva samples were obtained as a source of genomic DNA, and screening of *KRT3* and *KRT12* was performed. Potentially pathogenic variants were screened for in 200 control chromosomes. PolyPhen-2, SIFT, and PANTHER were used to predict the functional impact of identified variants. Short tandem repeat genotyping was performed to confirm paternity.

Results: Slit-lamp examination of the first proband demonstrated bilateral, diffusely distributed, clear epithelial microcysts, consistent with MECD. Screening of *KRT3* revealed a heterozygous missense variant in exon 1, c.250C>T (p.(Arg84Trp)), which has a minor allele frequency of 0.0076 and was not identified in 200 control chromosomes. In silico analysis with PolyPhen-2 and PANTHER predicted the variant to be damaging to protein function; however, SIFT analysis predicted tolerance of the variant. The second proband demonstrated bilateral, diffusely distributed epithelial opacities that appeared gray-white on direct illumination and translucent on retroillumination. Neither parent demonstrated corneal opacities. Screening of *KRT12* revealed a novel heterozygous insertion/deletion variant in exon 6, c.1288_1293delinsAGCCCT (p.(Arg430_Arg431delinsSerPro)). This variant was not present in either of the proband's parents or in 200 control chromosomes and was predicted to be damaging by PolyPhen-2, PANTHER, and SIFT. Haplotype analysis confirmed paternity of the second proband, indicating that the variant arose de novo.

Conclusions: We present a novel *KRT12* mutation, representing the first de novo mutation and the first indel in *KRT12* associated with MECD. In addition, we report a variant of uncertain significance in *KRT3* in an individual with MECD. Although the potential pathogenicity of this variant is unknown, it is the first variant affecting the head domain of K3 to be reported in an individual with MECD and suggests that disease-causing variants associated with MECD may not be restricted to primary sequence alterations of either the helix-initiation or helix-termination motifs of K3 and K12.

First described in 1935 by Pameijer, and later in 1939 by Meesmann and Wilke, Meesmann corneal dystrophy (MECD; OMIM 122100) is a rare dominantly inherited disorder affecting the corneal epithelium [1,2]. MECD is primarily characterized by the presence of fine round intraepithelial microcysts that are diffusely distributed or limited to the interpalpebral zone, extending to the limbus [3,4]. Although individuals with MECD may be asymptomatic, they typically experience mild symptoms, including glare, photophobia, foreign body sensation, lacrimation, contact lens intolerance, recurrent corneal erosions, as well as deterioration in visual acuity [5]. The most severe cases may necessitate phototherapeutic keratectomy (PTK) and, rarely, lamellar or penetrating keratoplasty to manage corneal erosions or visual impairment secondary to subepithelial scarring and associated irregular astigmatism [6,7]. However, symptoms are expected to recur

as the abnormal limbal epithelial stem cells repopulate the corneal epithelium after PTK or keratoplasty [8,9].

MECD was first linked to mutations in the (*KRT3*; gene ID #3850; OMIM #148043) and keratin 12 (*KRT12*; gene ID #3859; OMIM #601687) genes in 1997 by Irvine et al [6]. These genes encode the highly conserved, cornea-specific keratins K3 and K12, which are the intermediate filament proteins primarily responsible for imparting mechanical strength and structural support to corneal epithelial cells [10]. As corneal keratins naturally occur as obligate K3/K12 heterodimers, gene mutations altering the encoded protein of either *KRT3* or *KRT12* are expected to negatively impact the K3/K12 heterodimer complex. To date, 25 mutations in *KRT3* and *KRT12* have been identified in individuals with MECD, each located in the helix-initiation (*KRT12*) or helix-termination (*KRT3* and *KRT12*) motifs (Table 1). Herein, we report the first de novo mutation associated with MECD, highlighting the clinical utility of molecular genetic analysis in the diagnosis of a dominantly inherited corneal disorder in the absence of a family history. Additionally, we report a

Correspondence to: Anthony J. Aldave, Stein Eye Institute, 100 Stein Plaza, UCLA, Los Angeles, CA 90095-7003; Phone: (310) 206-7202; FAX: (310) 794-7906; email: aldave@jsei.ucla.edu

TABLE 1. MUTATIONS IN *KRT3* AND *KRT12* ASSOCIATED WITH MECD.

Gene	Exon	Nucleotide change	Amino acid change	References
<i>KRT3</i>	1	c.250C>T*	p.(Arg84Trp)*	Current study
	7	c.1493A>T	p.(Glu498Val)	[10]
	7	c.1508G>C	p.(Arg503Pro)	[26]
	7	c.1525G>A	p.(Glu509Lys)	[6]
<i>KRT12</i>	1	c.385A>G	p.(Met129Val)	[27]
	1	c.386T>C	p.(Met129Thr)	[28,29]
	1	c.389A>C	p.(Gln130Pro)	[31,32]
	1	c.395T>A	p.(Leu132His)	[33]
	1	c.395T>C	p.(Leu132Pro)	[8]
	1	c.399T>G	p.(Asn133Lys)	[9]
	1	c.403A>G	p.(Arg135Gly)	[15]
	1	c.404G>T	p.(Arg135Ile)	[15]
	1	c.404G>C	p.(Arg135Thr)	[29,30]
	1	c.405A>C	p.(Arg135Ser)	[13]
	1	c.409G>C	p.(Ala137Pro)	[34]
	1	c.419T>G	p.(Leu140Arg)	[15]
	1	c.419T>A	p.(Leu140Gln)	[31]
	1	c.427G>C	p.(Val143Leu)	[6]
	1	c.427G>T	p.(Val143Leu)	[18]
	6	c.1198_1199ins27	p.(Leu399_Gln400ins9)	[13]
	6	c.1276A>G	p.(Ile426Val)	[35]
	6	c.1277T>G	p.(Ile426Ser)	[28]
	6	c.1285T>G	p.(Tyr429Asp)	[15]
	6	c.1286A>G	p.(Tyr429Cys)	[26]
6	c.1288_1293delinsAGCCCT	p.(Arg430_Arg431delins-SerPro)	Current study	
6	c.1289G>C	p.(Arg430Pro)	[36]	
6	c.1298T>G	p.(Leu433Arg)	[37]	

*Pathogenicity of this variant is uncertain.

variant of unknown significance in the head domain of K3, which also represents the first potential mutation in either *KRT3* or *KRT12* associated with MECD that is not located within a helix-initiation or helix-termination motif.

METHODS

Two individuals referred to one of the authors (AJA) were recruited for this study. Proband 1 is a 60-year-old man, and proband 2 is an 8-year-old boy, both otherwise healthy at the time of enrollment. The mother and father of proband 2 were also recruited. Informed consent was obtained from all subjects according to the tenets of the Declaration of Helsinki, and the study adhered to the ARVO statement on human subjects. The Institutional Review Board at the University of

California, Los Angeles approved the study described herein (UCLA IRB #11-000020).

Slit-lamp imaging, DNA collection, and preparation: Saliva samples were collected from both probands and the parents of proband 2 using the Oragene Saliva Collection Kit (DNA Genotek, Inc., Ottawa, Canada). Genomic DNA was extracted from buccal epithelial cells using the Oragene prepIT•L2P protocol for genomic DNA purification (DNA Genotek, Inc.). Slit-lamp biomicroscopic imaging was performed for all individuals from whom DNA was collected.

PCR and gel extraction: The exonic regions of *KRT3* and *KRT12* were amplified using custom designed primers (Appendix 1). Reactions were prepared as 25 µl mixtures containing 1X KAPA GC/A buffer (Kapa Biosystems,

Wilmington, MA), 200 μ M dNTPs, 1 unit of Kapa 2G Robust DNA polymerase (Kapa Biosystems), 240 nM of each forward and reverse primer, and 20–40 ng of genomic DNA. A C1000 Touch Thermal Cycler (Bio-Rad, Hercules, CA) was used to perform thermal cycling. Reactions were cycled with the following program: denaturation at 95 °C for 3 min; 36 cycles of annealing and extension at 95 °C for 30 s, 50–60 °C for 30 s, 72° for 30 s; and elongation at 72 °C for 10 min. Amplified DNA was purified using the QIAquick Gel Extraction Kit according to the manufacturer's instructions (Qiagen, Hilden, Germany).

DNA sequencing: Before sequencing, 15–30 ng of each amplicon was purified by treatment with 5.0 units of exonuclease I and 0.5 units of shrimp alkaline phosphatase (USB Corp., Cleveland, OH), followed by incubation at 37 °C for 15 min and inactivation at 80 °C for 15 min. Bidirectional sequencing of the purified PCR template was performed by Laragen Sequencing & Genotyping (Laragen Inc., Culver City, CA). Sequences were viewed using 4Peaks (Nucleobytes Inc., Amsterdam, The Netherlands), and the *KRT3* and *KRT12* exon and exon-intron junction sequences were compared to the NCBI reference sequences for *KRT3* (Genbank Accession: [NM_057088.2](#)) and *KRT12* (Genbank Accession: [NM_000223](#)). Identified sequence variants were annotated according to the [HGVS](#) nomenclature guidelines. The [dbSNP](#), [1000 Genomes](#), and [Exome Aggregation Consortium](#) browser databases were used to identify the minor allele frequencies of identified variants.

Paternity testing: DNA samples from proband 2 and his parents were submitted to Genetica DNA Laboratories, Inc. (Cincinnati, OH) for paternity testing. Genotyping was performed for a gender-associated marker, amelogenin, and 15 different short tandem repeats using the PowerPlex 16 HS System (Promega Corporation, Madison, WI).

In silico protein analysis: A web tool ([DNAtoProtein](#)) was used to generate an in silico translation of the mutant *KRT3* and *KRT12* sequences. [PolyPhen-2](#), [SIFT](#), and [PANTHER](#) were used to predict the functional impact of the identified variants. [ConSurf](#) was used to predict the evolutionary conservation of the amino acids affected by each identified variant.

RESULTS

Clinical findings:

Case 1—A 60-year-old Caucasian man (proband 1) with a history of corneal epitheliopathy since age 2 was examined by two of the authors (S.X.D. and A.J.A.). He reported experiencing episodes of foreign body sensation, tearing,

stinging, photophobia, and decreased visual acuity approximately every 6 months. Corneal epithelial debridement had been performed previously, with relief of symptoms for up to 1 year. Corrected distance visual acuity (CDVA) measured 20/20 OU, and slit-lamp biomicroscopic examination revealed bilateral, diffusely distributed, fine, clear epithelial microcysts (Figure 1A). Given the confluent nature of the fine epithelial microcysts, the cornea demonstrated a stippled appearance following the instillation of fluorescein dye (Figure 1B). The proband's parents were deceased, he had no siblings, and his only offspring, a daughter, was not available for examination or genetic testing.

Case 2—An 8-year-old Caucasian boy (proband 2) was examined by one of the authors (A.J.A.). The patient has had a history of photophobia since age 1 and was diagnosed with MECD by an outside provider following an exam under anesthesia at age 2. The proband's parents denied a family history of either MECD or corneal transplantation. Uncorrected Snellen visual acuities measured 20/200–1 OD (pinhole 20/80) and 20/80–2 OS (pinhole no improvement). Slit-lamp examination revealed diffuse, bilateral punctate gray-white epithelial opacities. In the superior and inferior corneal quadrants, the epithelial opacities appeared as parallel lines that stained with fluorescein and extended to the limbus (Figure 1C,D). Both of the proband's parents were also examined and demonstrated clear corneas.

Genetic screening: Screening of *KRT3* in proband 1 revealed three heterozygous missense variants and one synonymous substitution, but screening of *KRT12* demonstrated one heterozygous missense variant (Appendix 2). Each identified variant has been reported to be present in more than 5% of the population, except c.250C>T (p.(Arg84Trp)) in *KRT3* exon 1, which corresponds to the head domain of the K3 protein (Figure 2A). The presence of the variant was confirmed with forward and reverse sequencing, and by sequencing with a second primer pair. Although the variant was not identified in 200 control chromosomes, it has been reported to be present in 80/66,638 Europeans (0.1%) and 186/10,380 Africans (1.8%) according to the Exome Aggregation Consortium browser database, with an overall minor allele frequency (MAF) of 0.0076 per the dbSNP and 1000 Genomes databases.

Screening of *KRT3* in proband 2 demonstrated two of the three missense variants and the synonymous substitution identified in proband 1, each homozygous (Appendix 2). Screening of *KRT12* demonstrated a novel heterozygous insertion/deletion variant (indel), c.1288_1293delCGCCGCinsAGCCCT (p.(Arg430_Arg431delinsSerPro)), in the helix-termination motif. The presence of this variant in exon 6 was confirmed with forward and reverse sequencing, and by sequencing

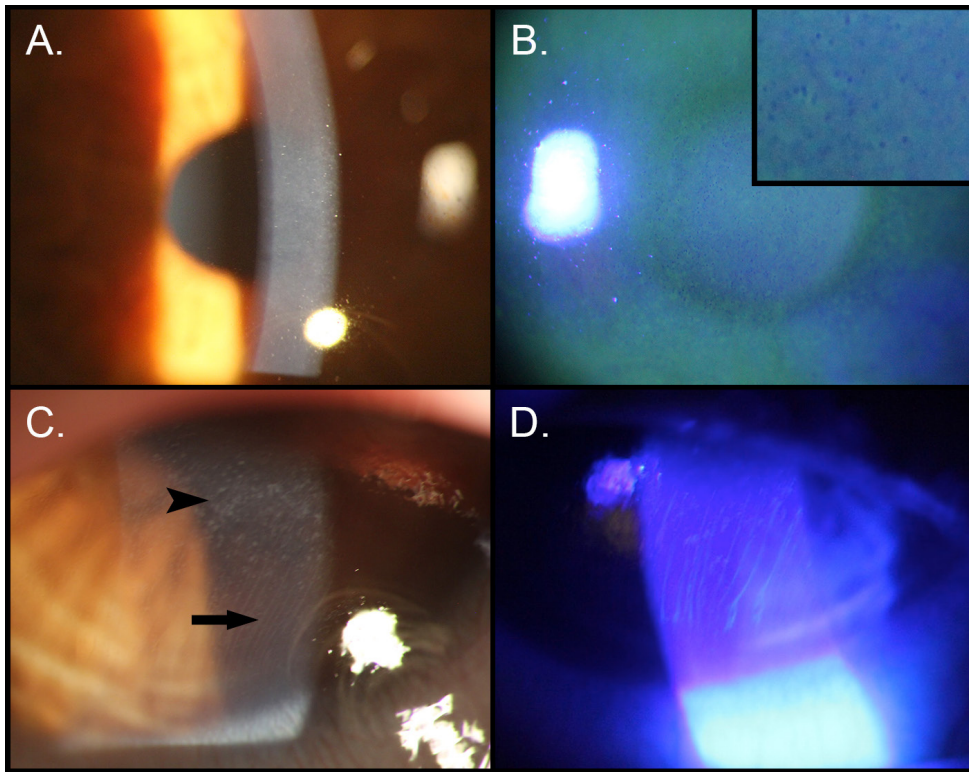


Figure 1. Slit-lamp photomicrographs of two individuals with Meesmann corneal dystrophy. **A:** Proband 1, left eye. Direct illumination demonstrates subtle, fine round epithelial opacities best visualized at the pupillary border. **B:** Proband 1, left eye. Fluorescein staining reveals generalized stippling of the epithelium, produced by diffuse epithelial microcysts (inset). **C:** Proband 2, right eye. Gray-white corneal epithelial opacities are observed in the central cornea (arrowhead), and gray-white parallel epithelial lines are present in the inferior corneal periphery (arrow). **D:** Proband 2, left eye. Fluorescein staining of the peripheral, linear corneal epithelial opacities is seen.

with a second primer pair. The variant was not identified in the unaffected mother or father of the proband, or in 200 control chromosomes. Genotyping of the proband and his parents confirmed (with greater than 99.999% certainty) that the proband's mother and father were his biological parents (Table 2).

Protein in silico analysis: In silico analysis with PolyPhen-2 and PANTHER predicted p.(Arg84Trp) in K3 to be likely damaging to protein function; however, SIFT analysis predicted that the missense change would be tolerated (Table 3). In addition, ConSurf assigned amino acid 84 of K3 a score of 4 (scale: 1–9), indicative of slightly variable conservation across species.

Both missense mutations identified in *KRT12* in proband 2, p.(Arg430Ser) and p.(Arg431Pro), were predicted to be damaging to the function of the encoded protein by all three protein prediction tools. ConSurf calculations assigned amino acid 430 a score of 9, which indicates the highest level of conservation across species, and amino acid 431 a score of 5, which indicates average conservation across species.

DISCUSSION

Keratins are a group of structural proteins in the epithelia of the skin, hair, nails, and cornea. These proteins occur as obligate heteropolymers, assembled from dimers composed of type I and type II intermediate filaments. In the cornea, the type I intermediate filament is K12, but the type II intermediate filament is K3 [11]. Structurally, intermediate filaments consist of an N-terminal head domain, a central α -helical rod domain that begins with a helix-initiation motif and ends with a helix-termination motif, and a C-terminal tail domain (Figure 3) [12,13]. The rod domain, and in particular the helix boundary motifs, is highly conserved across species. Thus, mutations in this region often substantially alter the structure of the encoded keratin protein and negatively impact keratin function [14,15]. Specifically, mutations in the helix boundary motifs have been observed to compromise intermediate filament assembly during the early stages of filament elongation, resulting in cytoplasmic filament clumping and more severe disease phenotypes than those associated with mutations of other keratin protein domains [11,14,16]. Keratin gene mutations have consequently been linked to several tissue-specific fragility syndromes, with certain features commonly observed, such as cytolysis, hyperkeratosis, and filament aggregation [16].

The head domain, while fairly conserved, varies the most between tissue-specific keratins, and therefore accounts for the diversity of keratins among epithelia [16]. In contrast to the helical rod domains, which form the backbone of the keratin filaments and are responsible for maintaining the structural integrity of the heterodimer unit, the head domain plays a more significant role in higher-order intermediate filament assembly [12,16]. These assembly functions include intermediate filament organization, dimer binding to form heterotetramers, and end-to-end linkage of the polymers to form keratin filaments [12,17]. Though not yet well understood, the

ability of the head domain to confer tissue-specific properties to keratins is attributed to post-translational modification of this region, which possesses numerous sites that serve as substrates for phosphorylation [11,17].

Before this report, no keratin mutations in the head domain of either K3 or K12 had been identified that are presumed to cause MECD, although head domain mutations in other keratin proteins have been implicated in various dermatologic disorders, including epidermolysis bullosa simplex [11]. Nielsen et al. previously reported two single

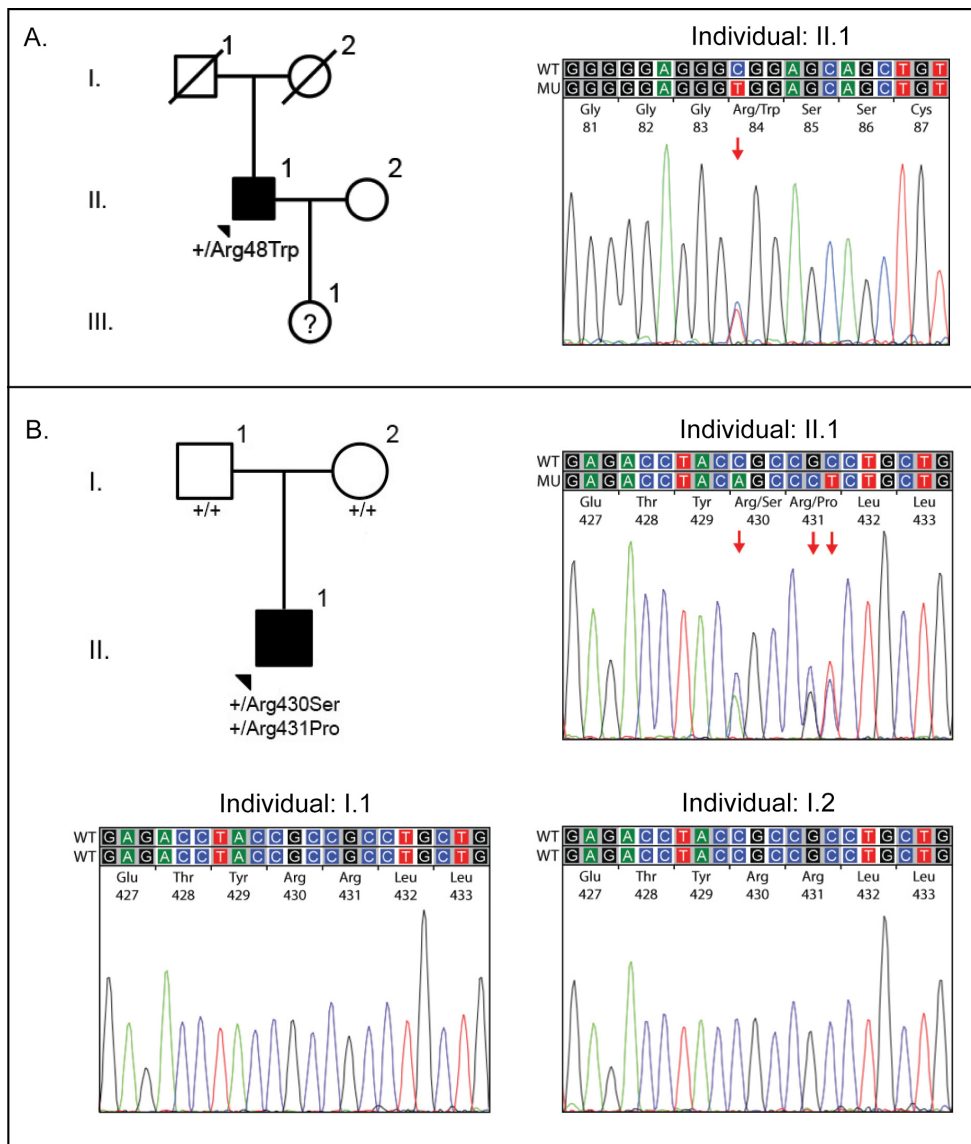


Figure 2. Pedigrees and chromatograms of two individuals with MECD. **A:** Pedigree of family of proband 1 and chromatogram demonstrating a portion of *KRT3* exon 1 in the proband. The chromatogram demonstrates a single heterozygous nucleotide change, c.250C>T, in exon 1 of *KRT3*. **B:** Pedigree of family of proband 2 and chromatograms demonstrating a portion of *KRT12* exon 6 in the proband and his unaffected parents. The chromatograms reveal a heterozygous insertion/deletion variant

(c.1288_1293delCGCCGinsAGCCCT) in proband 2 (II:1) that is not present in the proband's father (I:1) or mother (I:2). Filled symbols represent affected individuals; unfilled symbols represent unaffected individuals; question marks indicate individuals of unknown affected status; symbols with a diagonal line represent deceased individuals; arrowhead designates the proband. Below each symbol in which screening of *KRT3* and *KRT12* was performed, the results are given as wild-type (+) or the identified mutation is shown.

TABLE 2. DETERMINATION OF PATERNITY FOR PROBAND 2 BY GENOTYPING FOR A SEX-ASSOCIATED MARKER, AMELOGENIN (AMEL), AND 15 SHORT TANDEM REPEATS.

Allelic Marker	Father (CDDL267)		Child (CDDL266)		Mother (CDDL268)		Random Match Probability [38]
AMEL	X	Y	Y	X	X	X	N/A
CSF1PO	10	13	13	12	12	12	0.112
D13S317	11	12	12	9	9	13	0.085
D16S539	11	12	12	12	12	12	0.089
D18S51	12	18	18	12	12	12	0.028
D21S11	30	32.2	32.2	29	29	29	0.039
D3S1358	18	17	17	16	16	14	0.075
D5S818	13	12	12	11	11	10	0.158
D7S820	8	9	9	8	8	12	0.065
D8S1179	13	10	10	10	10	12	0.067
FGA	20	22	22	20	20	22	0.036
PENTA D	10	13	13	12	12	9	0.004
PENTA E	12	7	7	13	13	12	0.176
TH01	7	9.3	9.3	9	9	7	0.081
TPOX	11	9	9	11	11	11	0.195
VWA	18	18	18	17	17	15	0.062

Note: There is a greater than 99.999% percent probability that both parents are the biologic parents.

nucleotide polymorphisms (SNVs), c.43C>T (p.(Pro15Ser)) and c.55C>T (p.(Arg19Trp)), in the head domain of K12 in a family with ocular findings of MECD [18]. However, neither of the SNVs is likely pathogenic, as the MAF for each of these variants is 0.3095 and 0.0537, respectively, and the affected family members harbored a presumed pathogenic novel heterozygous mutation in the helix-initiation motif of K12. The K3 mutation we report in proband 1 is the sole coding region variant identified in *KRT3* and *KRT12* with an MAF of less than 0.05, although the associated MAF of 0.0076 is likely greater than the population prevalence of MECD. Additionally, although PolyPhen-2 and PANTHER predicted the variant to be damaging to protein function, SIFT analysis predicted tolerance of the variant. Despite the questions regarding the variant's pathogenicity, it remains

possible that the variant is associated with MECD, given the well-established association between keratin mutations and MECD. Unfortunately, as the parents of the proband were unavailable for examination, we were unable to establish an association between p.(Arg84Trp) in *KRT3* and MECD in other members of this family, and thus present it as a variant of uncertain significance.

Previous studies by Liao et al. and Allen et al. provided a proposed mechanism for how identified *KRT3* and *KRT12* mutations lead to the development of the corneal epithelial abnormalities that characterize Meesmann corneal dystrophy [19,20]. These investigators demonstrated a disruption of the normal intracellular keratin filament formation in cultured corneal epithelial cells transfected with mutant cDNA constructs, as well as rescue of normal keratin filament

TABLE 3. SUMMARY OF IN SILICO ANALYSIS RESULTS.

Gene	Nucleotide change	Amino acid change	Poly-phen-2	SIFT	PANTHER	ConSurf (score*)
<i>KRT3</i>	c.250C>T	p.(Arg84Trp)	Probably damaging	Tolerated	Probably damaging	Slightly variable (4)
<i>KRT12</i>	c.1288_1293delCGCCG<ins>AGCCCT	p.(Arg430_Arg431del<ins>SerPro)	Probably damaging	Probably damaging	Probably damaging	High (9)

* Scale: 1 to 9.

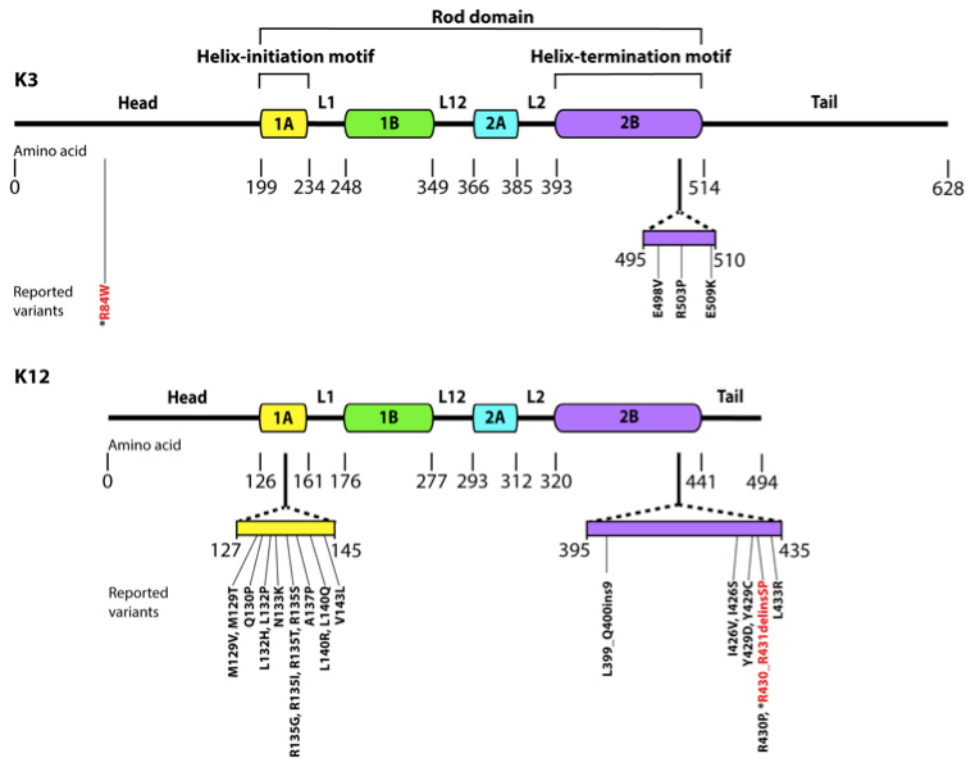


Figure 3. Protein structure of K3 and K12, constructed using data from the [Human Intermediate Filament Database](#). Each intermediate filament consists of an N-terminal head domain, a central α -helical rod domain, and a C-terminal tail domain. The rod domain is composed of four helical segments (1A (helix-initiation motif), 1B, 2A, and 2B (helix-termination motif)), which are connected to each other by non-helical linker regions (L1, L12, L2). Variants reported in current (*) and previous studies are depicted in their respective amino acid locations.

formation with allele-specific siRNA inhibition of the mutant allele [19,20]. Although it is likely that each of the identified mutations in *KRT3* and *KRT12*, including those that we report, also causes a disruption of the intracellular keratin filament network, similar functional studies must be performed to provide additional evidence for, or alternatively, to provide evidence against, the pathogenicity of each variant.

To date, all 25 mutations in *KRT3* and *KRT12* identified in individuals with MECD have been located in the helix boundary motifs of the respective keratin proteins (Figure 3). The majority (15/25) of the mutations are in the helix-initiation motif of K12; the remainder are in the helix-termination motifs of K3 and K12. We present a novel mutation, and the first reported indel, in *KRT12* associated with a previously unreported phenotype of MECD, which we demonstrate to have arisen spontaneously. De novo mutations have been identified in three other genes associated with corneal dystrophies: *TGFBI* (gene ID #21810; OMIM #601692); *ZEB1* (gene ID #21417; OMIM #189909), associated with posterior polymorphous corneal dystrophy 3; and *UBIADI* (gene ID #29914; OMIM #611632; associated with Schnyder corneal dystrophy) [21-25]. Such cases of de novo dominantly inherited corneal dystrophies highlight the utility of molecular genetic analysis to confirm the diagnosis of a suspected corneal dystrophy that is questioned given the absence of a family history. We

also report a missense mutation of unknown significance in *KRT3*, only the fourth to be associated with MECD and the first in the head domain of K3. Although this variant has not been demonstrated to be pathogenic, the possibility that disease-causing variants associated with MECD may not be restricted to primary sequence alterations of either the helix-initiation or helix-termination motifs of K3 and K12 should be considered.

APPENDIX 1. PRIMER SEQUENCES AND CONDITIONS USED FOR PCR.

Note: letters indicate primer pairs amplifying different regions of an exon, whereas numbers indicate alternative primer pairs used to sequence the entirety of an exon. To access the data, click or select the words "[Appendix 1.](#)"

APPENDIX 2. IDENTIFIED KRT3 AND KRT12 VARIANTS WITH MINOR ALLELE FREQUENCIES GREATER THAN 0.05.

*Homozygous change. To access the data, click or select the words "[Appendix 2.](#)"

ACKNOWLEDGMENTS

Funding was provided by National Eye Institute grants R01EY022082 (A.J.A.) and P30EY000331 (core grant), an unrestricted grant from Research to Prevent Blindness, and the Stein Eye Institute Medical Student Research Program (J.L.C.). The authors have no commercial or conflicting interests with the work published herein.

REFERENCES

- Pameijer JK. Über eine fremdartige familiäre oberflächliche Hornhaut-veränderung. *Klin Monatsbl Augenheilkd* 1935; 95:516-7. .
- Alois Meesmann FW. Klinische und anatomische Untersuchungen über eine bisher unbekannte, dominant vererbte. Epithel Dystrophie der Hornhaut 1939; 103:361-91. .
- Weiss JS, Moller HU, Aldave AJ, Seitz B, Bredrup C, Kivela T, Munier FL, Rapuano CJ, Nischal KK, Kim EK, Sutphin J, Busin M, Labbe A, Kenyon KR, Kinoshita S, Lisch W. IC3D classification of corneal dystrophies—edition 2. *Cornea* 2015; 34:117-59. [PMID: 25564336].
- Thiel HJ, Behnke H. [On the extent of variation of hereditary epithelial corneal dystrophy (Meesmann-Wilke type)]. *Ophthalmologica Journal international d'ophtalmologie International journal of ophthalmology Z Augenheilkd* 1968; 155:81-6. .
- Stocker FW, Holt LB. A rare form of hereditary epithelial dystrophy of the cornea: a genetic, clinical, and pathologic study. *Trans Am Ophthalmol Soc* 1954-1955; 52:133-44. [PMID: 13274420].
- Irvine AD, Corden LD, Swensson O, Swensson B, Moore JE, Frazer DG, Smith FJ, Knowlton RG, Christophers E, Rochels R, Uitto J, McLean WH. Mutations in cornea-specific keratin K3 or K12 genes cause Meesmann's corneal dystrophy. *Nat Genet* 1997; 16:184-7. [PMID: 9171831].
- Jalbert I, Stapleton F. Management of symptomatic Meesmann dystrophy. *Optom Vis Sci* 2009; 86:E1202-6. [PMID: 19741557].
- Hassan H, Thaug C, Ebenezer ND, Larkin G, Hardcastle AJ, Tuft SJ. Severe Meesmann's epithelial corneal dystrophy phenotype due to a missense mutation in the helix-initiation motif of keratin 12. *Eye (Lond)* 2013; 27:367-73. [PMID: 23222558].
- Irvine AD, Coleman CM, Moore JE, Swensson O, Morgan SJ, McCarthy JH, Smith FJ, Black GC, McLean WH. A novel mutation in KRT12 associated with Meesmann's epithelial corneal dystrophy. *Br J Ophthalmol* 2002; 86:729-32. [PMID: 12084738].
- Szaflik JP, Oldak M, Maksym RB, Kaminska A, Pollak A, Udziela M, Ploski R, Szaflik J. Genetics of Meesmann corneal dystrophy: a novel mutation in the keratin 3 gene in an asymptomatic family suggests genotype-phenotype correlation. *Mol Vis* 2008; 14:1713-8. [PMID: 18806880].
- Chamcheu JC, Siddiqui IA, Syed DN, Adhmi VM, Liovic M, Mukhtar H. Keratin gene mutations in disorders of human skin and its appendages. *Arch Biochem Biophys* 2011; 508:123-37. [PMID: 21176769].
- Hatzfeld M, Burba M. Function of type I and type II keratin head domains: their role in dimer, tetramer and filament formation. *J Cell Sci* 1994; 107:1959-72. [PMID: 7527050].
- Yoon MK, Warren JF, Holsclaw DS, Gritz DC, Margolis TP. A novel arginine substitution mutation in 1A domain and a novel 27 bp insertion mutation in 2B domain of keratin 12 gene associated with Meesmann's corneal dystrophy. *Br J Ophthalmol* 2004; 88:752-6. [PMID: 15148206].
- McLean WH, Lane EB. Intermediate filaments in disease. *Curr Opin Cell Biol* 1995; 7:118-25. [PMID: 7538772].
- Nishida K, Honma Y, Dota A, Kawasaki S, Adachi W, Nakamura T, Quantock AJ, Hosotani H, Yamamoto S, Okada M, Shimomura Y, Kinoshita S. Isolation and chromosomal localization of a cornea-specific human keratin 12 gene and detection of four mutations in Meesmann corneal epithelial dystrophy. *Am J Hum Genet* 1997; 61:1268-75. [PMID: 9399908].
- Irvine AD, McLean WH. Human keratin diseases: the increasing spectrum of disease and subtlety of the phenotype-genotype correlation. *Br J Dermatol* 1999; 140:815-28. [PMID: 10354017].
- Snider NT, Omary MB. Post-translational modifications of intermediate filament proteins: mechanisms and functions. *Nat Rev Mol Cell Biol* 2014; 15:163-77. [PMID: 24556839].
- Nielsen K, Orntoft T, Hjortdal J, Rasmussen T, Ehlers N. A novel mutation as the basis for asymptomatic meesmann dystrophy in a Danish family. *Cornea* 2008; 27:100-2. [PMID: 18245975].
- Liao H, Irvine AD, Macewen CJ, Weed KH, Porter L, Corden LD, Gibson AB, Moore JE, Smith FJ, McLean WH, Moore CB. Development of allele-specific therapeutic siRNA in Meesmann epithelial corneal dystrophy. *PLoS One* 2011; 6:e28582-[PMID: 22174841].
- Allen EH, Atkinson SD, Liao H, Moore JE, Leslie Pedrioli DM, Smith FJ, McLean WH, Moore CB. Allele-specific siRNA silencing for the common keratin 12 founder mutation in Meesmann epithelial corneal dystrophy. *Invest Ophthalmol Vis Sci* 2013; 54:494-502. [PMID: 23233254].
- Jang MS, Roldan AN, Frausto RF, Aldave AJ. Posterior polymorphous corneal dystrophy 3 is associated with agenesis and hypoplasia of the corpus callosum. *Vision Res* 2014; 100:88-92. [PMID: 24780443].
- Krafchak CM, Pawar H, Moroi SE, Sugar A, Lichter PR, Mackey DA, Mian S, Nairus T, Elner V, Schteingart MT, Downs CA, Kijek TG, Johnson JM, Trager EH, Rozsa FW, Mandal MN, Epstein MP, Vollrath D, Ayyagari R, Boehnke M, Richards JE. Mutations in TCF8 cause posterior polymorphous corneal dystrophy and ectopic expression of COL4A3 by corneal endothelial cells. *Am J Hum Genet* 2005; 77:694-708. [PMID: 16252232].

23. Romero P, Moraga M, Herrera L. Different phenotypes of lattice corneal dystrophy type I in patients with 417C>T (R124C) and 1762A>G (H572R) mutations in TGFBI (BIGH3). *Mol Vis* 2010; 16:1601-9. [PMID: 20806046].
24. Tanhehco TY, Eifrig DE Jr, Schwab IR, Rapuano CJ, Klintworth GK. Two cases of Reis-Bucklers corneal dystrophy (granular corneal dystrophy type III) caused by spontaneous mutations in the TGFBI gene. *Arch Ophthalmol* 2006; 124:589-93. [PMID: 16606891].
25. Zhao XC, Nakamura H, Subramanyam S, Stock LE, Gillette TE, Yoshikawa S, Ma X, Yee RW. Spontaneous and inheritable R555Q mutation in the TGFBI/BIGH3 gene in two unrelated families exhibiting Bowman's layer corneal dystrophy. *Ophthalmology* 2007; 114:e39-46. [PMID: 17980739].
26. Chen YT, Tseng SH, Chao SC. Novel mutations in the helix termination motif of keratin 3 and keratin 12 in 2 Taiwanese families with Meesmann corneal dystrophy. *Cornea* 2005; 24:928-32. [PMID: 16227835].
27. Clausen I, Duncker GI, Grunauer-Kloevekorn C. Identification of a novel mutation in the cornea specific keratin 12 gene causing Meesmann's corneal dystrophy in a German family. *Mol Vis* 2010; 16:954-60. [PMID: 20577595].
28. Nichini O, Manzi V, Munier FL, Schorderet DF. Meesmann corneal dystrophy (MECD): report of 2 families and a novel mutation in the cornea specific keratin 12 (KRT12) gene. *Ophthalmic Genet* 2005; 26:169-73. [PMID: 16352477].
29. Corden LD, Swensson O, Swensson B, Smith FJ, Rochels R, Uitto J, Mc LW. Molecular genetics of Meesmann's corneal dystrophy: ancestral and novel mutations in keratin 12 (K12) and complete sequence of the human KRT12 gene. *Exp Eye Res* 2000; 70:41-9. [PMID: 10644419].
30. Ehlers N, Hjortdal J, Nielsen K, Thiel HJ, Orntoft T. Phenotypic variability in Meesmann's dystrophy: clinical review of the literature and presentation of a family genetically identical to the original family. *Acta ophthalmologica* 2008; 86:40-4. [PMID: 17986293].
31. Ogasawara M, Matsumoto Y, Hayashi T, Ohno K, Yamada H, Kawakita T, Dogru M, Shimazaki J, Tsubota K, Tsuneoka H. KRT12 mutations and in vivo confocal microscopy in two Japanese families with Meesmann corneal dystrophy. *Am J Ophthalmol* 2014; 157:93-102. [PMID: 24099278].
32. Corden LD, Swensson O, Swensson B, Rochels R, Wannke B, Thiel HJ, McLean WH. A novel keratin 12 mutation in a German kindred with Meesmann's corneal dystrophy. *Br J Ophthalmol* 2000; 84:527-30. [PMID: 10781519].
33. Wang LJ, Tian X, Zhang QS, Liu L. Analysis of mutation in KRT12 gene in a Chinese family with Meesmann's corneal dystrophy. *Zhonghua Yan Ke Za Zhi* 2007; 43:885-9. [PMID: 18201524].
34. Takahashi K, Takahashi K, Murakami A, Okisaka S, Kimura T, Kanai A. Heterozygous Ala137Pro mutation in keratin 12 gene found in Japanese with Meesmann's corneal dystrophy. *Jpn J Ophthalmol* 2002; 46:673-4. [PMID: 12543196].
35. Coleman CM, Hannush S, Covello SP, Smith FJ, Uitto J, McLean WH. A novel mutation in the helix termination motif of keratin K12 in a US family with Meesmann corneal dystrophy. *Am J Ophthalmol* 1999; 128:687-91. [PMID: 10612503].
36. Sullivan LS, Baylin EB, Font R, Daiger SP, Pepose JS, Clinch TE, Nakamura H, Zhao XC, Yee RW. A novel mutation of the Keratin 12 gene responsible for a severe phenotype of Meesmann's corneal dystrophy. *Mol Vis* 2007; 13:975-80. [PMID: 17653038].
37. Seto T, Fujiki K, Kishishita H, Fujimaki T, Murakami A, Kanai A. A novel mutation in the cornea-specific keratin 12 gene in Meesmann corneal dystrophy. *Jpn J Ophthalmol* 2008; 52:224-6. [PMID: 18661274].
38. Butler JM, Decker AE, Vallone PM, Kline MC. Allele frequencies for 27 Y-STR loci with U.S. Caucasian, African American, and Hispanic samples. *Forensic Sci Int* 2006; 156:250-60. [PMID: 16410169].

Articles are provided courtesy of Emory University and the Zhongshan Ophthalmic Center, Sun Yat-sen University, P.R. China. The print version of this article was created on 31 December 2015. This reflects all typographical corrections and errata to the article through that date. Details of any changes may be found in the online version of the article.